

ANTIBODIES TO GRANULOCYTIC *EHRlichia* IN MOOSE, RED DEER, AND ROE DEER IN NORWAY

Snorre Stuen,^{1,4} Johan Åkerstedt,² Karin Bergström,³ and Kjell Handeland²

¹ Norwegian School of Veterinary Science, Department of Sheep and Goat Research, Kyrkjevegen 332/334, N-4325 Sandnes, Norway

² Section of Wildlife Diseases, National Veterinary Institute, P.O. Box 8156, N-0033 Oslo, Norway

³ National Veterinary Institute, Department of Bacteriology, P.O. Box 7073, S-75007 Uppsala, Sweden

⁴ Corresponding author (e-mail: Snorre.Stuen@veths.no)

ABSTRACT: Serum samples from 104 moose (*Alces alces*), 124 red deer (*Cervus elaphus*) and 114 roe deer (*Capreolus capreolus*), collected from different counties in southern Norway from 1994 to 2000, were analysed by an indirect immunofluorescent antibody staining method for antibodies to *Ehrlichia equi*. The overall seroprevalences for granulocytic *Ehrlichia* spp. in moose, red deer, and roe deer from *Ixodes ricinus* infested counties were 43%, 55%, and 96%, respectively. Antibody prevalence was significantly higher in roe deer than in moose and red deer ($P < 0.001$). Mean antibody titers ($\log_{10} \pm SD$) to *E. equi* in sera from moose, red deer, and roe deer were 1:1,497 (3.17 ± 0.646), 1:234 (2.37 ± 0.424) and 1:676 (2.83 ± 0.404), respectively. The present work indicates that all these wild ruminant species are exposed to granulocytic *Ehrlichia* in Norway.

Key words: *Alces alces*, *Capreolus capreolus*, *Cervus elaphus*, *Ehrlichia equi*, ehrlichiosis, moose, red deer, roe deer, serosurvey.

INTRODUCTION

Tick-borne fever (TBF) caused by *Ehrlichia phagocytophila* and transmitted by the tick *Ixodes ricinus*, was first described in Scotland in 1932, but has since been diagnosed in domestic ruminants in several countries in Europe (Woldehiwet, 1983). Tick-borne fever is a common disease in domestic ruminants along the coast of southern Norway (Stuen, 1997; 1998), where *I. ricinus* and wild cervids are common.

In cervids, granulocytic *Ehrlichia* have been reported in mule deer (*Odocoileus hemionus hemionus*), black-tailed deer (*O. hemionus columbianus*), elk (*Cervus elaphus nannodes*), and white-tailed deer (*Odocoileus virginianus*) in the USA (Belongia et al., 1997; Foley et al., 1998), in red deer (*Cervus elaphus scoticus*) and roe deer (*Capreolus capreolus*) in the UK, Slovenia and Switzerland (Foggie, 1951; McDiarmid, 1965; Alberdi et al., 2000; Liz et al., 2000; Petrovec et al., 2000), and in moose (*Alces alces*) in Norway (Jenkins et al., 2001).

The purpose of the present study was to survey red deer, roe deer, and moose for antibodies against granulocytic *Ehrlichia*

in different *I. ricinus* infested areas in southern Norway.

MATERIALS AND METHODS

A total of 342 randomly chosen serum samples, which had been stored at $-20\text{ }^{\circ}\text{C}$, were obtained from the serum bank for wild cervids at the Section of Wildlife Diseases, National Veterinary Institute, Oslo, Norway. Sera were from moose ($n = 104$), red deer ($n = 124$), and roe deer ($n = 114$). Blood was mainly collected from the thoracic cavity of healthy animals shot by hunters from 1994 to 2000. Moose, red deer, and roe deer were sampled for 3, 2, and 1 yr, respectively. All animals in this study were more than 4-mo-old.

Animals from each geographic area were only sampled once, except that sera from both roe deer and red deer in the county of Sør-Trøndelag were collected from animals on the island of Hitra. These last samples were obtained during September to October, although in two different years. The origin of animals examined is shown in Figure 1.

Serum samples were analysed for antibodies to granulocytic *Ehrlichia* by an indirect immunofluorescence antibody assay (IFA) to *E. equi* (Artursson et al., 1999). Briefly, two-fold dilutions of sera were added to slides precoated with *E. equi* antigen (Protatek, St. Paul, Minnesota, USA). The conjugate used was fluorescein-isothiocyanate (FITC)-labelled rabbit anti-deer immunoglobulin G (Kierkegaard and Perry Laboratories, Gaithersburg, Maryland,

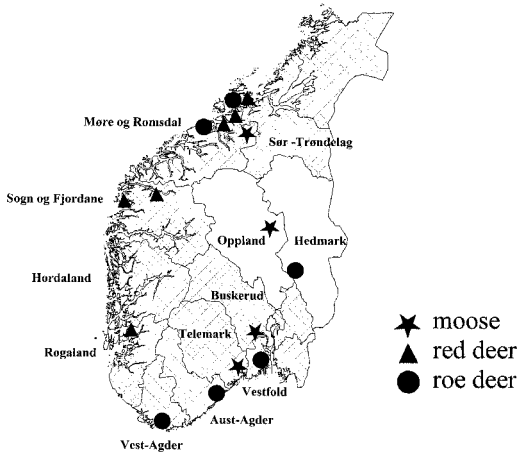


FIGURE 1. Geographic distribution of moose (*Alces alces*), red deer (*Cervus elaphus*), and roe deer (*Capreolus capreolus*) examined for antibodies to *Ehrlichia equi* in different counties of Norway. Shaded area: Counties with a coastal distribution of *Ixodes ricinus*.

USA). Sera were screened for antibodies at dilution 1:40. If positive, the serum was further diluted and retested. A titer of 1:40 or more was regarded as positive, and has previously been selected as a cut-off titer in samples from dogs, horses, and sheep (Artursson et al., 1999; Stuen et al., 1998; Egenvall et al., 2000).

Reactivity of the *Ehrlichia* antigens used was confirmed by testing positive sera from red deer experimentally infected with *E. phagocytophila* (Stuen et al., 2001) and by testing granulocytic *Ehrlichia* positive sera from natural infected red deer and roe deer (P. Zeman, Regional Centre of Hygiene, Prague, Czech Republic). Sera from cervids living in *I. ricinus* free areas were used as negative controls.

The overall seroprevalence in each species was estimated, as well as stratified by geographic location, sex, and age. The following two age categories were used: calves (<1 yr) and older animals (>1 yr). Statistical analyses on seroprevalences were performed using the chi-square contingency test, and antibody titers were compared using a two-sample *t*-test. *P*-value of <0.05 was considered significant. All analyses were performed using Statistix® (version 4.0, Analytical Software, Tallahassee, Florida, USA).

RESULTS

Seroprevalence and antibody titers are summarized in Table 1. Seroprevalence to *E. equi* in moose from Telemark was sig-

nificantly higher than the prevalence in moose from the other two *I. ricinus* infested counties, Buskerud and Møre og Romsdal ($P < 0.001$). The corresponding antibody titers (\log_{10}) were also significantly higher ($P < 0.05$). The serologic prevalence in red deer from some counties with *I. ricinus* differed significantly, while the seroprevalence in roe deer in each of the five *I. ricinus* counties examined were not significantly different (Table 1).

Seroprevalence to *E. equi* was significantly higher in roe deer than in red deer in the county of Sør-Trøndelag ($P < 0.001$). In addition, the corresponding antibody titers (\log_{10}) varied significantly between these two cervid species in this area ($P < 0.01$).

A total of 43%, 55%, and 96% of the sera from moose, red deer and roe deer, respectively, grazing in counties with *I. ricinus* were seropositive (Table 1). The overall seroprevalence to *E. equi* in areas with *I. ricinus* was significantly higher in roe deer compared with the other two species ($P < 0.001$). The antibody titers (\log_{10}) to *E. equi* in seropositive samples from moose, red deer, and roe deer were significantly different: moose/red deer ($P < 0.001$), moose/roe deer ($P < 0.01$), red deer/roe deer ($P < 0.001$).

No significant difference in either seroprevalence or antibody titer (\log_{10}) were observed between males and females or between calves and older animals in *I. ricinus* infested areas.

DISCUSSION

Strong serologic cross-reactions between *E. equi*, *E. phagocytophila*, and the agent causing human granulocytic ehrlichiosis (HGE) have been reported (Dumler et al., 1995; Nicholson et al., 1997; Pusterla et al., 1997). It is therefore possible to use any of these three closely related *Ehrlichia* antigens in serosurveys. However, IgG titers may differ depending on the antigen (Bjoersdorff et al., 1999; Walls et al., 1999). However, because the *Ehrlichia* sp. in cervids in Norway is unknown

TABLE 1. Seroprevalence and antibody titer (geometric mean) to *E. equi* in moose, red deer, and roe deer from counties with *Ixodes ricinus* in southern Norway. An antibody titer of 1:40 or more was considered positive.

County	Moose			Red deer			Roe deer		
	n	Sero-prevalence (%)	Antibody titer	n	Sero-prevalence (%)	Antibody titer	n	Sero-prevalence (%)	Antibody titer
Aust-Agder	— ^a	—	—	—	—	—	20	100	1:562
Buskerud ^b	20	20	1:95	—	—	—	—	—	—
Hedmark ^c	—	—	—	—	—	—	14	7 ^e	1:1,288
Hordaland	—	—	—	4	100	1:224	—	—	—
Møre og Romsdal ^d	27	15	1:269	20	35	1:132	20	100	1:813
Oppland ^c	20	0	Negative	20	35	1:158	—	—	—
Rogaland	—	—	—	16	25	1:224	—	—	—
Sogn og Fjordane ^d	—	—	—	20	95	1:245	—	—	—
Sør-Trøndelag	—	—	—	24 ^f	95	1:331	—	—	—
Telemark	—	—	—	20	25	1:158	20	100	1:692
Vest-Agder	37	76	1:2,754	—	—	—	—	—	—
Vestfold	—	—	—	—	—	—	20	90	1:692
Vestfold	—	—	—	—	—	—	20	90	1:617
Total	104	43	1:1,497	124	55	1:234	114	96	1:676

^a No samples.

^b Marginal distribution of *I. ricinus*.

^c No known distribution of *I. ricinus*.

^d Two different locations.

^e Only one animal was seropositive; not included in the total seroprevalence.

^f Four seropositive animals had been housed indoors for more than 6 mo before sampling.

and antigen from *E. phagocytophila* was not available, we chose to use *E. equi* for antigen in the IFA.

Interpretation of antibody results in wild ruminants without additional laboratory tests such as western blot or PCR analyses must be made with caution. Serologic cross-reactivity between *E. chaffeensis* and granulocytic *Ehrlichia* has been observed (Wong et al., 1997; Comer et al., 1999), but *E. chaffeensis* infection has not been confirmed in Europe (Brouqui, 1999). Heat-shock proteins may also cause cross-reactivity between *B. burgdorferi* and *Ehrlichia* (Wormser et al., 1996; Wong et al., 1997; Ijdo et al., 1998). However, the IFA results seem to be reliable, because only one antibody positive animal was found in areas outside the normal distribution of *I. ricinus*, and the mean antibody titer in both roe deer and moose sera was high (>1: 640).

Exposure to granulocytic *Ehrlichia* is

abundant in wild cervids living in *I. ricinus* areas in Norway. Calves probably are infected during the first grazing summer. *Ixodes ricinus* is the only tick in Norway known to transmit infections to animals (Mehl et al., 1987). The only seropositive animal from areas outside the normal distribution of *I. ricinus*, was a 1.5-yr-old male roe deer. Roe deer have rather limited home ranges, but some animals, especially young males, are known to move distances of up to several 100 km (Østbye and Bjørnsen, 1990). It is likely that the seropositive roe deer may have come from a tick-infested area.

Surveys of roe deer from Switzerland and the UK showed a seroprevalence to granulocytic *Ehrlichia* of 67% and 58%, respectively (Alberdi et al., 2000; Liz et al., 2000). In Slovenia the seroprevalence to granulocytic *Ehrlichia* in red deer and roe deer was above 70% (Petrovec et al., 2000).

The significantly higher seroprevalence in roe deer compared with moose and red deer may have several explanations. One important reason may be that roe deer have relatively small home ranges, and the sampling sites in the present study comprised coastal areas which are heavily infested with ticks. This makes roe deer more exposed to ticks throughout summer, compared with moose and red deer which normally migrate to inland areas with little or no tick exposure during summer.

Exposure to *Ehrlichia* may vary in different geographic areas. The questing season for *I. ricinus* in Norway is normally from April to October, but animals may also become infested with ticks in December (Stuen et al., 1999). Most of the samples were collected from September to December, and some of the animals might therefore have been sampled while they were in an early phase of the infection with no detectable antibodies. In experimental *E. phagocytophila* infected red deer, an increase in antibody titer was first observed 2- to 3-wk after inoculation with infected blood (Stuen et al., 2001).

Four red deer calves were seropositive after having been housed indoors during wintertime for more than 6 mo. Thus serologic titers to granulocytic *Ehrlichia* may persist for several months in cervids, and animals infected during the grazing season may be seropositive the following autumn and winter. Antibody titers to granulocytic *Ehrlichia* in sheep, horses, and humans may persist for several months after primary infection (Bakken et al., 1996; Stuen et al., 1998; Artursson et al., 1999).

Red deer and roe deer graze the same areas on the island of Hitra. Although the seroprevalence within a population may vary over time, the significantly higher seroprevalence and antibody titers in roe deer compared with red deer may indicate that roe deer are more exposed to ticks and granulocytic *Ehrlichia* infection. However, experimental *E. phagocytophila* infection in red deer indicated that some in-

fectured animals may remain seronegative for several months (Stuen et al., 2001).

A negative or low antibody response will underestimate the actual prevalence of exposed animals, and tests such as PCR analyses should be conducted, in order to identify all *Ehrlichia* infected animals. Other investigations indicated that prevalence to HGE agent estimated by IFA was low compared with PCR in white-tailed deer, mule deer, black-tailed deer, and elk (Belongia et al., 1997; Foley et al., 1998).

Studies in the UK and Slovenia indicated that roe deer are reservoir hosts for granulocytic *Ehrlichia* infection in Europe (Petrovec et al., 1997; Alberdi et al., 2000). In the present investigation, evidence was found that both moose and red deer are exposed to this infection in Norway. However, further work must be done to establish if different species of wild cervids could act as reservoir hosts and be of epidemiologic importance for the maintenance of granulocytic *Ehrlichia* infection in domestic animals and humans.

ACKNOWLEDGEMENTS

The authors wish to thank U.-B. Wikstrøm for excellent technical assistance and P. Zeman for the use of positive serum samples from red and roe deer.

LITERATURE CITED

- ARTURSSON, K., A. GUNNARSSON, U.-B. WIKSTRØM, AND E. OLSSON ENGVALL. 1999. A serological and clinical follow-up in horses with confirmed equine granulocytic ehrlichiosis. *Equine Veterinary Journal* 31: 473-477.
- ALBERDI, M. P., A. R. WALKER, AND K. A. URQUHART. 2000. Field evidence that roe deer (*Capreolus capreolus*) is a natural host for *Ehrlichia phagocytophila*. *Epidemiology and Infection* 124: 315-323.
- BAKKEN, J. S., J. KRUEH, C. WILSON-NORDSKOG, R. L. TILDEN, K. ASANOVICH, AND J. S. DUMLER. 1996. Clinical and laboratory characteristics of human granulocytic ehrlichiosis. *Journal of the American Medical Association* 275: 199-205.
- BELONGIA, E. A., K. D. REED, P. D. MITCHELL, C. P. KOLBERT, D. H. PERSING, J. S. GILL, AND J. J. KAZMIERCZAK. 1997. Prevalence of granulocytic *Ehrlichia* infection among white-tailed deer in Wisconsin. *Journal of Clinical Microbiology* 35: 1465-1468.

- BJOERSDORFF, A., P. BROUQUI, I. ELIASSON, R. F. MAS-SUNG, B. WITTESJÖ, AND J. BERGLUND. 1999. Serological evidence of *Ehrlichia* infection in Swedish Lyme borreliosis patients. *Scandinavian Journal of Infectious Diseases* 31: 51–55.
- BROUQUI, P. 1999. Ehrlichiosis in Europe. In *Rickettsiae and rickettsial diseases at the turn of the third millennium*, D. Raoult and P. Brouqui (eds.). Elsevier, Paris, France, pp. 220–232.
- COMER, J. A., W. L. NICHOLSON, J. G. OLSON, AND J. E. CHILDS. 1999. Serologic testing for human granulocytic ehrlichiosis at a national referral center. *Journal of Clinical Microbiology* 37: 558–564.
- DUMLER, J. S., K. M. ASANOVICH, J. S. BAKKEN, P. RICHTER, R. KIMSEY, AND J. E. MADIGAN. 1995. Serologic cross-reaction among *Ehrlichia equi*, *Ehrlichia phagocytophila* and human granulocytic *Ehrlichia*. *Journal of Clinical Microbiology* 33: 1098–1103.
- ENGVALL, A., I. LILLIEHÖÖK, A. BJÖERSDORFF, E. O. ENGVALL, E. KARLSTAM, K. ARTURSSON, M. HELDTANDER, AND A. GUNNARSSON. 2000. Detection of granulocytic *Ehrlichia* species DNA by PCR in persistently infected dogs. *The Veterinary Record* 146: 186–190.
- FOGGIE, A. 1951. Studies on the infectious agent of tick-borne fever in sheep. *Journal of Pathology and Bacteriology* 63: 1–15.
- FOLEY, J. E., J. E. BARLOUGH, R. B. KIMSEY, J. E. MADIGAN, E. DEROCKE, AND A. POLAND. 1998. *Ehrlichia* spp. in cervids from California. *Journal of Wildlife Diseases* 34: 731–737.
- IJDO, J., Y. ZHANG, M. L. ANDERSSON, D. GOLDBERG, AND E. FIKRIG. 1998. Heat shock protein 70 of the agent of human granulocytic ehrlichiosis binds to *Borrelia burgdorferi* antibodies. *Clinical and Diagnostic Laboratory Immunology* 5: 118–120.
- JENKINS, A., K. HANDELAND, S. STUEN, L. SCHOULS, I. VAN DE POL, R.-T. MEEN, AND B.-E. KRISTIANSEN. 2001. Ehrlichiosis in a moose calf in Norway. *Journal of Wildlife Diseases* 37: 201–203.
- LIZ, J. S., L. ANDERES, J. W. SUMNER, L. GERN, B. RUTTI, AND M. BROSSARD. 2000. Granulocytic *Ehrlichiae* in tick vectors and wild mammal reservoirs in Switzerland. Proceedings of the 15th meeting of the American Society for Rickettsiology, Captiva Island, Florida, USA, Abstract no. 57.
- MCDIARMID, A. 1965. Modern trends in animal health and husbandry. Some infectious diseases in free-living wildlife. *British Veterinary Journal* 121: 245–257.
- MEHL, R., P. SANDVEN, AND L. R. BRAATHEN. 1987. The tick *Ixodes ricinus*. *Tidsskrift for den Norske Lægeforening* 107: 1642–1644. [In Norwegian].
- NICHOLSON, W. L., L. A. COMER, J. W. SUMNER, C. GINGRICH-BAKER, R. T. COUGHLIN, L. A. MAGNARELLI, J. G. OLSON, AND J. E. CHILDS. 1997. An indirect immunofluorescence assay using a cell culture-derived antigen for detection of antibodies to the agent of human granulocytic ehrlichiosis. *Journal of Clinical Microbiology* 35: 1510–1516.
- ØSTBYE, E., AND B. BJØRNSSEN. 1990. The roe deer. In *Norges dyr. Pattedyrene 2*, A. Semb-Johanson and R. Frislid (eds.). J.W. Cappelen Forlag AS, Oslo, Norway, pp. 128–147. [In Norwegian].
- PETROVEC, M., A. BIDOVEC, T. AVSIC-ZUPANC, S. KOREN, J. W. SUMNER, W. L. NICHOLSON, AND J. E. CHILDS. 1997. The role of roe-deer (*Capreolus capreolus*) as a reservoir of the agent of human granulocytic ehrlichiosis in Europe. Proceedings of the 13th meeting of the American Society for Rickettsiology, Champion, Philadelphia, USA, Abstract no. 103.
- , J. W. SUMNER, W. L. NICHOLSON, J. E. CHILDS, AND T. AVSIC-ZUPANC. 2000. Infection of roe and red deer with *Ehrlichia* sp. in Slovenia. Proceedings of the 15th meeting of the American Society for Rickettsiology, Captiva Island, Florida, USA, Abstract no. 40.
- PUSTERLA, N., C. WOLFENBERGER, R. GERBER-BRETSCHER, AND H. LUTZ. 1997. Comparison of indirect immunofluorescence for *Ehrlichia phagocytophila* and *Ehrlichia equi* in horses. *Equine Veterinary Journal* 29: 490–492.
- STUEN, S. 1997. The distribution of tick-borne fever (TBF) in Norway. *Norsk Veterinærtidsskrift* 109: 83–87. [In Norwegian].
- . 1998. Sjødogg (tick-borne fever)—a historical review. *Norsk Veterinærtidsskrift* 110: 703–706. [In Norwegian].
- , E. OLSSON ENGVALL, AND K. ARTURSSON. 1998. Persistence of *Ehrlichia phagocytophila* infection in lambs in relation to clinical parameters and antibody responses. *The Veterinary Record* 143: 553–555.
- , B. BRÄNDSTRÖM, AND J. SLETTEBØ. 1999. A case of ovine tick-borne fever in December in Norway. *Acta Veterinaria Scandinavica* 40: 351–354.
- , K. HANDELAND, T. FRAMMARSVIK, AND K. BERGSTRÖM. 2001. Experimental *Ehrlichia phagocytophila* infection in red deer (*Cervus elaphus*). *The Veterinary Record* 149: 390–392.
- WALLS, J. J., M. AGUERO-ROSENFELD, J. S. BAKKEN, J. L. GOODMAN, D. HOSSAIN, R. C. JOHNSON, AND J. S. DUMLER. 1999. Inter- and intralaboratory comparison of *Ehrlichia equi* and human granulocytic ehrlichiosis (HGE) agent strains for serodiagnosis of HGE by the immunofluorescent-antibody test. *Journal of Clinical Microbiology* 37: 2968–2973.
- WOLDEHIWET, Z. 1983. Tick-borne fever: A review. *Veterinary Research Communications* 6: 163–175.
- WONG, S. J., G. S. BRADY, AND J. S. DUMLER. 1997. Serological responses to *Ehrlichia equi*, *Ehrlichia*

chaffeensis and *Borrelia burgdorferi* in patients from New York State. *Journal of Clinical Microbiology* 35: 2198–2205.

WORMSER, G. P., H. W. HOROWITZ, J. S. DUMLER, I. SCHWARTZ, AND M. AGUERO-ROSENFELD. 1996.

False positive Lyme disease serology in human granulocytic ehrlichiosis. *Lancet* 347: 981–982.

Received for publication 21 March 2001.