

DETECTION OF VIRUS-LIKE PARTICLES IN THE LIVER OF BLACK AND WHITE RUFFED LEMURS WITH HEPATITIS

Michael B. Worley^{1,3} and Ilse H. Stalis²

¹ Virology and Immunology Laboratory and ²Department of Pathology, Center for Reproduction of Endangered Species, Zoological Society of San Diego, P.O. Box 120551, San Diego, California 92112, USA

³ Corresponding author (e-mail: mworley@sandiegozoo.org)

ABSTRACT: Two young black and white ruffed lemurs (*Varecia variegata variegata*) died at the San Diego Zoo (San Diego, California, USA) with extensive liver lesions suggestive of acute viral infection. Immunoassays performed to detect hepatitis B virus (HBV) markers were negative. Polymerase chain reaction (PCR) primers overlapping the HBV core gene produced an amplicon of approximately 411 base pairs (bp) from serum DNA of a HBV-positive western lowland gorilla (*Gorilla gorilla gorilla*) but not from serum DNA of either lemur. Cesium chloride gradient fractions of liver homogenates from both lemurs contained a peak protein fraction with a density of 1.18 g/cm³. Electron microscopic analysis of fraction contents, concentrated by ultracentrifugation, revealed numerous pleomorphic, spherical particles varying in diameter from 16–25 nm. In one of the lemurs, this peak fraction also contained a double-shelled virus-like particle 47–50 nm in diameter. The size, morphology, and density of these particles suggest they are members of the *Hepadnaviridae*, a group of hepatotropic DNA-genome viruses for which HBV is the prototype.

Key words: Hepatitis virus, lemur, liver disease, prosimian.

INTRODUCTION

Lemurs are primates that inhabit Madagascar and belong to the suborder Prosimii. All species belonging to the five distinct families in the superfamily Lemuroidea are listed as endangered by the World Conservation Union. Because of the endangered status of these primates, captive breeding programs have become an integral component of their conservation. In addition, reintroduction programs of captive-raised animals have been initiated for some species. A major objective in the intensive management of all lemurs is recognition of diseases affecting them and an understanding of their causative factors. To achieve this goal, it is imperative that investigative studies be undertaken to determine the etiology of prevalent, but poorly understood, diseases of this suborder of primates.

A summary of diseases and lesions seen in lemurs at the San Diego Zoo (San Diego, California, USA) revealed a spectrum of liver lesions that include hepatitis, hepatic necrosis, chronic hepatic degeneration, hepatoma, and hepatocellular carcinoma (Benirschke et al., 1985; Spelman et

al., 1989). Excess iron deposition (hemosiderosis) in the duodenum, liver, and spleen was present in almost all of the individuals with these lesions (Spelman et al., 1989). The degree of hemosiderosis progressed over time, leading to extensive iron overload throughout the gastrointestinal tract and a variety of other tissues. Eighty-seven percent of lemurs with hemosiderosis had histopathologic evidence of liver disease (Spelman et al., 1989). However, several lemurs had liver lesions (e.g., hepatitis, hepatic necrosis, and hepatoma) in the absence of hepatic hemosiderosis and light microscopic evidence of an infectious microorganism.

Of the many viruses associated with liver disease in humans (e.g., hepatitis viruses A–G, cytomegalovirus, Epstein-Barr virus, and yellow fever virus), acute and chronic infection with hepatitis B virus (HBV), a member of the *Hepadnaviridae*, produces liver lesions that resemble those seen in lemurs at the San Diego Zoo. Among non-human primates, evidence for hepadnavirus infection, determined by DNA sequence, has been obtained in chimpanzee (*Pan troglodytes*) (Vaudin et al., 1988; Hu et al., 2000), western lowland gorilla (*Go-*

rilla gorilla gorilla) (Grethe et al., 2000), white-handed gibbon (*Hylobates lar*) (Norder et al., 1996), orangutan (*Pongo pygmaeus*) (Warren et al., 1999), and woolly monkey (*Lagothrix lagotricha*) (Lanford et al., 1998). Natural hepadnavirus infection in apes is not usually associated with clinical signs or microscopic lesions. However, a hepadnavirus was recently isolated from a woolly monkey with fulminant hepatitis that resulted in death (Lanford et al., 1998). To our knowledge, there have not been any published reports demonstrating a potential viral etiology for liver lesions in lemurs. To determine whether a hepadnavirus might be associated with these liver lesions, we analyzed sera and liver extracts from lemurs that did not have evidence of hemosiderosis. In this report, we describe the morphologic and biophysical characteristics of hepadnavirus-like particles in liver homogenates from two black and white ruffed lemurs (*Varecia variegata variegata*) with hepatitis.

MATERIALS AND METHODS

Samples of liver from two lemurs that died at the San Diego Zoo were collected during necropsies. Tissues were fixed in 10% neutral buffered formalin, processed routinely, and stained with hematoxylin and eosin. Serum and plasma samples collected during medical examinations, as well as tissues collected during necropsy were stored in -70°C freezers. Frozen serum and liver tissue from a western lowland gorilla that was positive for HBV infection (Linnemann et al., 1984) were received from the Cincinnati Zoo for use as a positive control. Serum and tissues from a black and white ruffed lemur with no microscopic liver lesions were used as negative controls.

Serum samples from individual animals were assayed for hepatitis B surface antigen (HBsAg), antibody to HBsAg, and antibody to hepatitis B core antigen (Ausria, Ausab, and Corzyme immunoassay kits, respectively, Abbott Diagnostics, Abbott Park, Illinois, USA). In addition, immunoassays for detection of immunoglobulin G antibody to hepatitis A virus (HAV) were also performed (Havab, Abbott Diagnostics). Prior to death, the Cincinnati Zoo gorilla was also tested for hepatitis B e antigen (HBeAg), antibody to HBeAg, and both im-

munoglobulin G and M antibody to HAV (Linnemann et al., 1984).

Approximately 200 μl of serum was clarified in an Eppendorf 5415C microcentrifuge (Eppendorf Scientific, Westbury, New York, USA) at $16,000 \times G$ for 30 min prior to ultracentrifugation in a Beckman L-75 (Beckman Instruments, Fullerton, California) using a SW60 rotor at $336,840 \times G$ for 1 hr. Pelleted material was resuspended in 300 μl of lysis buffer (10 mM Tris-HCl, pH 8.0, 5 mM EDTA, 0.5% sodium dodecyl sulfate, 100 $\mu\text{g}/\text{ml}$ proteinase K) (Kaneko et al., 1989) and incubated overnight at 55°C . DNA was extracted twice with an equal volume of phenol:chloroform:isoamyl alcohol (25:24:1) followed by a single extraction with chloroform:isoamyl alcohol (24:1). DNA was precipitated in a final concentration of 1 M ammonium acetate and 2.5 volumes of ice-cold 100% ethanol overnight at -20°C . Precipitated DNA was pelleted in a microcentrifuge at $16,000 \times G$ for 30 min at 4°C . Pellets were washed once in ice-cold 70% ethanol and dried in a Savant DNA Speedvac (Thermo Savant, Holbrook, New York) for 20 min. DNA pellets were resuspended in 50–100 μl of TE (10 mM Tris-HCl, pH 7.4, 0.1 mM EDTA, pH 8.0) and stored at 4°C until use.

Approximately 300–400 mg of each frozen liver sample was thawed and minced on ice, then homogenized in a glass homogenizer in grinding buffer (20 mM Tris-HCl, pH 7.5). The suspension was sonicated twice for 15 sec each, then centrifuged in a Sorval SS-34 rotor (Kendro Laboratory Products, Newtown, Connecticut, USA) at $12,100 \times G$ for 30 min (4°C). The pellet from each sample was resuspended in grinding buffer, sonicated as described above, and centrifuged in a SS-34 rotor. Supernatants from both centrifugation steps were pooled, layered over 5 ml of 20% sucrose (weight/volume in grinding buffer), and centrifuged in a SW28 rotor (Beckman Instruments) at $72,128 \times G$ at 4°C for 18 hr. Individual pellets were resuspended in Dulbecco's phosphate buffered saline (PBS) followed by 281.98 mg/ml of CsCl to make the density 1.2090 g/ml. After centrifugation in a SW 60 rotor (Beckman Instruments) at $204,933 \times G$ at 10°C for 72 hr, gradient fractions (~ 0.25 ml) were collected by bottom puncture. The specific gravity of each fraction was determined by weight and protein content was determined by UV absorbance. Individual fractions were diluted in PBS and spun in a SW 60 rotor at $336,840 \times G$ for 1 hr. Pellets were resuspended in 20 μl of PBS of which 2 μl were examined by electron microscopy and another 2 μl were assayed for HBV surface antigen. The remaining 16 μl were diluted to

300 μ l with TE and the DNA extracted as described above for DNA extraction from serum.

Resuspended pelleted material was layered onto copper grids, air dried, stained with 1% phosphotungstate, and then examined with a Phillips 300 electron microscope.

DNA extracted from sera and fractions of liver homogenates were subjected to polymerase chain reaction (PCR) using a pair of primers selected from a highly conserved domain overlapping the core gene and recently used to amplify a portion of a hepadnavirus genome from a woolly monkey (Lanford et al., 1998). The forward primer 5'-CCTTGGGTGGCTTTGGGCA spanned nucleotides 1884–1904 of the HBV genome and the reverse primer 5'-GGGCATTTGGTGGTCTATA spanned nucleotides 2295–2274. DNA from the equivalent of 40 μ l of serum and from 20% of the total DNA from each gradient fraction were individually subjected to PCR in a 25 μ l volume containing 1.5 mM MgCl₂, 200 nM deoxynucleotide phosphates, 400nM of each primer, and 2.5 units of Ampli-Taq Gold (PE Biosystems, Foster City, California) at 94 C for 10 min for an initial denaturation step; followed by 35 cycles of 1 min at 94 C, 2 min at 42 C, and 3 min at 72 C; and a final step of 10 min at 72 C. Reaction products were separated on a 2% agarose gel containing ethidium bromide and DNA bands were photographed on an Alpha Imager 220 (Alpha Innotech Corporation, San Leandro, California).

RESULTS

Case reports

Lemur No. 1 (N17835), a female approximately 12.5 mo old, was found comatose on the floor of the exhibit bedroom. Physical examination revealed labored breathing, cold mucous membranes, and icterus. The lemur was given oxygen via a mask, placed on a heating pad, and given 100 ml of a balanced electrolyte solution (Normosol-R, Abbott Laboratories, North Chicago, Illinois) and 50 mg of prednisolone sodium succinate (Solu-Delta Cortef, Upjohn, Peapack, New Jersey, USA) intravenously. Blood was collected for a complete blood count and determination of blood urea nitrogen (BUN) and glucose levels. An intravenous catheter was installed and a slow drip of electrolytes was started. The packed cell volume was 1, and glucose and BUN values were

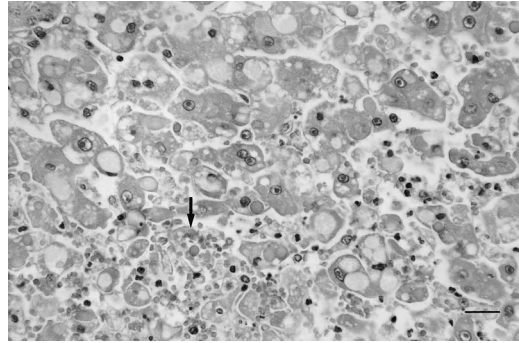


FIGURE 1. Photomicrograph of liver from black and white ruffed lemur No. 1. Hepatic cords are disorganized and there is regional loss of hepatocytes (lower left corner, area indicated by arrow). Variably-sized cytoplasmic vacuoles are present within hepatocytes. There is variation in nuclear size and a binucleate hepatocyte is present at the center of the photomicrograph. HE. Bar = 25 μ m.

85 and 44 mg/dl., respectively. Because of severe anemia, a CBC was not done. The patient continued labored breathing and was intubated and maintained on oxygen until death, less than 2 hr after admission.

At necropsy, the liver was large and faintly mottled. Microscopic changes (Fig. 1) were characterized by disruption of hepatic cords, with randomly multifocal to coalescing expansion of sinusoids containing small numbers of neutrophils in addition to erythrocytes. Most remaining hepatocytes were enlarged and the cytoplasm contained variably sized vacuoles. Some vacuoles were clear; others contained wispy eosinophilic material, and some contained homogeneous pink to green-tinged material. Many hepatocytes contained a single large vacuole filled with wispy eosinophilic material. Occasional hepatocytes had pyknotic nuclei. Most bile ducts contained a small amount of bile, and scattered canalicular bile stasis was also found. A few small aggregates of mononuclear cells, mostly lymphocytes, were found predominantly in portal areas.

Lemur No. 2 (N19515), also a female approximately 12.5 mo old, was found to be lethargic and extremely weak, and was presented with icterus, poor appetite, and a history of slow gastrointestinal transit

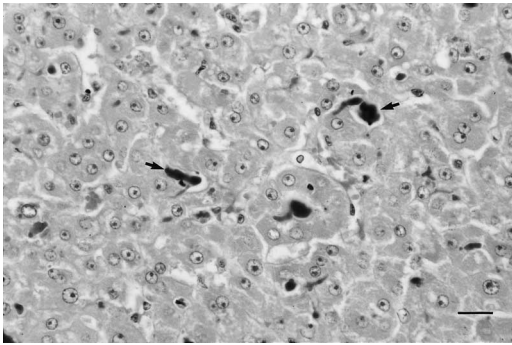


FIGURE 2. Photomicrograph of liver from black and white ruffed lemur No. 2. Hepatocellular cords are disorganized and there is extensive canalicular bile stasis (arrows). Hepatocyte nuclei are of variable size. HE. Bar = 25 μm.

time. Although the abdomen was distended, no distinct masses were detected by palpation. Two radiologic examinations, one 15 hr and the second 30 hr after a forced barium swallow did not reveal any gastrointestinal obstruction or other abnormality. The patient was given 20 mg of trimethoprim sulfa (Tribrissen, Schering, Kenilworth, New Jersey) subcutaneously once daily. Although the patient became more alert after initial admission to the hospital, she remained lethargic and only occasionally ate some oranges. The patient was found dead in the early morning 10 days after presentation. Blood analysis conducted 3 days prior to death revealed a total white blood cell count of 10,900/μl, consisting of 26% segmented neutrophils, 1% bands, 1% basophils, and 72% lymphocytes. The packed cell volume was 47% and hemoglobin was 16 g/dl. Abnormal serum chemistry values included: total protein, 2.9 g/dl; calcium, 6.3 mg/dl; cholesterol, 11 mg/dl; total bilirubin, 2.6 mg/dl; and BUN, 42 mg/dl.

At necropsy, the liver was mottled tan-brown and was moderately soft. Microscopic changes in different areas of the liver were of varying severity (Fig. 2). Lesions were characterized by extensive canalicular bile stasis. There was variation in hepatocyte nuclear size, with the largest nuclei twice the size of the smallest. Sev-

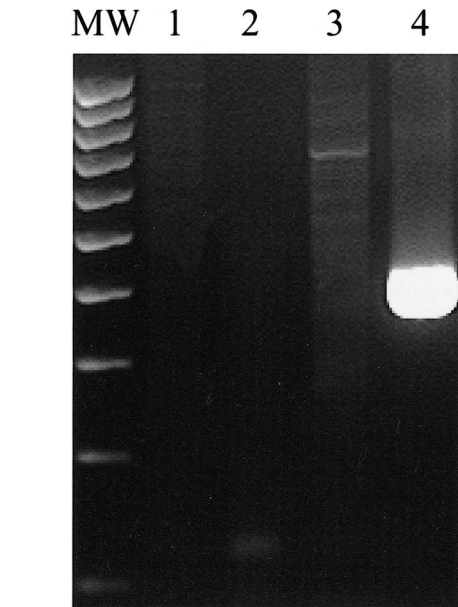


FIGURE 3. Gel analysis of PCR products from serum DNA using HBV-specific primers. Results from the negative control, lemurs No. 1 and No. 2, and the gorilla positive control are seen in lanes 1 through 4, respectively. The band visualized in lane 4 is approximately 411 bp in size, as determined by the outer coordinates of the primer sequences. The far left lane contains molecular weight markers at 100 bp intervals.

eral hepatocyte syncytia were seen. There was a moderate degree of hepatocellular cytoplasmic vacuolar change and many hepatocytes contained an intracytoplasmic, homogeneous, eosinophilic globule. Occasional small foci of hepatocellular hyperplasia were also present. There were a few scattered foci of acute necrosis.

Serology

Serum from the gorilla was positive for HbsAg, HBeAg, and IgG anti-HAV (Linemann et al., 1984). Serum from both clinical cases and the negative control lemur were negative for all viral markers with the exception that Lemur No. 1 had a low titer (1:4) to HbsAg.

Polymerase chain reaction

Results of gel analysis of PCR products are shown in Figure 3. A band of approximately 400 bp represented amplification

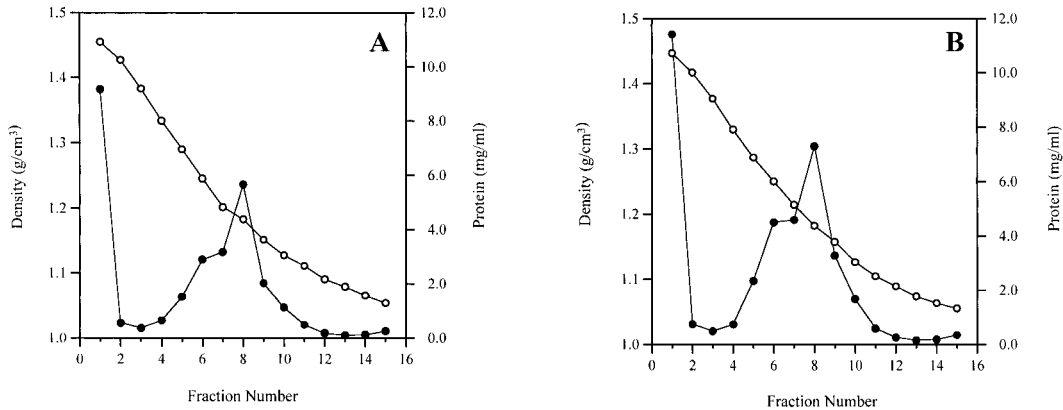


FIGURE 4. Profiles of gradient fraction of liver homogenates. The gradient profile in panel A represents the positive control HBV-positive gorilla. Panel B represents gradient fractions from lemur No. 2. Open circles represent values for density; solid circles represent values for protein concentration.

of part of the HBV core gene from virus particles in serum of the gorilla. No amplified product was observed by PCR of serum from the negative control or either clinical case. Genomic DNA from livers of the three lemurs and gorilla were also subjected to PCR using the core region primers. Gel analysis of PCR products from all four animals revealed numerous weakly-stained bands of varying sizes, several of which were in the size range of the expected product of 400 bp (not shown). Modification of PCR parameters (e.g., varying the annealing temperature, decreasing the length of the denaturing, annealing, or extension components of each cycle) did not affect this result. Because alteration of PCR parameters did not change the staining pattern observed on various gels (e.g., disappearance of bands in negative control lanes or increased intensity of bands in lanes of the positive control and clinical cases), we consider these results to be non-specific and not diagnostic for presence of hepadnavirus in these samples.

Analysis of gradient fractions of liver homogenates

Profiles of gradient fractions for the positive control and Lemur No. 2 are shown in Figure 4. The gradient profile for Lemur No. 1 was similar in general pattern

to that of Lemur No. 2. Varying levels of protein were present throughout the gradients seen in Figure 4 with a peak seen in fraction 8. The density of this fraction was 1.18 g/cm^3 . This value is compatible with the density, in cesium chloride, of surface antigen particles of HBV, the woodchuck hepatitis virus (WHV), and the ground squirrel hepatitis virus (GSHV) (Summers, 1981). The high level of protein in fraction 1 of both gradients is pelleted cellular material.

Electron microscopy

Pelleted material from fractions 7, 8, and 9 from the gradients of all four animals were examined by negative stain electron microscopy. A cluster of pleomorphic, roughly spherical particles varying in size from approximately 16–25 nm (Fig. 5A) is representative of the size and morphology of particles seen in fraction 8 of the gradient from the positive control. A slightly lower power view of fraction 8 from Lemur No. 2 (Fig. 5B) revealed numerous particles, similar in size and morphology to those seen in the positive control. A larger particle, approximately 47–50 nm in diameter and double-shelled in appearance, is compatible in size and morphology with the hepatitis B virus (Zuckermann and Howard, 1979). Stained material from fraction 7 revealed fewer particles than

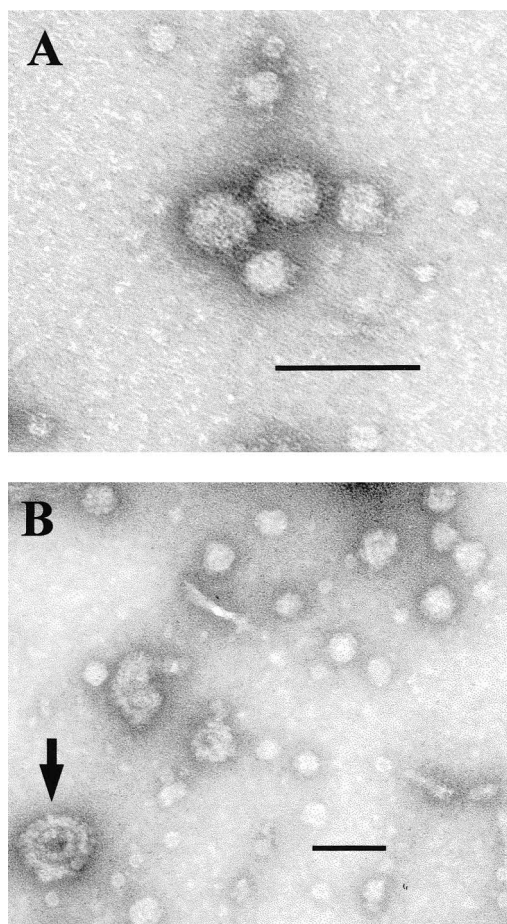


FIGURE 5. Negative stain electron micrograph of peak protein-containing fraction contents. A. (positive control) shows a cluster of pleomorphic, spherical particles ranging in diameter from 16–25 nm. B. (lemur No. 2) shows numerous spherical particles similar in size and morphology to those seen in panel A. A larger double-shelled 47–50 nm particle is also seen (arrow). Bar = 50 nm.

seen in fraction 8, while few, if any, particles were observed in fraction 9. Analysis of gradient fractions from lemur No. 1 revealed the smaller spherical particles seen in lemur No. 2 and the positive control (Fig. 5a, b). Compared to those of the positive control and the clinical cases, the gradient fractions of the negative control animal contained protein at a much lower level and without a peak in fraction 8. Electron microscopic analysis of pelleted material from fractions 7 through 9 re-

vealed scattered cellular debris but a lack of particles as seen in the other animals.

DISCUSSION

Although not pathognomonic, changes described in these two cases are compatible with acute viral hepatitis (Scheuer, 1994). Application of immunoassays for serum viral markers and utilization of HBV-specific primers in an attempt to PCR amplify viral sequences of DNA from serum and gradient-fractionated liver homogenates failed to detect a hepadnavirus. However, electron microscopic examination of concentrated material from peak protein-containing gradient fractions from livers of a positive control and the two clinical cases revealed two types of particles, compatible in size and morphology with HBV and the sub-viral spherical surface antigen (Zuckerman and Howard, 1979). These particles possessed a density of 1.18 g/cm^3 , which is compatible with the density, in cesium chloride, of spherical surface antigen particles of several hepadnaviruses.

Presence of particles resembling HBV and HBV surface antigen in lemur livers in the absence of serologic markers or a positive PCR product is reasonable based on phylogenetic analysis of hepadnavirus genome sequences results (Lanford et al., 1998; Grethe et al., 2000; MacDonald et al., 2000). Although the phylogenetic tree of the various primate HBV variants described in chimpanzees, gibbons, orangutans, and the woolly monkey does not reflect the phylogeny of the host species, the sequence of the woolly monkey virus is quite distinct from HBV found in humans and apes (Lanford et al., 1998). Therefore it is possible to speculate that a prosimian hepadnavirus, although similar in morphology to HBV of humans and apes, might possess a genomic sequence divergent enough to evade detection by human HBV-specific immunological reagents and PCR primers.

Techniques other than PCR are available for detecting lemur hepadnavirus.

Hepatitis B virus was originally cloned by digesting the virus with the restriction enzyme, *EcoRI*, and ligating the digested virus into an *EcoRI*-digested plasmid cloning vector. Virus particles observed in liver gradient fractions could be concentrated and used as a source of viral DNA for such an approach. Cloning products could be screened by DNA hybridization techniques or shotgun sequencing and, while laborious compared to direct PCR followed by sequencing, a portion or all of the genome could be obtained. Representational difference analysis (RDA) is a type of subtractive hybridization capable of isolating rare genomic fragments from an exogenous infectious agent found in an infected specimen but not in an otherwise matched uninfected specimen (Lisitsyn et al., 1993). This technique was used to detect herpesvirus sequences in Kaposi's sarcomas, leading to characterization of human herpesvirus 8 (Chang et al., 1994). Identification of flavivirus-like genomes in the GB hepatitis agent from tamarin sera used this methodology (Simons et al., 1995).

Detection of a putative hepadnavirus in serum of lemurs is problematic. Until viral sequence is obtained from which viral species-specific primers can be constructed, detection of virus will only be performed for research purposes and will not be practical for broad screening of either captive or free-ranging animals. Considering the spectrum of liver lesions observed in one collection, many of which may not be solely the result of hemosiderosis, definitive identification of these virus-like particles and establishment of a specific assay to detect their presence in living animals is paramount.

ACKNOWLEDGEMENTS

This work was supported by the Zoological Society of San Diego. The authors thank M. Anderson and P. Harper for the original pathology case work.

LITERATURE CITED

- BENIRSCHKE, K., C. MILLER, R. IPPEN, AND A. HELD-STAB. 1985. The pathology of prosimians, especially lemurs. *In* *Advances in Veterinary Medicine and Comparative Medicine* 30: 167–208.
- CHANG, Y., E. CESARMAN, M. S. PESSIN, F. LEE, J. CULPEPPER, D. M. KNOWLES, AND P. S. MOORE. 1994. Identification of herpesvirus-like DNA sequences in AIDS-associated Kaposi's sarcoma. *Science* 266: 1865–1869.
- GRETHE, S., J.-O. HECKEL, W. RIETSCHEL, AND F. T. HUFERT. 2000. Molecular epidemiology of hepatitis B virus variants in nonhuman primates. *Journal of Virology* 74: 5377–5381.
- HU, X., H. S. MARGOLIS, R. H. PURCELL, J. EBERT, AND B. H. ROBERTSON. 2000. Identification of hepatitis B virus indigenous to chimpanzees. *Proceedings of the National Academy of Sciences USA* 97: 1661–1664.
- KANEKO, S., R. H. MILLER, S. M. FEINSTONE, M. UNOURA, K. KOBAYASHI, N. HATTORI, AND R. H. PURCELL. 1989. Detection of serum hepatitis B virus DNA in patients with chronic hepatitis using the polymerase chain reaction assay. *Proceedings of the National Academy of Sciences USA* 86: 312–316.
- LANFORD, R. E., D. CHAVEZ, K. M. BRASKY, R. B. BURNS III, AND R. RICO-HESE. Isolation of a hepadnavirus from the woolly monkey, a new world primate. *Proceedings of the National Academy of Sciences USA* 95: 5757–5761.
- LINNEMANN JR., C. C., L. W. KRAMER, AND P. A. ASKEY. 1984. Familial clustering of hepatitis B infection in gorillas. *American Journal of Epidemiology* 119: 424–430.
- LISITSYN, N., N. LISITSYN, AND M. WIGLER. 1993. Cloning the differences between two complex genomes. *Science* 259: 946–951.
- MACDONALD, D. M., E. C. HOLMES, J. C. M. LEWIS, AND P. SIMMONDS. 2000. Detection of hepatitis B virus infection in wild-born chimpanzees (*Pan troglodytes verus*): Phylogenetic relationships with human and other primate genotypes. *Journal of Virology* 74: 4253–4257.
- NORDER, H., J. W. EBERT, H. A. FIELDS, I. K. MUSHAWAR, AND L. O. MAGNIUS. 1996. Complete sequencing of a gibbon hepatitis B virus genome reveals a unique genotype distantly related to the chimpanzee hepatitis B virus. *Virology* 218: 214–223.
- SCHEUER, P. J. 1994. Viral hepatitis. *In* *Pathology of the liver*, 3rd Edition. Churchill Livingstone, New York, New York, pp. 243–267.
- SIMONS, J. N., T. J. PILOT-MATIAS, T. P. LEARY, G. J. DAWSON, S. M. DESAL, G. G. SCHLAUDER, A. S. MUEHROFF, J. C. ERKER, S. L. BUIJK, M. L. CHALMERS, C. L. VAN SANT, AND I. K. MUSHAWAR. 1995. Identification of two flavivirus-like ge-

- nomes in the GB hepatitis agent. Proceedings of the National Academy of Sciences USA 92: 3401–3405.
- SPELMAN, L. H., K. G. OSBORN, AND M. P. ANDERSON. 1989. Pathogenesis of hemosiderosis in lemurs: Role of dietary iron, tannin, and ascorbic acid. *Zoo Biology* 8: 239–251.
- SUMMERS, J. 1981. Three recently described animal models for human hepatitis B virus. *Hepatology* 1: 179–183.
- VAUDIN, M., A. J. WOLSTENHOLME, K. N. TSIQUAYE, A. J. ZUCKERMAN, AND T. J. HARRISON. 1988. The complete nucleotide sequence of the genome of a hepatitis B virus isolated from a naturally infected chimpanzee. *Journal of General Virology* 69:1383–1389.
- WARREN, K. S., J. L. HEENEY, R. A. SWAN, HERIYANTO, AND E. J. VERSCHOOR. 1999. A new group of hepadnaviruses naturally infecting orangutans (*Pongo pygmaeus*). *Journal of Virology* 73: 7860–7865.
- ZUCKERMAN, A. J., AND C. R. HOWARD. 1979. *Hepatitis viruses of man*. Academic Press. London.

Received for publication 7 August 2000.