

EXPERIMENTAL INOCULATION OF NORTH AMERICAN OPOSSUMS (*DIDELPHIS VIRGINIANA*) WITH *MYCOBACTERIUM BOVIS*

Kelly L. Diegel,^{1,5} Scott D. Fitzgerald,¹ Dale E. Berry,² Steven V. Church,² Willie M. Reed,¹ James G. Sikarskie,³ and John B. Kaneene⁴

¹ Department of Pathobiology and Diagnostic Investigation, College of Veterinary Medicine, Michigan State University, P.O. Box 30076, Lansing, Michigan 48909, USA

² Michigan Department of Community Health Tuberculosis Laboratory, Lansing, Michigan 48909, USA

³ Department of Small Animal Clinical Sciences, Michigan State University, East Lansing, Michigan 48824, USA

⁴ Population Medicine Center, College of Veterinary Medicine, Michigan State University, East Lansing, Michigan 48824, USA

⁵ Corresponding author (e-mail: butlerk@ahdl.msu.edu)

ABSTRACT: Eight North American opossums (*Didelphis virginiana*) were inoculated with 1×10^5 colony forming units of *Mycobacterium bovis* to investigate their potential as reservoir hosts for bovine tuberculosis in Michigan. Four animals received this dose orally and four were inoculated intramuscularly (IM). In each group, two animals were euthanized 1 mo postinoculation (PI) and two at 2 mo PI. Four control animals were housed separately and sacrificed in the same manner as those inoculated. One of four orally inoculated opossums and three of four IM-inoculated opossums were positive for *M. bovis* by culture of tissues obtained at necropsy. The oral recipient had positive cultures from intestine and pooled lymphoid samples. Pooled lymphoid samples were positive in three IM-inoculated animals and two of these also had positive liver and lung cultures. One animal with gross and histologic lesions compatible with tuberculosis had negative tissue cultures. The findings suggest that opossums are susceptible to *M. bovis* infection by multiple routes, although their relative susceptibility compared to true reservoir hosts appears to be low.

Key words: *Didelphis virginiana*, opossum, *Mycobacterium bovis*, tuberculosis.

INTRODUCTION

Surveillance for *Mycobacterium bovis* in wild and captive cervids in Michigan (USA) has been ongoing since 1995 in order to estimate the prevalence of tuberculosis in free-ranging white-tailed deer (*Odocoileus virginianus*) (Schmitt et al., 1997). Over the past 6 yr, carnivores and omnivores have been included in the surveillance program to identify reservoir hosts other than white-tailed deer. No additional reservoir host has been identified yet spillover infections have been identified in black bears (*Ursus americanus*), bobcats (*Felis rufus*), coyotes (*Canis latrans*), raccoons (*Procyon lotor*), red foxes (*Vulpes vulpes*), and North American opossums (*Didelphis virginiana*).

This study was originally designed to compare the susceptibility to *M. bovis* of opossums to another marsupial, the brush-tailed possum (*Trichosurus vulpecula*). The brush-tailed possum is an important wildlife reservoir for *M. bovis* in New Zealand (O'Reilly and Daborn, 1995; Buddle

et al., 2000). They often become severely debilitated from infection with *M. bovis* and may develop fistulous tracts that drain externally from affected lymph nodes, resulting in shedding of large numbers of organisms. A second aim of this study was to compare infection of opossums with *M. bovis* to that of the European badger (*Meles meles*). The badger is an efficient reservoir for bovine tuberculosis and is responsible for maintaining *M. bovis* in parts of Ireland and the United Kingdom. However, unlike the brush-tailed possum, badgers may shed organisms for long periods through urine, feces, and respiratory secretions while showing neither internal lesions nor outward signs of debilitation (Little et al., 1982; Mahmood et al., 1987).

This pilot study was designed to challenge opossums with *M. bovis* using two routes of inoculation. The intramuscular (IM) route was selected because this route of inoculation results in rapid dissemination of infection with abscess formation in multiple organ systems in the brush-tailed

possum (Corner and Presidente, 1980). Oral inoculation was selected because it is the most likely source of natural exposure in Michigan (Bruning-Fann et al., 2001).

MATERIALS AND METHODS

Opossums

Our study was limited to 12 opossums (seven females and five males) due to funding and biolevel-3 laboratory space restrictions. Initially, five adult opossums were live-trapped in Ingham County, Michigan (State Scientific Collector's Permit number SC1057). One of these adults was a late-term pregnant female. This female was observed for several days when she gave birth to seven offspring. These young were captive-raised, weaned as juveniles, and included as subjects in this study. Animals received a diet of approximately 120 ml dry dog food (Hill's Science Diet Canine Maintenance Dry, Hill's Pet Nutrition, Inc., Topeka, Kansas, USA) daily and approximately 60 ml canned dog food (Hill's Canine p/d Canned) every other day. This diet was supplemented with fresh fruit and strawberry preserves weekly prior to inoculation and only with fruit weekly post-inoculation. During the diet acclimation period, each animal received 100 mg/kg fenbendazole (Panacur®, Hoechst-Roussel Agri-Vet Co., Somerville, New Jersey, USA) orally, once daily, for three consecutive days. Control and inoculated opossums were moved to separate wards 1 wk prior to inoculation to allow acclimation to the new laboratory.

Inocula

Mycobacterium bovis isolates from white-tailed deer in Michigan are maintained by the Tuberculosis Laboratory, Michigan Department of Community Health (MDCH, Lansing, Michigan, USA). Inocula were prepared using a typical strain (evaluated by the restriction fragment length polymorphism analyses [RFLP]) common to all cases. Seven-day growth in Middlebrook 7H9 broth was adjusted to a 0.5 McFarland turbidity standard, diluted 1:100 with sterile water, and tested by plate counts to determine the colony forming units (CFUs) per unit of volume. One milliliter containing approximately 1×10^5 CFU/ml was used for intramuscular (IM) inoculation into the left hind limb. The oral inoculum was 0.2 ml containing the same CFU. A more concentrated solution was used for oral inoculation to assure complete delivery. Opossums received the oral inocula mixed in strawberry preserves spread onto a 6.5 cm² piece of bread. Animals were

monitored to assure the complete dose was consumed.

Experimental design

Twelve opossums were randomly divided into three groups: four received oral inoculation, four received IM inoculation, and four were non-inoculated controls. All inoculated opossums were housed in separate Horsfall units in HEPA-filtered rooms (biolevel-3 conditions) at the Michigan State University Containment Facility. Control opossums were housed in standard rabbit cages in a separate ward in the facility. The clinical condition, food consumption, and water consumption of each opossum were recorded daily.

Animals were weighed on the day prior to inoculation and every 2 wk throughout the experiment. In order to assess shedding, fecal samples for mycobacterial culture were collected from all animals on the day prior to inoculation, 24 hr post-inoculation (PI), and 31 days PI. Half of the animals in each group were euthanized 31 days PI and the remaining animals were euthanized 61 days PI. Euthanasia was performed via intracardiac injection of sodium pentobarbital solution (Fatal Plus®, Vortech Pharmaceuticals, Dearborn, Michigan) after initial sedation using 5 mg/kg xylazine (Rompun®, Miles, Inc., Shawnee, Kansas, USA) injected IM. Fecal samples and tissue samples were collected for mycobacterial culture at necropsy.

Total body weight, organ weights (spleen, liver, kidneys, and lung), and gross lesions were recorded at necropsy. Tissues submitted for mycobacterial isolation and identification included pooled sections of liver and kidney, pooled sections of small and large intestine, pooled sections of spleen and lymph nodes (cranial, thoracic, and mesenteric), and sections of lung. Sections of brain, heart, lung, tracheo-bronchial lymph node, stomach, small intestine, pancreas, large intestine, mesenteric lymph node, liver, kidney, adrenal gland, spleen, urinary bladder, testis or ovary, skin, hindlimb musculature, and an entire eye were collected from each animal at necropsy and fixed in 10% neutral buffered formalin solution for histologic processing and examination. Tissues were stained with hematoxylin and eosin (HE) and Ziehl-Neelsen acid fast stains (Prophet et al., 1992).

Mycobacterial isolation and identification

Mycobacterial cultures were performed at the MDCH, Tuberculosis Laboratory. Tissue specimens were ground, digested, and concentrated as previously described (Kent and Ku-

TABLE 1. Histologic and mycobacterial culture results of North American opossums inoculated with *Mycobacterium bovis*.

Inoculation group	Number in group	Acid-fast organisms observed histologically	Mycobacterial tissue culture positives
Control	4	0	0
Oral	4	0	1
Intramuscular	4	3	3

bica, 1985). A Lowenstein-Jensen medium slant (Becton-Dickinson, Cockeysville, Maryland, USA), a Middlebrook 7H11S medium slant (Becton-Dickinson), and a Bactec12B broth vial (Becton-Dickinson, Sparks, Maryland) were inoculated with the material. Media were examined for growth on a weekly basis for 8 wk. Bacterial growth, determined to be acid-fast by slide examination (Kent and Kubica, 1985), was tested by genetic probe (Accuprobes, Gen-Probe, San Diego, California, USA) to determine whether the bacteria were members of the *M. tuberculosis* complex as described (Reisner et al., 1994). Species identification was performed using biochemical testing and high performance liquid chromatography to differentiate *M. bovis* from the other members of the *M. tuberculosis* complex (*M. bovis*, *M. tuberculosis*, *M. microti*, and *M. africanum*), and from other mycobacteria (Kent and Kubica, 1985; Butler et al., 1991; Nolte and Mettcock, 1995).

RESULTS

All animals gained weight during the experiment. The amount gained by controls was similar to that gained by inoculated groups. No significant differences in organ weights were noted. Gross lesions included hepatomegaly in one oral and one IM-inoculated animal, splenomegaly in two animals in each inoculation group, and gastrointestinal parasitism in animals in all groups. Two IM-inoculated animals had lesions in the lungs and at the injection site. The lesion in the first of these animals was a 4.0 mm diameter, irregular, yellow to tan, firm granuloma within the parenchyma of the caudal-dorsal right lung lobe. The lung lesion in the second animal was a 0.5 mm diameter, irregular, gray to tan, firm plaque, also within the caudal right lung

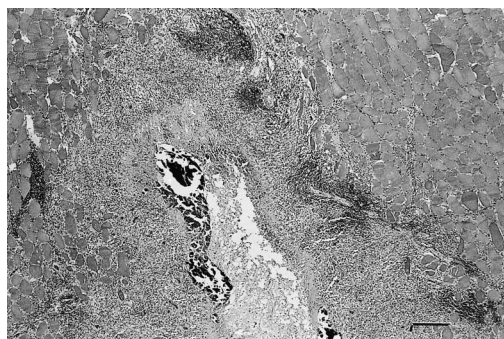


FIGURE 1. Section of skeletal muscle from a North American opossum inoculated intramuscularly with *M. bovis*. Severe caseogranulomatous myositis with central mineralization is featured. HE. Bar = 1 mm.

lobe. Both of these animals had large (3 cm × 2 cm and 3 cm × 3 cm, respectively) abscesses within the musculature of the left hind limb. The abscesses contained approximately 3 to 5 ml of exudate which ranged from thick and yellow-green to watery and straw-colored. The abscesses extended into a deep cellulitis and fasciitis in one animal.

Histologic lesions attributable to *M. bovis* were not present in any of the HE or acid-fast stained tissue sections examined from control or oral inoculation groups (Table 1). In the IM-inoculated group, two animals had numerous acid-fast bacilli in skeletal muscle sections. Each case featured severe, multifocal and coalescing to dissecting, chronic-active, pyogranulomatous to caseogranulomatous myositis, cellulitis, and fasciitis, with foci of mineralization and multinucleate giant cells (Fig. 1). Acid-fast bacilli were present within the cytoplasm of inflammatory cells in these lesions and free within centers of caseous exudate. An additional IM-inoculated animal had similar skeletal muscle lesions but bacilli were not seen histologically. This animal, however, had low numbers of acid-fast organisms within the cytoplasm of macrophages in sections of lung. Lesions in the lung of this animal were characterized as moderate to severe, multifocal, chronic, granulomatous inter-

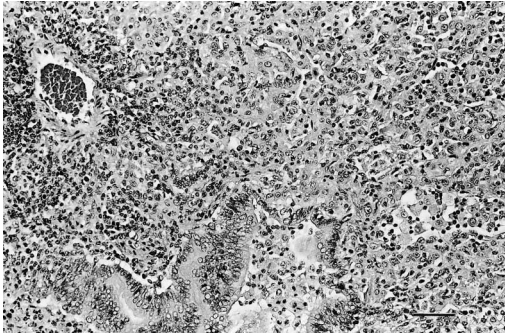


FIGURE 2. Section of lung from a North American opossum inoculated intramuscularly with *M. bovis*. Note large numbers of macrophages filling alveoli. HE. Bar = 100 μ m.

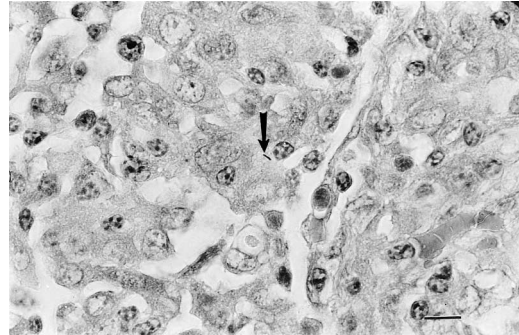


FIGURE 3. Section of lung from same opossum as Figure 2. Acid-fast bacillus within the cytoplasm of one of several large macrophages in an alveolus (arrow). Ziehl-Neelsen acid-fast stain. Bar = 40 μ m.

stitial pneumonia with foci of caseation and multinucleate giant cells. Low numbers of acid-fast bacilli within inflammatory cells in the lung associated with a similar caseogranulomatous pneumonia were present in another IM-inoculated opossum (Figs. 2, 3). This animal was one of the two inoculated animals with granulomatous myositis with acid-fast organisms. No other significant histologic lesions were noted in any animal.

Several incidental histologic lesions not related to tuberculosis were noted in all groups. These lesions included: diffuse microvacuolar to granular hepatopathy; diffuse, eosinophilic to nonsuppurative enterocolitis; endogenous lipid pneumonia; splenic, pulmonary, and hepatic congestion; nonspecific lymphoid reactivity in multiple organs; and protozoal cysts consistent with either *Besnoitia darlingi* or *Sarcocystis* sp. in various tissues.

Fecal cultures were negative for mycobacteria in all animals prior to inoculation. *Mycobacterium bovis* was cultured from feces of one orally inoculated opossum 24 hr after inoculation and from another orally inoculated opossum 31 days PI. No additional positive fecal cultures were obtained from any animal (Table 2).

Tissue cultures were positive in one oral and three IM-inoculated opossums (Table 2). Mycobacteria were not isolated from the only animal with a combination of

gross and histologic lesions compatible with tuberculosis.

DISCUSSION

Opossums that were IM-inoculated had more histologic lesions consistent with tuberculosis and had larger numbers of positive tissue cultures as a group than did those receiving oral inoculation. Only those inoculated orally had positive fecal cultures at any time during the experiment, suggesting fecal shedding may occur in naturally infected animals. One animal had a positive fecal culture 1 day PI only, suggesting that shedding was directly related to the inoculum. No gross or histologic evidence of disease was present in one orally-inoculated animal, even though this animal had positive fecal and intestinal cultures. Culture is probably more sensitive than histopathology; organisms are more likely to be identified when present in conjunction with an identifiable lesion.

Two IM-inoculated opossums developed pulmonary lesions consistent with tuberculosis. At least a partial affinity of the organism for the lung in this species is suggested by this finding.

Many of the gross lesions, such as gastrointestinal parasitism, hepatomegaly, and splenomegaly, were present in all groups and therefore did not seem to be related to mycobacterial disease. Only one of three animals with gross lung lesions had

TABLE 2. Gross and microscopic lesions, fecal culture, and tissue culture findings in North American opossums inoculated with *Mycobacterium bovis*.

Age ^a	Sex ^b	Inoculation route/ days PI ^c euthanized	Gross lesions/organs affected ^d	Microscopic lesions/organ affected ^d	Positive fecal culture/days PI	Positive tissue culture/ organ affected ^d
J	M	Oral/31	No	No	Yes/31	Yes/I, Ln
J	M	Oral/61	No	No	Yes/1	No
J	M	IM ^e /31	No	Yes/Mu, Lu	No	Yes/Lu, Liv, Ln
J	F	IM/61	Yes/Mu, Lu	Yes/Mu, Lu	No	No
A	F	IM/61	No	No	No	Yes/Ln

^a J = juvenile; A = adult.

^b F = female; M = male.

^c PI = post-inoculation.

^d Mu = muscle; Lu = lung; I = pooled small and large intestine; Ln = pooled spleen and lymph nodes; Liv = pooled liver and kidney.

^e IM = intramuscular.

histologically confirmed evidence of tuberculosis. One opossum with lung lesions suggestive of granulomas grossly had pulmonary besnoitiosis based on histologic examination of the tissue. *Besnoitia darlingi* or *Sarcocystis* sp. were noted histologically in various tissues in all groups. *Besnoitia darlingi* is not implicated as causing disease in opossums (Davidson and Nettles, 1997). Some animals had endogenous lipid pneumonia, which is a rather common finding in wild opossums (Brown, 1988). In both opossums with myositis near injection sites, infection was caused by the inoculum based on histologic examination rather than by a foreign body injection reaction.

Only one animal met the three criteria (gross lesions, histologic lesions, and positive mycobacterial isolation/identification) considered diagnostic for *M. bovis* tuberculosis (Dungworth, 1993). Histologic evidence of disease could be missed when only small sections of tissue are examined. There is also potential for false negative culture results, particularly when stringent tissue preparations/digestions are necessary as is the case with some mycobacterial culture techniques.

While the opossum is susceptible to *M. bovis*, the likelihood of it serving as a reservoir host under natural conditions appears less than that of the brush-tailed possum. The dose of microorganisms used in this pilot study was much higher than that used in studies with brush-tailed possums; at similar times PI necropsy of opossums revealed fewer lesions than those reported in brush-tailed possum (Corner and Presidente, 1980). Experimentally and naturally infected brush-tailed possums may develop severe, generalized lesions, including fistulous tracts that drain externally from infected lymph nodes (Corner and Presidente, 1980; Buddle et al., 1994; Cooke et al., 1995). When lesions in our experimentally-inoculated animals or in wild opossums with tuberculosis are compared to those found naturally in brush-tailed possums (Cooke et al., 1995) differ-

ences in gross and histologic lesions are striking.

European badgers may shed *M. bovis* without clinical disease (Little et al., 1982; Gallagher et al., 1998). Even in laboratory studies, badgers may live several years without evidence of clinical disease (Corner and Presidente, 1980; Pritchard et al., 1987; Buddle et al., 1994). The opossum may be similarly affected when exposed to *M. bovis*, although its role as a reservoir host remains to be seen and our study was too short to assess long-term infection. This species probably represents a "spill-over host" with relatively high resistance to infection.

Studies of transmission and excretion routes of *M. bovis* in opossums are warranted. Based on lesion distribution, opossums seem more likely to spread tuberculosis by the respiratory route when compared to other wild carnivore and omnivore species in Michigan. Intratracheal or aerosol nebulization inoculation studies may provide a better understanding of the disease process in this species.

ACKNOWLEDGMENTS

The authors thank S. Arduin of the Michigan Department of Community Health, Tuberculosis Laboratory for her assistance in culture procedures. We also wish to thank R. Common, Department of Veterinary Pathology, Michigan State University for his assistance in the preparation of photomicrographs. This study was partially funded by a United States Department of Agriculture, Animal and Plant Health Inspection Service Grant.

LITERATURE CITED

- BROWN, C. C. 1988. Endogenous lipid pneumonia in opossums from Louisiana. *Journal of Wildlife Diseases* 24: 214–219.
- BRUNING-FANN, C. S., S. M. SCHMITT, S. D. FITZGERALD, J. S. FIERKE, P. D. FRIEDRICH, J. B. KANEENE, K. A. CLARKE, K. L. BUTLER, J. B. PAYEUR, D. L. WHIPPLE, T. M. COOLEY, J. M. MILLER, AND D. P. MUZZO. 2001. Bovine tuberculosis in free-ranging carnivores from Michigan. *Journal of Wildlife Diseases* 37: 58–64.
- BUDDLE, B. M., F. E. ALDWELL, A. PFEFFER, AND G. W. DE LISLE. 1994. Experimental *Mycobacterium bovis* infection in the brushtail possum (*Trichosurus vulpecula*): I. Pathology, haematology and lymphocyte stimulation responses. *Veterinary Microbiology* 38: 241–254.
- , M. A. SKINNER, AND M. A. CHAMBERS. 2000. Immunological approaches to the control of tuberculosis in wildlife reservoirs. *Veterinary Immunology and Immunopathology* 74: 1–16.
- BUTLER, W. R., K. C. JOST, JR., AND J. O. KILBURN. 1991. Identification of mycobacteria by high performance liquid chromatography. *Journal of Clinical Microbiology* 29: 2468–2472.
- COOKE, M. M., R. JACKSON, J. D. COLEMAN, AND M. R. ALLEY. 1995. Naturally occurring tuberculosis caused by *Mycobacterium bovis* in brushtail possums (*Trichosurus vulpecula*): II. Pathology. *New Zealand Veterinary Journal* 43: 315–321.
- CORNER, L. A., AND P. J. A. PRESIDENTE. 1980. *Mycobacterium bovis* infection in the brush-tailed possum (*Trichosurus vulpecula*): I. Preliminary observations on experimental infection. *Veterinary Microbiology* 5: 309–321.
- DAVIDSON, W. R., AND V. F. NETTLES. 1997. Opossums. In *Field manual of wildlife diseases in the southeastern United States*, 2nd Edition. Southeastern Cooperative Wildlife Disease Study, The University of Georgia, Athens, Georgia, pp. 211–219.
- DUNGWORTH, D. L., K. F. V. JUBB, P. C. KENNEDY, AND N. PALMER (Editors). 1993. The respiratory system. In *Pathology of domestic animals*, 4th Edition, Vol. 2. North Academic Press, Inc., San Diego, California, pp. 610–613.
- GALLAGHER, J., R. MONIES, M. GAVIER-WIDEN, AND B. RULE. 1998. Role of infected, non-diseased badgers in the pathogenesis of tuberculosis in the badger. *The Veterinary Record* 142: 710–714.
- KENT, P. T., AND G. P. KUBICA. 1985. Public health mycobacteriology. A guide for the level III laboratory. U.S. Department of Health and Human Services. Atlanta, Georgia, 207 pp.
- LITTLE, T. W. A., P. F. NAYLOR, AND J. W. WILESMITH. 1982. Laboratory study of *Mycobacterium bovis* infection in badgers and calves. *The Veterinary Record* 111: 550–557.
- MAHMOOD, K. H., G. A. ROOK, J. L. STANFORD, F. A. STUART, AND D. G. PRITCHARD. 1987. The immunological consequences of challenge with bovine tubercle bacilli in badgers (*Meles meles*). *Epidemiology and Infection* 98: 155–163.
- NOLTE, F. S., AND B. METCHOCK. 1995. *Mycobacterium*. In *Manual of clinical microbiology*, P. R. Murray, E. J. Baron, M. A. Pfaller, F. C. Tenover, and R. H. Tenover (eds.). American Society for Microbiology Press, Washington, D.C., pp. 400–437.
- O'REILLY, L. M., AND C. J. DABORN. 1995. The epidemiology of *Mycobacterium bovis* infections in animals and man: A review. *Tubercle and Lung Disease* 76, Supplement 1: 1–46.
- PRITCHARD, D. G., F. A. STUART, J. I. BREWER, AND K. H. MAHMOOD. 1987. Experimental infection

- of badgers (*Meles meles*) with *Mycobacterium bovis*. *Epidemiology and Infection* 98: 145–154.
- PROPHET, E. B., B. MILLS, J. B. ARRINGTON, AND L. H. SOBIN (Editors). 1992. *Laboratory methods in histotechnology*. Armed Forces Institute of Pathology, American Registry of Pathology, Washington, D.C., 279 pp.
- REISNER, B. S., A. M. GATSON, AND G. L. WOODS. 1994. Use of gen-probe accuprobes to identify *Mycobacterium avium* complex, *Mycobacterium tuberculosis* complex, *Mycobacterium kansasii* and *Mycobacterium gordonae* directly from Bactec TB broth cultures. *Journal of Clinical Microbiology* 32: 2995–2998.
- SCHMITT, S. M., S. D. FITZGERALD, T. M. COOLEY, C. S. BRUNING-FANN, L. SULLIVAN, D. E. BERRY, T. CARLSON, R. B. MINNIS, J. B. PAYEUR, AND J. SIKARSKIE. 1997. Bovine tuberculosis in free-ranging white-tailed deer from Michigan. *Journal of Wildlife Diseases* 33: 749–758.

Received for publication 16 March 2001.