

## EUROPEAN BROWN HARE SYNDROME VIRUS IN FREE-RANGING EUROPEAN BROWN HARES FROM ARGENTINA

Kai Frölich,<sup>1,4</sup> Olgierd E. J. Graf Kujawski,<sup>2</sup> Michael Rudolph,<sup>1</sup> Leif Ronsholt,<sup>3</sup> and Stephanie Speck<sup>1</sup>

<sup>1</sup> Institute for Zoo and Wildlife Research Berlin, Alfred-Kowalke-Str. 17, P.O. Box 601103, 10252 Berlin, Germany

<sup>2</sup> Müllerstr. 13, 35781 Weilburg, Germany

<sup>3</sup> Danish Veterinary Institute, Lindholm, 4771 Kalvehave, Denmark

<sup>4</sup> Corresponding author (email: froelich@izw-berlin.de)

**ABSTRACT:** From 1998 to 2000, serum samples of 80 shot European brown hares (*Lepus europaeus*) from Argentina were examined for antibodies against European brown hare syndrome virus (EBHSV) and 80 spleen samples were tested for EBHSV-antigen by enzyme linked immunosorbent assay (ELISA). Nine hares were positive for EBHSV-antigen. Antibodies against EBHSV were detected in only one individual. Based on negative staining electron microscopy of spleen homogenates, we observed calicivirus in one of five EBHSV-antigen positive hares. However, EBHS has not been reported to cause abnormal mortality in these hares. This is the first report of antibodies to EBHSV, EBHSV-antigen, and electron microscopy findings in free-ranging European brown hares from South America.

**Key words:** Argentina, electron microscopy, European brown hare syndrome virus, *Lepus europaeus*, serologic survey.

### INTRODUCTION

A general decline of European brown hare (*Lepus europaeus*) populations has been observed in several European countries. Although all reasons have not yet been identified, diseases have been suggested to play a role in the decline of local hare populations (Seck-Lanzendorf, 1997). European brown hare syndrome (EBHS) is caused by caliciviral infection of free-living and farmed hares, mainly characterized by acute hepatitis and hemorrhage of the internal organs (Poli et al., 1991). In the early 1980s, EBHS was diagnosed in Sweden for the first time (Gavier-Widén and Mörner, 1989), but outbreaks with lesions consistent with EBHS have been described from England since 1976 (Duff et al., 1997) and were known by hunters in Scandinavia in the early 1970s (Lenghaus et al., 2001). In 1989, Lavazza and Vecchi (1989) found viral particles in European brown hares that had died from EBHS. The causative agent is a small icosahedral, non-enveloped, and hemagglutinating virus (Gavier-Widén and Mörner, 1991), classified as a calicivirus (Ohlinger and Thiel, 1991). European brown hare syndrome virus (EBHSV) is highly contagious

and transmission usually occurs directly or indirectly by orofecal and respiratory routes (Xu and Chen, 1989).

European brown hare syndrome has been reported in many European countries (Frölich et al., 2001) but until now it was not known outside Europe (Lenghaus et al., 2001). In 1888, imported European brown hares were released for hunting in the province of Santa Fé, Argentina. Due to the presence of beneficial habitat the hare population increased rapidly and in 1907 the European brown hare was officially declared a pest. As a consequence, commercial hunting started in the early 1930s (Kujawski, 1998).

Our objective was to determine whether European brown hares in one area from Argentina were naturally infected with EBHSV.

### MATERIAL AND METHODS

The study area was located near the city of Azul (350 km southeast from Buenos Aires; 36°46'S, 59°57'W). European brown hares were culled and spleen and blood samples were collected by local Argentinian hunters. Eighty hares of both sexes and mixed ages (63 adult hares [ $>10$  mo]: 34 female, 29 male; 17 young hares [8–10 mo]: 12 female, five male) were shot between May and July 1998 ( $n=50$ ) and

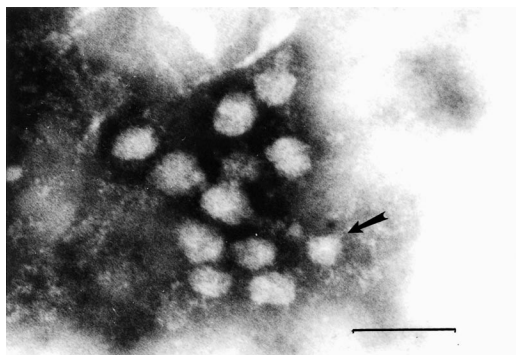


FIGURE 1. Negative staining electron microscope picture of calicivirus-like particles (36–40 nm) obtained from a spleen homogenate of a European brown hare from Argentina (Bar=100 nm).

in 2000 ( $n=30$ ), respectively. Sera and spleen samples were stored at  $-20\text{ C}$  and shipped frozen to the Institute for Zoo and Wildlife Research (IZW; Berlin, Germany) within 4 wk with support from Geti-Wilba GmbH (27432 Bremervörde, Germany). Virology and serology were performed on spleen and serum samples.

For antigen demonstration and serology we used an EBHSV-antigen and an antibody blocking enzyme-linked immunosorbent assay (ELISA) test kit according to Frölich et al. (1996) and Moussa et al. (1992). Spleen samples were tested for EBHSV-antigen and sera were tested for specific antibodies against EBHSV. Briefly, EBHSV-antigen ELISA microplates (Maxisorp, Nunc-Roskilde, Denmark) were coated with rabbit anti-EBHSV immunoglobulin G (IgG), and the supernatants from the spleen material were analyzed as quadruplicates. Following overnight incubation and washing, the wells were reacted with immunosorbent treated guinea-pig anti-EBHSV hyperimmune serum in two wells and with normal guinea-pig serum in the residual two wells, and finally all wells were incubated with rabbit anti-guinea-pig peroxidase conjugate (Denmark code P141, DAKO Diagnostik GmbH, Hamburg, Germany) and orthophenylene-diamine (OPD) substrate (Sigma-Chemie GmbH, Deisenhofen, Germany). The results were read at 490 nm on a MTF 10 spectrophotometer (Wissenschaftlicher Gerätebau, Berlin, Germany). Test samples that deviated  $>3$  standard deviation (SD) from the mean of the negative controls were considered positive.

A modification of the antigen-ELISA technique, as described above, was used for detection of blocking antibodies against EBHSV in a competitive assay. Briefly, serum samples were added to anti-EBHSV IgG pre-coated

wells, followed by a predetermined dilution of a known EBHSV-antigen suspension. After a new incubation period the previously described procedure for the antigen ELISA was followed. Sera that deviated  $<3$  SD from the mean of negative control sera in a dilution of  $\geq 1:10$  were considered antibody positive. Sensitivity and specificity of the antibody-blocking ELISA was 100% and 60% in a serum dilution of  $\geq 1:2$ , respectively and 100% for both in a dilution  $\geq 1:4$ .

Spleen samples of five EBHSV antigen positive hares where a sufficient quantity of samples was available, were examined by electron microscopy using the negative staining technique according to Gelderblom and Ötzel (1983). Specimens were homogenized in a tissue grinder with sterile sea sand and phosphate buffered saline (PBS, pH 7.2). After centrifugation, the sediment was placed on 100 mesh copper grids (Baltec, Walluf, Germany) covered with formvar film and coated with carbon (Plano, Marburg, Germany). Finally, the grids were negatively stained with 2% phosphotungstic acid (Serva, Heidelberg, Germany) pH 7.0 and examined on an EM 902 A electron microscope (Carl Zeiss, Oberkochen, Germany).

## RESULTS

European brown hare syndrome virus antigen was present in nine of 80 (11%) spleen samples examined. Of these, seven samples were positive when diluted 1:10 and two samples were positive up to a dilution of 1:100 (Table 1). Virus particles characteristic for calicivirus were found in one spleen homogenate of the nine EBHSV-antigen-positive hares by negative staining electron microscopy. Antibodies against EBHSV were detected in only one of 80 hares. This serum was positive when diluted 1:10. However, the corresponding spleen sample was negative for EBHSV-antigen.

## DISCUSSION

Nine European brown hares from Argentina were positive for EBHSV-antigen but negative for antibodies against EBHSV in the corresponding serum sample. In these cases the hares might have been shot prior to development of specific antibodies in an early viremic stage of infection or serum sample quality was poor affecting

TABLE 1. Antibody titers against European brown hare syndrome virus among free-ranging European brown hares from Argentina.

	1998						2000		
	a <sup>a</sup>	a	a	a	a	a	a	y <sup>a</sup>	a <sup>b</sup>
Age									
Sex	m <sup>a</sup>	f <sup>a</sup>	f	f	m	m	f	m	f
Titer	1:100	1:10	1:10	1:10	1:10	1:100	1:10	1:10	1:10

<sup>a</sup> y=young, a=adult, m=male, f=female.

<sup>b</sup> Electron microscopy positive sample.

test sensitivity. The low number of antibody-positive reactors in general may be also explained by the poor serum sample quality. Viral particles indicative of calicivirus were demonstrated by negative staining electron microscopy in one of five antigen-positive hares. However, virus isolation, molecular characterization, pathology, and experimental investigations of the pathogenicity of this virus have not been performed but will be conducted in the future.

To our knowledge, this is the first report of EBHSV-antigen and antibodies in free-ranging hares from South America. In the study area, EBHS has not been reported to cause abnormal mortality in hares to date. However, undetected wildlife die-offs in this area cannot be excluded.

It is conceivable, that a less pathogenic variant of EBHSV may be present in the population investigated which does not cause clinical symptoms suggestive of EBHS. This form of EBHSV may have been carried from Europe to Argentina in the 19th century by the importation of European brown hares and remained apathogenic until now. This hypothesis is supported by the following studies; Bascunana et al. (1997) reported detection of EBHSV-antigen by polymerase chain reaction in paraffin embedded specimens collected in the 1970s in Sweden, although the earliest confirmed clinical case characterized by severe hepatic lesions was found in 1980 (Gavier-Widén and Mörner, 1989). Lesions consistent with EBHS have been described from England since 1976 (Duff et al., 1994) and specific antibodies were found in sera archived since 1962

(Duff et al., 1997), although confirmed clinical cases of EBHS were first diagnosed by pathologic and electron microscopy findings in the UK in 1990 (Chasey and Duff, 1990). This demonstrates that EBHSV might have occurred in European hare populations years before clinical signs of EBHS were described. Retrospective serologic investigations on the closely related rabbit hemorrhagic disease virus (RHDV) also revealed similar results in Europe; antibodies against RHDV were found in rabbit sera from the Czech Republic and Austria as far back as 1961, indicating that an apathogenic variant of the virus had been endemic in European rabbits for some time before clinical signs of the infection appeared (Nowotny et al., 1997).

In conclusion, it is conceivable that a less pathogenic variant of EBHSV may exist among European brown hares in Argentina and that an ancestor of the present European EBHSV strain might have been apathogenic.

#### ACKNOWLEDGMENTS

The authors thank Geti-Wilba GmbH (Germany) for their assistance regarding the transport of samples. We also thank D. Viertel, B. Kirsch and K. Hönig for their technical assistance and R. Delahay for correcting the manuscript.

#### LITERATURE CITED

- BASCUNANA, C. R., N. NOWOTNY, AND S. BELAK. 1997. Detection and differentiation of rabbit hemorrhagic disease and European brown hare syndrome viruses by amplification of VP60 genomic sequences from fresh and fixed tissue specimens. *Journal of Clinical Microbiology* 35: 2492–2495.

- CHASEY, D., AND P. DUFF. 1990. European brown hare syndrome and associated virus particles in the UK. *The Veterinary Record* 126: 623–624.
- DUFF, J. P., D. CHASEY, R. MUNRO, AND M. WOOLDRIDGE. 1994. European brown hare syndrome in England. *The Veterinary Record* 134: 669–673.
- , K. WHITWELL, AND D. CHASEY. 1997. The emergence and epidemiology of European brown hare syndrome in the UK. *In Proceedings: First international symposium on calicivirus, European Society for Veterinary Virology* 1: 176–181.
- FRÖLICH, K., H. H. D. MEYER, Z. PIELOWSKI, L. RONSHOLT, S. VON SECK-LANZENDORF, AND M. STOLTE. 1996. European brown hare syndrome in free-ranging hares in Poland. *Journal of Wildlife Diseases* 32: 280–285.
- , G. HAERER, L. BACCARINI, M. JANOVSKY, M. RUDOLPH, AND M. GIACOMETTI. 2001. European brown hare syndrome (EBHS) in free-ranging European brown and mountain hares from Switzerland. *Journal of Wildlife Diseases* 37: 803–807.
- GAVIER-WIDEN, D., AND T. MÖRNER. 1989. The European brown hare syndrome in Sweden. *In Proceedings: 31st International Symposium über die Erkrankungen der Zoo- und Wildtiere. Dortmund, Germany*, pp. 261–264.
- , AND ———. 1991. Epidemiology and diagnosis of the European brown hare syndrome in Scandinavian countries. *Revue Scientifique et Technique* 10: 453–458.
- GELDERBLUM, H., AND M. ÖTZEL. 1983. Zur Virusdiagnostik mit dem Elektronenmikroskop. *Kleintierpraxis* 28: 39–45.
- KUJAWSKI, O. E. J. GRAF. 1998. *Die neue Wild Küche*. 2. Aufl., Leopold Stocker Verlag, Graz, Germany, 72 pp.
- LAVAZZA, A., AND G. VECCHI. 1989. Osservazioni su alcuni episodi di mortalità nelle lepri. Evidenziazione al microscopio elettronico di una particella virale. Nota preliminare. *Selezione Veterinaria* 30: 461–467.
- LENGHAUS, C., M. J. STUDDERT, AND D. GAVIER-WIDEN. 2001. Calicivirus infections. *In Infectious diseases of wild mammals*, 3rd Edition, E. S. Williams and I. K. Barker (eds.). Iowa State University Press, Ames, Iowa, pp. 280–291.
- MOUSSA, A., D. CHASEY, A. LAVAZZA, L. CAPUCCI, B. SMID, G. MEYERS, C. ROSSI, H.-J. THIEL, R. VLAŠAK, L. RONSHOLT, N. NOWOTNY, K. MCCULLOUGH, AND D. GAVIER-WIDEN. 1992. Haemorrhagic disease of lagomorphs: Evidence for a calicivirus. *Veterinary Microbiology* 33: 375–381.
- NOWOTNY, N., C. R. BASCUNANA, A. BALLAGI-PORDANY, D. GAVIER-WIDEN, M. UHLEN, AND S. BELAK. 1997. Phylogenetic analysis of rabbit haemorrhagic disease and European brown hare syndrome viruses by comparison of sequences from the capsid protein gene. *Archives of Virology* 142: 657–673.
- OHLINGER, V. F., AND H. J. THIEL. 1991. Identification of the viral hemorrhagic disease virus of rabbits as a calicivirus. *Revue Scientifique et Technique* 10: 311–323.
- POLI, A., M. NIGRO, D. GALLAZZI, G. SIRONI, A. LAVAZZA, AND D. GELMETTI. 1991. Acute hepatitis in the European brown hare (*Lepus europaeus*) in Italy. *Journal of Wildlife Diseases* 27: 621–629.
- SECK-LANZENDORF, S. 1997. Der Einfluss des Ökofaktors Erkrankungen auf die Populationsentwicklung des Feldhasen (*Lepus europaeus*) im Forschungsrevier Czempin in Polen. *Veterinär Medizinische Dissertation, Freie Universität Berlin, Germany*, 231 pp.
- XU, Z. J., AND W. X. CHEN. 1989. Viral hemorrhagic disease in rabbits: A review. *Veterinary Research Communications* 13: 205–212.

Received for publication 15 February 2002.