

# CLINICAL RESPONSE OF CAPTIVE COMMON WOMBATS (*VOMBATUS URSINUS*) INFECTED WITH *SARCOPTES SCABIEI* VAR. *WOMBATI*

Lee F. Skerratt<sup>1,2,3</sup>

<sup>1</sup> University of Melbourne, School of Veterinary Science, Veterinary Clinical Centre, 250 Princes Highway, Werribee, Victoria 3030, Australia

<sup>2</sup> Current address: US Department of the Interior, US Geological Survey, National Wildlife Health Center, 6006 Schroeder Road, Madison, Wisconsin 53711, USA

<sup>3</sup> Corresponding author (email: lskerratt@usgs.gov)

**ABSTRACT:** Seven common wombats (*Vombatus ursinus*) were exposed and two of these were re-exposed to *Sarcoptes scabiei* var. *wombati* (Acari: Sarcoptidae). For wombats exposed for the first time, five exposed to 5,000 mites on their shoulder developed moderate to severe parakeratotic mange after 11 wk compared with two given 1,000 mites that developed mild clinical signs of mange after 11 wk. For re-exposed wombats, one of two given 5,000 mites developed mild parakeratotic mange and the other developed severe parakeratotic mange. Initial signs of mange were erythema followed by parakeratosis, alopecia, excoriation and fissuring of parakeratotic crust and skin. Erythema usually became apparent within 14 days after exposure (DAE) or within 24 hrs of re-exposure. Parakeratosis was visible 14–21 DAE and alopecia first occurred 35–77 DAE. Clinical signs increased in severity over time and lesions spread slowly from the site of exposure. Mangy wombats scratched excessively, lost weight, and exhibited a significant neutrophilia compared with control wombats. Treatment of mange with three injections of ivermectin, 300 µg/kg, 10 days apart led to complete resolution of clinical signs. However mites were not entirely eliminated until wombats received a second regime of treatment.

**Key words:** Clinical pathology, clinical signs, common wombat, experimental infection, sarcoptic mange, *Sarcoptes scabiei*, *Vombatus ursinus*.

## INTRODUCTION

Sarcoptic mange caused by *Sarcoptes scabiei* var. *wombati* currently occurs throughout the range of the common wombat (*Vombatus ursinus*) in southeast Australia and has the potential both to dramatically reduce the local abundance of wombats and threaten the survival of small isolated populations (Martin et al., 1998). However there has been little investigation of sarcoptic mange in wombats and the application of knowledge of *S. scabiei* in humans and other animals to this unique fossorial marsupial herbivore may be inappropriate (Skerratt et al., 1998). The histopathologic changes in skin and internal organs of common wombats with severe parakeratotic sarcoptic mange have been investigated (Skerratt, 1998). The lesions in affected wombat skin are similar to those found in other animals and humans except for the consistently mild inflammatory infiltrate seen in the dermis of wombats compared with the variable re-

sponse seen in other animals and humans (Skerratt, 1998). In addition, concurrent disease, which is a risk factor for severe parakeratotic sarcoptic mange in other animals and humans, is rare in free-living wombats (Skerratt, 1998).

Clinical signs, intensity of mite infection, and clinical pathology in free-living wombats with severe hyperkeratotic sarcoptic mange were recently investigated (Skerratt et al., 1999). Clinical signs of parakeratosis and alopecia were correlated with intensity of infection and several clinical pathologic changes indicative of anemia, inflammation, and starvation were seen (Skerratt et al., 1999). However, the published data provide no information on the temporal development of clinical signs or clinical pathologic changes. Such information is essential for diagnosing infections of short duration and for understanding the effects of mange on wombats. Therefore, the purpose of the study was to examine the clinical and clinical pathologic

responses of wombats exposed and re-exposed to varying numbers of mites.

## MATERIALS AND METHODS

### Collection and preparation of animals

Eight female and one male free-living sub-adult and adult common wombats (mean weight of 23 kg) were trapped on a cattle farm at Glenburn, Victoria, Australia (37°26'S, 145°25'E) by placing cage traps over active burrow entrances (McIlroy, 1976). Wombats without signs of sarcoptic mange (Skerratt et al., 1999) were transported to the Veterinary Clinical Centre (University of Melbourne, Werribee, Victoria), and housed in 20 m<sup>2</sup> cattle pens inside a shed. Each pen had a male and female or two females. The pens contained two kennels and a bed of straw on a concrete floor. Wombats were fed lucerne and clover hay, fresh oats, carrots, and straw and were given fresh water daily. They appeared to adjust to captivity within a few days.

A 10 cm<sup>2</sup> skin scraping was taken from the shoulder of wombats brought into captivity. Skin scrapings were examined under a stereomicroscope for the presence of mites. *Sarcoptes scabiei* were not found, however, five wombats were lightly infected with the endemic mite *Acaroptes vombatus*, which is regularly present on wombats and is usually not associated with skin disease (Skerratt, 1998). Therefore, all wombats were given two subcutaneous treatments of ivermectin at 200 µg/kg (Ivomec, Merck Sharp & Dohme Australia, South Granville, New South Wales, Australia) 10 days apart to eradicate *A. vombatus* and any undetected *S. scabiei*. All wombats were infested with ticks, mostly the common wombat tick (*Aponomma auruginans*), but some were infested with a few *Ixodes tasmani*. Ticks were removed manually if still attached following ivermectin treatment.

### Collection and preparation of *S. scabiei*

Two free-living adult common wombats with severe mange were collected from Kinglake (37°32'S, 145°22'E) and Healesville (37°41'S, 145°32'E), Victoria. Mangy wombats were euthanized with pentobarbitone sodium (162.5 mg/kg, Lethabarb, Virbac, Peakhurst, New South Wales, Australia) and mites were collected from skin and parakeratotic crust placed in petri dishes in a metal tray which was vibrated and warmed by a magnetic stirrer hot plate. This stimulated mites to move out of skin and parakeratotic crust (Sheahan and Hatch, 1975). Mites in petri dishes were counted using a stereomicroscope. The wombat from which mites were collected for the first experiment

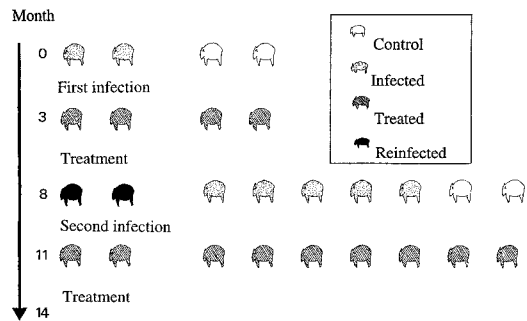


FIGURE 1. Schematic representation of experimental infection of wombats with *Sarcoptes scabiei* var. *wombati*. In the first part of the experiment, two wombats were exposed to 1,000 mites and there were two control wombats. Wombats were treated with ivermectin after 3 mo. At 8 mo, two wombats were re-exposed and five were exposed for the first time to 5,000 mites; there were two control wombats. Wombats were treated with ivermectin 3 mo later.

(see below) was dead 24 hr before mites were harvested. For the second experiment, mites were harvested immediately after the wombat was euthanized and were kept at room temperature or at 10 C overnight before being transferred to experimental wombats.

### Study design (Fig. 1)

**Experiment 1:** A pilot study to see if wombats would develop mange after being exposed to approximately 1,000 mixed life-cycle stages of *S. scabiei* was conducted. Four healthy wombats were held in captivity for 35 days prior to exposure in order to allow them to adapt to captivity and for the acaricidal activity of the ivermectin treatment to wane. In swine, given a similar treatment regime of ivermectin, acaricidal activity, which prevents *S. scabiei* infection, persists for 9 days after treatment (Arends et al., 1999). Two wombats were exposed simultaneously and two remained as unexposed controls and were kept separate from the exposed wombats. Eleven weeks after exposure to mites, all wombats were treated with three doses of ivermectin at 300 µg/kg, each dose given 10 days apart. Wombats were also given long acting penicillin injections, procaine and benzathine penicillin, 15 mg/kg and 11 mg/kg, respectively (Norocillin LA, Heriot, Rowville, Victoria, Australia).

**Experiment 2:** Five months after wombats were treated for mange in experiment 1, three additional wombats, which had been in captivity for 90 days were exposed simultaneously to approximately 5,000 mixed life-cycle stages of mites. The four wombats from the first exper-

iment were also exposed to 5,000 mites, which was the second time that two of these animals had been exposed. These two wombats were exposed on the right shoulder opposite to the left shoulder exposed in the first experiment. Therefore seven wombats were exposed to 5,000 mites, five for the first time and two re-exposed. Two animals that had been in captivity for 9 mo were kept separate as unchallenged controls. All wombats were treated with ivermectin and penicillin 11 wk after exposure to mites using the same regime as in experiment 1.

Wombats were anesthetized with tiletamine/zolazepam at 4 mg/kg (Zoletil, Virbac, Peakhurst, New South Wales, Australia) in order to brush mites from petri dishes onto an area of approximately 500 cm<sup>2</sup> on their left shoulder. Wombats were anesthetized once a week for 5 wk and then once biweekly for 6 wk to visually assess the skin, to monitor clinical signs of sarcoptic mange, and to take 7 mm diameter skin biopsies to examine the cellular response to mite infection. In addition to tiletamine/zolazepam, wombats were given local anesthetic, lignocaine hydrochloride 20–40 mg (2% Lignocaine, Troy Laboratories, Smithfield, New South Wales, Australia), at the site for biopsy. Biopsy wounds were sutured with 0.4 mm thick nylon suture (Vetafil, Bengen, Germany). At this time wombats were weighed and blood taken from the cephalic vein for hematology and serum biochemistry.

Skin scrapings (10 cm<sup>2</sup>) or skin biopsies were taken during and at the end of experiments from shoulders exposed to mites to determine the intensity of mite infection (mites/cm<sup>2</sup>). These were macerated in 10% potassium hydroxide in test tubes placed in boiling water until the skin had dissolved. To determine the number of mites, the solution was made up to 10 ml with water and an aliquot of between 1–5 ml, depending on the density of mites and the solution's opacity, was examined under a stereomicroscope. If the density of mites was very high, then a 1 ml aliquot was added to 9 ml of water and an aliquot of between 1–5 ml of this solution was taken depending on the density of mites (Skerratt et al., 1999). On day 77 after exposure, each mangy and control wombat was monitored for 10 min when not sleeping, eating, or drinking to determine the proportion of time spent scratching.

Hematologic parameters were measured using a Coulter Counter, Model S-Plus 4, impedance hematology analyser, calibrated with human blood (Coulter Electronics, Hialeah, Florida, USA), and by examination with a compound microscope of a blood smear stained by the May-Gruenwald-Giemsa method (Strumia,

1963). Electrolyte concentrations were determined by the ion-specific potentiometry method (Baker and Silverton, 1985) using a Vet Lyte electrolyte analyser (Idexx Laboratories, Zetland, New South Wales, Australia). Calcium, phosphate, urea nitrogen, creatinine, glutamate dehydrogenase, alkaline phosphatase, aspartate aminotransferase, and creatine kinase concentrations were determined colorimetrically with a Cobas Mira spectrophotometer (Roche Diagnostics, Branchburg, New Jersey, USA) using reagents and methods from Trace Scientific (Baulkham Hills, New South Wales, Australia). Albumin and total protein concentrations were determined colorimetrically using methods and reagents from Randox Laboratories (Crumlin, Antrim County, UK). Electrophoretograms were performed on Gelman super sraphore mylar supported cellulose acetate strips in a Gelman semi-micro electrophoresis chamber. The strips were stained with Ponceau S and scanned with a Gelman ACD-18 densitometer (Gelman Sciences, Ann Arbor, Michigan, USA).

#### Data analysis

Changes in weight and hematologic and serum biochemical parameters between 0 and 77 days after exposure (DAE) were compared for infected and control wombats. Differences were assessed for significance using the Student's two tailed *t*-test, for paired and independent samples assuming either equal or unequal variances or the Mann-Whitney *U*-test (Sokal and Rohlf, 1997). When differences were significant, a repeated measures general linear model was used to test whether the change in the parameter during the course of the experiment at 0, 19, 34, and 77 DAE, was significantly different between exposed and control wombats (Sokal and Rohlf, 1997). The coefficient of rank (Spearman's) correlation, one tailed, was used to determine the correlation between two continuous variables (Sokal and Rohlf, 1997). All statistical calculations were performed either using a hand calculator or SPSS® for Windows 8.0 (SPSS Inc., Chicago, Illinois, USA). Differences were regarded as significant when *P* < 0.05. Two exposed wombats, No. 1 and No. 7, were excluded from statistical tests since one (No. 1) did not develop clinical signs of mange apart from erythema and excoriation and another (No. 7) died during the course of the experiment.

## RESULTS

### Clinical observations

All exposed animals developed clinical signs of sarcoptic mange whether wombats

had 1,000 ( $n=2$ ) or 5,000 ( $n=7$ ) *S. scabiei* placed on their shoulder or whether wombats were exposed for the first time ( $n=7$ ) or re-exposed ( $n=2$ ). Seven exposures resulted in erythema, parakeratosis, alopecia, and excoriation and fissuring of parakeratotic scale and skin. These occurred in one wombat (No. 2) given 1,000 mites for the first time, four (Nos. 3–6) given 5,000 mites for the first time, and two (Nos. 1 and 2) re-exposed to 5,000 mites (Table 1). In contrast, two exposures led to only some of the above clinical signs, erythema, and excoriation in a wombat (No. 1) given 1,000 mites for the first time and parakeratosis and fissuring of parakeratotic scale and skin in a wombat (No. 7) given 5,000 mites for the first time (Table 1). Previous infection with *Acaroptes* did not appear to affect the outcome of exposure to *S. scabiei* (Table 2). The four control wombats did not develop lesions.

Although the rate of development of lesions varied among wombats given a similar number of mites, clinical signs of mange developed earlier and lesions progressed more rapidly on wombats exposed to 5,000 mites compared with wombats exposed to 1,000 mites (Fig. 2, Table 1). In addition, erythema was seen earlier but lesions developed at a slower rate in re-exposed wombats (Fig. 2). This was seen especially in wombat (No. 2), which had previously developed mild sarcoptic mange (Table 1). The sequence of development of clinical signs of sarcoptic mange in eight of nine wombats was erythema, shortly followed by parakeratotic scale, which was adherent to the skin, and then several weeks later alopecia, excoriation, and fissuring of parakeratotic scale and skin (Table 1, Fig. 2).

The time of onset and rate of development of erythema, parakeratotic scale, and hair loss in each wombat are given in Table 1. Lifting of parakeratotic scale from the skin correlated with initial signs of alopecia. However, once parakeratotic scale started to build up and form a crust it was less likely to lift. Signs of excoriation were

evident in two wombats (Nos. 1 and 2) given 1,000 mites by 77 DAE and in six of seven wombats (Nos. 3–6 and 1 and 2 upon re-exposure) given 5,000 mites by 49 DAE. Fissuring of skin and parakeratotic crust first became apparent by 49 DAE and was present in all wombats that were exposed for the first time to 5,000 mites by 77 DAE.

#### Lesion distribution

During the course of infection, erythema and parakeratosis spread from the site of exposure on the left shoulder onto the face and along the flanks. The parakeratosis also thickened to form a parakeratotic crust, several millimeters thick on the shoulder of six wombats (Table 2). Erythema spread to the ventral surfaces of the thorax and abdomen and to the medial surface of the legs. Alopecia was confined mainly to the shoulder region but its severity increased during the experiment. Excoriation was evident on shoulders, flanks, and ventral surfaces. Fissuring of parakeratotic crust and skin was confined to the shoulders and flanks. The right shoulder, opposite the one exposed, developed erythema and some parakeratosis by 77 DAE in four wombats that developed severe parakeratotic sarcoptic mange on their left shoulder. In three wombats that developed mild to moderate parakeratotic sarcoptic mange on their left shoulder, the right shoulder showed little to no signs of sarcoptic mange.

#### Mite populations

*Sarcoptes scabiei* were recovered from eight of nine clinically affected wombats at the end of the experiments; six of seven wombats exposed for the first time and two of two re-exposed wombats (Table 2). Intensity of infection increased dramatically in wombats that were initially exposed to 5,000 mites (Table 2). Intensity of infection did not appear to increase greatly in one wombat (No. 2) exposed to 1,000 mites and mites were not found on another wombat (No. 1) given 1,000 mites

TABLE 1. Temporal development of clinical signs of sarcoptic mange in wombats exposed and re-exposed to 1,000 and 5,000 mites. Stars (\*) indicate presence, severity, and extent of clinical sign.

Wombat	Mites	Sign	Day treated ↓																
			0	1	3	14	21	35	49	77	105	112	119	140	161				
1	1,000	Erythema <sup>a</sup> Scale <sup>b</sup>							*										
2	1,000	Hair loss <sup>c</sup>				*	*	**	**	**	**	**	*	**	*				
		Erythema Scale			*	*	*	*	*	*	*	*	*	*	*	*	*	*	*
3	5,000	Hair loss				*	*	**	**	**	**	**	**	**	**	**	*	*	*
		Erythema Scale			*	*	*	*	*	*	*	*	*	*	*	*	*	*	*
4	5,000	Hair loss			*	*	*	*	*	*	*	*	*	*	*	*	*	*	*
		Erythema Scale			*	*	*	*	*	*	*	*	*	*	*	*	*	*	*
5	5,000	Hair loss		*	*	**	**	**	**	**	**	**	**	**	**	**	**	**	**
		Erythema Scale			*	*	*	*	*	*	*	*	*	*	*	*	*	*	*
6	5,000	Hair loss			*	*	*	*	*	*	*	*	*	*	*	*	*	*	*
		Erythema Scale			*	*	*	*	*	*	*	*	*	*	*	*	*	*	*
7	5,000	Hair loss			*	*	*	*	*	*	*	*	*	*	*	*	*	*	*
		Erythema Scale			*	*	*	*	*	*	*	*	*	*	*	*	*	*	*
1 (Reinfected)	5,000	Hair loss			*	*	*	*	*	*	*	*	*	*	*	*	*	*	*
		Erythema Scale			*	*	*	*	*	*	*	*	*	*	*	*	*	*	*
2 (Reinfected)	5,000	Hair loss		*	*	**	**	**	**	**	**	**	**	**	**	**	**	**	**
		Erythema Scale			*	*	*	*	*	*	*	*	*	*	*	*	*	*	*
Controls (n=4)	0	Hair loss				*	*	*	*	*	*	*	*	*	*	*	*	*	*
		Erythema Scale				*	*	*	*	*	*	*	*	*	*	*	*	*	*

<sup>a</sup> Erythema \* represents erythema on the exposed shoulder, each additional star (\*) represents erythema in an additional region, these being flank, face, abdomen, and chest.  
<sup>b</sup> Scale \* represents parakeratotic scale developing on the exposed shoulder, \*\* represents an increase in thickness of scale to 1–2 mm and the formation of continuous sheets of scale, additional stars (\*) represent the spread of parakeratosis to the flank and increasing thickness of scale with five stars indicating a scale thickness of approximately 10 mm thick on the shoulder.  
<sup>c</sup> Hair loss \* represents the first signs of hair loss on the exposed shoulder, additional stars (\*) represent increasing hair loss on the shoulder region and hair loss on the flank, with five stars indicating complete hair loss on the shoulder.



TABLE 2. Number of mites/cm<sup>2</sup> and thickness of scale crust on shoulders, percent of time spent scratching determined at 10 min periods of observation, and change in numbers of circulating neutrophils at 46 and 77 days after exposure of wombats to 1,000 or 5,000 mites on their shoulders.

Wombat	Number of mites Day 0	Mites on shoulder (/cm <sup>2</sup> )				Crust	Scratch	Neutrophil	Weight
		Day 46		Day 77		(mm)	(% of 10 min)	increase (×10 <sup>9</sup> /l)	increase (kg)
		Left	Right	Left	Right	Day 77 Right	Day 77	Day 77	Day 77
1 (Exposed) <sup>a</sup>	1,000	0	0	0	0	0	ND <sup>b</sup>	-2.1	2.8
2 (Exposed)	1,000	0	0	0.3	0	0	ND	3	1.6
3 (Exposed) <sup>a</sup>	5,000	0	66	9	6,200	10	52%	6.8	-1.1
4 (Exposed)	5,000	0	320	3	11,600	5	32%	10.6	-3.3
5 (Exposed) <sup>a</sup>	5,000	0	72	0	1,200	2	11%	-0.2	-0.9
6 (Exposed)	5,000	0	144	35	10,800	8	67%	6.4	-3
7 (Exposed)	5,000	0	2,480	ND <sup>c</sup>	ND <sup>c</sup>	ND <sup>c</sup>	ND <sup>c</sup>	ND <sup>c</sup>	ND <sup>c</sup>
1 (Re-exposed) <sup>a</sup>	5,000	0	20	8	4,800	4	9%	3.3	-1.3
2 (Re-exposed)	5,000	0	12	0	220	0	12%	2.1	-0.9
3 (Control) <sup>a</sup>	0	0	0	0	0	0	ND	0.5	3.6
4 (Control)	0	0	0	0	0	0	ND	0.2	3.1
8 (Control) <sup>a</sup>	0	0	0	0	0	0	2%	1.4	-1.2
9 (Control) <sup>a</sup>	0	0	0	0	0	0	0%	1.1	1.5

<sup>a</sup> Wombats previously infected with *Acaroptes*.

<sup>b</sup> ND=Not determined.

<sup>c</sup> Wombat No. 7 died on day 49.

that only developed erythema by 49 DAE (Table 1). For wombats given 5,000 mites, the lowest intensity of infection by at least a factor of five, 77 DAE, occurred in a reinfected wombat given 5,000 mites (Table 2). The highest intensity of infection by at least a factor of five, 49 DAE, occurred in a wombat given 5,000 mites that lost 12% of its starting body weight (Table 2). *Sarcoptes scabiei* were never found on control wombats. The density of mites was correlated with the thickness of parakeratotic crust on the shoulder for wombats given 5,000 mites,  $r=0.77$  ( $P<0.05$ ,  $n=6$ ), but not time spent scratching ( $P=0.1$ ,  $n=6$ ) (Table 2). Wombats with mange scratched significantly more than control wombats ( $P<0.05$ ,  $n=8$ ) using the Mann-Whitney  $U$ -test or the Student's two tailed  $t$ -test, for independent samples assuming unequal variances (Table 2).

#### Response to ivermectin

Clinical signs resolved in all wombats treated with three subcutaneous injections of ivermectin at 300  $\mu\text{g}/\text{kg}$  with each injection

given 10 days apart. However, a recrudescence of mild sarcoptic mange occurred in three wombats 2 mo after the last injection of ivermectin. *Sarcoptes scabiei* were recovered from skin scrapings. These wombats had the greatest intensity of infection prior to treatment. These wombats were re-treated with three injections of ivermectin and it appears that mites were successfully eliminated since they showed no signs of mange 4 mo after the last injection of ivermectin in the second treatment.

After treatment with ivermectin, parakeratotic crust started to detach from skin within 10 days and large amounts detached after 20 days. Fissuring of skin disappeared within 20 days. Within 28 days, parakeratotic crust had detached from the skin with most of it having been removed by the wombat. Erythema and excoriation were reduced but did not disappear until 63 days after treatment commenced (DAT). Alopecia increased substantially after treatment and extended until all parakeratotic crust had been removed 63 DAT. Hair regrowth became evident once scale

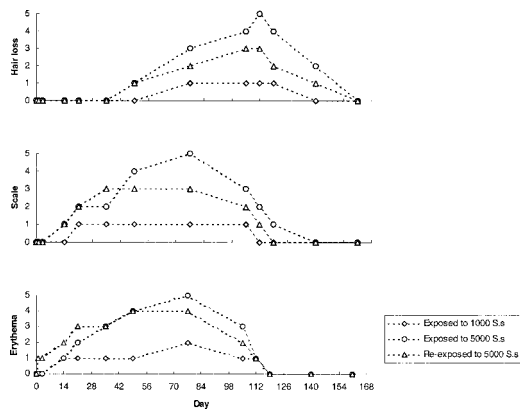


FIGURE 2. Temporal development of clinical signs of sarcoptic mange in wombats exposed to 1,000 ( $n=2$ ) and 5,000 ( $n=4$ ) mites and re-exposed to 5,000 ( $n=2$ ) *Sarcoptes scabiei* on their shoulders. The vertical scale is categorical and represents the increasing severity and extent of a clinical sign. Data points represent medians for each group of wombats raised to the nearest category. Categories are the same as used in Table 1 represented by a number here instead of stars as in Table 1. For erythema, each additional category represents erythema in a region additional to the shoulder, these being the flank, face, abdomen, and chest. For scale, category 1 represents parakeratotic scale developing on the exposed shoulder, category 2 represents an increase in thickness of scale to 1–2 mm and the formation of continuous sheets of scale, additional categories represent the spread of parakeratosis to the flank and increasing thickness of scale with category 5 indicating a scale thickness of approximately 10 mm thick on the shoulder. For hair loss, category 1 represents the first signs of hair loss on the exposed shoulder, additional categories represent increasing hair loss on the shoulder region and hair loss on the flank, with category 5 indicating complete hair loss on the shoulder.

crust had detached at 28 DAT but was not complete until 84 DAT.

#### Clinicopathologic findings

Seven infected wombats exhibited significant changes in counts of neutrophils and monocytes, and in concentration of sodium, phosphate, creatinine, total bilirubin, and gamma globulins by 77 DAE (Student's *t*-test for paired samples,  $P<0.05$ ; Tables 3, 4). However, only the concentration of leucocytes and neutrophils increased significantly after 77 days in wombats with mange compared with control wombats (Student's *t*-test, for in-

dependent samples, unequal variances assumed,  $P<0.05$ ; repeated measures general linear model,  $P>0.05$ ; Tables 3, 4). The change in neutrophil concentration was correlated with intensity of infection for wombats given 5,000 mites,  $r=0.89$  ( $P<0.05$ ,  $n=6$ ; Table 2). The rise in leucocyte and neutrophil counts occurred steadily during the 77 days of infection. Wombats lost weight during the development of clinical signs and this decline was significant when compared to the change in weight of control wombats,  $-1.3$  kg $\pm 0.6$  standard error (SE) versus 2.0 kg $\pm 0.9$  SE (Student's *t*-test, independent samples, equal variances assumed,  $P<0.05$ ,  $n=12$ ). Prior to the first experiment, one control wombat and one wombat to be infected gained weight and the other control wombat and wombat to be infected lost weight in captivity. All wombats had either gained or maintained their weight in the months prior to the commencement of the second experiment apart from one female wombat that had lost 3 kg, 12% of its bodyweight, attributed to harassment by its male pen mate. It was moved to an enclosure on its own for the second experiment. This wombat later died through misadventure 49 days after the start of experiment 2.

#### DISCUSSION

Erythema, which is the first clinical sign of sarcoptic mange in wombats, usually occurs within 14 days of infection with 5,000 mites. Humans, pigs, and foxes develop delayed hypersensitivity reactions, of which erythema is a clinical sign, within 14–28 days of infection with *S. scabiei* (Mellanby, 1944; Davis and Moon, 1990a; Little et al., 1998). Parakeratosis followed the development of erythema within 14 days. It arises from the actions of mites burrowing in the Malpighian layer of the epidermis leading to disturbance of the terminal differentiation of squamous epithelial cells (Van Neste and Lachapelle, 1981; Van Neste and Staquet, 1986). Parakeratotic scale does not readily detach

TABLE 3. Hematologic values for wombats infected with *Sarcoptes scabiei* and control wombats prior to and 11 wk after experimental infection.

Parameter	Infected <sup>a</sup> (n=7)			Control <sup>b</sup> (n=4)		
	Day 0 Mean±SE	Day 77 Mean±SE	Change Mean±SE	Day 0 Mean±SE	Day 77 Mean±SE	Change Mean±SE
Hemoglobin (g/dl)	11.0±0.4	11.5±0.4	0.5±0.4	10.5±0.7	11.1±0.7	0.6±1.3
Hematocrit (%)	33.9±1.3	34.4±1.1	0.6±1.7	31.8±1.9	34.5±1.9	2.8±3.3
MCHC <sup>e</sup> (g/dl)	32.4±0.6	33.3±0.3	0.9±0.5	33.0±0.9	32.3±0.5	-0.8±1.2
Leucocytes (×10 <sup>9</sup> /l)	8.3±0.8	12.5±2.1	4.2 <sup>c</sup> ±1.4	10.3±2.4	10.6±1.6	0.2 <sup>c</sup> ±1.0
Bands (×10 <sup>9</sup> /l)	0	0	0	0	0	0
Neutrophils (×10 <sup>9</sup> /l)	2.9 <sup>e</sup> ±0.4	7.5 <sup>c</sup> ±1.7	4.6 <sup>d</sup> ±1.4	3.2±0.5	4.0±0.4	0.8 <sup>d</sup> ±0.3
Lymphocytes (×10 <sup>9</sup> /l)	5.1±0.5	4.2±0.6	-0.9±0.3	6.9±2.0	6.0±1.3	-0.9±0.8
Monocytes (×10 <sup>9</sup> /l)	0.04 <sup>e</sup> ±0.03	0.23 <sup>c</sup> ±0.05	0.19±0.07	0.05±0.05	0.18±0.7	0.12±0.09
Eosinophils (×10 <sup>9</sup> /l)	0.26±0.09	0.49±0.12	0.23±0.07	0.23±0.09	0.43±0.13	0.20±0.17
Basophils (×10 <sup>9</sup> /l)	0	0.08±0.04	0.08±0.04	0	0	0
NRC <sup>f</sup> (/100 leucocytes)	0	0	0	0.25±0.25	0	-0.25±0.25
Platelets (×10 <sup>9</sup> /l)	449±59	404±50	-46±21	516±172	455±130	-61±42
Total solids (g/l)	65.6±1.8	69.1±1.4	3.6±2.4	59.8±3.4	66.0±5.0	6.3±5.9

<sup>a</sup> Five female, two male, adult wombats.

<sup>b</sup> Four female, one sub-adult, and three adult wombats.

<sup>c,d</sup> Means in a row sharing an identical superscript letter are significantly different from each other ( $P<0.05$ ).

<sup>e</sup> MCHC = mean corpuscular hemoglobin concentration.

<sup>f</sup> NRC = nucleated red cell.



TABLE 4. Biochemical values for wombats infected with *Sarcoptes scabiei* and control wombats prior to and 11 wk after experimental infection.

Parameter	Infected <sup>a</sup> (n=7)			Control <sup>b</sup> (n=4)		
	Day 0 Mean±SE	Day 77 Mean±SE	Change Mean±SE	Day 0 Mean±SE	Day 77 Mean±SE	Change Mean±SE
Sodium (mmol/l)	142 <sup>c</sup> ±1	150 <sup>c</sup> ±3	8±2	142±2	147±2	5±2
Potassium (mmol/l)	5.3±0.2	5.1±0.1	-0.3±0.2	5.7±0.1	5.2±0.2	-0.7±0.4
Chloride (mmol/l)	101±1	105±2	4±1	103±0	104±2	1±2
Calcium (mmol/l)	2.5±0.0	2.5±0.1	0.1±0.1	2.7±0.1	2.2±0.2	-0.4±0.3
Phosphate (mmol/l)	1.5 <sup>c</sup> ±0.1	1.2 <sup>c</sup> ±0.1	-0.3±0.1	1.5±0.3	1.2±0.2	-0.3±0.2
Urea (mmol/l)	5.9±0.4	6.1±0.5	0.2±0.3	6.5±1.4	5.8±0.4	-0.6±1.7
Creatinine (mmol/l)	0.10 <sup>c</sup> ±0.00	0.07 <sup>c</sup> ±0.00	-0.02±0.00	0.09±0.01	0.08±0.00	-0.01±0.01
Glucose (mmol/l)	3.7±0.3	4.4±0.2	0.7±0.2	4.3±0.6	4.9±0.4	0.6±0.9
Total bilirubin (μmol/l)	2.7 <sup>c</sup> ±0.3	1.3 <sup>c</sup> ±0.5	-1.4±0.6	2.3±0.5	1.3±0.08	-1.0±1.1
Glutamate dehydrogenase (U/l)	10.2±1.5	10.8±1.1	0.7±1.0	14.5±3.5	13.5±0.5	-1.0±4.0
Alkaline phosphatase (U/l)	335±66	186±27	-149±44	410±171	412±61	3±118
γ-glutamyltransferase (U/l)	8.0 <sup>c</sup> ±0.7	4.9 <sup>c</sup> ±0.6	-3.1±0.5	6.0±2.0	5.0±0.7	-1.0±2.5
Aspartate aminotransferase (U/l)	45±5	40±2	-4±4	80±27	36±5	-44±30
Creatine kinase (U/l)	73±23	63±5	-9±22	1183±982	65±13	-1119±972
Total protein (g/l) biuret <sup>d</sup>	69±2	69±1	0±1	63±3	65±5	2±3
Albumin (g/l) bromocresol <sup>e</sup> electrophoretic <sup>f</sup>	31±1	31±0	0±1	29±2	30±2	1±2
Total globulins (g/l)	31±1	31±1	0±1	31±1	31±2	0±2
Alpha 1 (g/l)	38±1	38±2	0±1	32±2	34±3	2±2
Alpha 2 (g/l)	2.5±0.1	2.8±0.2	0.2±0.3	2.6±0.5	2.2±0.2	-0.4±0.6
Beta (g/l)	6.5±0.5	6.6±0.4	0.1±0.6	6.5±0.4	6.3±0.2	-0.2±0.4
Beta (g/l)	26±1	26±2	0±1	21±1	23±3	2±2
Gamma (g/l)	2.7 <sup>c</sup> ±0.3	1.5 <sup>c</sup> ±0.3	-1.2±0.4	1.9±0.2	2.3±0.5	0.3±0.7

<sup>a</sup> Five female, two male, adult wombats.

<sup>b</sup> Four female, one sub-adult, and three adult wombats.

<sup>c,d</sup> Means in a row sharing an identical superscript letter are significantly different from each other ( $P<0.05$ ).

<sup>d</sup> Determined by the biuret method.

<sup>e</sup> Determined by the bromocresol green method.

<sup>f</sup> Determined electrophoretically.

from skin and so forms a crust. The production of parakeratosis is correlated with the density of mites burrowing in the epidermis (Skerratt et al., 1999) and in this study the thickness of parakeratotic crust was also correlated with the intensity of infection. Alopecia and excoriation did not become evident until several weeks after erythema and parakeratosis had developed. A similar progression of dermatologic changes was reported in coyotes (*Canis latrans*), dogs, and foxes (*Vulpes vulpes*) (Stone et al., 1972; Samuel, 1981; Bornstein, 1991; Arlian et al., 1995; Bornstein et al., 1995). Alopecia and excoriation were caused by scratching or rubbing, which occurred more frequently in infected compared with control wombats. Although correlated with alopecia (Skerratt et al., 1999), intensity of infection may not be causally related to hair loss. Intensity of infection was not correlated with proportion of time spent scratching in this study. Rather, the degree of pruritus and therefore scratching probably reflects the severity of an underlying dermatologic immune response (Davis and Moon, 1990b) although there may be a pruritic sensation associated directly with large numbers of mites burrowing in the skin.

The slower rate of development of clinical signs of mange in wombats given 1,000 mites compared with those given 5,000 mites could be directly related to the infecting dose. For example it is known that the rate of development of signs of cutaneous hypersensitivity in pigs is dependent on the number of *S. scabiei* present (Davis and Moon, 1990a). Variation in the rate of development of clinical signs of mange in wombats given approximately the same number of mites could also be due to minor variations in the infective dose. However, the immune response of the wombat to the mite and individual skin characteristics such as degree of soiling of the skin may also affect the rate of development of clinical signs. Rapid induction phases have been reported for humans reinfected with *S. scabiei* (Mellanby, 1944) and it is note-

worthy that one wombat infected for the first time developed erythema 1 DAE (No. 5). This animal also developed less severe mange and a lower intensity of infection than other wombats infected for the first time with approximately the same number of mites, suggesting that its early response to mite infection may have retarded the development of mange. The reason for this relatively early response is not known but it is possible that this wombat had previously had mange in the wild and that the early response was anamnestic. A secondary immune response may explain why one wombat (No. 2) developed erythema within 24 hr of reinfection and subsequently only mild mange and the lowest intensity of infection. Such a response has been reported to affect mite survival in humans, rabbits, and dogs but not in foxes (Mellanby, 1944; Arlian et al., 1994, 1996; Little et al., 1998). Loss of weight prior to the experiment may explain why one wombat (No. 7) developed little erythema, hair loss, or excoriation, which might be a manifestation of a suppressed immune response due to stress arising from captivity. It might also explain why this wombat had the thickest parakeratotic crust and a greater intensity of infection. An incompetent immune response is recognised as promoting the development of parakeratotic sarcoptic mange in wombats (Skerratt, 1998).

One wombat (No. 1) exposed to 1,000 mites and held in contact with a second wombat (No. 2) that developed mange after being exposed to 1,000 mites, only developed clinical signs of erythema and slight excoriation. Mites were not found on this wombat at the end of the first experiment. It is possible that the mites, used to inoculate the wombat, were affected by the 24 hr delay in harvesting them and that they did not readily establish on their new host. In addition, this male wombat had dirty and often wet skin, which may have affected the ability of mites to infect it. It is possible that the threshold dose of *S. scabiei* required before mange will de-

velop varies between individuals since this wombat developed mange when it was given a higher dose of mites. Failure of *S. scabiei* to establish on a new host has occurred in an infection experiment with coyotes where a similar number of mites were transferred, 500–1,500 (Samuel, 1981).

Mange did not develop to any extent on the shoulder opposite the one infected after 77 days. Rather, mange occurred at the site of inoculation and then adjacent areas. Spread of infection from the inoculation site has also been reported for foxes. However, in this species, most of the body became involved within 4 wk after an initial dose of 5,500 mites (Little et al., 1998) reflecting a more rapid spread of mites than occurred in wombats. Mites also spread rapidly, within 5 wk, from the back to body extremities in dogs infected with *S. scabiei* from a red fox (Bornstein, 1991). Mites spread more slowly in red foxes infected on their midback with few mites, <200, with most body extremities infected within 4 mo (Bornstein et al., 1995). Rapid migration of mites from the body to the head in foxes is thought to be due to foxes gnawing at infection sites (Gerasimov, 1953). The slower migration of mites in wombats may be because they groom themselves differently than foxes and dogs, using only their claws and not their teeth, and do not sequentially groom their body (Triggs, 1996). Because wombats do not use their teeth they may not readily transfer mites from one side of the body to the other. This suggests that the symmetry of clinical signs of severe mange seen in free-living wombats (Skerratt et al., 1999) is due to mites infecting both sides of the wombat simultaneously or longer duration of infection. However, significant difference in intensity of infection of *S. scabiei* between adjacent sites on the body suggests that there are preferential sites for the mite (Skerratt et al., 1999).

The only significant hematologic change associated with development of sarcoptic mange in wombats was neutrophilia with-

out a left shift; this is indicative of a continuing acute but not overwhelming inflammatory response (Duncan et al., 1994). Neutrophilia may be largely due to secondary effects of *S. scabiei* infection, such as excoriation with traumatic injury to the skin and intra-dermal abscesses, although change in neutrophil concentration was correlated with intensity of infection. Skerratt (1998) reported that neutrophilic exocytosis in the skin of wombats with severe hyperkeratotic sarcoptic mange appeared to be associated more commonly with bacteria than mites. Free-living wombats with severe hyperkeratotic sarcoptic mange exhibited neutrophilia. However they also had other hematologic and biochemical changes indicative of anaemia, chronic inflammatory disease, and starvation (Skerratt et al., 1999), most likely reflecting a longer duration of clinical disease. *Sarcoptes scabiei* infection in other animals causes neutrophilia along with other hematologic and biochemical changes (Pence et al., 1983; Arlian et al., 1988b, 1995; Dalapati et al., 1996; Little et al., 1998). Difference in hematologic and biochemical changes among studies may be due to difference in severity, extent, and duration of mange rather than a host difference. Changes seen in this study are most similar to those seen in short term infection studies, 7–8 wk, of dogs and foxes (Arlian et al., 1995; Little et al., 1998). In addition to a significant rise in neutrophils, dogs exhibited a significant decrease in hemoglobin concentration and hematocrit and foxes exhibited a rise in eosinophils (Arlian et al., 1995; Little et al., 1998). Although animals developed severe mange in the current study and the studies of Arlian et al. (1995) and Little et al. (1998), hematologic and biochemical changes were few. It appears that mange must be chronic or occur in free-living animals before severe hematologic and biochemical changes occur (Arlian et al., 1988b; Pence et al., 1983; Dalapati et al., 1996; Skerratt et al., 1999).

Weight loss by mangy wombats has also

been seen in free-living wombats and is thought to be due to the "energy demands" of mange (Skerratt et al., 1999). The demand is not accounted for by the energy consumption of mites (Arlian et al., 1988a) but is likely to be due to production of parakeratotic scale and scratching and possibly due to reduced food intake secondary to systemic effects of severe inflammatory disease.

Recrudescence of sarcoptic mange in wombats after treatment and recovery from mange could have been due to reinfection by mites persisting in the environment, such as in scale crust. In cattle, the treatment regime used would have resulted in therapeutic levels of the drug being maintained for at least a month (Campbell, 1989), but similar data are not available for wombats. *Sarcoptes scabiei* survive at least 3 wk in the laboratory under favorable conditions of high humidity (97%) and low temperature (10 C; Arlian et al., 1989). Although ivermectin is an effective acaricide in a variety of mammals (Campbell, 1989), failure of treatment with three doses of ivermectin given 14 days apart has been reported in Australian aboriginals with crusted scabies (Walton et al., 1999). In wombats, successful elimination of mites may be achieved by concurrently treating with another acaricide topically and manually removing scale crust (unpubl. obs.). Similar treatment regimes have been used successfully in horses and humans with hyperkeratotic scabies (Christensson et al., 1984; Meinking et al., 1995). Higher doses of drug may be more effective, since psoroptic mites were eliminated more rapidly in rabbits given higher doses of ivermectin (800 µg/kg; Harikrishnan et al., 1996). However there is potential for drug toxicity especially in animals severely debilitated by sarcoptic mange because of an alteration in the pharmacokinetic properties of drugs.

In conclusion, the sequence of clinical signs of sarcoptic mange observed in wombats was generally consistent between animals and was independent of initial dose

of mites or of previous, recent exposure to *S. scabiei*. Erythema occurred initially, closely followed by parakeratotic scale, then alopecia and, finally, fissuring. The extent and severity of clinical signs such as the thickness of parakeratotic crust and degree of alopecia increased with time and spread slowly from the infection site. The rate of development of clinical signs was dependent on the initial dose of mites and probably on factors such as naïvety of the immune system and body condition. The rate of increase in intensity of infection was also probably dependent on similar factors. Neutrophils rose steadily in concentration in blood, weight was lost gradually, and pruritus increased significantly as sarcoptic mange developed in wombats. Treatment with three injections of ivermectin given 10 days apart led to complete resolution of clinical signs but not all mites were eliminated and there was a recrudescence of sarcoptic mange. Mites were successfully eliminated after a second treatment with three injections of ivermectin.

#### ACKNOWLEDGMENTS

C. Andersen and J. Bryant are especially thanked for help with handling, sample collection and husbandry of wombats. I. Beveridge and D. Middleton are thanked for supervision of this study and comments on the manuscript and G. Anderson is thanked for statistical advice. L. Steinmann, K. Steinmann, D. Harms, M. Twaddell, D. Reddan, J. McAuliffe, I. Beveridge, P. Holz, and J. Ferguson are thanked for their help in trapping wombats. D. Presidente, T. Smith, and Judy Robertson are thanked for clinical pathologic work. Two anonymous referees and an assistant editor are thanked for their comments on the manuscript. The Holsworth Wildlife Research Fund funded this research and Dr. Holsworth is thanked for his support. L. Skerratt was supported by an Australian postgraduate scholarship. This research was conducted with approval from the Veterinary Science Animal Experimentation Ethics Sub-Committee, register number 97082 and a permit from the Department of Natural Resources and Environment, permit number RP-97-138.

#### LITERATURE CITED

- ARENDS, J. J., T. L. SKOGERBOE, AND L. K. RITZHAUPT. 1999. Persistent efficacy of doramectin and iver-

- mectin against experimental infestations of *Sarcoptes scabiei* var. *swis* in swine. *Veterinary Parasitology* 82: 71–79.
- ARLIAN, L. G., M. AHMED, D. L. VYSZENSKI-MOHER, S. A. ESTES, AND S. ACHAR. 1988a. Energetic relationships of *Sarcoptes scabiei* var. *canis* (Acari: Sarcoptidae) with the laboratory rabbit. *Journal of Medical Entomology* 25: 57–63.
- , ———, AND ———. 1988b. Effects of *S. scabiei* var. *canis* (Acari: Sarcoptidae) on blood indexes of parasitized rabbits. *Journal of Medical Entomology* 25: 360–369.
- , D. L. VYSZENSKI-MOHER, AND M. J. POLE. 1989. Survival of adults and developmental stages of *Sarcoptes scabiei* var. *canis* when off the host. *Experimental and Applied Acarology* 6: 181–187.
- , C. M. RAPP, D. L. VYSZENSKI-MOHER, AND M. S. MORGAN. 1994. *Sarcoptes scabiei*: Histopathological changes associated with acquisition and expression of host immunity to scabies. *Experimental Parasitology* 78: 51–63.
- , M. S. MORGAN, C. M. RAPP, AND D. L. VYSZENSKI-MOHER. 1995. Some effects of sarcoptic mange on dogs. *Journal of Parasitology* 81: 698–702.
- , ———, ———, AND ———. 1996. The development of protective immunity in canine scabies. *Veterinary Parasitology* 62: 133–142.
- BAKER, F. J., AND R. E. SILVERTON. 1985. Introduction to medical laboratory medicine, 6th Edition. Butterworth & Co., Sydney, New South Wales, Australia, 383 pp.
- BORNSTEIN, S. 1991. Experimental infection of dogs with *Sarcoptes scabiei* derived from naturally infected wild red foxes (*Vulpes vulpes*): Clinical observations. *Veterinary Dermatology* 2: 151–159.
- , G. ZAKRISSON, AND P. THEBO. 1995. Clinical picture and antibody response to experimental *Sarcoptes scabiei* var. *vulpes* infection in red foxes (*Vulpes vulpes*). *Acta Veterinaria Scandinavica* 36: 509–519.
- CAMPBELL, W. C. 1989. Ivermectin and abamectin. Springer-Verlag, New York, New York, 363 pp.
- CHRISTENSSON, D., E. LINDSTEDT, M. WIERUP, AND J. AROSENIUS. 1984. *Sarcoptes*-skabb hos häst I Sverige. *Svensk Veterinärtidning* 36: 15–17.
- DALAPATI, M. R., M. K. BHOWMIK, AND S. SARKAR. 1996. Clinico-haematological, biochemical and pathomorphological changes of scabies in goats. *Indian Journal of Animal Science* 66: 351–354.
- DAVIS, D. P., AND R. D. MOON. 1990a. Density of itch mite, *Sarcoptes scabiei* (Acari: Sarcoptidae) and temporal development of cutaneous hypersensitivity in swine mange. *Veterinary Parasitology* 36: 285–293.
- , AND ———. 1990b. Dynamics of swine mange: A critical review of the literature. *Journal of Medical Entomology* 27: 727–737.
- DUNCAN, J. R., K. W. PRASSE, AND E. A. MAHAFFEY. 1994. *Veterinary laboratory medicine*. Iowa State University Press, Ames, Iowa, 300 pp.
- GERASIMOV, Y. A. 1953. Zudnevaya chesotka dikikh lisits. Bsesoyuznii Nauchno-issledovatel' skii Institut, Ohotnichevo Promisla. *Voprosy Biologii Pushnykh Zverey* 13: 116–134.
- HARIKRISHNAN, T. J., D. B. PREMKUMAR, G. SARATH-CHANDRA, AND A. ALBERT. 1996. Efficacy of ivermectin against rabbit mange. *Journal of Veterinary Animal Science* 27: 145–147.
- LITTLE, S. E., W. R. DAVIDSON, P. M. RAKICH, T. L. NIXON, D. I. BOUNOUS, AND V. F. NETTLES. 1998. Responses of red foxes to first and second infection with *Sarcoptes scabiei*. *Journal of Wildlife Diseases* 34: 600–611.
- MARTIN, R., K. HANDASYDE, AND L. F. SKERRATT. 1998. Current distribution of sarcoptic mange in wombats. *Australian Veterinary Journal* 76: 411–414.
- MCILROY, J. C. 1976. Aspects of the ecology of the common wombat, *Vombatus ursinus* 1. Capture, handling, marking and radio-tracking techniques. *Australian Wildlife Research* 3: 105–116.
- MEINKING, T. L., D. TAPLIN, J. L. HERMIDA, R. PARDO, AND F. A. KERDEL. 1995. The treatment of scabies with ivermectin. *New England Journal of Medicine* 333: 26–30.
- MELLANBY, K. 1944. The development of symptoms, parasitic infection and immunity in human scabies. *Parasitology* 35: 197–206.
- PENCE, D. B., L. A. WINDBERG, B. C. PENCE, AND R. SPROWLS. 1983. The epizootiology and pathology of sarcoptic mange in coyotes *Canis latrans* from south Texas. *Journal of Parasitology* 69: 1100–1115.
- SAMUEL, W. M. 1981. Attempted experimental transfer of sarcoptic mange (*Sarcoptes scabiei*, Acarina: Sarcoptidae) among red fox, coyote, wolf and dog. *Journal of Wildlife Diseases* 17: 343–347.
- SHEAHAN, B. J., AND C. HATCH. 1975. A method for isolating large numbers of *Sarcoptes scabiei* from lesions in the ears of pigs. *Journal of Parasitology* 61: 350.
- SKERRATT, L. F. 1998. Diseases and parasites of the common wombat *Vombatus ursinus* in the Healesville area of Victoria. In *Wombats*, R. T. Wells and P. A. Pridmore (eds.). Surrey Beatty & Sons, Chipping Norton, New South Wales, Australia, pp. 317–328.
- , R. MARTIN, AND K. HANDASYDE. 1998. Sarcoptic mange in wombats. *Australian Veterinary Journal* 76: 408–410.
- , D. MIDDLETON, AND I. BEVERIDGE. 1999. Distribution of life cycle stages of *Sarcoptes scabiei* var. *wombati* and effects of severe mange on common wombats in Victoria. *Journal of Wildlife Diseases* 35: 633–646.
- SOKAL, R. R., AND F. J. ROHLF. 1997. *Biometry*, 3rd Edition. W. H. Freeman and Company, New York, New York, 887 pp.



- STONE, W. B., E. PARKS, B. L. WEBER, AND F. J. PARKS. 1972. Experimental transfer of sarcoptic mange from red foxes and wild canids to captive wildlife and domestic animals. *New York Fish and Game Journal* 19: 1–11.
- STRUMIA, M. 1963. A rapid universal blood stain, May-Gruenwald-Giemsa in one solution. *Journal of Laboratory Clinical Medicine* 21: 930.
- TRIGGS, B. 1996. The wombat. Common wombats in Australia. University of New South Wales Press, Sydney, New South Wales, Australia, 148 pp.
- VAN NESTE, D. J. J., AND J. M. LACHAPELLE. 1981. Host-parasite relationships in hyperkeratotic (Norwegian) scabies: Pathological and immunological findings. *British Journal of Dermatology* 105: 667–678.
- , AND M. J. STAQUET. 1986. Similar epidermal changes in hyperkeratotic scabies of humans and pigs. *American Journal of Dermatopathology* 8: 267–273.
- WALTON, S., J. MCBROOM, J. D. MATHEWS, D. J. KEMP, AND B. CURRIE. 1999. Crusted scabies: A molecular analysis of *Sarcoptes scabiei* variety *hominis* populations from patients with repeated infestations. *Clinical Infectious Diseases* 29: 1226–1230.

*Received for publication 28 August 2001.*