

POXVIRUS INFECTION OF STELLER SEA LIONS (*EUMETOPIAS JUBATUS*) IN ALASKA

Kathy A. Burek,^{1,6} Kimberlee Beckmen,² Tom Gelatt,³ Woody Fraser,⁴ Alexa J. Bracht,⁵ Kara A. Smolarek,⁵ and Carlos H. Romero⁵

¹ Alaska Veterinary Pathology Services, PO Box 773072 Eagle River, Alaska, 99577 USA

² Alaska Department of Fish and Game, Division of Wildlife Conservation, 1300 College Rd., Fairbanks, Alaska 99701, USA

³ Alaska Department of Fish and Game, Division of Wildlife Conservation, Marine Mammals Section, 525 W 67th Ave., Anchorage, Alaska, 99518 USA

⁴ Florida Department of Agriculture and Consumer Services, Kissimmee Diagnostic Laboratory, Kissimmee, Florida 34741, USA

⁵ Department of Pathobiology, College of Veterinary Medicine, University of Florida, 2015 SW 16th Ave., Gainesville, Florida 32610, USA

⁶ Corresponding author (email: fnkab1@uaf.edu)

ABSTRACT: Lesions suggestive of poxvirus infection were observed in two Steller sea lions (*Eumetopias jubatus*) in Alaska during live capture-and-release studies during 2000 and 2001. Both of these animals, female pups in poor body condition, were from Prince William Sound; this population is part of the declining western stock. Umbilicated, typically ulcerated dermal nodules were present, primarily on the fore flippers in one case, and over most of the body in the second case. Histologically, there were discrete masses in the superficial dermis composed of epithelial cells, some of which contained eosinophilic intracytoplasmic inclusion bodies. Negative staining of skin biopsy homogenates demonstrated the presence of orthopoxvirus-like particles. Total DNA extracted from skin biopsies were analyzed by polymerase chain reaction (PCR) using primers that targeted the DNA polymerase and DNA topoisomerase genes. These primers directed the amplification of fragments 543 base pairs (bp) and 344 bp, respectively, whose deduced amino acid sequences indicated the presence of a novel poxvirus within the Chordopoxvirinae subfamily. Comparison of these amino acid sequences with homologous sequences from members of the Chordopoxvirinae indicated highest identity with orthopoxviruses.

Key words: Chordopoxvirus, DNA polymerase, DNA topoisomerase, PCR, Steller sea lion.

INTRODUCTION

There are two genetically distinct populations of Steller sea lions (*Eumetopias jubatus*) in Alaska; the eastern and western stocks (Bickham et al., 1996), that are listed under the Endangered Species Act as threatened and endangered populations, respectively. The western stock of Steller sea lions has declined since the late 1970s, whereas the eastern stock has increased (Trites and Larkin, 1996; Loughlin, 1998). Numbers in the western population declined approximately 70% in the 1970s and 1980s but ameliorated to about 5% per year in the 1990s. The cause of the decline is undetermined; possible factors include malnutrition, disease, predation by killer whales, climate changes, exposure to toxic substances, entanglement in marine debris, and incidental and intentional mor-

talities by humans (Loughlin, 1998; Trites and Donnelly, 2003). The spatial and temporal patterns of this decline are consistent with concurrent disease, but few sea lion carcasses have been recovered. On serologic studies, there has been no evidence of exposure to disease agents known to cause significant mortality or morbidity in pinnipeds such as marine mammal morbilliviruses (Burek et al., 2003), influenza A viruses (Danner et al., 1998), *Brucella* sp. or *Leptospira interrogans* (Burek et al., 2003). By serology, a wide variety of caliciviruses (Barlough et al., 1987), an adenovirus, herpesviruses related to Phocid herpesvirus 1 and 2 (Zarnke et al., 1997), *Toxoplasma gondii* (Dubey et al., 2003) and *Chlamyphila psittaci* appear to be endemic throughout the range (Burek et al., 2003). Because these findings are based on serology, specific endemic agents have

not been adequately identified or described in relation to their distribution or effect on the sea lion population. Lesions associated with poxviruses have not been previously documented in Steller sea lions. These viruses can cause a wide variety of diseases in domestic animals that range from localized skin lesions to highly invasive systemic disease characterized by generalized skin lesions and high mortality. This paper reports two cases of poxvirus infection in two young Steller sea lions and the molecular characterization of a unique orthopox-like virus.

MATERIAL AND METHODS

The two animals with skin lesions were live captured underwater by SCUBA divers within Prince William Sound (PWS), Alaska, using a noosed pole during routine biologic and physiologic sampling. Both animals were young females; 2 and 5-mo-old. Animals were anesthetized with isoflurane (Heath et al., 1997). Body condition was assessed based on a subjective scoring system using palpation of ribs and bony processes. A 6 mm punch biopsy was taken from the skin lesions. One-half of the biopsy was placed in 10% neutral buffered formalin and the other half was frozen in dry ice and stored at -80°C . Formalin-fixed samples were embedded in paraffin, sectioned at $5\ \mu\text{m}$, and stained with hematoxylin and eosin for evaluation by light microscopy. Negative staining electron microscopy was also performed on formalin-fixed specimens. The samples were homogenized in distilled water in a Ten-Broeck grinder and clarified by centrifugation at $4,000 \times G$ for 5 min; the supernatant was removed to a clean tube and centrifuged at $12,000 \times G$ for 1 hr. The pellet was resuspended in 2% phosphotungstic acid solution at pH 6.8 containing 0.01% bovine serum albumin. A drop of this suspension was applied to a carbon-coated formvar film on a 400 mesh copper grid and excess liquid was wicked away. The grid was examined with a Zeiss EM 109 microscope (Carl Zeiss, Inc., Thornwood, New York, USA).

For polymerase chain reaction (PCR) analyses, total DNA was extracted from both biopsies using the DNAeasy tissue kit (Qiagen Inc., Valencia, California, USA). Two sets of consensus primers that target highly conserved regions within the DNA polymerase and the DNA topoisomerase genes of *Capripoxvirus* (Accession number NC_003027), *Swinepox virus* (SWPV) (Accession number NC_003389), and mule deerpox virus (unpublished sequences)

were used. Primers to amplify the DNA polymerase fragment were: forward primer DNA-pol FP 5'-CTA TTT TTA AAT CCC ATT AAA CC-3' and reverse primer DNApol RP 5'-ATA CAG AGC TAG TAC ITT AAT AAA AG-3'. These primers yield an amplification product of 543 base pairs (bp). Primers to amplify the DNA topoisomerase fragment were: forward primer DNAtopo FP 5'-TAA TGG AAA CAA GTT TTT TTA T-3' and reverse primer DNAtopo RP 5'-CCA AAA ATT ATA TAA AAA CG-3'. These primers produce an amplification product of 344 bp. Cycling conditions for the amplification of both fragments consisted of an initial denaturation step at 94°C for 1 min, followed by 40 amplification cycles, each consisting of a denaturation step at 94°C for 30 sec, an annealing step at 45°C for 30 sec, and an extension step at 72°C for 1 min. The elongation step in the last cycle was extended to 10 min. All PCR reactions were performed in $100\ \mu\text{l}$ volumes and contained 500 ng to $1\ \mu\text{g}$ of total DNA, 20 mM Tris-Cl, pH 8.4, 5 mM KCl, 100 μM for each of the four deoxynucleoside triphosphates, 200 nM for the specific forward and reverse primers, and 2 units of Taq DNA polymerase (Invitrogen Inc., Carlsbad, California, USA). Pan-parapoxvirus primers previously described for the PCR diagnosis of parapoxvirus infections in seals (Becher et al., 2002) and ungulates (Inoshima et al., 2000) were used following the published protocols. Approximately $40\ \mu\text{l}$ of the PCR reactions were resolved by gel electrophoresis in 1.2% agarose. DNA fragments for sequencing were resolved by electrophoresis in 1.2% low melting point agarose (Invitrogen), excised from the gel, and purified using the MinElute gel extraction kit (Qiagen Inc.). Fragments were sequenced using the Beckman Coulter CEQ 2000XL DNA Analysis System (Beckman Coulter, Inc., Fullerton, California, USA) following the manufacturer's protocol. Chromatograms were exported and checked for errors with the Chromas 1.45 program (Technelysium PTy Ltd., Southport, Queensland, Australia), and the nucleotide and amino acid sequences were analyzed using the Seqed, Gap, Translate, Lineup, Pileup and Pretty programs of the Wisconsin Package Version 10.0 (Genetics Computer Group [GCG], Madison, Wisconsin, USA).

RESULTS

The first case was a 2-mo-old female pup captured at The Needle haulout site ($60^{\circ}6.7'\text{N}$, $147^{\circ}36.1'\text{W}$) in August 2000. She was in poor body condition and had multiple one-half to 1 cm raised, often ul-

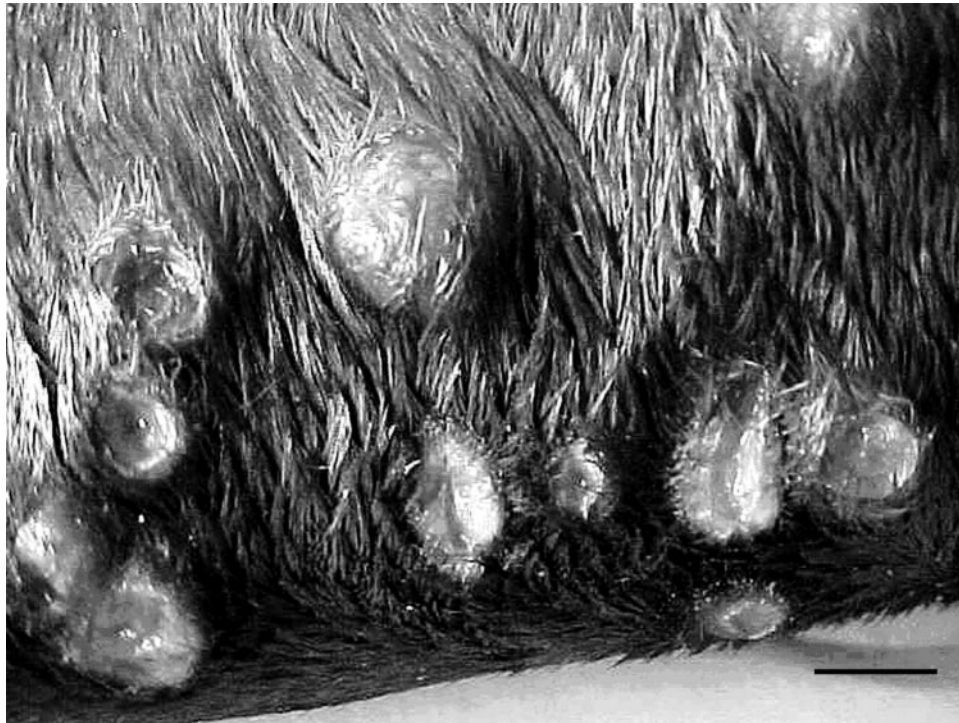

FIGURE 1. Gross appearance of pox lesions. Approximately 1 cm diameter raised smooth, hairless often umbilicated nodules were scattered across the body. Scale bar=1 cm.

cerated lesions on the fore-flippers (Fig. 1). This pup was not branded, so resight data were not available. Histologically, there were masses within the dermis composed of broad cords of large, polygonal epithelial cells. The cells had sharply delineated cytoplasmic borders, and a moderate amount of lightly basophilic cytoplasm. Nuclei were consistent in size and were round to oval with one or two prominent nucleoli/nucleus, fine granular chromatin, and 0–4 mitotic figures/high-power field. Some nuclei contained one or two clear vacuoles. Many of these epithelial cells contained a single large brightly eosinophilic inclusion body (Fig. 2). The centers of the epithelial cords were necrotic and occasionally mineralized. Scattered lymphocytes, plasma cells, and neutrophils were present in the dermis surrounding the mass. The epithelium overlying the masses was intact and did not contact the mass in sections examined.

The second case was a 5-mo-old female

pup captured at Perry Island (60°44.1'N, 147°54.1'W) in November 2001. She was in poor body condition and had raised, sometimes umbilicated, approximately 1 cm diameter nodules over a large part of her body. She was hot branded at the time of processing and was resighted 19 May, 21 May, and 11 September 2002 at the Needle and on 16 September 2002 at Perry Island. The histopathology was similar to the first case except that scattered cells contained one or two small, variably sized basophilic cytoplasmic inclusions (type B poxvirus inclusions).

Virus particles observed by electron microscopy were smooth, rounded rectangles approximately 350×270 nm, consistent with published reports of orthopoxviruses and other mammalian non-parapoxviruses (Dubochet et al., 1994) (Fig. 3).

Agarose gel electrophoresis of PCR products showed that both the DNA polymerase and DNA topoisomerase sets of primers directed the amplification of DNA

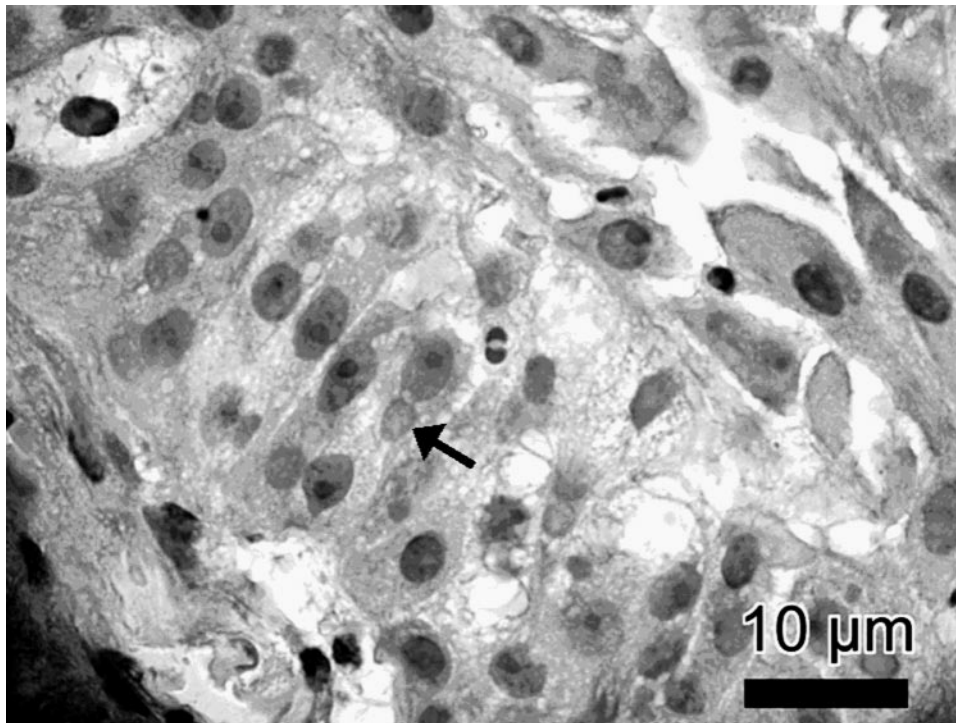


FIGURE 2. Histopathologic appearance of cutaneous lesions caused by Steller sea lion poxvirus, showing epithelial cells containing acidophilic intracytoplasmic inclusion bodies (arrow).

fragments of the expected sizes; 543 bp for the former set and 344 bp for the latter (Fig. 4).

Nucleotide sequences of the DNA polymerase fragments obtained from both biopsies were 543 bp in length and identical

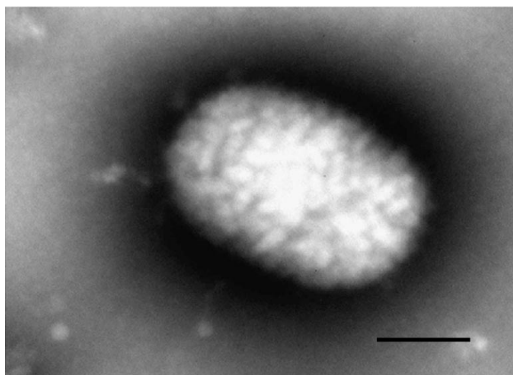


FIGURE 3. Negatively stained poxvirus particle from cutaneous lesion of Steller sea lion (SSL) observed by electron microscopy. The "skew" pattern of orthopoxviruses is evident as opposed to the "basket-weave" pattern of parapoxviruses. Scale bar=100 nm.

(GenBank accession no. AY424954) and analyses of the deduced amino acid sequence indicated that the poxvirus associated with the lesions was a unique poxvirus (Fig. 5), with closest identity to Variola virus (VARV; smallpox virus) (77%), Cowpox virus (CPXV) (77%), Monkeypox virus (MPXV) (77%), Vaccinia virus (VACV) (77%), Myxoma virus (MYXV) (76%), Camelpox virus (CMLV) (76%), Capripoxvirus (74%), and SWPV (72%). Analyses of the nucleotide sequences of both DNA topoisomerase fragments showed them to be identical and 344 bp in length (GenBank accession no. AY 424955). Comparison of the deduced amino acid sequences confirmed that the poxvirus associated with the lesions was a novel poxvirus (Fig. 6), with closest identity to VARV (70%), MPXV (69%), VACV (69%), CMLV (69%), Capripoxvirus (69%), SWPV (68%) and MYXV (65%). No DNA amplification was obtained when the pan-parapoxvirus prim-

breaks typically occur during the post-weaning period when animals are introduced into captivity; this suggests that stress may precipitate the disease. In captive gray seals, only animals with access to cement pools developed lesions, suggesting that abrasion of the epithelial surface may be required for infection or the development of lesions (Hicks and Worthy, 1987). It also has been suggested that concurrent infection with Phocine distemper virus could predispose animals to pox disease outbreaks (Osterhaus et al., 1994). Most of the poxviruses described have zoonotic potential and cases have occurred in people that were in direct contact with captive gray seals with seal pox (Hicks and Worthy, 1987).

In Steller sea lions, the potential relationship between poxvirus and declining populations needs to be understood. Potentially adverse effects may be indirectly associated with abnormalities in immune function or other health parameters. Both of the animals in this report were young and in poor condition, and originated from the declining western stock. Future work will involve attempts to culture the virus and develop serologic assays to better understand the epidemiology of this virus within these sea lion populations.

ACKNOWLEDGMENTS

The authors would like to thank Chris Terzi for collecting some of the field samples and the sea lion capture crews at the Alaska Department of Fish and Game. The Florida Fish and Wildlife Conservation Commission through the Marine Mammal Health Program of the University of Florida funded part of this work. The samples were collected under a MMPA/ESA National Marine Fisheries Service Scientific Research Permit Number 358-1564-00 issued to the Alaska Department of Fish and Game.

LITERATURE CITED

- BARLOUGH, J. E., E. S. BERRY, E. A. GOODWIN, R. F. BROWN, R. L. DELONG, AND A. W. SMITH. 1987. Antibodies to marine caliciviruses in the Steller sea lion (*Eumetopias jubatus schreber*). *Journal of Wildlife Diseases* 23: 34–44.
- BECHER, P., M. KONIG, G. MULLER, U. SIEBERT, AND H.-J. THIEL. 2002. Characterization of seal-pox virus, a separate member of the parapoxviruses. *Archives of Virology* 147: 1133–1140.
- BICKHAM, J. W., J. C. PATTON, AND T. R. LOUGHLIN. 1996. High variability for control-region sequences in a marine mammal: implications for conservation and biogeography of Steller sea lions (*Eumetopias jubatus*). *Journal of Mammalogy* 77: 95–108.
- BUREK, K. A., F. M. D. GULLAND, G. SHEFFIEDL, E. KEYES, T. R. SPRAKER, A. W. SMITH, D. E. SKILLING, J. EVERMANN, J. L. STOTT, AND A. W. TRITES. 2003. Disease agents in Steller sea lions in Alaska: A review and analysis of serology data from 1975–2000. *Fisheries Centre Research Reports*. 11(4): 27 pp.
- DANNER, G. R., M. W. MCGREGOR, R. L. ZARNKE, AND C. W. OLSEN. 1998. Serologic evidence of influenza virus infection in a ringed seal (*Phoca hispida*) from Alaska. *Marine Mammal Science* 14: 380–384.
- DUBEY, J. P., R. ZARNKE, N. J. THOMAS, S. K. WONG, W. VAN BONN, M. BRIGGS, J. W. DAVIS, R. EWING, M. MENSE, O. C. H. KWOK, S. ROMAN, AND R. THULLIEZ. 2003. *Toxoplasma gondii*, *Neospora caninum*, *Sarcocystis neurona*, and *Sarcocystis canis*-like infections in marine mammals. *Veterinary Parasitology* 116: 275–296.
- DUBOCHET, J., M. ADRIAN, K. RICHTER, J. GARCES, AND R. WITTEK. 1994. Structure of intracellular mature vaccinia virus observed by cryoelectron microscopy. *Journal of Virology* 68: 1935–1941.
- FLOM, J. O., AND E. J. HOUK. 1979. Morphologic evidence of poxvirus in “tattoo” lesions from captive bottlenose dolphins. *Journal of Wildlife Diseases* 15: 593–596.
- GENBANK, National Center for Biotechnology Information, National Library of Medicine, National Institutes of Health, www.ncbi.nlm.nih.gov/Genbank/
- GERACI, J. R., B. D. HICKS, AND D. J. ST. AUBIN. 1979. Dolphin pox: A skin disease of cetaceans. *Canadian Journal of Comparative Medicine* 43: 399–404.
- HADLOW, W. J., N. F. CHEVILLE, AND W. L. JELLISSON. 1980. Occurrence of pox in a northern fur seal on the Pribilof Islands in 1951. *Journal of Wildlife Diseases* 16: 305–312.
- HEATH, R. B., R. DELONG, V. JAMESON, D. BRADLEY, AND T. SPRAKER. 1997. Isoflurane anesthesia in free ranging sea lion pups. *Journal of Wildlife Diseases* 33: 206–210.
- HICKS, B. D., AND G. A. J. WORTHY. 1987. Sealpox in captive grey seals (*Halichoerus grypus*) and their handlers. *Journal of Wildlife Diseases* 23: 1–6.
- INOSHIMA, Y., A. MOROOKA, AND H. SENTSU. 2000. Detection and diagnosis of parapoxvirus by the polymerase chain reaction. *Journal of Virological Methods* 84: 201–208.
- KENNEDY-STOSKOPF, S. 2001. Viral diseases. *In*

- CRC Press handbook of marine mammal medicine, 2nd Edition. L. A. Dierauf and F. M. D. Gulland (eds.). CRC Press, Boca Raton, Florida, pp. 285–307.
- LOUGHLIN, T. R. 1998. The Steller sea lion: A declining species. *Biosphere Conservation* 1: 91–98.
- MULLER, G., S. GROTERS, U. SIEBERT, T. ROSENBERGER, J. DRIVER, M. KONIG, P. BECHER, U. HETZEL, AND W. BAUMGARTNER. 2003. Parapoxvirus infection in harbor seals (*Phoca vitulina*) from the German North Sea. *Veterinary Pathology* 40: 445–454.
- NETTLETON, P. F., R. MUNRO, I. POW, J. GILRAY, E. W. GRAY, AND H. W. REID. 1995. Isolation of a parapoxvirus from a grey seal (*Halichoerus grypus*). *Veterinary Record* 137: 562–564.
- OSTERHAUS, A. D. M. E., H. W. J. BROEDERS, I. K. G. VISSER, J. S. TEPPEMA, AND T. KUIKEN. 1994. Isolation of a parapoxvirus from pox-like lesions in grey seals. *Veterinary Record* 135: 601–602.
- , ———, ———, AND E. J. VEDDER. 1990. Isolation of an orthopoxvirus from pox-like lesions of a grey seal (*Halichoerus grypus*). *Veterinary Record* 127: 91–92.
- TRITES, A. W., AND C. P. DONNELLY. 2003. The decline of Steller sea lions in Alaska: a review of the nutritional stress hypothesis. *Mammal Review* 33: 3–28.
- , AND P. A. LARKIN. 1996. Changes in the abundance of Steller sea lions (*Eumetopias jubatus*) in Alaska from 1956 to 1992: How many were there? *Aquatic Mammals* 22: 153–166.
- VAN BRESSEM, M.-F., K. V. WAEREBEEK, AND J. A. RAGA. 1999. A review of virus infections of cetaceans and the potential impact of morbilliviruses, poxviruses and papillomaviruses on host population dynamics. *Diseases of Aquatic Organisms* 38: 53–65.
- WILSON, T. M., AND I. POGLAYEN-NEUWALL. 1971. Pox in South America sea lions (*Otaria byronia*). *Canadian Journal of Comparative Medicine* 35: 174–177.
- , N. F. CHEVILLE, AND L. KARSTAD. 1969. Seal pox. *Bulletin of the Wildlife Disease Association* 5: 412–418.
- , A. D. BOOTHE, AND N. F. CHEVILLE. 1972a. Sealpox field survey. *Journal of Wildlife Diseases* 8: 158–160.
- , R. W. DYKES, AND K. S. TSAI. 1972b. Pox in young, captive harbor seals. *Journal of the American Veterinary Medical Association* 161: 611–617.
- ZARNKE, R. L., T. C. HARDER, H. W. VOS, J. M. VERHOEF, AND A. D. M. E. OSTERHAUS. 1997. Serologic survey for phocid herpesvirus-1 and -2 in marine mammals from Alaska and Russia. *Journal of Wildlife Diseases* 33: 459–465.

Received for publication 15 December 2003.