

First Identification of Canine Distemper Virus in Hoary Fox (*Lycalopex vetulus*): Pathologic Aspects and Virus Phylogeny

Jane Megid,^{1,4} Carlos Roberto Teixeira,¹ Renee Laufer Amorin,¹ Adriana Cortez,² Marcos Bryan Heinemann,³ João Marcelo Azevedo de Paula Antunes,¹ Luciana Fachini da Costa,¹ Felipe Fornazari,¹ Joseane Regina Bosso Cipriano,¹ Arita Cremasco,² and Leonardo José Richtzenhain²

¹ UNESP, School of Veterinary Medicine and Animal Sciences, Botucatu-SP, Brazil; ² University of São Paulo, Department of Preventive Veterinary Medicine and Animal Health, School of Veterinary Medicine, Av. Prof. Dr. Orlando Marques Paiva, 87, CEP 05508-000, São Paulo, SP, Brazil; ³ Department of Preventive Veterinary Medicine, School of Veterinary Medicine, Universidade Federal de Minas Gerais, 9 31270-901 Belo Horizonte, MG, Brazil; ⁴ Corresponding author (email: jane@fmvz.unesp.br)

ABSTRACT: Canine distemper virus (CDV) has been reported in several wild animal species, but there have been no reports of CDV in hoary fox (*Lycalopex vetulus*). This paper characterizes the first case of natural CDV infection in hoary fox, including the clinical and pathologic aspects of the disease as well as the viral strain phylogeny.

Key words: Canine distemper virus, hoary fox, *Lycalopex vetulus*, phylogeny, RT-PCR.

Canine distemper virus (CDV) is an RNA virus belonging to the family *Paramyxoviridae*, genus *Morbillivirus*. The disease has a worldwide distribution and is considered one of the most important infectious diseases of domestic dogs (*Canis familiaris*). In many parts of the world, dogs are the likely maintenance hosts and sources of virulent pathogens for wildlife. Canine distemper originating from dogs has been reported in several wild animals (Bengston et al., 1991; Alexander and Appel, 1994; Mamaev et al., 1995; Roelke-Parker et al., 1996).

The objective of this study was to report a natural case of CDV infection in wild hoary fox (*Lycalopex vetulus*) and the virus strain phylogeny.

In April 2008, a wild hoary fox was found after being hit by a car on a road located in a rural area of Botucatu city (22°53'S, 48°26'W) in São Paulo State, Brazil. The animal was examined at the veterinary hospital and had severe dehydration, dyspnea, nasal and ocular discharge, tetraparesis, myoclonus, and diarrhea. Hematologic exam indicated lymphopenia and thrombocytopenia; in-

tracytoplasmic viral-body inclusions were observed in blood smears.

The animal was euthanized and samples from brain and lung were collected for the detection of the CDV nucleocapsid protein RNA by reverse transcription–polymerase chain reaction (PCR). Total RNA was extracted with the Illustra RNAspin Mini RNA isolation kit (GE Healthcare, Little Chalfont, Buckinghamshire, UK), according to the manufacturer's instruction. Reverse transcription–PCR was performed using the protocol described in Amaral (2007).

Amplified products with the expected molecular masses were purified using a commercial kit (Illustra GFX™ PCR DNA and Gel Band Purification Kit, GE Healthcare) and sequenced with both forward and reverse primers using the BigDye™ Terminator Kit (Applied Biosystems, Foster City, California, USA) on an automated sequencer (ABI model 377, Applied Biosystems), according to the manufacturer's instructions. The complete sequence assemblies were created with the PHRED/PHRAP (Ewing and Green, 1998) and CAP3 (Huang and Madan, 1999) programs using nucleotide data with quality higher than 20. The derived CDV sequences were aligned using BIOEDIT version 7.0.5 (Hall, 1999).

Phylogenetic analysis was performed on the aligned dataset and a rooted tree was constructed using the distance-based neighbor-joining method in the Mega version 4.0 package (Tamura et al.,

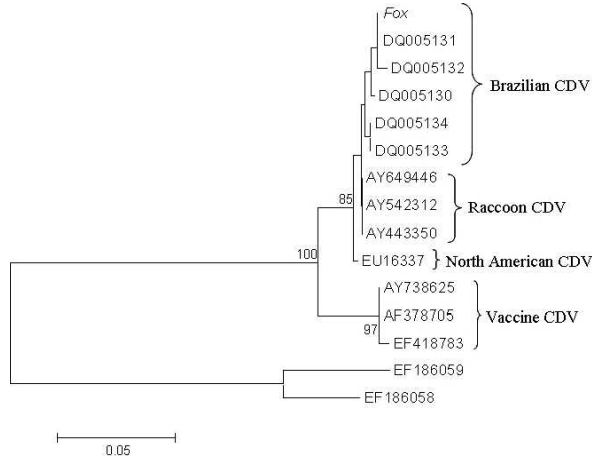


FIGURE 1. Phylogenetic trees based on 192 bp of a canine distemper virus (CDV) nucleoprotein gene fragment. A neighbor-joining tree was generated by using the MEGA program with 1,000 bootstrap replications. Brazilian CDV strains isolated from dogs (AY738653, DQ005128, DQ005132, DQ005133, DQ005134), European CDV strain isolated from dogs (AF166268, AF166269), a North American CDV strain isolated from dog (EU716337), North American CDV strains isolated from raccoons (AY443350, AY466011, AY542312), vaccine CDV strain (AY684629 [Onderstepoort], EF418783 [Lederle]), and rinderpest virus (out-group: EF186058, EF186062).

2007). The rinderpest viral sequence served as an out-group. Bootstrap values were calculated from 1,000 replicates using the heuristic method.

Accession numbers for sequences acquired from the public databases were as follows: Brazilian CDV strains isolated from dogs (AY738653, DQ005128, DQ005132, DQ005133, DQ005134), European CDV strain isolated from dogs (AF166268, AF166269), a North American CDV strain isolated from dog (EU716337), North American CDV strains isolated from raccoons (AY443350, AY466011, AY542312), vaccine CDV strain (AY684629 [Onderstepoort], EF418783 [Lederle]), and rinderpest virus (out-group: EF186058, EF186062).

Macroscopic results consisted of pneumonia and hemorrhage in the abdominal cavity near the kidneys as well as hepatic and splenic congestion. Histopathologic lesions were characterized by granulomatous meningoencephalomyelitis under the meninges. The main injuries present were multifocal spongiform lesions in the white matter of the cerebellum, which occurred with myelin loss, and degenerative lesions

in the adjacent area of the fourth ventricle, which was characterized by gliosis. Vascular congestion in the lungs, extensive cytoplasmic vacuolation in liver, as well as glomerulonephritis and inclusion bodies in the urinary bladder epithelium were also observed. Canine distemper virus was detected by PCR in brain and lung samples from the hoary fox and it was phylogenetically similar to CDV from domestic dogs (Fig. 1).

In this report, clinical signs of CDV infection in *Lycalopex vetulus* were identical to those observed in domestic dogs affected by CDV, which demonstrates the susceptibility of this species to CDV and the similarity of this clinical disease to the CDV observed in domestic dogs (Greene and Appel, 2006). Histopathologic lesions are typically multifocal and more numerous than indicated by the clinical signs during neurologic examination. There was a predilection for infection of the cerebellar peduncles, rostral medullary velum, optic tract, hippocampal fornix, and spinal cord white matter, which is most likely a result of the proximity of these tracts. The main injury observed was a spongy white

matter in the cerebellum, myelin loss, and gliosis adjacent to the fourth ventricle. These lesions in the white matter are usually evident only in chronic cases when lymphocytic inflammation is extensive, which results in considerable demyelination and/or necrosis (Summers and Appel, 1994). The advanced stages of canine distemper in this animal may have contributed to it being hit by the car.

The phylogeny of the virus suggests that domestic dogs are a source of infection to the hoary fox, similarly to the observed recent cases of CDV in *Cerdocyon thous* in this region (Megid et al, 2009), in *Lycaon pictus* in Tanzania (Van de Bildt et al., 2002), in *Panthera leo* in the Serengeti (Roelke-Parker et al., 1996), and in several other wild animal species (McCarthy et al., 2007).

This is the first report of CDV in an individual of *Lycalopex vetulus* in Brazil and the relevance and impact of CDV infection to the local population of hoary fox could be significant.

LITERATURE CITED

- ALEXANDER, K. A., AND M. J. APPEL. 1994. African wild dogs (*Lycaon pictus*) endangered by a canine distemper epizootic among domestic dogs near the Masai Mara National Reserve, Kenya. *Journal of Wildlife Disease* 30: 481–485.
- AMARAL, H. A. 2007. Detecção o vírus da cinomose pela técnica de RT-PCR em cães com sintomatologia neurológica. [Detection of canine distemper virus by RT-PCR from dogs with neurological signs]. PhD Thesis, Veterinary Medicine, Faculty of Veterinary Medicine and Zootecnia, University of São Paulo, Brazil, p. 72. www.teses.usp.br. Accessed August 2008.
- BENGSTON, J. L., P. BOVENG, U. FRANKZEN, P. HAVE, M. P. HEIDE-JORGENSE, AND R. HÄRKÖNEN. 1991. Antibodies to canine distemper virus in Antarctic seals. *Marine Mammal Science* 71: 85–88.
- EWING, B., AND P. GREENE. 1998. Basecalling of automated sequencer traces using PHRED II. *Error probabilities*. *Genome Research* 8: 186–194.
- GREENE, C. E., AND M. J. APPEL. 2006. Canine distemper. In *Infectious diseases of the dog and the cat*, C. E. Greene (ed.). W.B. Saunders Company Ltd., Philadelphia, Pennsylvania, pp. 9–22.
- HALL, T. A. 1999. BioEdit: A user-friendly biological sequence alignment editor and analysis program for Windows 95/98/NT. *Nucleic Acids Symposium Series*. 41: 95–98.
- HUANG, X., AND A. MADAN. 1999. CAP3: A DNA sequence assembly program. *Genome Research* 9: 868–877.
- MAMAEV, L. V., N. N. DENIKINA, S. I. BELIKOV, V. E. VOLCHKOV, L. K. VISSER, M. FLEMING, C. KAI, T. C. HARDER, B. LIESS, A. D. OSTERHAUS, AND T. BARRETT. 1995. Characterization of morbilliviruses isolated from Lake Baikal's seals (*Phoca sibirica*). *Veterinary Microbiology* 44: 251–259.
- MCCARTHY, A. J., M. A. SHAW, AND S. J. GOODMAN. 2007. Pathogen evolution and disease emergence in carnivores. *Proceedings of the Royal Society B: Biological Sciences* 274: 3165–3174.
- MEGID, J., V. A. F. SOUZA, C. R. TEIXEIRA, A. CORTEZ, R. L. AMORIN, M. B. HEINEMMAN, D. Q. CAGNINI, AND L. J. RICHTZENHAIN. 2009. Canine distemper virus in a crab-eating fox (*Cerdocyon thous*) in Brazil. Case report and phylogenetic analyses. *Journal of Wildlife Diseases* 45: 527–530.
- ROELKE-PARKER, M. E., L. MUNSON, C. PARCKER, R. KOCK, S. CLEAVELAND, M. CARPENTER, S. J. O'BRIEN, A. POSPISCHIL, R. HOFMANN-LEHMANN, H. LUTZ, G. L. M. MWAMENGELE, M. N. MGASA, G. A. MACHANGE, B. A. SUMMERS, AND M. J. G. APPEL. 1996. A canine distemper virus epidemic in Serengeti lions (*Panthera leo*). *Nature* 379: 441–445.
- SUMMERS, B. A., AND M. J. APPEL. 1994. Aspects of canine distemper virus and measles virus encephalomyelitis. *Neuropathology and Applied Neurobiology* 20: 525–534.
- TAMURA, K., J. DUDLEY, M. NEI, AND S. KUMAR. 2007. Mega4: Molecular Evolutionary Genetics Analysis (MEGA) software version 4.0. *Molecular Biology and Evolution* 24: 1596–1599.
- VAN DE BILD, M. W. G., T. KUIKEN, A. M. VISEE, S. LEMA, T. R. FITZJOHN, AND A. D. M. E. OSTERHAUS. 2002. Distemper outbreak and its effect on African wild dog conservation. *Emerging Infectious Diseases* 8: 211–213.

Received for publication 11 June 2008.