

# HEMATOLOGIC AND SERUM BIOCHEMICAL VALUES OF GRAVID FRESHWATER AUSTRALIAN CHELONIANS

T. Franciscus Scheelings,<sup>1,3</sup> and Anthony R. Rafferty<sup>2</sup>

<sup>1</sup> Australian Wildlife Health Centre, Healesville Sanctuary, Badger Creek Road, Healesville, Victoria, 3777, Australia

<sup>2</sup> School of Biological Sciences, Monash University, Wellington Road, Clayton, Victoria, 3800, Australia

<sup>3</sup> Corresponding author (email: fscheelings@zoo.org.au)

**ABSTRACT:** Hematologic and serum biochemical analyses were performed on 30 wild-caught, gravid, Australian freshwater chelonians. Species sampled were western long-necked turtles (*Chelodina oblonga*;  $n=13$ ), common long-necked turtles (*Chelodina longicollis*;  $n=8$ ), and Murray River turtles (*Emydura macquarii*;  $n=9$ ). Turtles were obtained from Lake Goollellal in Perth, Western Australia (*C. oblonga*), and Lake Coranderk in Healesville, Victoria (*C. longicollis* and *E. macquarii*). All turtles were considered healthy at the time of sample collection. Blood results were similar to those reported in other freshwater chelonians, with the exception of elevated calcium levels in all species. Hypercalcemia was attributed to egg development and maturation. A hemoparasite morphologically resembling *Haemogregarina clelandi* was found in all *C. oblonga* samples and in four *C. longicollis* samples. Infection with *H. clelandi* appeared to have no physiological effects on blood parameters or morphometrics of infected turtles. Blood parameters were also considered poor indicators of female chelonian morphometrics and fecundity.

**Key words:** Biochemistry, *Chelodina longicollis*, *Chelodina oblonga*, common long-necked turtle, *Emydura macquarii*, hematology, Murray River turtle, western long-necked turtle.

## INTRODUCTION

Hematologic and serum or plasma biochemical analyses are important in the clinical assessment of reptiles, although their usefulness depends on validated species-specific reference ranges. One of the challenges involved in using blood parameters to assess the health of animals is to remove sources of inherent and confounding variation potentially arising from factors relating to the individual animal. For example, individuals vary in age (or size), body condition, parasite load, sex and nutritional status, and such factors may influence hematologic and serum or plasma biochemical parameters (Harr et al., 2001; Campbell and Ellis, 2007; Hidalgo-Vila et al., 2007).

Side-necked turtles of the suborder Pleurodira comprise two families, Pelomedusidae and Cheluidae (Seddon et al., 1997). Excluding the unique pig-nosed turtle (*Carettochelys insulpta*), all Australian freshwater chelonians are members of the family Cheluidae, which is restricted to Australia, New Guinea, and South America (Seddon et al., 1997; Wilson and Swan,

2008). With the exception of Anderson et al. (1997), there are few comparative data on the hematology or biochemistry of the suborder Pleurodira. Endemic freshwater chelonians are commonly kept either as pets or display animals in zoological institutions in Australia. Gravid, freshwater chelonians are frequently presented to the Australian Wildlife Health Centre (Healesville Sanctuary, Victoria, Australia) for management of traumatic injuries and their triage is hampered by a lack of normal physiologic data.

Our aims were to obtain basic morphometric data of gravid, wild Australian freshwater chelonians, establish preliminary baseline values for hematological and serum biochemical parameters in these species, determine the prevalence of hemoparasites, and determine if blood values and hemoparasite load can be used as predictors of fecundity or morphology.

## MATERIALS AND METHODS

### Animals

Thirty, wild, gravid, freshwater Australian chelonians were captured for assessment of hematologic and biochemical values. Species

that were included in this study were western long-necked turtles (*Chelodina oblonga*;  $n=13$ ), common long-necked turtles (*Chelodina longicollis*;  $n=8$ ), and Murray River turtles (*Emydura macquarii*;  $n=9$ ). *Chelodina oblonga* were trapped at Lake Goollellal ( $31^{\circ}48'29''S$ ,  $115^{\circ}47'38''E$ ) in Perth, Western Australia, 1–7 October 2010 (spring) with the use of baited, modified funnel traps. In October 2010 the mean minimum temperature in Perth was 10.7 C and the mean maximum temperature was 24.6 C. During this time Perth experienced rainfall on five occasions with a maximum precipitation of 8.4 mm and total precipitation of 20.6 mm. No rainfall was recorded during trapping dates (Australian Government Bureau of Meteorology, 2011). Captured *C. oblonga* were housed in plastic tubs with moist towels and flown to Monash University, where they were transferred into large aquariums. All *C. oblonga* were sampled within 3 days of capture at the Australian Wildlife Health Centre.

*Chelodina longicollis* and *E. macquarii* were trapped at Lake Coranderrk ( $37^{\circ}40'56''S$   $145^{\circ}31'54''E$ ) in Healesville, Victoria, between 10 October and 15 December 2010 (spring to early summer), with the use of baited fyke nets. During this time the mean minimum temperature in Healesville was 9.2 C and the mean maximum temperature was 22.4 C. From October–December 2010, Healesville experienced rainfall on 41 occasions, with a maximum precipitation of 58.4 mm and a total precipitation of 386.2 mm (Australian Government Bureau of Meteorology, 2011). Once captured, both species were immediately transferred to the Australian Wildlife Hospital (approximately 1 km from capture site) for blood collection. Only animals considered healthy by clinical examination were included in this study.

This investigation was conducted in concert with another project investigating egg development in female chelonians and was approved by the Monash University School of Biological Sciences Ethics Committee (BSCI/2009/28). Collection of chelonians was approved with permits obtained from the Victorian Department of Sustainability and the Environment. All animals were released alive at their point of origin at the conclusion of this investigation.

#### Sample collection and processing

The sample size for this investigation was restricted to the number of gravid females that could be captured within the time constraints of the ethics and collection permits. Never-

theless, the sample size correlated with previously published literature documenting the relationship between the physiological condition of female western pond turtles in California ( $n=14$ ) and various aspects of female morphometrics (Polo-Cavia, 2010). Significant hematologic and biochemical relationships have also been detected in studies with sample sizes of as few as six individuals (Ots et al., 1998). It is therefore unlikely that significant relationships went undetected in this study.

Following capture, all animals were transported to the Australian Wildlife Health Centre so that sampling could be performed by an experienced reptile veterinarian. The presence of eggs was confirmed by radiography and chelonians were weighed, and carapace length and width measured. They were then manually restrained and 2 ml of blood was collected from the jugular vein with a 22-gauge needle attached to a 3-ml syringe. Half of the blood collected was immediately transferred into a lithium heparin container (BD Microtainer™ Tubes, Vacutainer Systems, Franklin Lakes, New Jersey, USA) and the other half into a plain container (BD Microtainer™ Tubes, Vacutainer Systems). A small volume of blood was also collected into microhematocrit tubes (Iris Sample Processing, Westwood, Massachusetts, USA). Blood in the plain tube was immediately centrifuged and the resulting serum analyzed with the use of the avian–reptilian rotor on the Vet Scan analyzer (Abaxis Inc., Union City, California, USA).

The packed cell volume (PCV) was determined with the use of standard centrifugation of the microhematocrit tubes. A leukocyte differential count was performed by examination of air-dried, whole-blood films on a microscope slide stained with Romanowsky stain (Rapid Diff, Australian Biostain Pty. Ltd., Traralgon, Victoria, Australia). Smears were made immediately after collection by dragging a droplet of blood across a glass microscope slide with a second glass slide. Leukocytes were classified as heterophils, lymphocytes, eosinophils, basophils, or monocytes. Heterophil/eosinophil counts were performed manually with a hemocytometer and an Avian Leukopet™ (Avian Leukopet™, Vetlab Supply, Palmetto Bay, Florida, USA) designed for counting eosinophils and heterophils. The total white blood cell (TWBC) count was calculated by correcting the manual count for the percentage of heterophils and eosinophils present (Dein et al., 1994).

Blood smears were also used to identify and assess the prevalence of hemoparasites within

erythrocytes by examining 1,000 erythrocytes under 1,000 $\times$  magnification and determining the percentage of infected cells. We considered this an estimate of parasite load within these species.

### Statistical analysis

Data analyses were conducted with the use of R, statistical package 2.11.0 (R Development Core Team, 2010). Data were normally distributed and linear mixed models using the "LME" function in the 'nlme' package of R were used to determine if female body morphometrics (weight, carapace length, and carapace width) and prevalence of hemoparasites were predicted by hematologic and biochemical values, and whether these values differed among females of the same species. In the mixed models, female body morphometrics and hemoparasite count acted as response variables, the hematologic and biochemical values were the fixed effects, and the female individual identification number was the random effect. Analysis of variance (ANOVA) and Tukey's honestly significant difference (HSD) tests were also conducted to identify whether there was a significant difference in hematologic and biochemical values between species. Degrees of freedom (df) and  $F$ ,  $P$ , and  $r^2$  values are included for all tests. Statistical significance was accepted if  $P \leq 0.05$ , and only  $r^2$  results that showed a strong correlation have been reported.

## RESULTS

The morphometric data, and hematologic and biochemical results for three species of gravid, freshwater, Australian chelonians are presented in Table 1. The PCV ranged from 17% to 35% in *C. oblonga*, from 16% to 26% in *C. longicollis*, and from 18% to 30% in *E. macquarii*. Erythrocyte morphology for all species was typical of that previously described in chelonians (Campbell and Ellis, 2007). Immature erythrocytes comprised <1% of the erythrocyte population. Thrombocytes had a darkly staining nucleus with a lightly staining cell membrane and colorless cytoplasm. Clumping prevented estimation of thrombocyte numbers in all three species.

The TWBC ranged from  $6 \times 10^3$  to  $16.9 \times 10^3$  cells/ $\mu$ l in *C. oblonga*, from

$6 \times 10^9$  to  $35.6 \times 10^9$  cells/l in *C. longicollis*, and from  $2.4 \times 10^3$  to  $9.5 \times 10^3$  cells/ $\mu$ l in *E. macquarii*. Leukocyte morphology was typical of that previously described in chelonians (Campbell and Ellis, 2007). The differences in TWBC observed between *C. longicollis* and *E. macquarii* was statistically significant (df=2,  $F=7.92$ ,  $P=0.002$ ). No statistically significant differences were found between the TWBC of *C. longicollis* and *C. oblonga* or *C. oblonga* and *E. macquarii*.

Percentage of heterophils was significantly greater in *C. oblonga* than *C. longicollis* (df=2,  $F=7.14$ ,  $P=0.0034$ ) but there was no significant difference detected between *E. macquarii* and *C. longicollis* or between *C. oblonga* and *E. macquarii*. Percentage of monocytes was significantly greater in *C. oblonga* than *C. longicollis* and *E. macquarii* (df=2,  $F=9.62$ ,  $P<0.001$ ) but no statistical difference was detected between *C. longicollis* and *E. macquarii*. Percentage of eosinophils was significantly greater in *C. longicollis* than in *C. oblonga* (df=2,  $F=14.31$ ,  $P<0.040$ ); however, no significant difference was detected between *E. macquarii* and *C. longicollis* or between *E. macquarii* and *C. oblonga*.

Between 0.1% and 0.9% of erythrocytes in *C. oblonga* and between 0% and 0.2% of erythrocytes in *C. longicollis* contained large ( $12 \times 5 \mu$ m) sausage-shaped inclusions that had a dark-staining nucleus at one pole (Fig. 1). These inclusions were morphologically similar to hemoparasites previously identified as *Haemogregarina clelandi* (Mackerras, 1961; Jakes et al., 2001). The presence of intraerythrocytic hemoparasites resulted in enlargement of the infected RBCs and terminal displacement of their nuclei. No hemoparasites were observed in any blood smears from *E. macquarii* and a statistically significant difference in parasite number was detected among species (df=2,  $F=14.63$ ,  $P<0.001$ ). Hemoparasite numbers were not significantly correlated with PCV, serum globulin, serum protein, or female

TABLE 1. Morphometric, hematologic and serum biochemical values for wild-caught, gravid, western long-necked turtles (*Chelodina oblonga*; n = 13), common long-necked turtles (*Chelodina longicollis*; n = 8), and Murray River turtles (*Emydura macquarii*; n = 9). *Chelodina oblonga* were captured from Lake Goollellal in Perth, Western Australia in October 2010. *Chelodina longicollis* and *E. macquarii* were captured from Lake Coranderrk in Healesville, Victoria between October and December 2010.

Analyte (units)	<i>C. oblonga</i>			<i>C. longicollis</i>			<i>E. macquarii</i>		
	Mean (SD)	Range (median)	Mean (SD)	Range (median)	Mean (SD)	Range (median)	Mean (SD)	Range (median)	
Weight (gm)	1572 (360.4)	859.3–2,135.1 (1,597.8)	814.4 (351.7)	540–1,637.9 (705.1)	2,644.4 (515.6)	1,940–3,200 (2,640)			
Carapace length (cm)	25.2 (2.1)	21.9–28.5 (24.9)	20.9 (3)	18.6–27.8 (19.9)	30.5 (3.3)	26.2–34.9 (29.1)			
Carapace width (cm)	16.9 (2.76)	14.1–24 (15.9)	17 (1.7)	15.3–20.2 (16.3)	23.6 (3.6)	18.7–27.9 (25.7)			
Eggs (n)	12.7 (2.87)	7–18 (12)	10.6 (4.6)	6–18 (9.5)	21.2 (5.2)	15–30 (25.7)			
Packed cell volume (%)	28 (6)	17–35 (30)	22 (3)	16–26 (20)	24 (4)	18–30 (24)			
Total white blood cells ( $\times 10^9/\mu\text{l}$ )	12.1 (3.76)	6–16.9 (12.7)	14.6 (9.4)	6–35.9 (12.7)	6.5 (2.1)	2.4–9.5 (6.9)			
Heterophils (%)	53.9 (13.2)	36–77 (51.5)	28.1 (15)	9–58 (25)	45.9 (17.2)	18–69 (45)			
Lymphocytes (%)	24.1 (7.9)	11–35 (23.5)	52.7 (18.4)	29–82 (51.5)	39.2 (19.4)	12–63 (49)			
Monocytes (%)	18.4 (6.6)	6–27 (19.5)	9.1 (5.8)	2–19 (8)	7.8 (5.5)	1–18 (5)			
Eosinophils (%)	3.1 (2.5)	0–7 (3)	9.1 (5.7)	4–20 (7)	6.9 (6.8)	1–24 (5)			
Basophils (%)	0.5 (0.7)	0–2 (0)	0.9 (1.4)	0–4 (0.5)	0.2 (0.4)	0–1 (0)			
Hemoparasites (n/1,000 RBC)	3.8 (2.56)	1–9 (3)	0.6 (0.7)	0–2 (0.5)	0 (0)	0 (0)			
Aspartate aminotransferase (IU/l)	461.8 (199)	212–861 (466)	69.4 (21.8)	25–91 (72.5)	97.4 (39)	54–181 (92)			
Creatinine kinase (IU/l)	2,608.6 (1,705.8)	259–5,244 (2,091)	126.9 (148.6)	17–390 (61.5)	568.7 (462.1)	100–1,360 (534)			
Uric acid (mmol/l)	67.3 (26.7)	29–124 (69)	65.6 (18.6)	39–89 (72.5)	56.6 (12.3)	42–79 (54)			
Glucose (mmol/l)	7.16 (2.9)	1.4–11.8 (7.15)	7.7 (1.6)	5–10.4 (7.8)	6.14 (1.6)	3.5–8.4 (5.9)			
Calcium (mmol/l)	4.66 (0.4)	3.95–5 (4.7)	4 (0.5)	3.3–5 (3.9)	3.4 (0.8)	2–4 (4)			
Phosphorus (mmol/l)	2 (0.5)	1.4–2.8 (2)	1.5 (0.3)	0.9–1.8 (1.5)	1.8 (0.6)	1.1–2.8 (1.6)			
Total protein (g/l)	68 (4.9)	60–76 (68)	45 (4.6)	37–53 (1.5)	35 (5.7)	25–42 (36)			
Albumin (g/l)	20 (2)	16–24 (21)	18 (1.8)	14–20 (18)	18 (3.3)	12–22 (18)			
Globulin (g/l)	48 (4.4)	41–54 (48)	27 (4.1)	23–35 (26)	15 (6.9)	0–23 (17)			
Potassium (mmol/l)	5.1 (0.9)	3.5–6.9 (4.9)	3.4 (0.5)	2.9–4.3 (3.3)	3.4 (0.4)	2.8–4.2 (3.4)			
Sodium (mmol/l)	131.5 (5.7)	126–147 (132)	130.2 (3.7)	124–136 (131)	131.1 (3)	128–135 (131)			

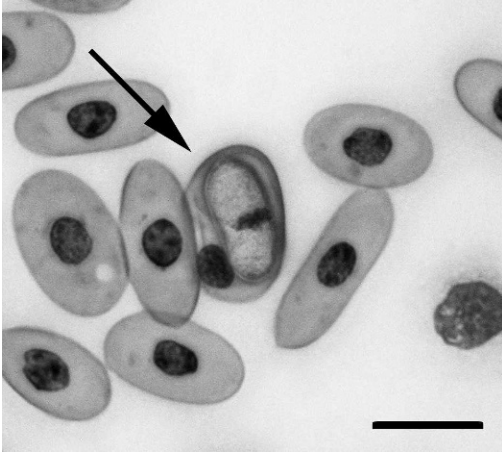


FIGURE 1. Erythrocyte from western long-necked turtle (*Chelodina oblonga*) captured from Lake Goollellal in Perth, Western Australia in October 2010, infected with hemoparasite suspected to be *Haemogregarina clelandi* (arrow). Romanowski stain. Bar=10  $\mu$ m.

morphometrics (weight, carapace length, carapace width, or fecundity) in any species examined. However, TWBC was negatively associated with parasite count in *C. oblonga* ( $df=10$ ,  $F=5.80$ ,  $P=0.0369$ ,  $r^2=0.37$ ). A significant increase in percentage of circulating eosinophils was observed in *C. longicollis* as intraerythrocytic parasite numbers increased ( $df=6$ ,  $F=11.86$ ,  $P=0.0137$ ,  $r^2=0.66$ ).

Aspartate aminotransferase (AST) was significantly greater in *C. oblonga* than in *C. longicollis* or *E. macquarii* ( $df=2$ ,  $F=28.98$ ,  $P<0.001$ ) but no significant difference existed between *C. longicollis* and *E. macquarii*. Creatinine kinase (CK) was greatest in *C. oblonga* ( $df=2$ ,  $F=13.96$ ,  $P<0.001$ ) but no difference was detected between *C. longicollis* and *E. macquarii*. Calcium ( $Ca^{2+}$ ) was also greatest in *C. oblonga* ( $df=2$ ,  $F=12.44$ ,  $P<0.001$ ) but no difference was detected between *C. longicollis* and *E. macquarii*. Total protein (TP) differed significantly between all species ( $df=2$ ,  $F=114.46$ ,  $P<0.001$ ) and was highest in *C. oblonga* and lowest in *E. macquarii*. Albumin (Alb) was significantly higher in *C. oblonga* than in *E. macquarii* ( $df=2$ ,  $F=3.92$ ,  $P=$

0.0325) but there were no differences detected between *E. macquarii* and *C. longicollis* or between *C. oblonga* and *C. longicollis*. Globulin (Glob) differed significantly among species ( $df=2$ ,  $F=103.04$ ,  $P<0.001$ ) and was highest in *C. oblonga* and lowest in *E. macquarii*. Potassium ( $K^+$ ) was significantly higher in *C. oblonga* ( $df=2$ ,  $F=19.59$ ,  $P<0.001$ ), but no differences existed between *C. longicollis* and *E. macquarii*. Bile acids could not be measured in any species with the use of the Abaxis rotor.

## DISCUSSION

For all species examined, RBC and leukocyte morphology were similar to those described in other chelonians (Campbell and Ellis, 2007; Chung et al., 2009; Chansue et al., 2011). Packed cell volume was not significantly different between *C. longicollis* and *E. macquarii* and was similar to values reported in other chelonians (Diethelm and Stein, 2006; Hidalgo-Vila et al., 2007; Innis et al., 2007; Perpiñán et al., 2008; Chung et al., 2009; Chansue et al., 2011). Greater total protein in *C. longicollis* than in *E. macquarii* is most likely due to diet. *Chelodina longicollis* is an obligate carnivore (Chessman, 1984), whereas *E. macquarii* is an omnivore with filamentous algae constituting approximately 53% of the diet (Spencer et al., 1998). The higher PCV of *C. oblonga* compared *C. longicollis* and *E. macquarii* was still within normal limits of other freshwater turtles (Rangel-Mendoza et al., 2009; Rossini et al., 2010), although TP was higher than in other species of aquatic chelonians (Anderson et al., 1997; Diethelm and Stein, 2006; Hidalgo-Vila et al., 2007; Innis et al., 2007; Perpiñán et al., 2008; Chung et al., 2009; Rangel-Mendoza et al., 2009; Rossini et al., 2010; Chansue et al., 2011). The increased erythrocyte volume and serum protein in *C. oblonga* may be normal in this species or it could possibly reflect mild dehydration at the time of sampling

due to transportation. None of the *C. oblonga* showed clinical signs of dehydration when they were initially examined, but this may be difficult to detect in some species of reptiles and thus only be apparent with biochemical analysis.

The TWBC and leukocyte differentials for all three species examined were similar to those of other freshwater chelonians (Hidalgo-Vila et al., 2007; Chung et al., 2009; Rangel-Mendoza et al., 2009; Rossini et al., 2010; Chansue et al., 2011). Variation in the leukocyte differential counts observed between species is likely to reflect species-specific variation. Leukocyte counts in reptiles may be influenced by age (or size), body condition, parasite load, sex, environmental conditions and nutrition and these need to be considered carefully when interpreting results (Harr et al., 2001; Campbell and Ellis, 2007; Hidalgo-Vila et al., 2007; Rangel-Mendoza et al., 2009).

A hemoparasite morphologically resembling *Haemogregarina clelandi* was found in all 13 blood samples from *C. oblonga* and in four blood samples from *C. longicollis*. This parasite was not seen in any blood smears from *E. macquarii*, despite these animals originating from the same water body as *C. longicollis*. *Haemogregarina clelandi* has been reported in *E. macquarii* (Mackerras, 1961), and its lack of detection may be an indication of low prevalence in this species or parasite preference for *C. longicollis* when both hosts are available. It is also possible that the use of molecular methods to detect hemoparasites may have improved detection of *H. clelandi* infection in *C. longicollis* and *E. macquarii* and contributed to definitive identification (Ujvari et al., 2004). The lifecycle of *H. clelandi* is unknown in Australian chelonians (Jakes et al., 2001).

Intraerythrocytic parasites are commonly encountered in reptiles and are often considered to be an incidental finding (Campbell, 2006). Although infection with hemoparasites may not result in overt clinical disease, it is known to exert marked physiologic costs on hosts, causing

anemia, increased circulating immature RBCs, decreased hemoglobin, decreased maximal oxygen consumption, decreased running stamina, smaller testes, less fat storage in preparation for winter dormancy, poor body condition, smaller home ranges, and social submissiveness (Schall, 1982, 1983; Schall and Dearing, 1987; Oppliger et al., 1996; Buoma et al., 2007). Parasitemia in female reptiles has been correlated with poor reproductive output (Schall, 1983; Madsen et al., 2005). Infection with hemoparasites is not always associated with poor health in free-ranging reptiles, especially when hosts are infected with low numbers of parasites (Caudell et al., 2002; Brown et al., 2006). Infection with *H. clelandi* in *C. oblonga* and *C. longicollis* did not appear to influence most blood values, morphology, or reproductive success in these species. The statistically significant decrease in TWBC in *C. oblonga* associated with increased parasite numbers was not considered biologically significant, given that the TWBC was still within reported ranges and turtles did not display signs of clinical disease. The observed eosinophilia in parasitized *C. longicollis* may be associated with hemoparasitism and stimulation of the immune system; however, some species of turtles may have up to 20% circulating eosinophils in normal animals (Campbell and Ellis, 2007). Despite the apparent lack of pathophysiological effects of hemoparasitism in the chelonians in this study, infection with *H. clelandi* must impose an energetic cost, as parasites are exploiting nutrients that could otherwise be utilized by the host (Hanssen et al., 2003; Oppliger et al., 1996). It is possible that the lack of energetic cost may be due to abundant food resources available to chelonians in this study, facilitating their ability to compensate for the energy or nutrients appropriated by *H. clelandi*. Food availability at capture sites was not assessed as part of this investigation.

Serum biochemistry values for all three species examined were similar to those

previously reported in chelonians with the exception of  $\text{Ca}^{2+}$  (Anderson et al., 1997; Diethelm and Stein, 2006; Hidalgo-Vila et al., 2007; Innis et al., 2007; Chung et al., 2009; Rangel-Mendoza et al., 2009; Rossini et al., 2010; Chansue et al., 2011). Calcium was notably higher in the chelonians in this study and is likely to reflect egg production and development (Anderson et al., 1997; Harr et al., 2001). The most notable difference in serum biochemistry analyses between species was CK, which was significantly higher in *C. oblonga* than in *C. longicollis* and *E. macquarii*. This may reflect differences in trapping method and transportation. Results of CK analysis for *C. oblonga* were also significantly higher than those reported in other chelonians (Diethelm and Stein, 2006). It is possible that *C. oblonga* may have struggled more in the funnel traps or during transportation, resulting in more muscle damage. Other observed differences in biochemistry values are likely to represent species-specific values.

We attempted to correlate blood values with female morphometric data. Although some analytes were statistically correlated to turtle size, these could not be attributed to biological traits and therefore blood parameters are unlikely to be useful predictors of body size and weight in these species examined.

This is the first baseline study of hematologic and serum biochemical values in wild-caught, gravid *C. oblonga*, *C. longicollis*, and *E. macquarii*. The differences in blood values between species highlight the need for species-specific values when assessing the health of reptiles. Infection with the hemoparasite *H. clelandi* had little physiologic consequences on its chelonian hosts. Blood values were poor predictors of morphologic data. These data provide an insight into the effects of morphology and hemoparasitism on blood parameters of Australian chelonians and the relationship between parasitism and reproductive performance in these species.

## ACKNOWLEDGMENTS

We thank the ABAXIS Company for generously donating the biochemistry rotors for this study.

## LITERATURE CITED

- ANDERSON, N. L., R. F. WACK, AND R. HATCHER. 1997. Hematology and clinical chemistry reference ranges for clinically normal, captive New Guinea snapping turtle (*Elseya novaeguineae*) and the effects of temperature, sex, and sample type. *Journal of Zoo and Wildlife Medicine* 28: 394–403.
- AUSTRALIAN GOVERNMENT BUREAU OF METEOROLOGY. 2011. [www.bom.gov.au](http://www.bom.gov.au). Accessed October 2011.
- BROWN, G. P., C. M. SHILTON, AND R. SHINE. 2006. Do parasites matter? Assessing the fitness consequences of haemogregarine infection in snakes. *Canadian Journal of Zoology* 84: 668–676.
- BUOMA, M. J., C. J. SMALLRIDGE, M. C. BULL, AND J. KOMDEUR. 2007. Susceptibility to infection by a haemogregarine parasite and the impact of infection in the Australian sleepy lizard *Tiliqua rugosa*. *Parasitological Research* 100: 949–954.
- CAMPBELL, T. W. 2006. Hemoparasites. In D. R. Mader (ed.), *Reptile medicine and surgery*. 2nd Edition. Saunders Elsevier, St. Louis, Missouri, pp. 801–805.
- , AND C. K. ELLIS. 2007. Hematology of reptiles. In T. W. Campbell and C. K. Ellis (eds.), *Avian and exotic animal hematology and cytology*. 3rd Edition. Blackwell Publishing, Ames, Iowa, pp. 3–82.
- CAUDELL, J. N., J. WHITTIER, AND M. R. CONOVER. 2002. The effects of haemogregarine-like parasites on brown tree snakes (*Boiga irregularis*) and slaty-grey snakes (*Stegonotus cucullatus*) in Queensland, Australia. *International Biodeterioration & Biodegradation* 49: 113–119.
- CHANSUE, N., A. SAILASUTA, J. TANGTRONGPIROS, S. WANGNAITHAM, AND N. ASSAWAWONGKASEM. 2011. Hematology and clinical chemistry of adult yellow-headed temple turtles (*Hieremys annandalii*) in Thailand. *Veterinary Clinical Pathology* 40: 174–184.
- CHESSMAN, B. C. 1984. Food of the snake-necked turtle, *Chelodina longicollis* (Shaw) (Testudines: Chelidae) in the Murray Valley, Victoria and New South Wales. *Australian Wildlife Research* 11: 573–578.
- CHUNG, C., C. CHENG, S. CHIN, A. LEE, AND C. CHI. 2009. Morphologic and cytochemical characteristics of Asian yellow pond turtle (*Ocadia sinensis*) blood cells and their hematologic and plasma biochemical reference values. *Journal of Zoo and Wildlife Medicine* 40: 76–85.
- DEIN, F. J., A. WILSON, D. FISCHER, AND P. LANGENBERG. 1994. Avian leucocyte counting

- using the hemocytometer. *Journal of Zoo and Wildlife Medicine* 25: 432–437.
- DIETHELM, G., AND G. STEIN. 2006. Hematologic and blood chemistry values in reptiles. In D. R. Mader (ed.). *Reptile medicine and surgery*. 2nd Edition. Saunders Elsevier, St. Louis, Missouri, pp. 1103–1118.
- HANSEN, S. A., I. FOLSTAD, K. E. ERIKSTAD, AND A. OKSANEN. 2003. Costs of parasites in Common Eiders: Effects of antiparasite treatment. *Oikos* 100: 105–111.
- HARR, K. E., A. R. ALLEMAN, P. M. DENNIS, L. K. MAXWELL, B. A. LOCK, R. A. BENNETT, AND E. R. JACOBSON. 2001. Morphologic and cytochemical characteristics of blood cells and hematologic and plasma biochemical reference ranges in green iguanas. *Journal of the American Veterinary Medical Association* 218: 915–921.
- HIDALGO-VILA, J., C. DÍAZ-PANIAGUA, N. PÉREZ-SANTIGOSA, A. PLAZA, I. CAMACHO, AND F. RECIO. 2007. Hematologic and biochemical reference intervals of free-living Mediterranean pond turtles (*Mauremys leprosa*). *Journal of Wildlife Diseases* 43: 798–801.
- INNIS, C. J., M. TLUSTY, AND D. WUNN. 2007. Hematologic and plasma biochemical analysis of juvenile head-started northern red-bellied cooters (*Pseudemys rubriventris*). *Journal of Zoo and Wildlife Medicine* 38: 425–432.
- JAKES, K. A., P. O'DONOGHUE, M. MUNRO, AND R. ADLARD. 2001. Hemoprotozoa of freshwater turtles in Queensland. *Journal of Wildlife Diseases* 37: 12–19.
- MACKERRAS, M. J. 1961. The haematozoa of Australian reptiles. *Australian Journal of Zoology* 9: 61–122.
- MADSEN, T., B. UJVARI, AND M. OLSSON. 2005. Old pythons stay fit; effects of haematozoan infections on life history traits of a large tropical predator. *Oecologia* 142: 407–412.
- OPPLIGER, A., M. L. CELERIER, AND J. CLOBERT. 1996. Physiological and behaviour changes in common lizards parasitized by haemogregarines. *Parasitology* 113: 443–438.
- OTS, I., A. MURUMÄGI, AND P. HÓRAK. 1998. Haematological health state indices of reproducing Great Tits: Methodology and sources of natural variation. *Functional Ecology* 12: 700–707.
- PERPIÑÁN, D., S. M. HERNANDEZ-DIVERS, K. S. LATIMER, T. AKRE, C. HAGEN, K. A. BUHLMANN, AND S. J. HERNANDEZ-DIVERS. 2008. Hematology of the Pascagoula map turtle (*Graptemys gibbsoni*) and the Southeast Asian box turtle (*Cuora amboinensis*). *Journal of Zoo and Wildlife Medicine* 39: 460–463.
- POLO-CAVIA, N., T. ENGSTROM, P. LÓPEZ, AND J. MARTÍN. 2010. Body condition does not predict immunocompetence of western pond turtles in altered versus natural habitats. *Animal Conservation* 13: 256–264.
- RANGEL-MENDOZA, J., M. WEBER, C. E. ZENTENO-RUIZ, M. A. LÓPEZ-LUNA, AND E. BARBA-MACÍAS. 2009. Hematology and serum biochemistry comparison in wild and captive Central American river turtles (*Dermatemys mawii*) in Tabasco, Mexico. *Research in Veterinary Science* 87: 313–318.
- ROSSINI, M., P. A. BLANCO, E. MARÍN, S. COMERMA-STEFFENSEN, AND H. ZERPA. 2010. Haematological values of post-laying Arrau turtle (*Podocnemis expansa*) in the Orinoco River, Venezuela. *Research in Veterinary Science*, November 29 (Epub ahead of print).
- SCHALL, J. J. 1982. Lizards infected with malaria: Physiological and behavioral consequences. *Science* 217: 1057–1058.
- . 1983. Lizard malaria: Cost to vertebrate host's reproductive success. *Parasitology* 87: 1–6.
- , AND M. D. DEARING. 1987. Malarial parasitism and male competition for mates in the western fence lizard, *Sceloporus occidentalis*. *Oecologia* 73: 389–392.
- SEDDON, J. M., A. GEORGES, P. R. BAVERSTOCK, AND W. McCORD. 1997. Phylogenetic relationships of chelid turtles (Pleurodira: Chelidae) based on mitochondrial 12S rRNA gene sequence variation. *Molecular Phylogenetics and Evolution* 7: 55–61.
- SPENCER, R., M. B. THOMPSON, AND I. D. HUME. 1998. The diet and digestive energetics of an Australian short-necked turtle, *Emydura macquarii*. *Comparative Biochemistry and Physiology A* 121: 341–349.
- UJVARI, B., T. MADSEN, AND M. OLSSON. 2004. High prevalence of *Hepatozoon* spp. (Apicomplexa, Hepatozoidae) infection in water pythons (*Liasis fuscus*) from tropical Australia. *Journal of Parasitology* 90: 670–672.
- WILSON, S., AND G. SWAN. 2008. Side-necked freshwater turtles family Cheluidae. In S. Wilson and G. Swan (eds.). *A complete guide to reptiles of Australia*. 2nd Edition. New Holland Publishers, Sydney, Australia, pp. 32–49.

Submitted 2 August 2011.

Accepted 20 October 2011.