

Exertional Myopathy in Pileated Woodpeckers (*Dryocopus pileatus*) Subsequent to Capture

Mark G. Ruder,¹ Brandon L. Noel,² James C. Bednarz,² and M. Kevin Keel^{1,3} ¹ Southeastern Cooperative Wildlife Disease Study, 589 D. W. Brooks Dr., College of Veterinary Medicine, University of Georgia, Athens, Georgia 30602, USA; ² Department of Biological Sciences, Graduate Program in Environmental Sciences, Arkansas State University, 2713 Pawnee, State University, Arkansas 72467, USA; ³ Corresponding author (email: mkkeel@uga.edu)

ABSTRACT: Out of 33 Pileated Woodpeckers (*Dryocopus pileatus*) captured and fitted with radio-transmitters, 12 were later found dead. Three carcasses were recovered and submitted for necropsy. One bird had large pale foci in multiple muscles. Microscopically, skeletal muscle in all three had evidence of severe coagulative necrosis, consistent with capture myopathy.

Exertional myopathy, commonly referred to as capture myopathy, is a significant risk associated with the physical restraint of wild animals. It is usually associated with the restraint of ungulates, but it has also been reported in birds (Williams and Thorne, 1996; Spraker et al., 1987; Marco et al., 2006). The following case series describes the capture, mortality, and diagnostic examination of three Pileated Woodpeckers (*Dryocopus pileatus*).

To investigate the ecology of large woodpeckers in bottomland hardwood forests, Pileated Woodpeckers were captured and fitted with radio-transmitters (Noel, 2011). Several capture techniques, including mist nets, hoop nets, and canopy nets, were used, and radio-transmitters were attached by a modified figure-eight harness or a tail-mount method (Kenward, 2001). Mean handling time was 52.6 min (SD ± 17.1 min). Radio-tracking began within 6 hr of release and was continued nearly every day as weather conditions and logistics permitted. Fieldwork was conducted February through June, 2007 to 2009, and ambient temperatures varied from approximately –3 C to 29 C. All study sites were in eastern Arkansas (34°04'N, 91°04'W) and included Cache River National Wildlife Refuge, White River National Wildlife Refuge, Wattensaw Wildlife Management

Area, and Dagmar Wildlife Management Area.

Transmitters installed in 2008 were equipped with position switches. Mortality was suspected when a position switch on the transmitter indicated no movement by the woodpecker. The transmitter was subsequently located to verify mortality and to collect any remains. Time intervals between the detection of a suspected mortality and identification of the woodpecker remains was <24 hr to several days.

A modified figure-eight harness was initially used on 22 birds. Due to the higher than expected mortality rates, the attachment method was changed to a tail-mounted technique (Kenward, 2001) in late 2008. Eleven birds were fitted with tail-mounted transmitters. After two more birds died in 2009, data collection was adjusted further to reduce handling times to <30 min.

Eleven of the 12 mortalities occurred within 12 days of capture, whereas one bird died 40 days after capture. Only three of the birds confirmed dead were in condition suitable for necropsy. They included an adult female (bird L) and an adult male (bird M) that were recovered in March 2008. Both were fitted with a figure-eight harness and died 2 days and 7 days after capture, respectively. Another adult male (bird P) died in March 2009, one day after it was fitted with a tail-mounted transmitter. All three birds were frozen and were submitted in September 2009 to the Southeastern Cooperative Wildlife Disease Study (SCWDS, Athens, Georgia) for postmortem examination.

Gross lesions consistent with capture myopathy (Williams and Thorne, 1996)

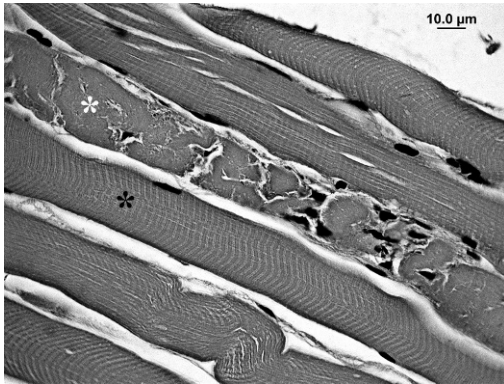


FIGURE 1. Photomicrograph of the triceps brachii muscle of a Pileated Woodpecker (*Dryocopus pileatus*; bird L), which died 2 days after handling. A necrotic myofiber (white asterisk) is adjacent to histologically normal myofibers (black asterisk). Hematoxylin and eosin stain. 1,000 \times .

were only observed in bird M. The pectoralis profundus muscles, triceps brachii muscles, and the muscles of the posterior pelvic limb all had variably well-demarcated regions that were very pale. The ventral, coelomic body wall of bird L had multiple, small puncture wounds with a small amount of hemorrhage in the adjacent soft tissues and in the coelomic cavity. These were suggestive of wounds caused by a predator, and the hemorrhage indicated the lesions occurred before death.

Histopathology confirmed coagulative necrosis of varying duration and severity in multiple skeletal muscles of all three birds. These changes were consistent with those described in previous reports of exertional myopathy (Williams and Thorne, 1996; Spraker et al., 1987). The lesions in birds L and P were acute and consisted of multifocal coagulative necrosis characterized by myofiber swelling, dissolution of microfilaments, and fragmentation of the sarcoplasm (Fig. 1). Affected muscles included the pectoralis profundus, triceps brachii, gastrocnemius, and thigh muscles. In addition to coagulative muscle necrosis, bird M had extensive myofiber loss, with replacement by moderate numbers of macrophages and

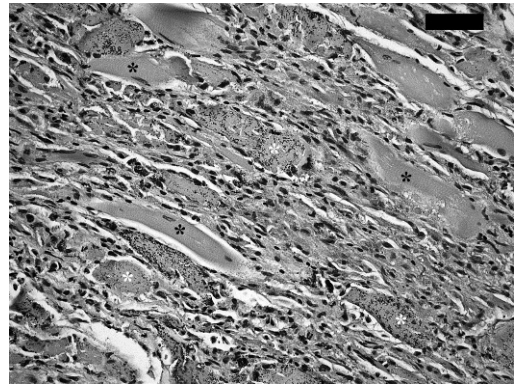


FIGURE 2. Photomicrograph of the triceps brachii muscle of a Pileated Woodpecker (bird M), which died 7 days following handling. Relatively few recognizable myofibers remain (black asterisks), and many necrotic myofibers are mineralized (white asterisks). Fibroblasts and inflammatory cells replace much of the necrotic tissue. Hematoxylin and eosin stain. 1,000 \times . Bar=50 μ m.

abundant, immature, fibrous, connective tissue. Many of the myofibers remaining in affected muscles were shrunken, hyper-eosinophilic, and had accumulations of mineral in the cytoplasm (Fig. 2). These changes were consistent with a time course approximating the interval between the capture and death of bird M (Valentine and McGavin, 2007). No lesions were observed in the heart or kidneys of any of the three birds. Attempts at virus isolation, using previously published methods, were unsuccessful for each bird (Allison and Stallknecht, 2009).

The history of capture and prolonged physical restraint, coupled with the microscopic lesions of myonecrosis in each bird, suggests that capture myopathy directly caused, or contributed to, the death of the three birds examined. Bird L had puncture wounds consistent with an attack by a predator, but severe necrosis in multiple muscle groups could have predisposed the bird to predation (Spraker et al., 1987). The lack of tissue response to the punctures, other than hemorrhage, indicates they were much more recent than the event that caused the muscle necrosis.

Postmortem examination could not be performed on the other nine woodpeckers known to have died, because only feather piles were discovered with the transmitters. However, the time from handling to death in eight of the nine birds was ≤ 12 days. The relatively brief survival time suggests capture myopathy could have also played a role in their mortality. After recognition of the problem, handling times were reduced to less than 30 min, and great care was taken to minimize physical, visual, and auditory stress. Mortality ceased after the protocols were modified. From April to June 2009, 13 additional birds were captured, and all survived the duration of the study.

The high rate of capture-associated mortality initially observed in this study (39.4%) was unacceptable and was likely the result of relatively long handling times. The importance of minimizing handling times during avian captures has been previously reported (Nicholson et al., 2000; Ponjoan et al., 2008). Our findings demonstrate that Pileated Woodpeckers, and probably other species in the family *Picidae*, are susceptible to capture myopathy. This report also serves as a reminder that every attempt should be made to prevent capture myopathy during field studies and that this disease should be a key consideration when designing such projects.

We gratefully acknowledge the support of Southeastern Cooperative Wildlife Disease Study member agencies. All animal handling procedures were approved through Arkansas State University Institutional Animal Care and Use Committee (protocol JB01-22A). Funding for fieldwork was provided by the U.S. Fish and Wildlife Service.

LITERATURE CITED

- ALLISON, A. B., AND D. E. STALLKNECHT. 2009. Genomic sequencing of Highlands J virus: A comparison to western and eastern equine encephalitis viruses. *Virus Research* 145: 334–340.
- KENWARD, R. E. 2001. Tag attachment. In *A manual for wildlife radio tagging*, R. E. Kenward. Academic Press (Harcourt Science and Technology), London, UK, pp. 123–146.
- MARCO, I., G. MENTABERRE, A. PONJOAN, G. BOTA, S. MAÑOSA, AND S. LAVÍN. 2006. Capture myopathy in Little Bustards after trapping and marking. *Journal of Wildlife Diseases* 42: 889–891.
- NICHOLSON, S. D., R. L. LOCHMILLER, M. D. STEWART, R. E. MASTERS, AND D. M. LESLIE. 2000. Risk factors associated with capture-related death in Eastern Wild Turkey hens. *Journal of Wildlife Diseases* 36: 308–315.
- NOEL, B. L. 2011. Breeding ecology of the Pileated Woodpecker (*Dryocopus pileatus*) with reference to the conservation of the Ivory-billed Woodpecker (*Campyphilus principalis*). PhD Dissertation, Arkansas State University, Jonesboro, Arkansas, 312 pp.
- PONJOAN, A., G. BOTA, E. L. GARCIA DE LA MORENA, M. B. MORALES, A. WOLFF, I. MARCO, AND S. MAÑOSA. 2008. Adverse effects of capture and handling of Little Bustards. *Journal of Wildlife Management* 72: 315–319.
- SPRAKER, T. R., W. J. ADRIAN, AND W. R. LANCE. 1987. Capture myopathy in wild turkeys (*Meleagris gallopavo*) following trapping, handling, and transportation in Colorado. *Journal of Wildlife Diseases* 23: 447–453.
- VALENTINE, B. A., AND M. D. MCGAVIN. 2007. Skeletal muscle. In *Pathologic basis of veterinary disease*, 4th Edition, M. D. McGavin and J. F. Zachary (eds.). Mosby, Inc., St. Louis, Missouri, pp. 973–1039.
- WILLIAMS, E. S., AND E. T. THORNE. 1996. Exertional myopathy (capture myopathy). In *Noninfectious diseases of wildlife*, 2nd Edition, A. Fairbrother, L. N. Locke and G. L. Hoffe (eds.). Iowa State University Press, Ames, Iowa, pp. 181–193.

Submitted for publication 17 March 2011.

Accepted 4 October 2011.