

EVIDENCE OF ACCELERATED BEAK GROWTH ASSOCIATED WITH AVIAN KERATIN DISORDER IN BLACK-CAPPED CHICKADEES (*POECILE ATRICAPILLUS*)

Caroline Van Hemert,^{1,2,3} Colleen M. Handel,¹ and Todd M. O'Hara²

¹ US Geological Survey, Alaska Science Center, 4210 University Drive, Anchorage, Alaska 99508, USA

² Department of Biology and Wildlife, Institute of Arctic Biology, University of Alaska Fairbanks, PO Box 757000, Fairbanks, Alaska 99775, USA

³ Corresponding author (email: cvanhemert@usgs.gov)

ABSTRACT: We recently documented an epizootic of beak deformities in more than 2,000 Black-capped Chickadees (*Poecile atricapillus*) and other wild bird species in North America. This emerging avian disease, which has been termed *avian keratin disorder*, results in gross overgrowth of the rhamphotheca, the outer, keratinized layer of the beak. To test the hypothesis that the beak deformities characteristic of this disorder are associated with accelerated keratin production, we measured rates of beak growth and wear in affected Black-capped Chickadees ($n=16$) and a control sample of unaffected chickadees ($n=14$) collected from south-central ($61^{\circ}09'–61^{\circ}38'N$, $149^{\circ}11'–149^{\circ}48'W$) and interior Alaska ($64^{\circ}51'–64^{\circ}53'N$, $147^{\circ}49'–147^{\circ}59'W$). Rates of absolute growth were 50–100% higher in affected birds than they were in control birds and exceeded records from other passerine species. These results suggest that abnormally rapid epidermal growth is the primary physical mechanism by which beak deformities develop and are maintained in affected chickadees. Although beak overgrowth typically worsened over time, differential patterns of wear influenced the severity and morphology of deformities. In some cases, the effects of accelerated keratin growth were partially mitigated by frequent breakage of rhamphothecal tips. However, mortalities occurred in 9 of 16 birds (56%) with beak deformities during the study, suggesting that avian keratin disorder results in severe health consequences for affected birds. Additional study of factors that control beak keratin production is needed to understand the pathogenesis of this debilitating disease in wild birds.

Key words: Avian keratin disorder, Black-capped Chickadee, beak, deformity, disease, rhamphotheca.

INTRODUCTION

Abnormalities of the rhamphotheca, the outer, cornified layer of the beak, have been documented in a wide range of species (Pomeroy, 1962; Craves, 1994) and may be associated with certain disease conditions, nutritional disorders, and exposure to environmental contaminants, although specific mechanisms are generally not well understood (Harrison, 1986; O'Hara and Rice, 1996; Tully et al., 2000; Keymer and Samour, 2008). An emerging epizootic of beak deformities among wild birds in Alaska, other regions of North America (Handel et al., 2010; Van Hemert and Handel, 2010), and, more recently, Europe (Harrison, 2011), presented the need for detailed investigation of beak growth in a passerine species. Adult Black-capped Chickadees (*Poecile atricapillus*) in Alaska exhibit high prevalence (6.5%) of

deformities and have been the subjects of ongoing research on the ecology and pathology of what we have termed *avian keratin disorder* (Handel et al., 2010). Affected birds have elongated, sometimes crossed, beaks that compromise their ability to feed and preen (Handel et al., 2010; Van Hemert and Handel, 2010). Preliminary research suggested that these abnormalities primarily affect the rhamphotheca, with no apparent defects in the underlying bone (Handel et al., 2010). In field studies of affected chickadee populations, we observed very rapid onset of beak deformities in some individuals, with rates of net growth far exceeding those reported for other passerine species (Handel et al., 2010). Increased thickness and brittleness and irregularities in surface appearance were also suggestive of abnormal epidermal growth (Handel et al., 2010). Therefore, we suspected that rapid

production of keratin was contributing to beak overgrowth, but this hypothesis had not yet been tested.

In a normal beak, patterns of growth and wear are typically well balanced, allowing the rhamphotheca to maintain a consistent length and shape that closely matches that of the underlying skeletal structure (Campàs et al., 2010). The germinative layer of the beak epidermis grows continually, producing keratinized cells that become incorporated into the rhamphotheca as they mature. This growth process is mediated by behaviors such as feeding and pecking that result in mechanical wear and subsequent sloughing of the external, cornified layers (Stettenheim, 2000). It is not known whether growth rates are typically constant over time, with variability in wear and abrasion leading to seasonal changes in beak morphology (Clancey, 1948; Davis, 1954; Morton and Morton, 1987), or if growth may fluctuate in response to hormonal, physical, or other potential stimuli. Thus, the beak overgrowth characteristic of birds affected by avian keratin disorder could be due to accelerated growth, reduced wear, or a combination of these two processes (Handel et al., 2010).

Our primary objective was to test the hypothesis that beak deformities in Black-capped Chickadees are associated with accelerated keratin production. To do so, we compared rates of absolute beak growth between affected birds and a control sample of unaffected birds. We also assessed the role that beak wear plays in the development of these deformities by calculating rates of net growth and wear in the two groups.

MATERIALS AND METHODS

Field methods

In autumn 2008, we used funnel traps and mist nets (Handel et al., 2010) to capture adult Black-capped Chickadees from south-central (61°09'–61°38'N, 149°11'–149°48'W) and interior Alaska (64°51'–64°53'N, 147°49'–147°59'W). Through a targeted trapping

effort, we captured 16 individuals (8 males, 8 females) with various forms and severity of beak deformities using the criteria established by Handel et al. (2010). We selected 14 birds (7 males, 7 females) with normal beaks as controls. We determined bird ages by plumage characteristics (Pyle, 1997) and used molecular techniques to determine sex from blood samples drawn from the brachial vein (Handel et al., 2006; Handel et al., 2010).

Captive experiment

After transport to the University of Alaska Fairbanks (UAF) Biological Research and Diagnostic Facility, birds were individually housed in 76×46×46 cm, stainless steel cages and maintained at 10 C under full-spectrum lights set to the photoperiod of Anchorage, Alaska (61°10'N, 149°59'W), adjusted weekly to match natural seasonal changes in daylight period. Diet consisted of chipped sunflower seeds, suet, mealworms (*Tenebrio molitor*), and ground hard-boiled eggs provided ad libitum in low-rimmed petri dishes. Avian Calcium for Birds (Zoo Med Laboratories, Inc., San Luis Obispo, California, USA) and Avi-Con avian multivitamin (Vet-A-Mix, Lloyd, Inc., Shenandoah, Iowa, USA) were provided according to manufacturer guidelines. All work was completed under guidance of the UAF and the US Geological Survey Alaska Science Center Institutional Animal Care and Use committees (UAF assurance 08-57).

We examined the beak and took a series of seven measurements (with digital calipers to 0.1 mm) every 14 days between 9 December 2008 and 13 April 2009. On each occasion, we lightly etched beaks with a scalpel blade (see Hulscher, 1985) at two locations (proximal, distal) on the upper beak (approximately 3 and 5 mm distal of the nares) and one location on the lower beak (approximately 3 mm distal of the juncture of the rami at the base of the gonys). We measured the chord distance from the anterior end of the right nare or the base of the gonys to the respective markings for absolute growth and to the tip of the upper (nares-to-tip) or lower beak (gonys) for net growth. We also measured the chord of the upper beak beyond where it meets the lower beak (overbite) and the chord of the lower beak beyond the upper (underbite). All measurements were taken by a single individual (C.V.H.) throughout the study. During or shortly after the pretrial quarantine period, three birds with severe beak deformities died, reducing the initial sample size of affected birds to 13 (6 males, 7 females).

Statistical analyses

Absolute growth: We calculated the daily rate of absolute beak growth during each time period by dividing the difference between previous and current measurements by number of days elapsed. We conducted a repeated-measures, mixed-model analysis of growth rates at each of the three locations, with individual identity as a random effect (PROC MIXED, SAS 9.1, SAS Institute, Inc., Cary, North Carolina, USA). We included a categorical fixed effect for disorder status (affected versus control) and linear and quadratic fixed effects for time of season (measured at 14-day intervals), along with attendant interaction terms. We reduced the initial saturated model by dropping nonsignificant terms ($P > 0.05$) in a backward-stepwise procedure and then tested the reduced model for differences in marginal means between affected and control groups. We used a paired *t*-test to determine whether absolute growth rates differed between the proximal and distal regions of the upper beak for individuals in either the control or affected groups.

Net growth and wear: For each bird, we calculated the mean daily rate of net beak growth by dividing the cumulative change in beak length (nares-to-tip and gonys) by total number of days between the bird's first and last measurements. To estimate the mean daily rates of beak wear, we subtracted total net growth from total absolute growth (sum of absolute change at the proximal upper beak or lower beak location), and divided by total number of days. We then used a *t*-test with the Satterthwaite adjustment for unequal variances to compare rates of net growth and wear between control and affected birds. Beak tips occasionally broke off in individuals with severe deformities, which introduced an intermittent, catastrophic form of wear distinct from the usual gradual, abrasion-driven wear process. To address this issue, we used a general linear model with post hoc Tukey-Kramer comparisons and tested for differences in net growth and wear among control birds, affected individuals with breakage, and affected individuals without breakage.

We were also interested in whether the amount of abrasion-related beak wear during a specific period might stimulate absolute beak growth during the subsequent period. To test that, we created a model with absolute growth rates of the upper (proximal measurement) and lower beaks as response variables and included terms from the best-fitting model from the initial repeated-measures analysis. We then added a lag term for beak wear

(upper or lower) during the previous time period, excluding those in which breakage occurred, to determine whether previous beak wear explained any significant amount of variation in absolute beak growth.

Finally, we used mean beak length of each bird to assess the relative effect of the severity of deformity on beak wear. We regressed mean rate of wear (excluding periods with breakage) against mean beak length over the course of the study, with one data point per individual. We conducted analyses in SAS Version 9.1; all probabilities are two-tailed, and data are presented as mean \pm SE.

RESULTS

Beak morphology and observations

Affected birds demonstrated a variety of beak deformity morphologies that affected the upper beak, the lower beak, or both (Fig. 1). At the time of capture, affected birds ($n = 16$) had a mean (\pm SE) nares-to-tip length of 11.6 ± 1.2 mm (range, 6.8–25.2 mm) and a gonys length of 9.2 ± 1.2 mm (range, 6.7–24.1 mm), with an overbite of 4.2 ± 1.4 mm (range, 0–16.7 mm) and an underbite of 1.4 ± 1.0 mm (range, 0–15.0 mm). Three affected birds had crossed upper and lower beaks at the time of capture, and an additional nine affected birds later developed varying degrees of lateral deviation and crossing. In all cases, the severity of the deformity remained the same or worsened over time, with net increase in the upper and lower beak of up to 3.5 and 2.7 mm per month, respectively. Breakage of the beak tips was relatively common in extremely elongated beaks, which reduced the deformity length and sometimes resulted in a more normal appearance of the beak. However, the beak typically returned to a similarly deformed state within 2–6 wk.

Control birds ($n = 14$) had a mean (\pm SE) nares-to-tip length of 7.3 ± 0.1 mm (range, 6.8–7.6 mm) and a gonys length of 6.7 ± 0.1 mm (range, 5.8–7.0 mm) at the time of capture. We observed only minor overbite (0.1 ± 0.02 mm) and no underbite. Slight changes in beak morphology (< 1.0 mm) occurred among several indi-

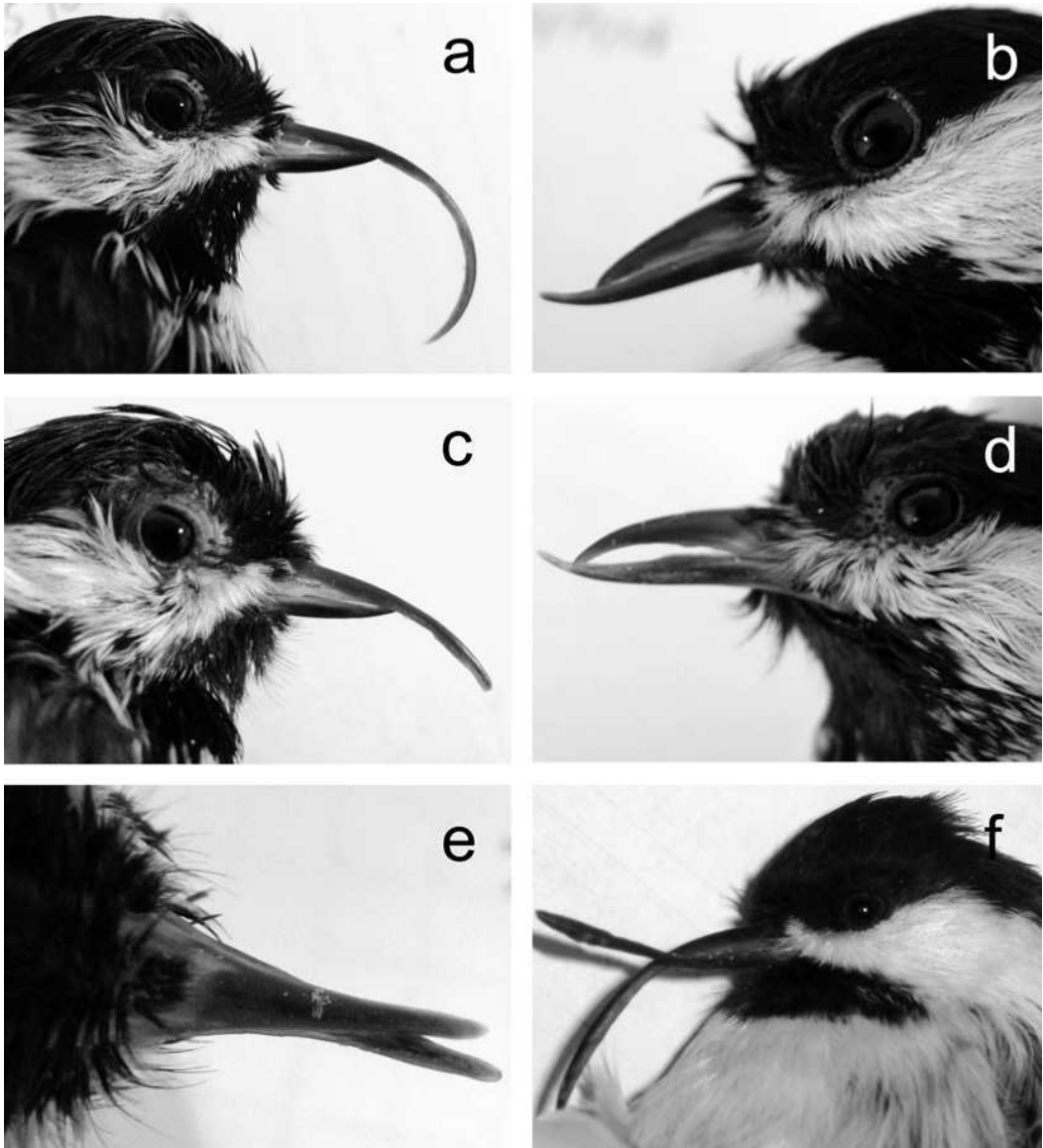


FIGURE 1. Black-capped Chickadees (*Poecile atricapillus*) affected by “avian keratin disorder” displayed various beak-deformity morphologies: (a, c) overbite, (b) underbite, (d) elongation of both upper and lower beak, and (e, f) crossing and lateral deviation, with (e) showing a ventral view.

viduals in the control group, but these changes were typically transient, and beaks regained their original shape and size within several weeks.

Nine of 16 ($56.3 \pm 12.4\%$) affected birds died during the study. Mortalities occurred between 5 and 105 days after introduction to captivity and happened most frequently among individuals with severe beak

deformities. In contrast, none of the control birds died ($\chi^2=11.2$, $df=1$, $P=0.001$). Affected birds also displayed other signs of poor health, including skin lesions, which will be described in detail elsewhere.

Beak growth

Absolute growth: The upper beak grew nearly twice as rapidly in affected birds

($n=13$) as it did in control birds ($n=14$), with marginal mean (\pm SE) absolute growth rates of 0.115 ± 0.006 mm/day versus 0.070 ± 0.002 mm/day for the proximal region ($t_{18.7}=-7.26$, $P<0.001$) and 0.120 ± 0.007 mm/day versus 0.069 ± 0.002 mm/day for the distal region ($t_{15.8}=-7.26$, $P<0.001$; Fig. 2). The rate of absolute growth of the lower beak was about 50% greater in affected birds (0.094 ± 0.004 mm/day) than it was in control birds (0.065 ± 0.001 mm/day; $t_{16.3}=-7.36$, $P<0.001$; Fig. 2). Time of season had a slight but significant effect on absolute growth rates, with different patterns for control and affected birds (Table 1 and Fig. 2).

The variable lag (wear) was not a significant predictor of absolute growth for either the upper beak ($F_{1,135}=1.77$, $P=0.186$) or lower beak ($F_{1,151}=0.02$, $P=0.886$), suggesting no relationship between the amount of beak wear and subsequent growth rate. Mean rates of absolute growth were the same for the proximal and distal regions of the upper beak for control birds ($t_{13}=0.28$, $P=0.783$) and differed only marginally for affected birds ($t_{12}=-1.94$, $P=0.076$).

Net growth and wear: For control birds, mean (\pm SE) net growth rates were equivalent to zero for both the upper beak (0.002 ± 0.001 mm/day) and lower beak (0.002 ± 0.002 mm/day). For affected birds overall, net growth rates for the upper beak (0.024 ± 0.012 mm/day) and lower beak (0.018 ± 0.009 mm/day) were higher, but statistically indistinguishable, from control birds (upper beak: $t_{13}=0.28$, $P=0.783$; lower beak: $t_{12}=-1.94$, $P=0.076$). However, net growth rates differed significantly between affected individuals with breakage and those without breakage (Fig. 3). The resulting groups (control, affected with breakage, affected without breakage) differed significantly for both the upper ($F_{2,26}=13.48$, $P<0.001$) and lower ($F_{2,26}=41.28$, $P<0.001$) beaks. Net growth rate in affected birds with breakage was approximately zero

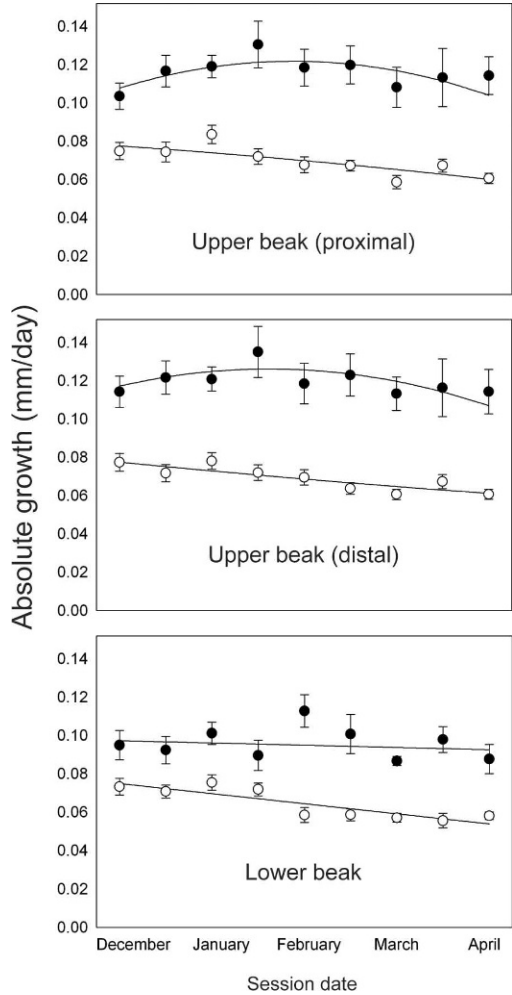


FIGURE 2. Mean (\pm SE) rates of absolute beak growth (mm/day) measured at three locations on the rhamphotheca between late winter and early spring in captive Black-capped Chickadees (*Poecile atricapillus*) affected (black circles) and unaffected (white circles) by "avian keratin disorder". Lines show best-fit regressions for each group.

for both the upper and lower beak (nares to tip, -0.002 ± 0.009 mm/day, $n=7$; gonys, 0.001 ± 0.003 mm/day, $n=9$) and did not differ from that in control birds (nares to tip, $P=0.091$; gonys, $P=0.970$). In contrast, net growth rate in affected birds without breakage was significantly higher than it was in control birds for both the upper beak (0.054 ± 0.017 mm/day; $P<0.001$, $n=6$) and the lower beak (0.058 ± 0.012 mm/day; $P<0.001$, $n=4$; Fig. 3).

TABLE 1. Results of repeated-measures, mixed-model analysis on the effect of “avian keratin disorder” status (affected versus control) and time of season (linear or quadratic) on keratin growth at three locations on the beak for Black-capped Chickadees (*Poecile atricapillus*) in captivity between December 2008 and April 2009.

Variable ^a	df	F	P
Upper beak			
Proximal			
Avian keratin disorder status	2,132	91.7	<0.001
Time of season	1,116	3.7	0.058
(Time of season) ²	1,113	5.8	0.017
Status × time	1,116	6.0	0.016
Status × (time) ²	1,113	4.5	0.036
Distal			
Avian keratin disorder status	2,129	116.5	<0.001
Time of season	1,102	1.45	0.231
(Time of season) ²	1,99.7	3.33	0.071
Status × time	1,102	4.7	0.032
Status × (time) ²	1,99.7	4.07	0.046
Lower beak			
Avian keratin disorder status			
disorder status	2,129	100.8	<0.001
Time of season	1,118	0.15	.699
Status × time	1,118	4.17	0.043

^a Variables squared represent quadratic results.

Rates of beak wear showed the same pattern, with no significant differences between controls and all affected birds combined (upper beak, $t_{13,1}=1.79$, $P=0.097$; lower beak, $t_{12,9}=1.5$, $P=0.157$). However, when affected birds were split according to the presence or absence of breakage, rates of wear differed significantly among the three groups for both the upper beak ($F_{2,26}=19.50$, $P<0.001$) and lower beak ($F_{2,26}=33.47$, $P<0.001$). Rates of wear in affected individuals with breakage (upper beak, 0.125 ± 0.014 mm/day; lower beak, 0.095 ± 0.004 mm/day) were higher than they were in those of control birds (upper beak, 0.068 ± 0.003 mm/day; lower beak, 0.063 ± 0.002 mm/day) or affected birds without breakage (upper beak, 0.054 ± 0.011 mm/day; lower beak, 0.035 ± 0.001 mm/day; all $P<0.001$). Mean rates of wear were lower for affected birds without breakage than

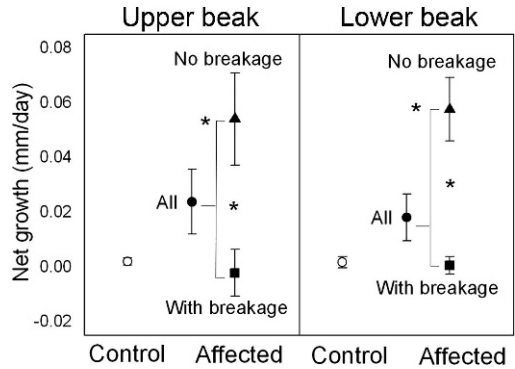


FIGURE 3. Mean (\pm SE) rate of net growth (mm/day) in length of the upper beak (left panel) and lower beak (right panel) in captive Black-capped Chickadees (*Poecile atricapillus*) affected (black symbols) and unaffected (white circles) by “avian keratin disorder.” Affected birds with no breakage of beak tips (black triangles) had significantly higher rates of net growth than did affected birds with intermittent breakage (black squares) and control birds. Rates of net growth did not differ significantly between all affected birds combined (black circles) and control birds. Net growth was calculated using straight chord from nares to the tip of the upper beak and along gonys of the lower beak.

they were for control birds, but that difference was only significant for the lower beak ($P=0.003$). The rate of abrasion-driven wear decreased as mean beak length increased for both the upper beak ($R^2_{adj}=0.873$, $F_{2,13}=5.94$, $P=0.033$) and the lower beak ($R^2_{adj}=0.885$, $F_{2,13}=12.35$, $P=0.005$).

DISCUSSION

Our findings support the hypothesis that abnormally rapid epidermal growth, and not lack of wear, is the primary means by which beak deformities develop and are maintained in Black-capped Chickadees. Rates of absolute beak growth were 50–100% faster in affected birds, relative to control birds, and exceeded records for all other passerines (Lüdicke, 1933; Wydoski, 1964; Menzel and Lüdicke, 1974; Matthysen, 1989) and some nonpasserines (Lüdicke, 1933; Menzel and Lüdicke, 1974; Hulscher, 1985). Affected chickadees also showed much greater variability in rates

and patterns of beak growth than did control birds. Our results from unaffected birds indicated that the beak epidermis normally grows at a consistent rate and at a similar speed in the upper and lower beaks, which concurs with measurements from other species (Lüdicke, 1933; Menzel and Lüdicke, 1974; Hulscher, 1985). In contrast, growth rates of affected birds varied and typically corresponded with the severity and the morphology of the deformity. We also detected a statistically marginal, but potentially biologically significant, difference between rates of growth at the proximal and distal regions of the upper beak for affected individuals, a trend that may reflect irregular rates or pulses of accelerated growth. The seasonal pattern of growth rates in affected birds differed from that for control birds, which is likely related to variability in growth rates within individuals as well as changes in the sample population during the study period because of mortalities.

We found that the effects of accelerated keratin growth may be partially mitigated by beak wear in some individuals. Fracturing of beak tips, a catastrophic and intermittent form of wear, occurred at least once in most affected birds and often resulted in significant changes in beak length. Reduction in natural beak wear via abrasion also affected the severity of deformities, but the magnitude of that effect was relatively small given the frequency of breakage. Although captive conditions do not exactly match chickadees' natural environment and rates of breakage may differ between the two settings, we have observed a similar phenomenon among free-ranging birds with beak deformities, which might help to explain the surprising persistence of some severely affected individuals in the wild (Handel et al., 2010).

In the absence of extreme, compensatory wear caused by breakage, beak length increased quickly in affected birds. Given the maximum rate of net growth observed in this study, an average beak could more

than double in length during a period of 10–12 weeks. Because deformed beaks often become curved as they increase in length, our estimate of net growth using a straight chord measurement was conservative and thus reflected only a minimum net increase. The potential for high rates of net growth corresponds with the rapid development of deformities that we have documented in some wild birds (Handel et al., 2010). Rates of abrasion-driven wear also declined with increased beak length, which presumably resulted from altered use and lack of normal apposition of the beak tips (Lumeij, 1994).

Results from control birds in this study provide insights about normal beak growth, a process that has not been well documented in the literature. Our failure to detect a relationship between amount of beak wear and absolute growth rates suggests that vascular stimulation via mechanical use does not affect beak keratin production, which is consistent with previous research (Hulscher, 1985). We also documented a slight, but significant, seasonal decrease in growth rates in control birds for both the upper and lower beak between early winter and late spring. This pattern has been observed inconsistently in other studies of absolute growth (Wydoski, 1964; Hulscher, 1985; Matthysen, 1989).

Although the population-level effects of these widespread deformities are still under investigation, the high mortality rate in captive chickadees suggests that avian keratin disorder severely compromises the health of affected birds. Black-capped Chickadees typically tolerate captive conditions well (Foote et al., 2010), and mortalities are rarely reported in other laboratory studies of this species. Mortalities occurred throughout the duration of our study, indicating that affected birds were in poor health, not only upon entering captivity from the wild but also upon the introduction of an easily accessible, ad libitum diet and removal of natural environmental stressors.

The evaluation of possible etiologies has proven challenging, but evidence of accelerated beak growth provides an important insight into this disorder. Among birds, certain viral, bacterial, and fungal infections can result in abnormal keratin growth and share some features consistent with avian keratin disorder (e.g., Tully et al., 2000; Schmidt et al., 2003; Stewart et al., 2006). However, most conditions that affect the beak result in different clinical signs from what we have observed in chickadees (Handel et al., 2010), and only limited research has been conducted on avian, hard-cornified tissues (reviewed by Van Hemert et al., 2012). Detailed histopathology and other diagnostic tests are currently underway to identify possible mechanisms and likely causative agents for this rapidly emerging avian disease.

ACKNOWLEDGMENTS

We thank L. Pajot for her help with bird captures and genetic analyses. J. Blake, C. Terzi, J. Jack, and C. Willetto provided animal care and veterinary oversight. J. Terenzi and M. Pajot offered technical and field assistance. C.V.H. received funding from a National Science Foundation Graduate Research Fellowship and an Angus Gavin Memorial Migratory Bird Research Grant. Other sources of financial support were provided by the US Geological Survey and the National Center for Research Resources (NCR), a component of the National Institutes of Health (NIH; Grant 5P20RR016466 to T.M.O.). D. O'Brien, T. Lee, S. Nash, D. Rintoul, R. Botzler, and two anonymous reviewers offered comments that improved this manuscript. The contents of this publication are solely the responsibility of the authors and do not necessarily represent the official views of NCR or NIH. Any use of trade, product, or firm names is for descriptive purposes only and does not imply endorsement by the US Government.

LITERATURE CITED

- CAMPÀS, O., R. MALLARINO, A. HERREL, A. ABZHANOV, AND M. P. BRENNER. 2010. Scaling and shear transformations capture beak shape variation in Darwin's finches. *Proceedings of the National Academy of Sciences* 107: 3356–3360.
- CLANCEY, P. A. 1948. Seasonal bill variation in Tree-Sparrow. *British Birds* 41: 115–116.
- CRAVES, J. A. 1994. Passerines with deformed bills. *North American Bird Bander* 19: 14–18.
- DAVIS, J. 1954. Seasonal changes in bill length of certain passerine birds. *Condor* 56: 142–149.
- FOOTE, J. R., D. J. MENILL, L. M. RATCLIFFE, AND S. M. SMITH. 2010. Black-capped Chickadee (*Poecile atricapillus*). In *Birds of North America* online, A. Poole (ed.). Cornell Lab of Ornithology, Ithaca, New York, <http://bna.birds.cornell.edu/bna/species/039>. Accessed March 2012.
- HANDEL, C. M., L. M. PAJOT, S. L. TALBOT, AND G. K. SAGE. 2006. Use of buccal swabs for sampling DNA from nestling and adult birds. *Wildlife Society Bulletin* 34: 1094–1100.
- , ———, S. M. MATSUOKA, C. VAN HEMERT, J. TEREZI, S. L. TALBOT, D. M. MULCAHY, C. U. METEYER, AND K. A. TRUST. 2010. Epizootic of beak deformities among wild birds in Alaska: An emerging disease in North America? *Auk* 127: 882–898.
- HARRISON, G. J. 1986. Disorders of the integument. In *Clinical avian medicine and surgery*, G. J. Harrison and L. R. Harrison (eds.). W. B. Saunders Co., Philadelphia, Pennsylvania, pp. 397–407.
- HARRISON, T. 2011. Beak deformities of garden birds. *British Birds* 104: 138–141.
- HULSCHER, J. B. 1985. Growth and abrasion of the oystercatcher bill in relation to dietary switches. *Netherlands Journal of Zoology* 35: 124–154.
- KEYMER, I. F., AND J. SAMOUR. 2008. Disorders of the digestive system. In *Avian medicine*, J. Samour (ed.). Elsevier, New York, New York, pp. 281–302.
- LÜDICKE, M. 1933. Wachstum und abnutzung des vogelschnabels. *Zoologische Jahrbücher, Abteilung für Anatomie und Ontogenie der Tiere* 57: 435–564.
- LUMEIJ, J. T. 1994. Gastro-enterology. In *Avian medicine: Principles and application*, B. W. Ritchie, G. J. Harrison and L. R. Harrison (eds.). Wingers Publishing, Inc., Lake Worth, Florida, pp. 522–537.
- MATTHYSEN, E. 1989. Seasonal variation in bill morphology of Nuthatches *Sitta europaea*: Dietary adaptations or consequences? *Ardea* 77: 117–125.
- MENZEL, R., AND M. LÜDICKE. 1974. Funktionell-anatomische und autoradiographische Untersuchungen am Schnabelhorn von Papageien (Psittaci). *Zoologische Jahrbücher, Abteilung für Anatomie und Ontogenie der Tiere* 93: 175–218.
- MORTON, M. L., AND G. A. MORTON. 1987. Seasonal changes in bill length in summering mountain White-Crowned Sparrows. *Condor* 89: 197–200.
- O'HARA, T. M., AND C. D. RICE. 1996. Polychlorinated biphenyls. In *Noninfectious diseases of wildlife*, A. Fairbrother, L. N. Locke and G. L. Hoff (eds.). Iowa State University Press, Ames, Iowa, pp. 71–86.

- POMEROY, D. E. 1962. Birds with abnormal bills. *British Birds* 56: 49–72.
- PYLE, P. 1997. Identification guide to North American birds: A compendium of information on identifying, ageing, and sexing ‘near-passerines’ and passerines in the hand. Slate Creek Press, Bolinas, California, 278 pp.
- SCHMIDT, R. E., D. R. REAVILL, AND D. N. PHALEN. 2003. Pathology of pet and aviary birds. 1st Edition. Iowa State Press, Ames, Iowa, 234 pp.
- STETTENHEIM, P. R. 2000. The integumentary morphology of modern birds—An overview. *American Zoologist* 40: 461–477.
- STEWART, M. E., R. PERRY, AND S. R. RAIDAL. 2006. Identification of a novel circovirus in Australian Ravens (*Corvus coronoides*) with feather disease. *Avian Pathology* 35: 86–92.
- TULLY, T. N. JR, M. P. C. LAWTON, AND G. M. DORRESTEIN (eds.) 2000. Handbook of avian medicine. 2nd Edition. Butterworth-Heinemann, Elsevier Science Ltd., New York, New York, 411 pp.
- VAN HEMERT, C., AND C. M. HANDEL. 2010. Beak deformities in Northwestern Crows: Evidence of a multispecies epizootic. *Auk* 127: 746–751.
- , ———, J. E. BLAKE, R. M. SWOR, AND T. M. O’HARA. 2012. Microanatomy of passerine hard-cornified tissues: Beak and claw structure of the Black-capped Chickadee (*Poecile atricapillus*). *Journal of Morphology* 273: 226–240.
- WYDOSKI, R. S. 1964. Seasonal changes in the color of Starling bills. *Auk* 81: 542–550.

Submitted for publication 17 November 2011.

Accepted 1 January 2012.