

Case Report

Skeletal Anchorage for Orthodontic Correction of Severe Maxillary Protrusion after Previous Orthodontic Treatment

Eiji Tanaka^a; Akiko Nishi-Sasaki^b; Takuro Hasegawa^c; Clarice Nishio^d; Nobuhiko Kawai^e; Kazuo Tanne^f

Abstract: The correction of a severe maxillary protrusion in an adult by distal movement of the maxillary molars has been one of the most difficult biomechanical problems in orthodontics. This article reports on the treatment of an adult case of severe maxillary protrusion and a large overjet treated with a skeletal anchorage system. A female patient, age 22 years and 3 months, complained of the difficulty of lip closure due to severe maxillary protrusion with a gummy smile. Overjet and overbite were +7.6 mm and -0.9 mm, respectively. She had a history of orthodontic treatment in which her maxillary first premolars were extracted. In order to conduct distal movement of the maxillary molars, anchor plates were placed in the zygomatic process. After achieving a Class I molar relationship, retraction and intrusion of the maxillary incisors were performed. After a 2-year treatment, an acceptable occlusion was achieved with a Class I molar relationship. Her convex facial profile with upper lip protrusion was considerably improved, and the lips showed less tension in lip closure. After a 2-year retention period, an acceptable occlusion was maintained without recurrence of maxillary protrusion, indicating a stability of the occlusion. The result of this treatment indicated that skeletal anchorage is of great importance as a remedy for achieving intrusion and retraction of the maxillary incisors in cases of severe maxillary protrusion with a patient who had previous orthodontic treatment.

Key Words: Skeletal anchorage; Severe maxillary protrusion; Previous experience of orthodontic treatment; Distal movement of maxillary molars

INTRODUCTION

According to Newton's third law, every action has an equal and opposite reaction. Thus, orthodontists

have always been faced with difficulties trying to achieve maximal anchorage and complete distal molar movement, especially in adult cases. A loss of the stability of the anchoring teeth often leads to unexpected outcomes. The time necessary for correcting dental anchorage losses during orthodontic treatment is at least equal to that of the primary treatment.¹

Previously, a two-stage method was commonly used to move maxillary molars to the distal with various appliances such as head gear, repelling magnets, Wilson rapid molar distalizer, distal jet, a Jones jig, and a pendulum appliance.²⁻⁶ The amount of the maxillary first molar distal movement ranges from 2 mm to 6 mm. As pointed out by Sugawara et al,⁷ however, most of these studies were conducted at the first stage for

^a Associate Professor, Department of Orthodontics and Craniofacial Developmental Biology, Hiroshima University Graduate School of Biomedical Sciences, Hiroshima, Japan.

^b Research Assistant, Department of Orthodontics and Craniofacial Developmental Biology, Hiroshima University Graduate School of Biomedical Sciences, Hiroshima, Japan.

^c Graduate student (PhD), Department of Orthodontics and Craniofacial Developmental Biology, Hiroshima University Graduate School of Biomedical Sciences, Hiroshima, Japan.

^d Research Fellow, Department of Orthodontics and Craniofacial Developmental Biology, Hiroshima University Graduate School of Biomedical Sciences, Hiroshima, Japan.

^e Resident, Department of Orthodontics and Craniofacial Developmental Biology, Hiroshima University Graduate School of Biomedical Sciences, Hiroshima, Japan.

^f Professor and Department Chair, Department of Orthodontics and Craniofacial Developmental Biology, Hiroshima University Graduate School of Biomedical Sciences, Hiroshima, Japan.

Corresponding author: Dr E Tanaka, Department of Orthodontics and Craniofacial Developmental Biology, Hiroshima Uni-

versity Graduate School of Biomedical Sciences, 1-2-3 Kasumi, Minami-ku, Hiroshima 734-8553, Japan
(e-mail: etanaka@hiroshima-u.ac.jp)

Accepted: February 2007. Submitted: January 2007.

© 2008 by The EH Angle Education and Research Foundation, Inc.

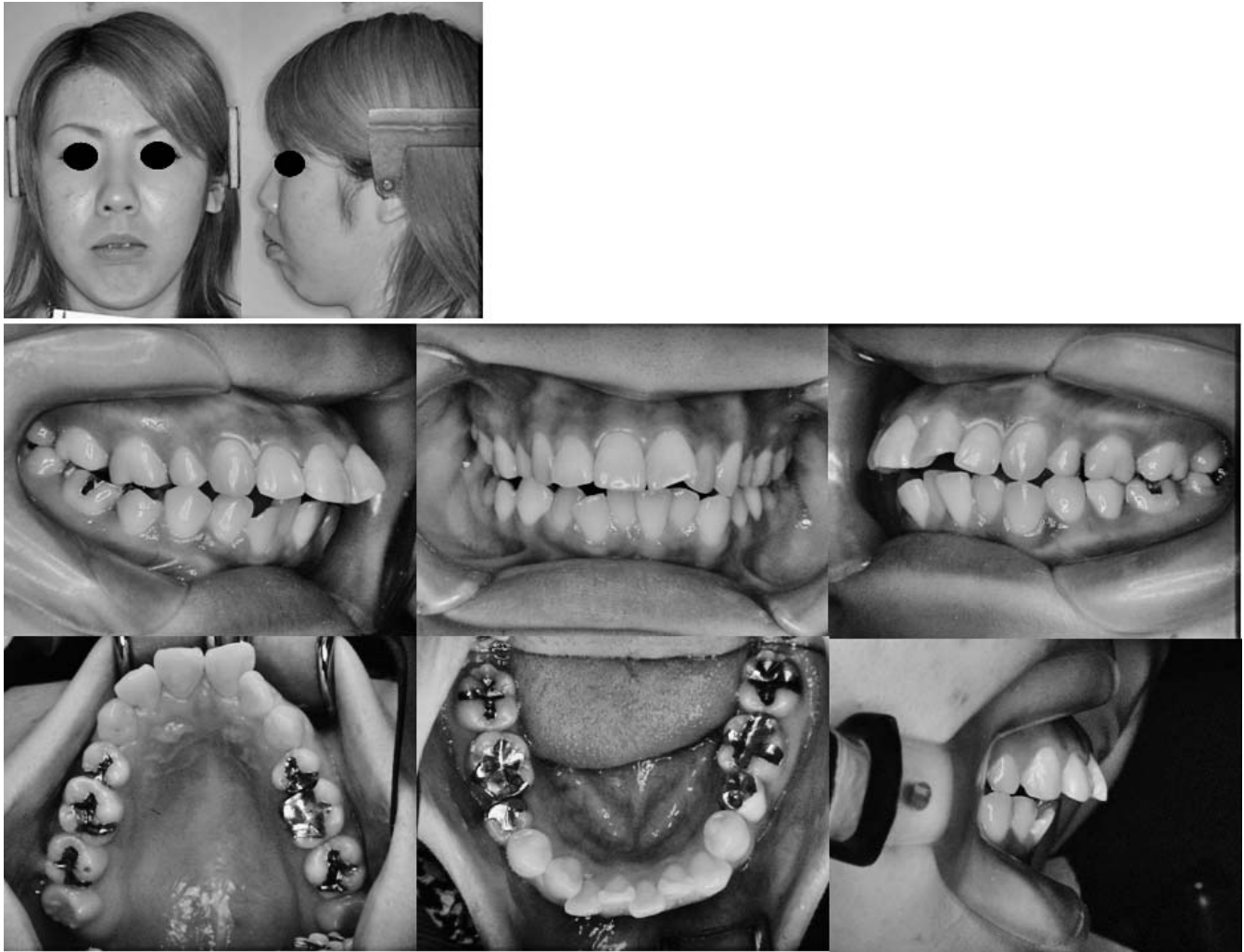


Figure 1. Facial and intraoral photographs before treatment (age 22 years 3 months).

adolescent patients, and they hardly evaluated the final amount of molar distal movement after retraction of the premolars and the anterior teeth. That is, it might be difficult to maintain the amount of distal molar movement obtained at the first stage until the end of the second stage.

In the correction of severe maxillary protrusion with a large overjet, it is of great importance to achieve maximal anchorage. Especially in cases with excessive molar anchorage loss and relapse, distal movement of the maxillary molars is not only a crucial, but also a difficult task. Recently, a skeletal anchorage system (SAS) was developed for correcting Class II malocclusions characterized by maxillary anterior crowding and large overjet. With the use of this system, the distal movements of the maxillary molars without unfavorable side effects became possible, and a significant amount of distal movement of the maxillary molars, such as 3.78 mm on average, has been reported previously.⁷

The purpose of this article is to present a case of an adult patient with severe maxillary protrusion and a large overjet and previous orthodontic treatment who was treated with a SAS.

Case Report

The patient was a 22-year 3-month-old woman who presented a maxillary protrusion with a Class II molar relationship (Figure 1). She complained about the difficulty of lip closure due to severe maxillary protrusion with a gummy smile. Her facial profile was convex with a protrusive upper lip and no facial asymmetry (Figure 1). Overjet and overbite were +7.6 mm and -0.9 mm, respectively. Occlusal contacts were recognized only at the premolar and molar regions at maximum intercuspation. Occlusal contacts were present only at the molar region at the protrusive mandibular position, which implied a horizontal openbite. When she was a student in elementary school, she submitted to an or-

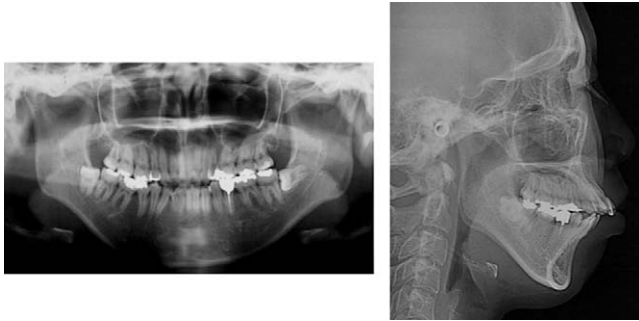


Figure 2. Panoramic radiograph and lateral cephalogram before treatment (age 22 years 3 months).

thodontic treatment with a multibracket appliance in which her maxillary first premolars were extracted.

The model analysis showed an arch length discrepancy of -14.5 mm on the upper and -4.5 mm on the lower arch. The panoramic radiograph showed mesial tipping of the upper and lower molars (Figure 2). The mandibular second premolars had received restorative treatment and the left one had been under endodontic treatment.

Cephalometric analysis indicated a tendency toward a skeletal Class II malocclusion (Figures 2 and 3). The mandibular plane and gonial angles were larger than those of the Japanese average control group.⁸ The mandible exhibited a backward and downward rotation and, consequently, the lower anterior facial height was larger than normal. The maxillary and mandibular incisors were tipped more labially.

From these findings, this patient's diagnosis was maxillary protrusion with a mandibular retrusion, and a large overjet. The treatment plan for this patient was:

- Placement of anchor plates in the zygomatic process as an absolute anchorage.
- Extraction of the maxillary third molars and the mandibular second premolars. The bilateral lower second premolars were chosen to be extracted because they were in poorer condition than the first premolars.
- Placements of a transpalatal arch on the upper and a lingual arch on the lower arch to avoid the buccal flare-out and mesial movement of the upper and lower molars, respectively.
- Distal movement of the maxillary second and first molars.
- Retraction and intrusion of the maxillary incisors by use of a multi-bracket appliance.
- Retention using lingual bonded retainers in both dentitions.

Treatment Progress

Y-shaped anchor plates (Orthoanchor SMAP, Dentsply-Sankin, Tokyo, Japan) were implanted onto the zygomatic process of the maxilla through the buccal mucosa under local anesthesia (Figure 4). The plates were contoured to fit the bone surface. The head portion was intraorally exposed and positioned outside the dentition. After a month for healing, integration, and adaptation, a

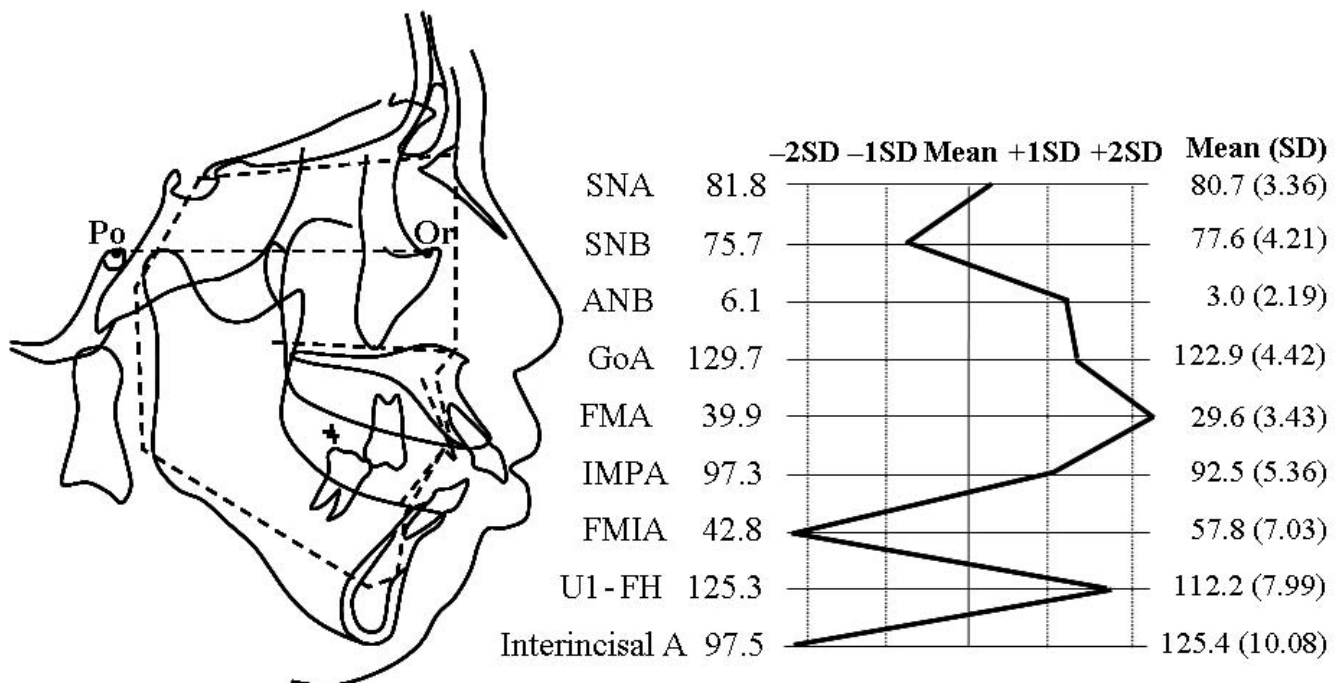


Figure 3. Cephalometric tracing before treatment (solid line). Dotted lines indicate a mean profilogram of Japanese adult female.

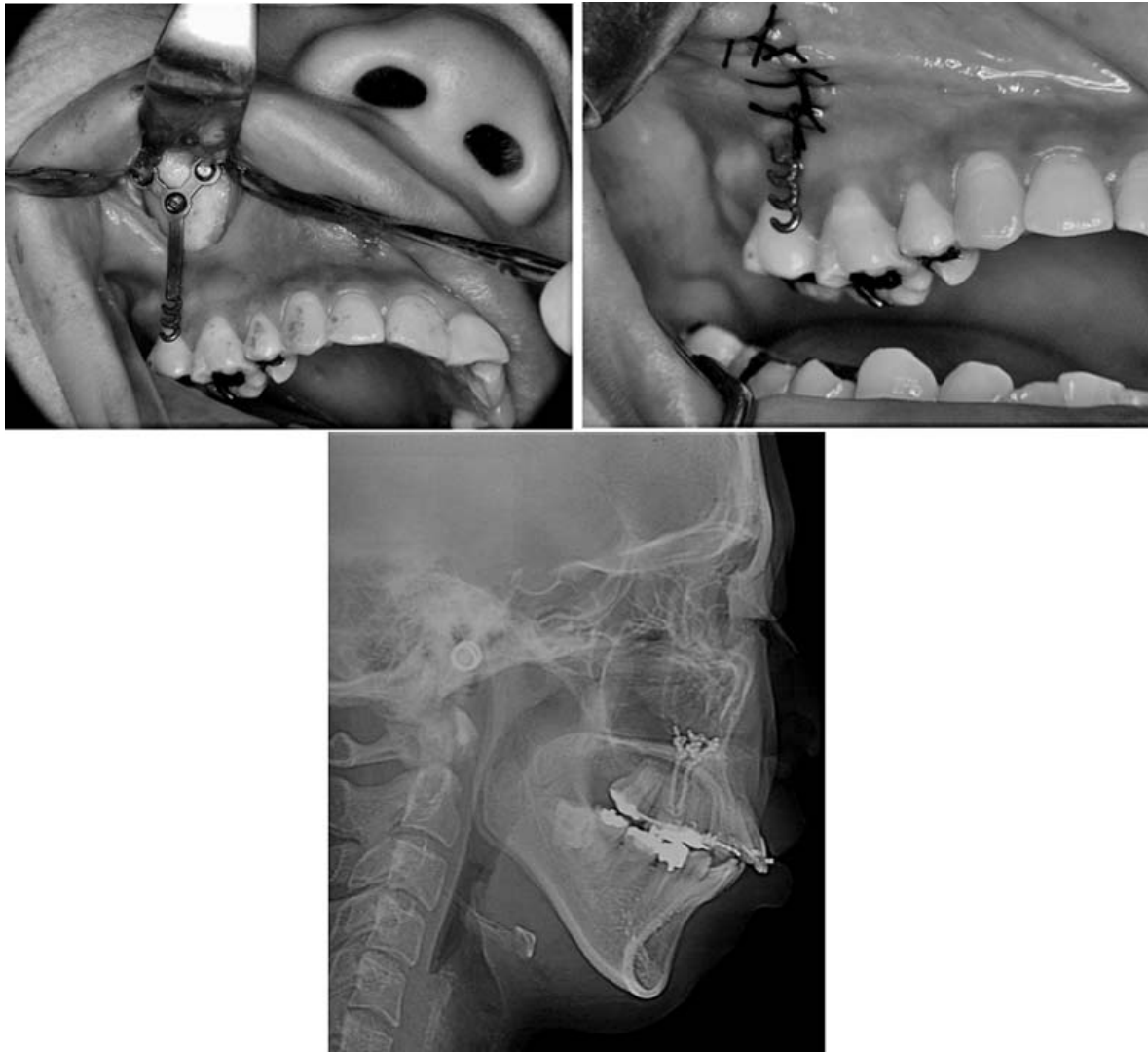


Figure 4. Placement of anchorage plates.

0.018 × 0.025 inch slot multi-bracket appliance was placed on the maxillary dentitions.

After the leveling of the posterior teeth, stiff segmental 0.016 × 0.022 inch wires were applied on the both canine-to-molar regions, and an open-coil spring was placed between the first and second molars to move the second molars distally. A 0.016-inch NiTi wire was overlaid for leveling of the anterior teeth (Figure 5a). During distal movement, an elastic chain was applied from the hook of the anchor plate to the upper canine to prevent the flaring the anterior teeth. After distal movement of the maxillary second molars, a plain stainless steel 0.016 × 0.022 inch wire was placed and en masse distal molar movement with sliding mechanics was performed (Figure 5b).

In the lower arch a lingual arch and a multibracket appliance were placed 7 months after initiating treatment of the upper arch. The initial arch was a 0.016

× 0.016 inch wire, and the retraction of the first premolars and the mesial movements of molars were started simultaneously with labial elastics. At 11 months after initiating treatment, incisal intrusion was performed using a utility arch in both arches (Figure 5c). After en masse distal movement, a transpalatal arch was placed on the upper arch to maintain the position of the molars (Figure 5d). After 2 years of orthodontic treatment, a well-balanced face and an acceptable occlusion were achieved, and the multibracket appliances were removed. Immediately after removal, lingual bonded retainers were placed on both dentitions. In addition, labial bonded wires were applied from the lower first premolar to the first molar.

Treatment Results

Facial photographs showed that overall facial balance was improved (Figure 6). Although the lower an-

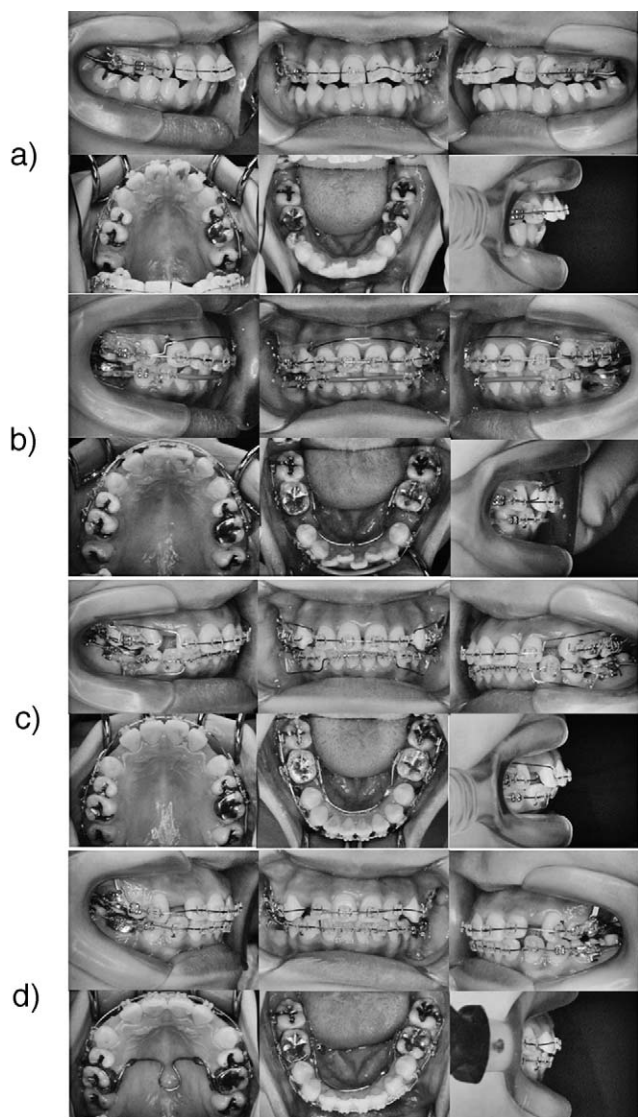


Figure 5. Intraoral photographs during treatment. (a) 3 months; (b) 7 months; (c) 11 months; (d) 18 months.

terior facial height was not changed, the lips showed less tension on closure. Acceptable occlusion was achieved and the overbite was improved to 1.2 mm and the overjet to 1.0 mm (Figure 6). The molar relationships were changed to Class I on the both sides. Cephalometric analysis indicated a slight clockwise rotation of the mandible (Figure 7). The inclinations of the upper and lower central incisors were improved within the normal range. The upper incisors were intruded 2.2 mm at the root apex. There was a slight apical root resorption observed in the upper and lower anterior teeth. From the superimposition of the maxilla, the average amount of distal movement of the upper first molars was 7.2 mm at the crown and 5.3 mm at the root level (Figure 7).

Two years after retention, an acceptable occlusion

was maintained without recurrence of the maxillary protrusion, indicating a stability of the occlusion (Figure 8).

DISCUSSION

The use of the implant anchor plate for absolute anchorage has proved to have many attractive features and advantages.⁹ First, is the ability to provide treatment possibilities and alternatives that were not previously feasible. Second, absolute anchorage leads to a more reliable treatment plan and enables a reduction in the treatment time. Third, this anchorage system obviates the dependency on patient compliance. Extraoral anchoring devices such as headgear could be replaced by this system unless patient cooperation could be obtained.

In the present case, orthognathic surgery was another treatment option. However, the patient had already received previous orthodontic treatment and refused to submit to an orthognathic surgery procedure. Furthermore, since her maxillary first premolars had already been extracted in the earlier orthodontic treatment, the only option to correct the large overjet and the critical upper arch length discrepancy (-14.5 mm) was to move all the posterior teeth to the distal. Therefore, SAS offered the best cost-benefit therapy choice because it caused the patient only a slight surgical invasion for placement of the anchor plate, and offered a treatment for the severe maxillary protrusion and upper dental crowding.

The patient's main complaints, which were difficulty of lip closure and also the gummy smile, were improved by the treatment. Since the overjet was corrected and the maxillary anterior teeth were uprighted, the upper lip became more relaxed and placed in a more downward position. As a result, the lips showed less tension and permitted the patient to close her lips effortlessly. In addition, the upper incisors were intruded 2.2 mm, which improved the appearance of the gummy smile.

When using a SAS, the average amounts of distal movement of the maxillary first molars were reported to be 3.78 mm and 3.20 mm at the crown and root levels, respectively.⁷ Furthermore, the maximum displacements were 6.8 mm at the crowns and 6.0 mm at the roots.⁷ This indicates that the skeletal anchorage system can be considered an effective modality for distal molar movement if noncompliance is present. In addition, these values enable us to make the treatment plan with a reliable treatment goal. In the present case, we observed that the amount of distal movement of the maxillary first molars was 7.2 mm and 3.5 mm at the crown and root levels, respectively. The displacement value at the crown level was almost equal to the

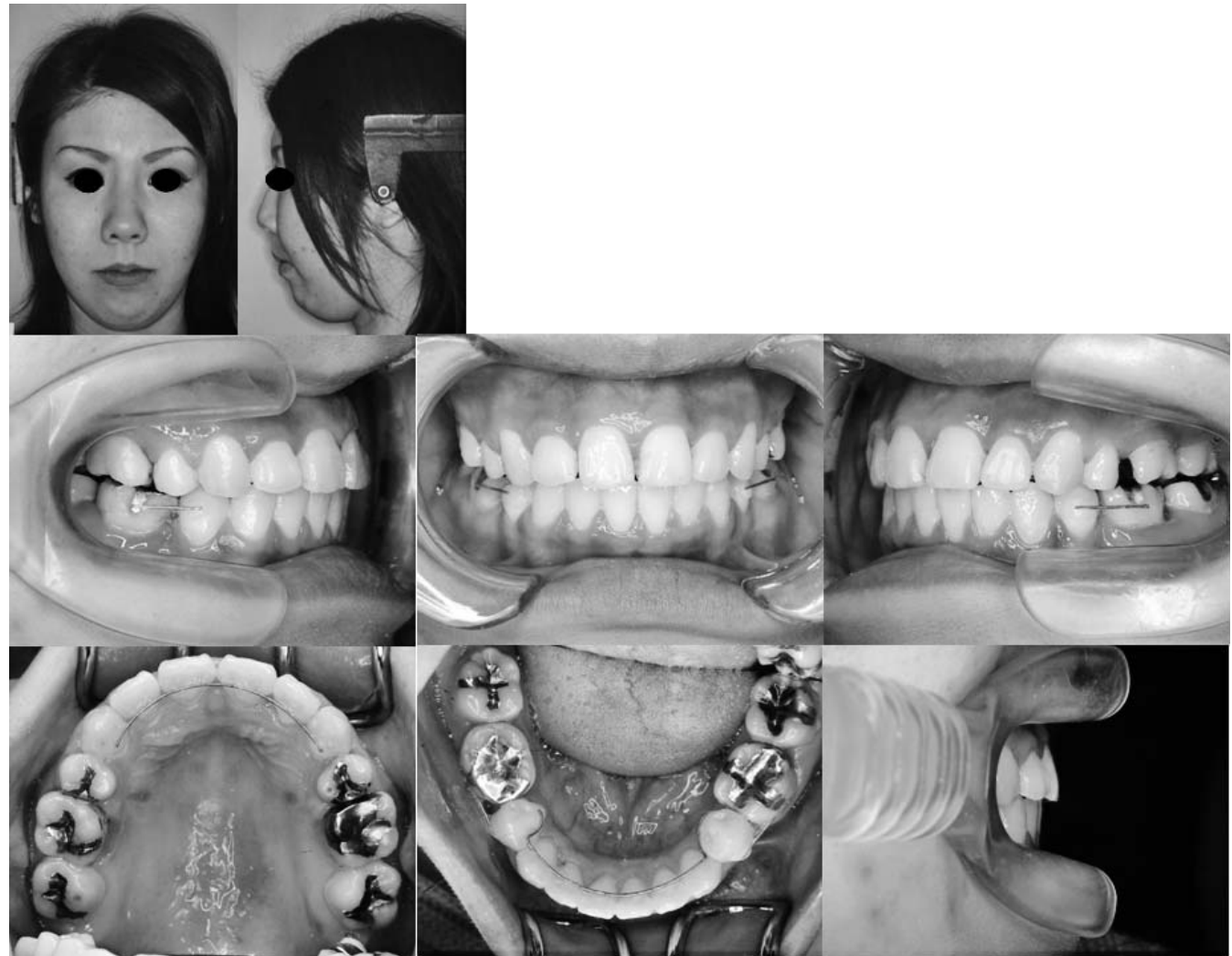

Figure 6. Facial and intraoral photographs after treatment (age 24 years 5 months).

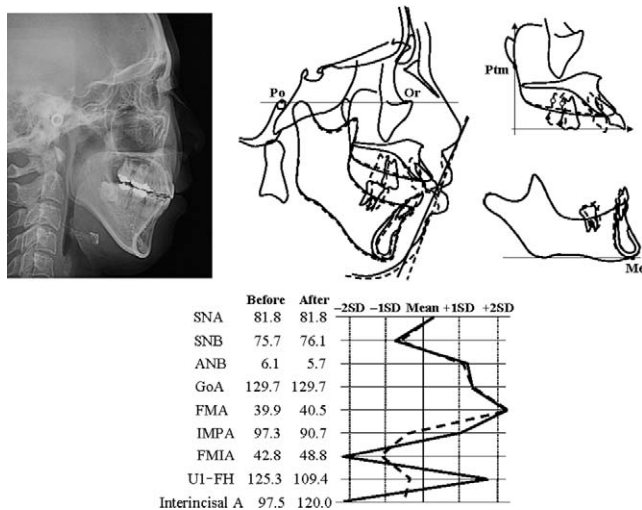


Figure 7. Lateral cephalogram and superimposition of cephalometric tracings before (solid line) and after (dotted line) treatment.

arch length discrepancy of the upper arch at the initial stage. The value of the posterior displacement at the crown level was more than the maximum reported previously.⁷ The possible explanation for the marked large displacement may be due to the mesial tipping of the maxillary first molars before treatment. This patient had received orthodontic treatment a decade before the beginning of the second treatment, and unfortunately, the treatment had a poor outcome with an excessive mesial tipping of the molars.

External apical root resorption is a multifactorial problem encountered in all disciplines of dentistry and one of the most common complications of orthodontic treatment. Force magnitude and direction have been suggested as important factors, and intrusion with continuous forces was most likely to exacerbate any external apical root resorption.^{10,11} In the present case, marked root resorption in the upper incisors was not found throughout the treatment period, although the

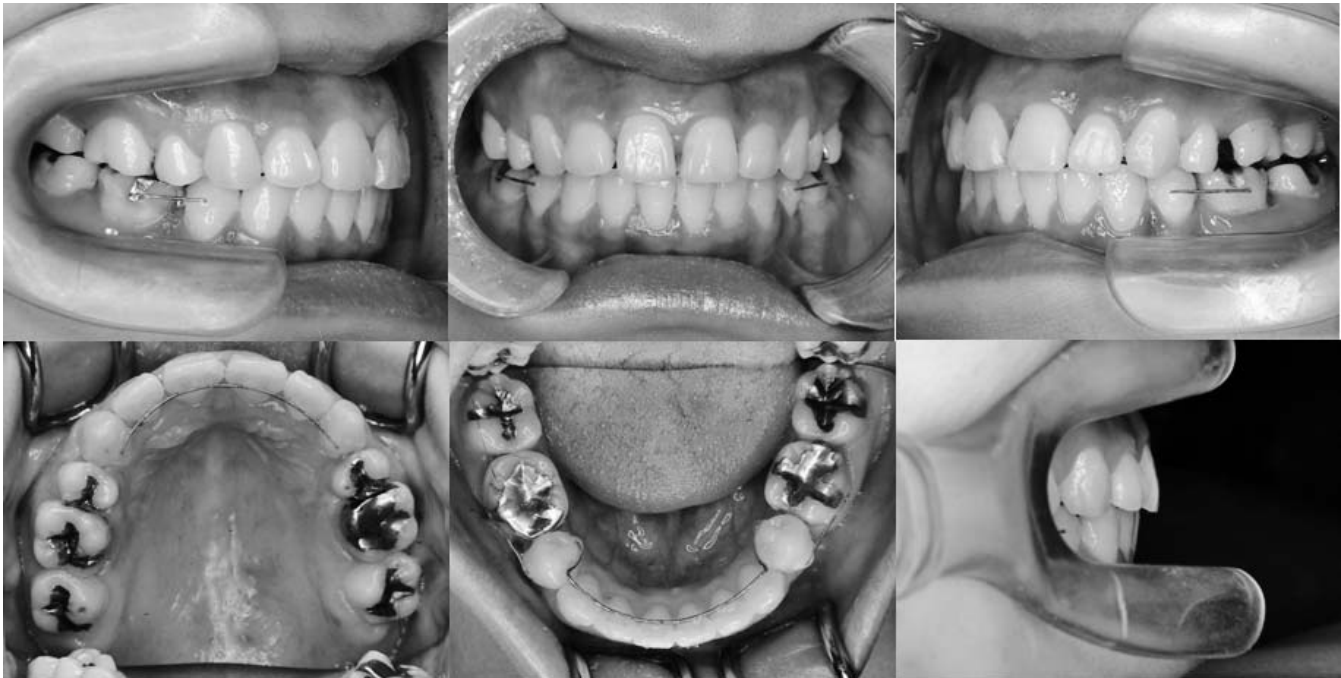

Figure 8. Intraoral photographs 2 years after treatment.

upper incisors were intruded 2.2 mm and retracted 3.1 mm at the root apex, and their incisal edge was placed 7.3 mm posteriorly.

With respect to the treatment factors causing root resorption, Sameshima and Sinclair¹² indicated that first premolar extraction cases had significantly more resorption than nonextraction cases for maxillary central incisors. Furthermore, they found a significant correlation between the amount of horizontal movement and the amount of apical root resorption for maxillary central incisors and suggested that the reason for extended treatment may itself shed some light on this association.¹² They also indicated that the horizontal root (but not crown) displacement of the incisors may have a higher estimated risk for root resorption.¹³ In the present study, both the maxillary first molars and central incisors were moved to the distal by almost the same amount. As the result, the present case could obtain an acceptable occlusion and good profile. Actually, maxillary anterior retraction is most effective for correction of a severe maxillary protrusion with a large overjet so that further information about the association between root resorption and tooth movement by means of a SAS will be absolutely necessary.

In conclusion, an adult case of severe maxillary protrusion with large overjet and critical upper arch length negative discrepancy was treated with a SAS. This system was used as an alternative treatment for an orthognathic surgery case. Although the patient showed a large discrepancy due to the extraction of the maxillary first premolars in previous orthodontic

treatment, the discrepancy was completely improved by distal movement of the maxillary molars with a SAS, resulting in an acceptable occlusion with a Class I molar relationship. The present case indicated that the skeletal anchorage is of great importance for achieving intrusion and retraction of the maxillary incisors, even in cases of severe maxillary protrusion with previous experience of orthodontic treatment.

REFERENCES

1. Wehrbein H, Merz BR, Diedrich P, Glatzmaier J. The use of palatal implants for orthodontic anchorage. Design and clinical application of the orthosystem. *Clin Oral Implants Res.* 1996;7:410–416.
2. Baumrind S, Korn EL, Isaacson RJ, West EE, Molthen R. Quantitative analysis of the orthodontic and orthopedic effects of maxillary traction. *Am J Orthod.* 1983;84:384–393.
3. Bondemark L, Kurol J. Distalization of maxillary first and second molars simultaneously with repelling magnets. *Eur J Orthod.* 1992;14:264–272.
4. Muse DS, Fillman MJ, Emmerson WJ, Mitchell RD. Molar and incisor changes with Wilson rapid molar distalization. *Am J Orthod Dentofacial Orthop.* 1993;104:556–565.
5. Bussick T, McNamara JA Jr. Dentoalveolar and skeletal changes associated with the pendulum appliance. *Am J Orthod Dentofacial Orthop.* 2000;117:333–343.
6. Brickman CD, Sinha PK, Nanda RS. Evaluation of the Jones jig appliance for distal molar movement. *Am J Orthod Dentofacial Orthop.* 2000;118:526–534.
7. Sugawara J, Kanzaki R, Takahashi I, Nagasaka H, Nanda R. Distal movement of maxillary molars in nongrowing patients with the skeletal anchorage system. *Am J Orthod Dentofacial Orthop.* 2006;129:723–733.

8. Wada K, Otani S, Sakuda M. Morphometric analysis in maxillary protrusion [in Japanese]. In: Yamauchi K, Sakuda M, eds. *Maxillary Protrusion*. Tokyo: Ishiyaku; 1989:95–130.
9. Umemori M, Sugawara J, Mitani H, Nagasaka H, Kawamura H. Skeletal anchorage system for open-bite correction. *Am J Orthod Dentofacial Orthop*. 1999;115:166–174.
10. Faltin RM, Arana-Chavez VE, Faltin K, Sander FG, Wichelhaus A. Root resorptions in upper first premolars after application of continuous intrusive forces. Intra-individual study. *J Orofac Orthop*. 1998;59:208–219.
11. Parker RJ, Harris EF. Directions of orthodontic tooth movements associated with external apical root resorption of the maxillary central incisor. *Am J Orthod Dentofacial Orthop*. 1998;114:677–683.
12. Sameshima GT, Sinclair PM. Predicting and preventing root resorption: Part II. Treatment factors. *Am J Orthod Dentofacial Orthop*. 2001;119:511–515.
13. Sameshima GT, Sinclair PM. Characteristics of patients with severe root resorption. *Orthod Craniofac Res*. 2004;7:108–114.