

Case Report

Temporomandibular disorders with skeletal open bite treated with stabilization splint and zygomatic miniplate anchorage: A case report

Fang Song^a; Shushu He^b; Song Chen^c

ABSTRACT

This case report describes the treatment of a patient with temporomandibular disorder (TMD) and skeletal open bite. First, the patient was treated with a stabilization splint to stabilize the condyles in centric relation and to alleviate TMD signs and symptoms. After making a definitive diagnosis from postsplint records, orthodontic treatment was initiated. Titanium miniplates were placed at bilateral zygomatic buttresses and used as orthodontic anchorage for molar intrusion and distalization. The treatment was completed after 30 months. Satisfactory appearance and function were achieved for this patient. (*Angle Orthod.* 2015;85:335–347.)

KEY WORDS: TMD; Occlusion; Stabilization splint; Open bite; Miniplate anchorage; Molar intrusion

INTRODUCTION

Temporomandibular disorders (TMD) is a subcategory of musculoskeletal disorders,¹ having a recurrent or chronic course with noticeable fluctuation over time.² Masticatory muscle pain, temporomandibular joint (TMJ) sounds, limited jaw opening capacity, and deviations in mandibular movements are common signs and symptoms of TMD.³ Various treatment methods for TMD have been used, including occlusal splints, physiotherapy, relaxation therapy, pharmacological interventions, and arthroscopic surgery, as well as educational and behavioral counseling.^{1,3} However, it has been reported that there were few changes in the TMJs with joint effusion after treatment and that the

significant decrease in signs and symptoms of TMD after extensive surgical-orthodontic or orthodontic treatment is likely related to favorable changes in muscular balance.⁴ Results from different modalities of TMD treatment indicate that recovering the harmony between the stability of the TMJ and support by occlusion is more important for providing long-lasting function of the masticatory system than we expected before.⁵

A stabilization splint is a hard acrylic splint that provides a temporary and removable ideal occlusion to reduce abnormal muscle activity and produces neuromuscular balance. With regard to the efficacy of stabilization splint treatment for TMD, much controversial research exists. Similar findings have been reported by several recent randomized clinical trials; these findings indicate that the stabilization splint is more effective than other treatments for TMD.^{6–8} However, there are some studies^{9–11} that have yielded contradictory results.

This case report demonstrates a skeletal open bite with TMD successfully treated by stabilization splint combined with titanium miniplate for orthodontic anchorage.

CASE REPORT

Diagnosis and Etiology

The patient, a 20-year-old girl, came with a chief complaint of “a chewing problem and pain of the right TMJ and right masseter muscles for 1 year.” She had

^a Postgraduate Student, State Key Laboratory of Oral Diseases, Department of Orthodontics, West China Hospital of Stomatology, Sichuan University, Chengdu, Sichuan, China.

^b Lecturer, State Key Laboratory of Oral Diseases, Department of Orthodontics, West China Hospital of Stomatology, Sichuan University, Chengdu, China.

^c Associate Professor, State Key Laboratory of Oral Diseases, Department of Orthodontics, West China Hospital of Stomatology, Sichuan University, Chengdu, Sichuan, China.

Corresponding author: Dr Song Chen, Associate Professor, Department of Orthodontics, West China College of Stomatology, Sichuan University, Section 3, No. 14, Renmin South Road, Chengdu, Sichuan, 610041 China (e-mail: songchen882002@hotmail.com)

Accepted: March 2014. Submitted: January 2014.

Published Online: April 28, 2014

© 2015 by The EH Angle Education and Research Foundation, Inc.

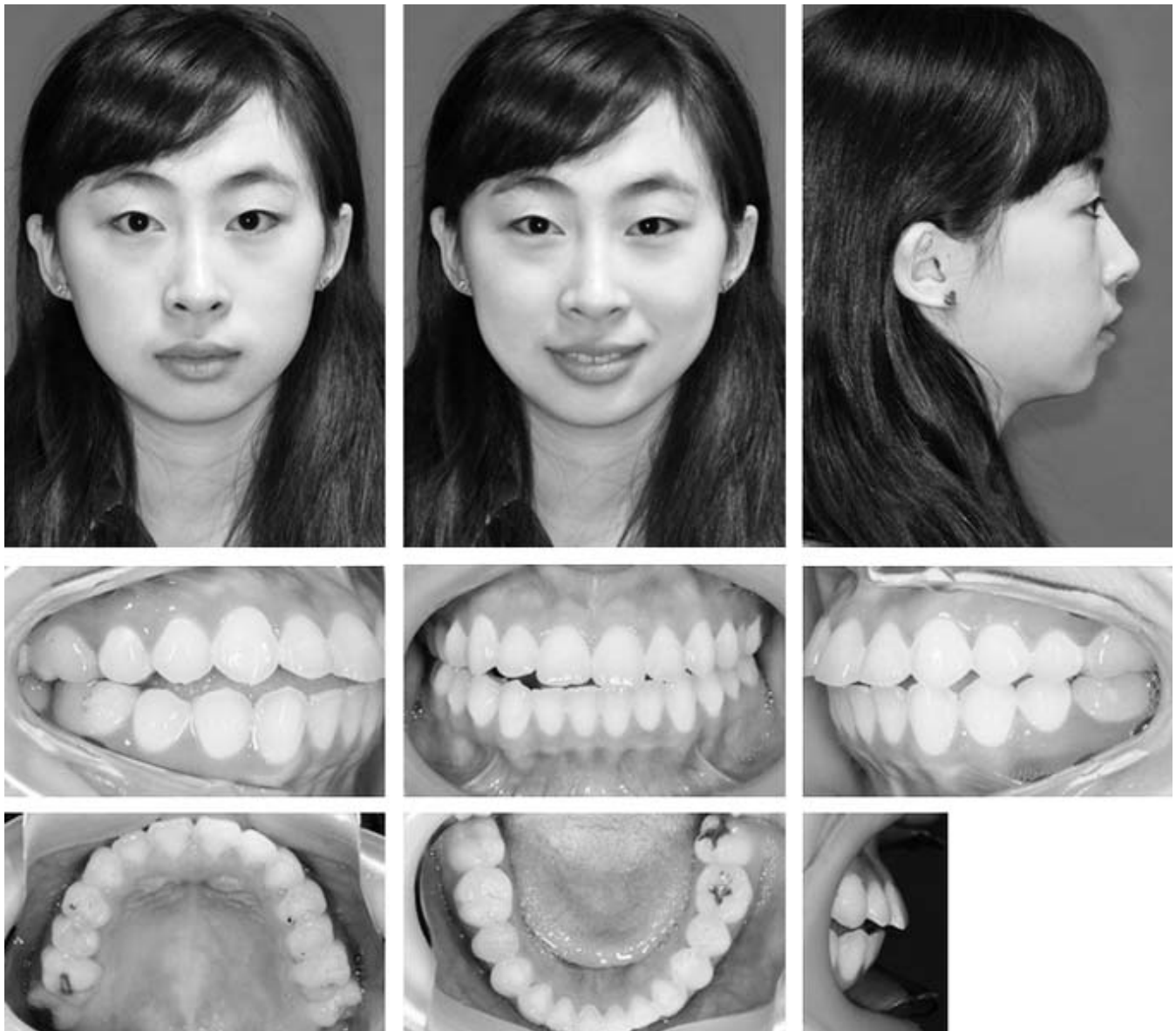


Figure 1. Pretreatment facial and intraoral photographs.

received previous fixed orthodontic treatment at age 11, which lasted for 2 years.

Diagnostic records were taken, including facial and intraoral photographs (Figure 1) and lateral cephalogram and panoramic radiograph (Figure 2). Facially, her profile was convex, while her nasolabial angle was about 90° , and no asymmetry was present in the frontal view. Intraorally, her molar and canine relationships were Class I and II, respectively, on both sides. Her upper dental midline was 2.0 mm right of the midsagittal plane, while her lower midline was on, and her second molars were in buccal crossbite on both sides. Cast analysis revealed no crowding in both arches; a 3.0-mm overjet and a 1.0-mm anterior open bite were visible, and she demonstrated lack of

occlusal contact from the left first premolar to the right second premolar. Cephalometric radiograph and tracing indicated a mild skeletal Class II relationship (ANB 5.5° , Table 1), a moderately steep mandibular plane (40.2° , Table 1), and labially proclined upper and lower incisors.

The status and function of the patient's TMJs were first evaluated based on guidelines established by Dawson,¹² and then diagnosis of TMD was confirmed by the research diagnostic criteria for TMD developed by Dworkin and Le Resche.¹³ More specifically, the patient reported moderate muscular and TMJ pain during mandibular movements and pain upon palpation of the right TMJ. The maximal mouth opening was decreased (37 mm), with deviation to the right side

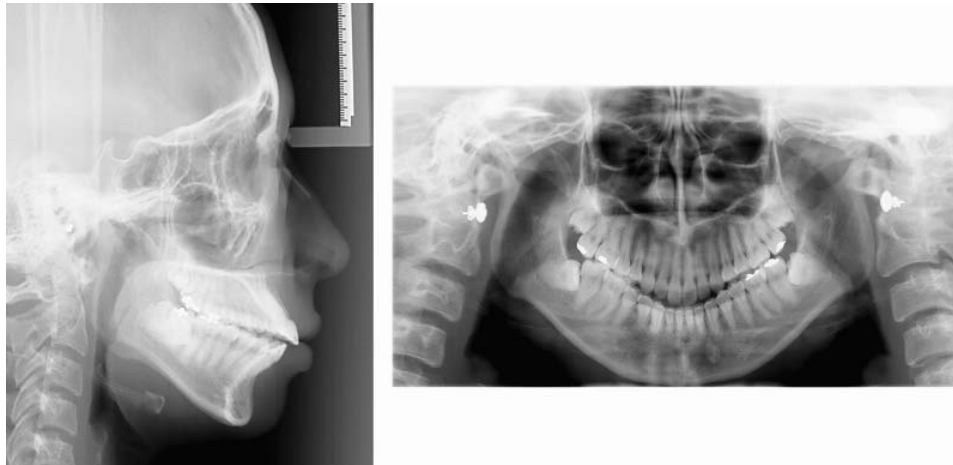


Figure 2. Pretreatment cephalogram and panoramic radiograph.

during jaw opening. A discrepancy of condylar position between centric relation (CR), defined as “the maxillomandibular relationship in which the condyles articulate with the thinnest avascular portion of their respective discs with the condyle in the anterior-superior position against the slopes of the articular eminenc,”¹⁴ and maximum intercuspation (MI), defined as “the complete intercuspation of the opposing teeth independent of condylar position,”¹⁴ was detected and measured by the condylar position indicator. On the horizontal plane, the condylar position in MI was 3 mm anteriorly dislocated from CR on both sides; on the vertical plane, the condylar position in MI was 2 mm and 1 mm inferiorly deviated from CR on the right and left sides, respectively; and on the transverse plane, the displacement was 1.5 mm to the right side.

Table 1. Cephalometric Analysis of the Patient at Pretreatment, Postsplint Treatment, and Posttreatment^a

	Mean ± SD Pretreatment	Postsplint	Posttreatment
SNA, °	81.69 ± 2.54	82.6	82.8
SNB, °	78.94 ± 2.19	77.1	75.5
ANB, °	2.75 ± 1.16	5.5	7.3
SN-MP, °	32.85 ± 4.21	40.2	42.4
Y axis, °	63.54 ± 3.23	66.5	68.2
S-Go/N-Me	65.85 ± 3.83	63.1	61.5
ANS-Me/N-Me	53.32 ± 1.84	51.2	52.2
U1-L1, °	123.22 ± 6.18	93.9	97.1
U1-SN, °	74.94 ± 6.22	69	69.4
U1-NA, °	23.26 ± 6.17	30.4	30.1
L1-NB, °	27.38 ± 4.74	50.2	45.6
U6-PP, mm	24.86 ± 1.85	19.7	19.7
L6-MP, mm	32.7 ± 2.34	30.7	30.3
FMIA, °	51.81 ± 7.26	32.6	39.6
UL-EP, mm	-0.46 ± 1.92	0.3	3.2
LL-EP, mm	1.31 ± 1.92	2.1	3.9
Z-Angle, °	74.06 ± 4.57	68.5	66.4
Overjet, mm		3	9
Overbite, mm		-1	-5

^a SD indicates standard deviation.

Magnetic resonance imaging (MRI) of the TMJs demonstrated anterior disc displacement without reduction (Figure 3A,B). Cone beam computed tomography (CBCT) of the TMJs showed flattening and erosion of both condyles (Figure 3C). The right condyle had an anterior position relative to the glenoid fossa.

Treatment Objectives

From these findings, the patient was diagnosed with TMD and open bite with a skeletal Class II relationship. Because of her significant signs and symptoms of TMD, the first treatment objective was to relieve the signs and symptoms of TMD and to stabilize the condyles in CR with an occlusal splint. After her condylar position was completely seated in CR, definitive treatment decision were formulated to correct the malocclusion according to the mandibular position and occlusion relationship in CR as well as to establish an ideal overjet and overbite and to achieve a functional and stable occlusion with Class I relationship.

Treatment Alternatives

To achieve the initial treatment objective, therefore, the patient was prescribed a stabilization splint. After the condylar position had been stabilized, detailed records for an accurate diagnosis were taken, including facial and intraoral photographs (Figure 4) and lateral cephalogram (Figure 5). Split casts were prepared and mounted on the semiadjustable articulator (Figure 6) with a wax bite in CR.

From the cephalometric superimposition (Figure 7), the mandible rotated clockwise when the condyles were seated in CR, resulting in a more severe open bite, with an overjet of 9.0 mm and an overbite of -5.0 mm compared to the initial records. There was

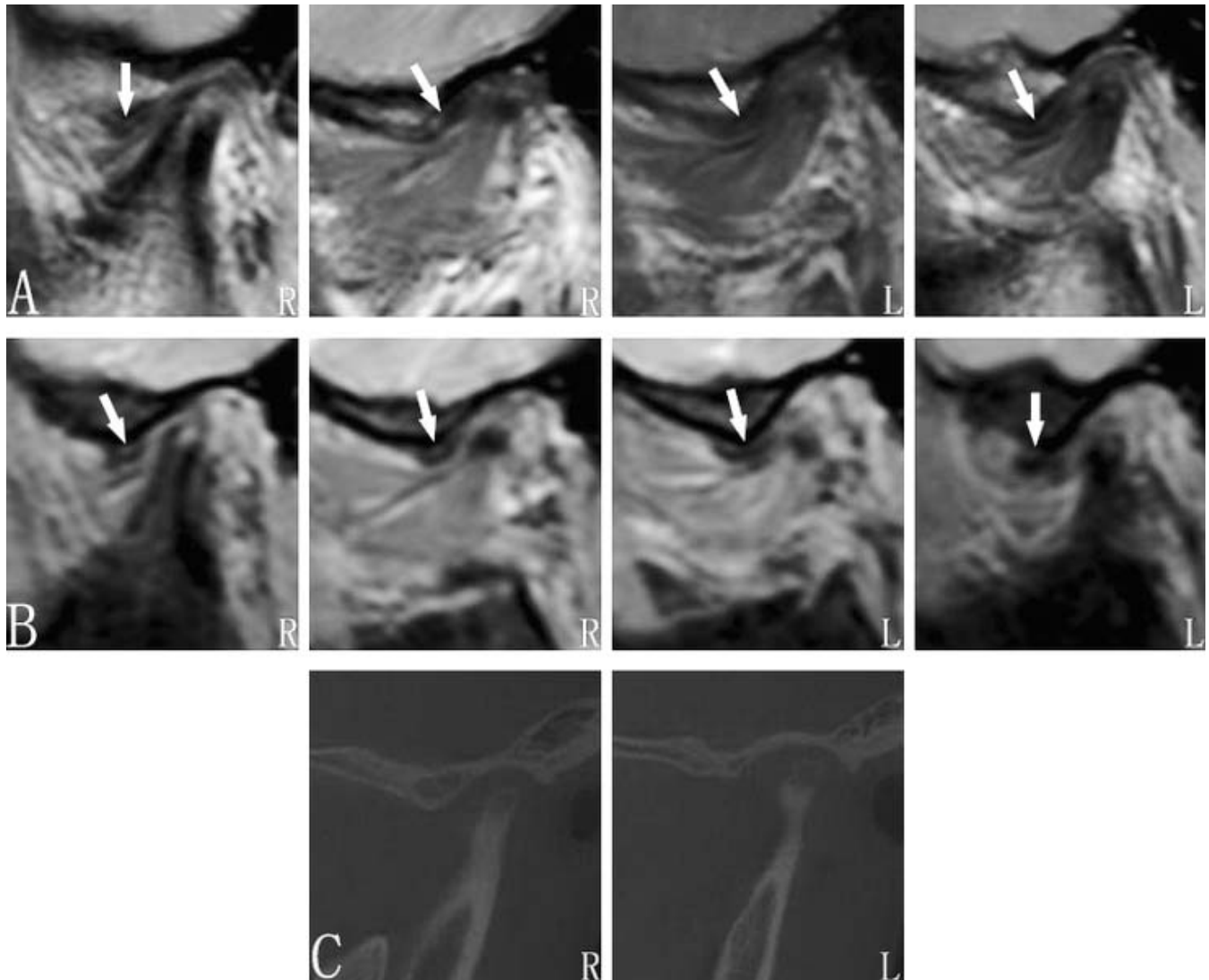


Figure 3. Pretreatment MRI (proton density-weighted images) and CBCT of TMJs: (A) disc (arrow) at both TMJs in oblique sagittal view of closed-mouth position on MRI; (B) disc (arrow) at both TMJs in oblique sagittal view of open-mouth position on MRI; (C) CBCT of both TMJs (R indicates the right TMJ; L, the left TMJ).

no occlusal contact from the second molar on the left to the first molar on the right. The skeletal Class II relationship was also aggravated, and molar relationships were Angle Class II on both sides.

The patient refused orthognathic surgery as a result of concerns related to high treatment costs and risk of surgery and instead selected the second option, which was to extract the maxillary second molars and mandibular third molars, followed by use of titanium miniplates as the anchorage to intrude the upper posterior teeth and to move the whole upper arch backward to reduce upper incisor proclination.

Treatment Progress

Before the stabilization splint was fabricated, an anterior deprogramming splint was used to relax the

patient's masticatory muscles, to alleviate pain, and to help us to determine CR more easily and accurately. The patient was instructed to wear the anterior deprogramming splint full time for 2 weeks, except when she was eating and tooth brushing. After that, the CR position was determined and recorded by the bimanual manipulation technique developed by Dawson.¹² A mandibular stabilization splint was subsequently fabricated on casts mounted in the CR registration record. The patient was instructed to wear the stabilization splint full time, which was regularly checked every 1 month and adjusted to ensure a mutually canine protected occlusion. Acrylic resin was added to the occlusal surface of the splint when needed to ensure that the condyles were seated into the uppermost and most forward position in the fossa according to the load testing.¹²

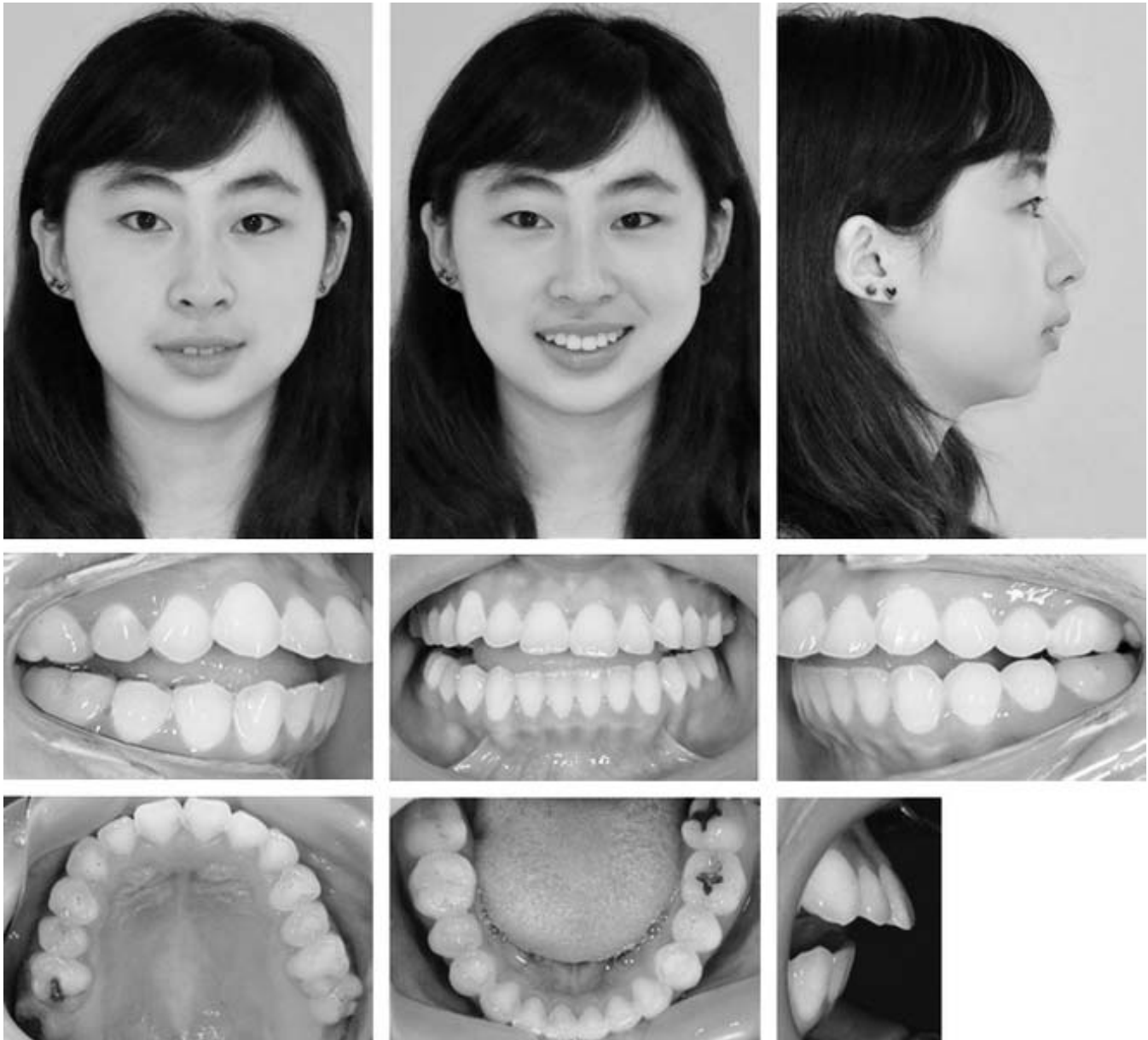


Figure 4. Postsplint treatment facial and intraoral photographs.

After 6 months of treatment, the patient's condyles completely stabilized in CR, and the pain of the TMJs and muscles was significantly alleviated. Then the upper second molars and lower third molars were extracted. Preadjusted fixed appliances (0.022×0.028 -inch, MBT system; 3M Unitek, Monrovia, Calif) were placed, and alignment in both upper and lower arches was achieved by sequenced 0.014- and 0.016-inch nickel-titanium wire. In the mandibular arch, a 0.047-inch lingual arch was placed between the first molars to maintain the width of the lower arch and to prevent labial tipping of the mandibular incisors during alignment and leveling (Figure 8). After leveling with

0.019 \times 0.025-inch nickel-titanium wire, the maxillary archwires were progressed to 0.019 \times 0.025-inch stainless-steel wire. Then a pair of L-shaped titanium miniplates was implanted in the zygomatic buttress area with the arm and two holes exposed to the oral cavity; the arm and holes were used to intrude the posterior upper teeth and retract the whole upper arch.

Three weeks were allowed to pass for healing and adaptation before we applied forces to the miniplates. After healing, elastic powerchains were placed bilaterally between the hole of the miniplate and the first molar buccal tube to create a directly vertical intrusive force (Figure 8). A transpalatal arch made from 0.047-

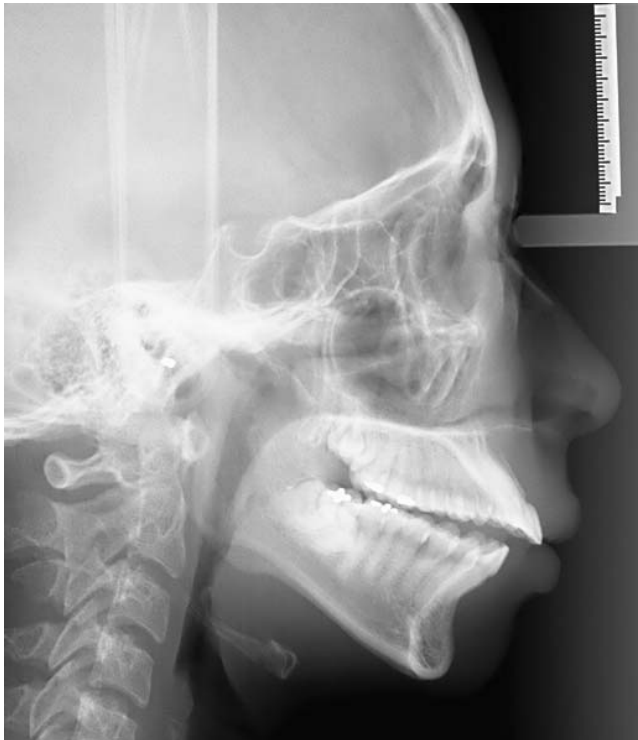

Figure 5. Postsplint treatment cephalogram.

inch stainless-steel wire positioned 3 mm away from the palate was used to prevent the buccal tipping of the molar segments during the intrusion (Figure 8). Then the nickel-titanium closed coil springs were applied to distalize the whole upper dentition (Figure 9A) and to correct the excessive overjet after 2 months of intrusion. To correct the right-deviated upper midline, two coil springs were applied on the left side (Figure 9B). Molar intrusion lasted for 6 months, while

maxillary arch retraction lasted for 4 months, with both discontinued simultaneously upon achieving a Class I molar relationship with proper overbite and overjet (Figure 9C).

During these treatments, the patient's maxillary third molars erupted vertically and established proper occlusion with the mandibular second molars by interarch elastics. After another 4 months of finishing and detailing, all appliances were removed. The total treatment time was 30 months. Clear retainers were used for retention in both arches.

Treatment Results

Angle Class I molar relationship with optimal anterior overjet, overbite, and sound interdigitation was achieved (Figure 10). The maxillary dental midline was coincident with the facial midline. No root absorption or other pathologic problems were shown on posttreatment panoramic radiograph (Figure 11). Cephalometric superimposition of the pretreatment, postsplint, and posttreatment cephalograms (Figure 12) showed a counterclockwise rotation of the mandible in response to a 3.0-mm (Table 1) maxillary molar intrusion. Dentally, upper and lower incisors were uprighted based on cephalometric measurements (Table 1) and superimposition (Figure 12). The posttreatment mandibular movement path was smooth without deviations, and neither clicking nor pain was present in the joints. CR-MI discrepancy was eliminated, and the condyle positions of CR in three planes of space were in accordance with those of MI. Favorable anterior/lateral guidance was established during the mandibular protrusive and laterotrusive movements (Figure 13). Although the articular disc

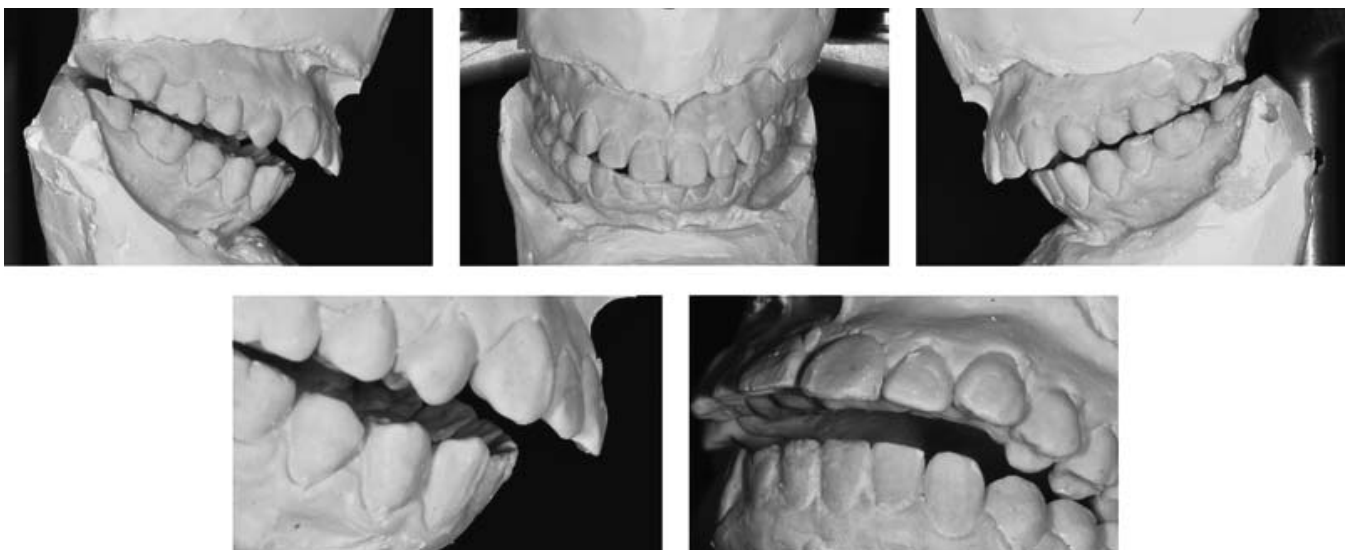


Figure 6. Models mounted in centric relation on the semiadjustable articulator of postsplint treatment.

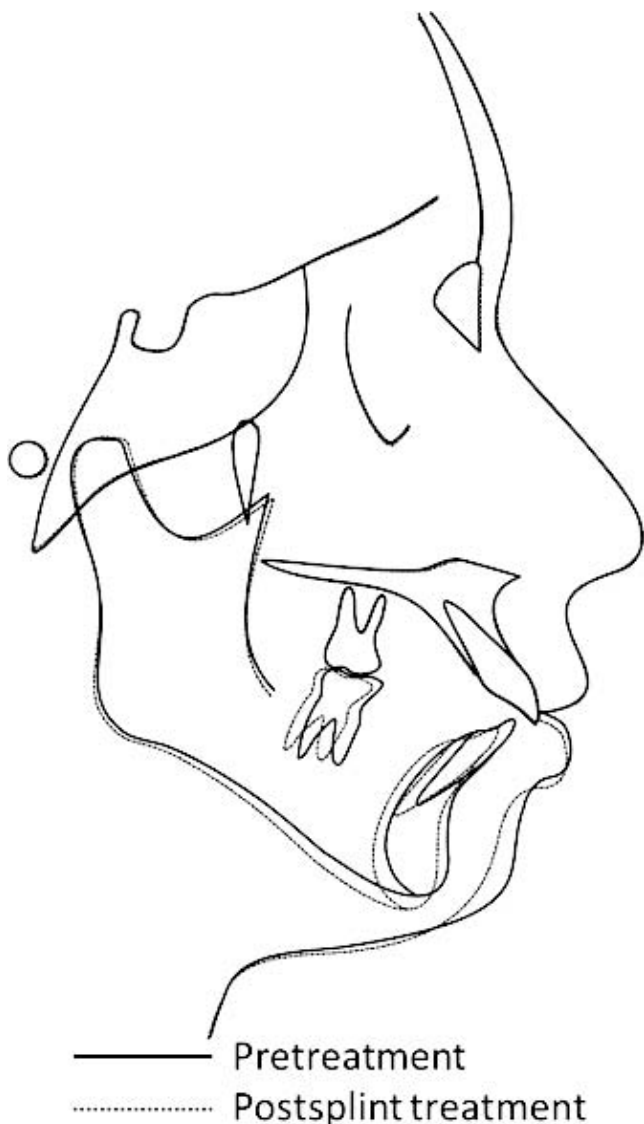


Figure 7. Cephalometric superimposition on the sella-nasion plane at sella.

remained displaced without reduction (Figure 14A,B), the condyles were centrally positioned in the glenoid fossae (Figure 14C). After 1 year of retention, the good occlusion and normal overbite and overjet were well maintained (Figure 15).

DISCUSSION

TMD is a complex disease, and its nature is not yet completely understood.¹⁵⁻¹⁷ The etiology of TMD is not clear but has been generally accepted to be multifactorial.^{18,19} Masticatory muscle pain, TMJ sounds, limited jaw opening capacity, and deviations in mandibular movements are common signs and symptoms of TMD, which tend to fluctuate with temporary remissions.^{6,20}

The actual role of occlusion in the etiology of TMD has been widely debated.^{21,22} It has been speculated that TMD is closely associated with some types of malocclusions, such as posterior crossbite, open bite, and deep bite, and the elimination of occlusion interference plus achievement of an occlusion system with no shift between CR and MI should be the primary goals of orthodontic treatment.^{23,24} Additionally, one current study²⁵ has reported that the degree of CR-MI discrepancy has a strong positive correlation with the severity of signs and symptoms of TMD and may be a contributory factor to the development of TMD. In reality, the mechanisms by which CR-MI discrepancy leads to the development of TMD have been proposed by Dawson¹² and Roth.²³ They declared that when CR interference is present during jaw closure, the inferior lateral pterygoid muscle, which should stay passive when CR-MI is in harmony, contracts nonphysiologically to pull the condyle out of CR to achieve MI. Therefore, the elevator muscles are thought to be hyperactivated, and the balance between the elevator and depressor muscles is broken, leading to masticatory muscle spasms and pain. It has been claimed that if the occlusal interference is not removed, chronic hyperactivity of the muscles will lead to articular disc derangement and forward displacement, which causes TMJ clicking, and further progression will result in intracapsular disorders, osteoarthritis, and even condylar absorption.

Alleviating the symptoms of TMD and stabilization of the condyles in CR were achieved after 6 months of stabilization splint therapy, which has been proposed to relax the muscles and seat the condyles in CR,^{3,12,26} during which attention had been paid to the follow-up adjustments of the stabilization splint until the joints stabilize, depending on how much remodeling of the TMJs would occur. Meanwhile, the pain in the muscles and TMJs was significantly reduced during mandibular movements, without any accompanying deflection. According to the functional occlusion theory,¹² when condyles are seated in CR without occlusal interference by a stabilization splint, the lateral pterygoid muscle would stay passive in MI position, which is in harmony with CR, and then the hyperactivated elevator muscles can be relieved, which would help to alleviate muscle pain and other symptoms. In terms of this case, it could be indicating that stabilization splint treatment might be an effective modality for TMD with CR-MI discrepancy.

Compared with pretreatment records, postsplint records have shown significant changes. To correct the more severe skeletal open bit, a treatment plan including molar intrusion and bodily distalization of the whole upper arch with temporary anchorage devices (TADs) was scheduled for the patient. In this case, significant maxillary molar intrusion and effective retraction of the

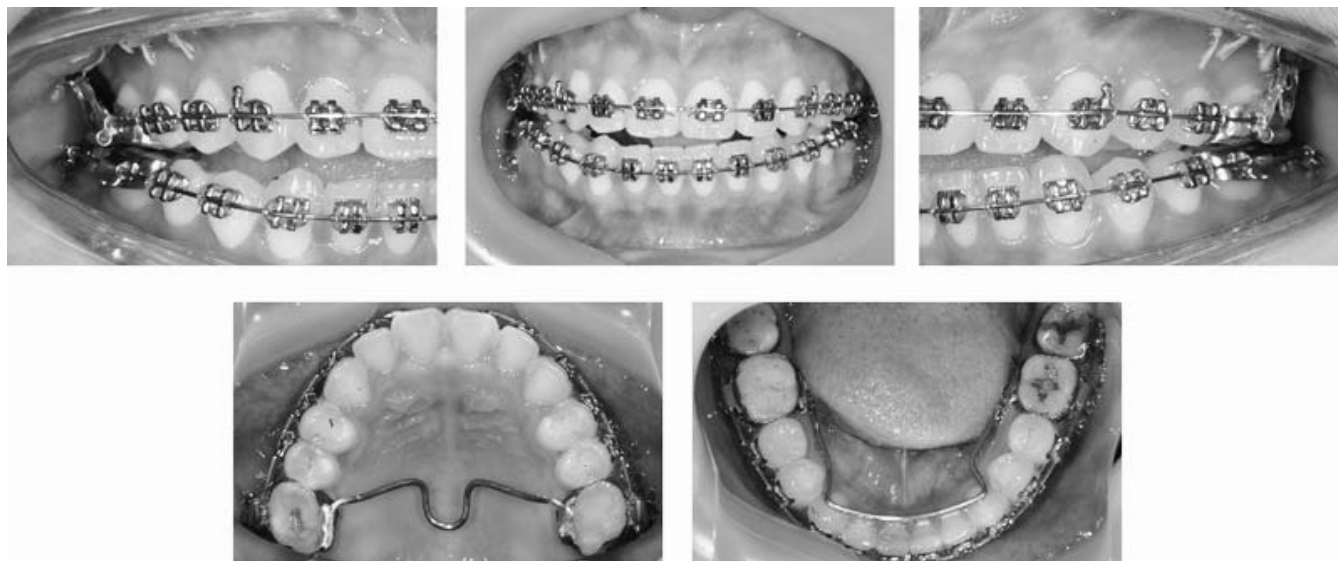


Figure 8. Intrusion of the maxillary molars with zygomatic miniplate anchorage.

whole upper arch had been achieved within 6 months, accompanied by the mandibular counterclockwise rotation, by the use of the miniplate anchorage.

Functional occlusion theory places much emphasis on establishing a stable occlusion, on the notion that

the anterior/lateral guidance assumes the key role, as well as on the immediate disocclusion of all posterior teeth in protrusive and lateral excursions of the mandible.¹² For this patient, in addition to the fact that the condyles were stably seated in CR, a favorable

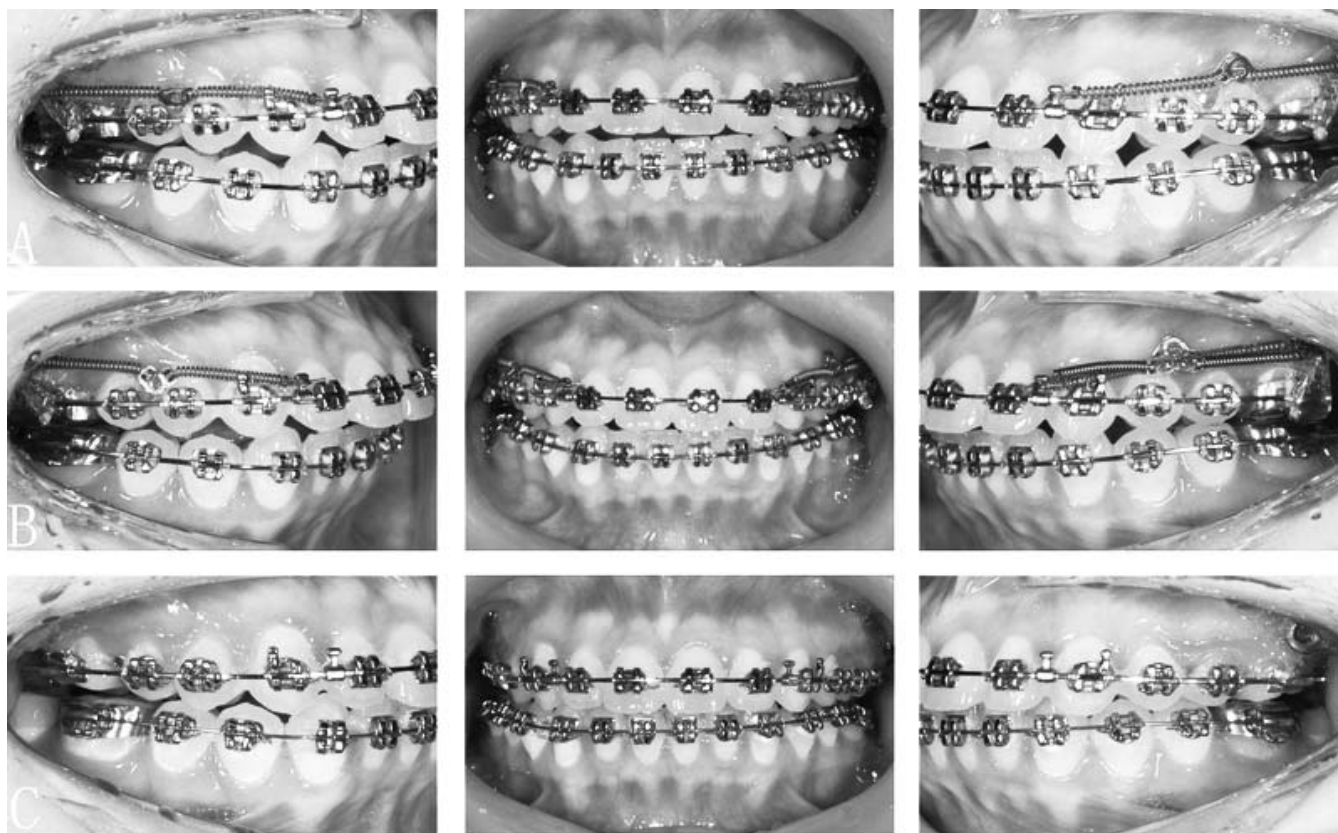


Figure 9. Progress of the maxillary molar intrusion and distalization of the upper dentition: (A) distalization of the whole upper dentition; (B) two coil springs applied on the left side to correct the right-deviated upper midline; (C) Class I molar relationship with proper overbite and overjet.

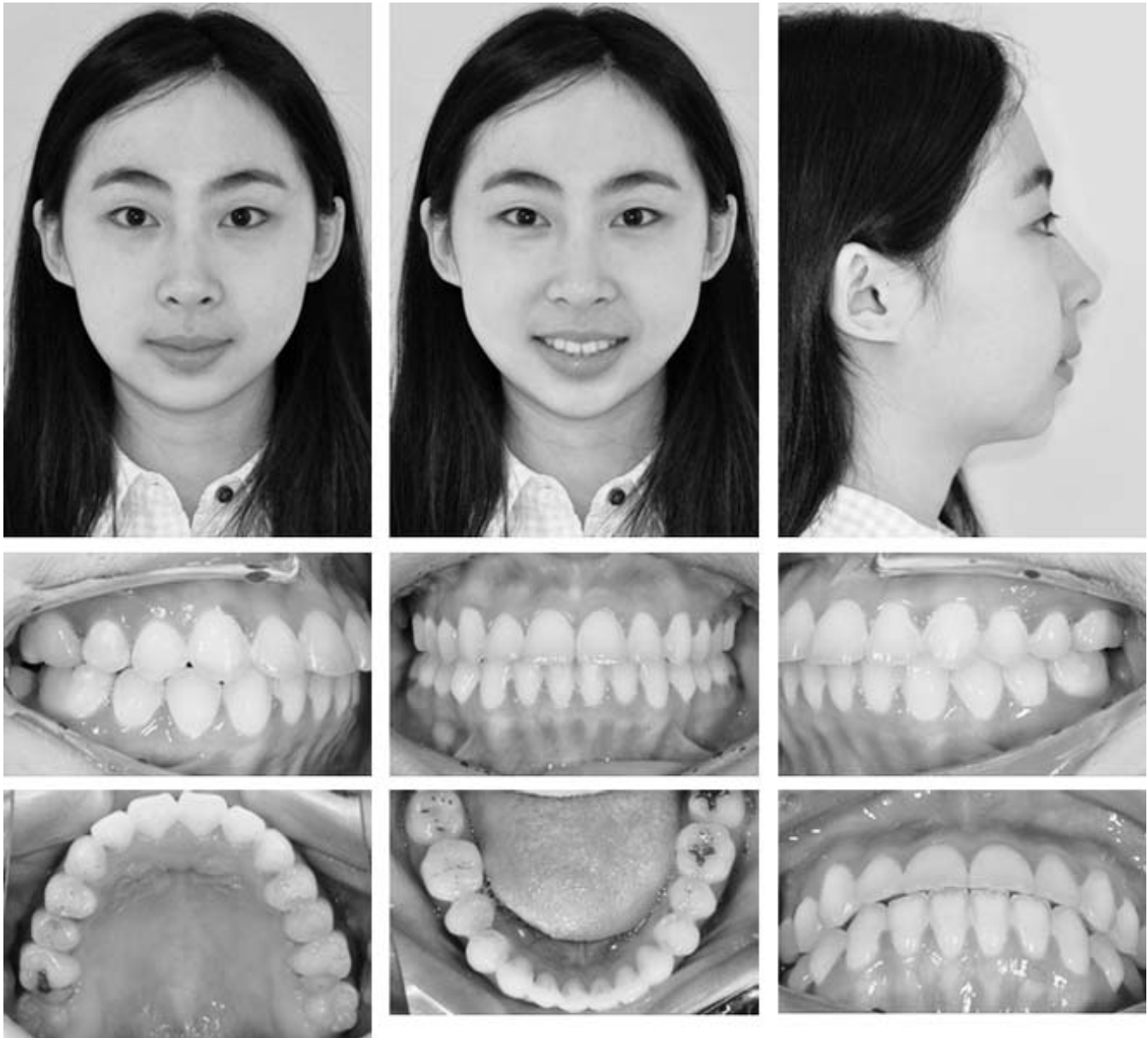


Figure 10. Posttreatment facial and intraoral photographs.

anterior/lateral guidance was also achieved after orthodontic treatment, as shown in Figure 13. In spite of the anterior disc displacement without reduction, as shown by MRI, it could be presumed that the favorable anterior/lateral guidance with periodic occlusal readjustment to maintain a peaceful neuromusculature would contribute to the long-term stability and retention of the occlusion.¹²

CONCLUSIONS

- This case demonstrated that the stabilization splint is of great significance for stabilizing the condyles in CR, eliminating CR-MI discrepancy, and the devel-

opment of accurate diagnosis and treatment plans for TMD patients.

- Zygomatic miniplate anchorage is effective for molar intrusion and upper arch distalization, which could comprise a useful alternative for patients with severe skeletal open bite.

REFERENCES

1. Okeson JP. *Management of Temporomandibular Disorders and Occlusion*. St Louis, Mo: Mosby; 2007.
2. Magnusson T, Egermark I, Carlsson GE. A longitudinal epidemiologic study of signs and symptoms of temporomandibular disorders.

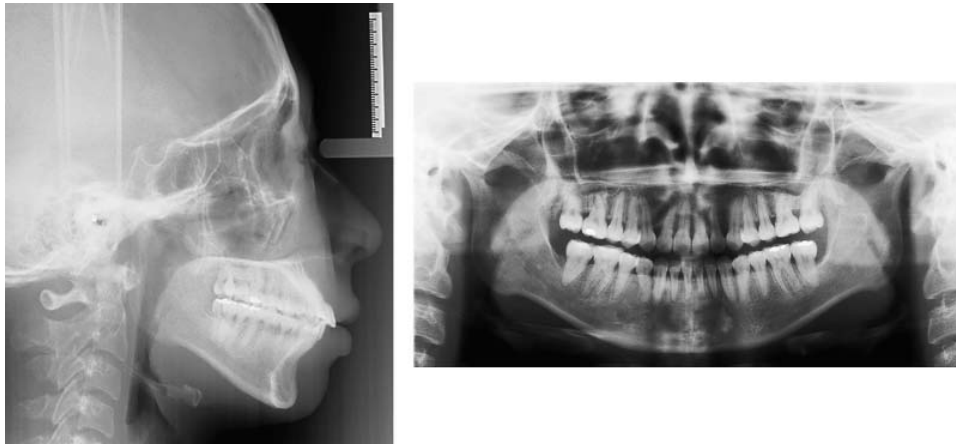


Figure 11. Posttreatment cephalogram and panoramic radiograph.

mandibular disorders from 15 to 35 years of age. *J Orofac Pain.* 2000;14:310–319.

3. Al-Ani Z, Gray RJ, Davies SJ, Sloan P, Glenny AM. Stabilization splint therapy for the treatment of temporomandibular myofascial pain: a systematic review. *J Dent Educ.* 2005;69:1242–1250.
4. Rusanen J, Pirttiniemi P, Tervonen O, Raustia A. MRI of TMJ in patients with severe skeletal malocclusion following surgical/orthodontic treatment. *Cranio.* 2008;26:182–190.
5. Kawagoe T, Akimoto S, Sato S. Orthodontic treatment of severe crowding malocclusion with temporomandibular joint closed-lock by means of multi-loop edgewise archwire: a case report. *J Stomat Occ Med.* 2010;3:49–60.
6. Ekberg E, Nilner M. Treatment outcome of appliance therapy in temporomandibular disorder patients with myofascial pain after 6 and 12 months. *Acta Odontol Scand.* 2004;62:343–349.
7. Magnusson T, Adiels AM, Nilsson HL, Helkimo M. Treatment effect on signs and symptoms of temporomandibular disorders—comparison between stabilization splint and a

new type of splint (NTI). A pilot study. *Swed Dent J.* 2004;28:11–20.

8. Ekberg E, Nilner M. A 6- and 12-month follow-up of appliance therapy in TMD patients: a follow-up of a controlled trial. *Int J Prosthodont.* 2002;15:564–570.
9. Wassel RW, Adams N, Kelly PJ. Treatment of temporomandibular disorders by stabilizing splints in general dental practice: results after initial treatment. *J Am Dent Assoc.* 2006;137:1089–1098.
10. Jokstad A, Mo A, Krogstad BS. Clinical comparison between two different splint designs for temporomandibular disorder therapy. *Acta Odontol Scand.* 2005;63:218–226.
11. Niemela K, Korpela M, Raustia A, Ylo Stalo P, Sipila K. Efficacy of stabilisation splint treatment on temporomandibular disorders. *J Oral Rehabil.* 2012;39:799–804.
12. Dawson PE. *Functional Occlusion: From TMJ to Smile Design.* St Louis, Mo: Mosby; 2006.
13. Dworkin SF, Le Resche L. Research diagnostic criteria for temporomandibular disorders: review, criteria, examinations and specifications, critique. *J Craniomandib Disord.* 1992;6:301–355.
14. The Academy of Prosthodontics, The glossary of prosthodontic terms. *J Prosthet Dent.* 2005;94:10–92.
15. Friction JR. Recent advances in temporomandibular disorders and orofacial pain. *J Am Dent Assoc.* 1991;122:24–32.
16. Friction JR, Olsen T. Predictors of outcome for treatment of temporomandibular disorders. *J Orofac Pain.* 1996;10:54–65.
17. de Wijer A, Steenks MH, Bosmon F, Helders PJM, Faber J. Symptoms of the stomatognathic system in temporomandibular and cervical spine disorders. *J Oral Rehabil.* 1996;23:742–750.
18. Luther F. TMD and occlusion part I. Damned if we do? Occlusion: the interface of dentistry and orthodontics. *Br Dent J.* 2007;202:38–39.
19. Mohlin BO, Derweduwen K, Pilley R, Kingdon A, Shaw WC, Kenealy P. Malocclusion and temporomandibular disorder: a comparison of adolescents with moderate to severe dysfunction with those without signs and symptoms of temporomandibular disorder and their further development to 30 years of age. *Angle Orthod.* 2004;74:319–327.
20. Alanen P, Kuttilla M, Le Bell Y. Fluctuation of temporomandibular disorders in accordance with two classifications: the Helkimo dysfunction index and treatment need grouping. *Acta Odontol Scand.* 1997;55:14–17.

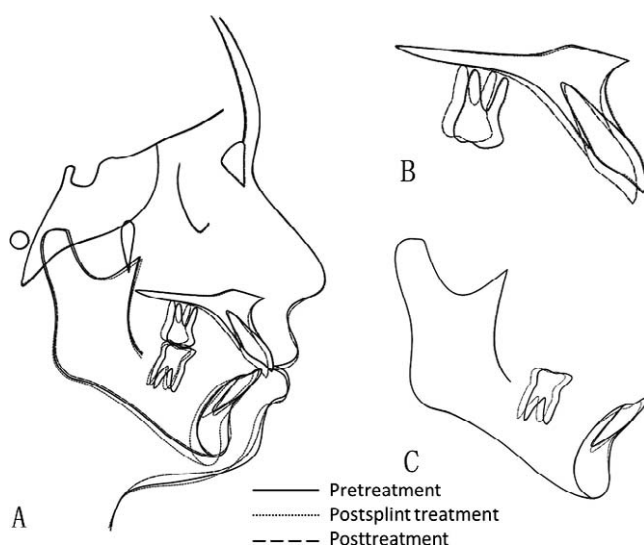


Figure 12. Cephalometric superimposition: (A) on the sella-nasion plane at sella; (B) on the palatal plane at ANS; (C) on the mandibular plane at menton.

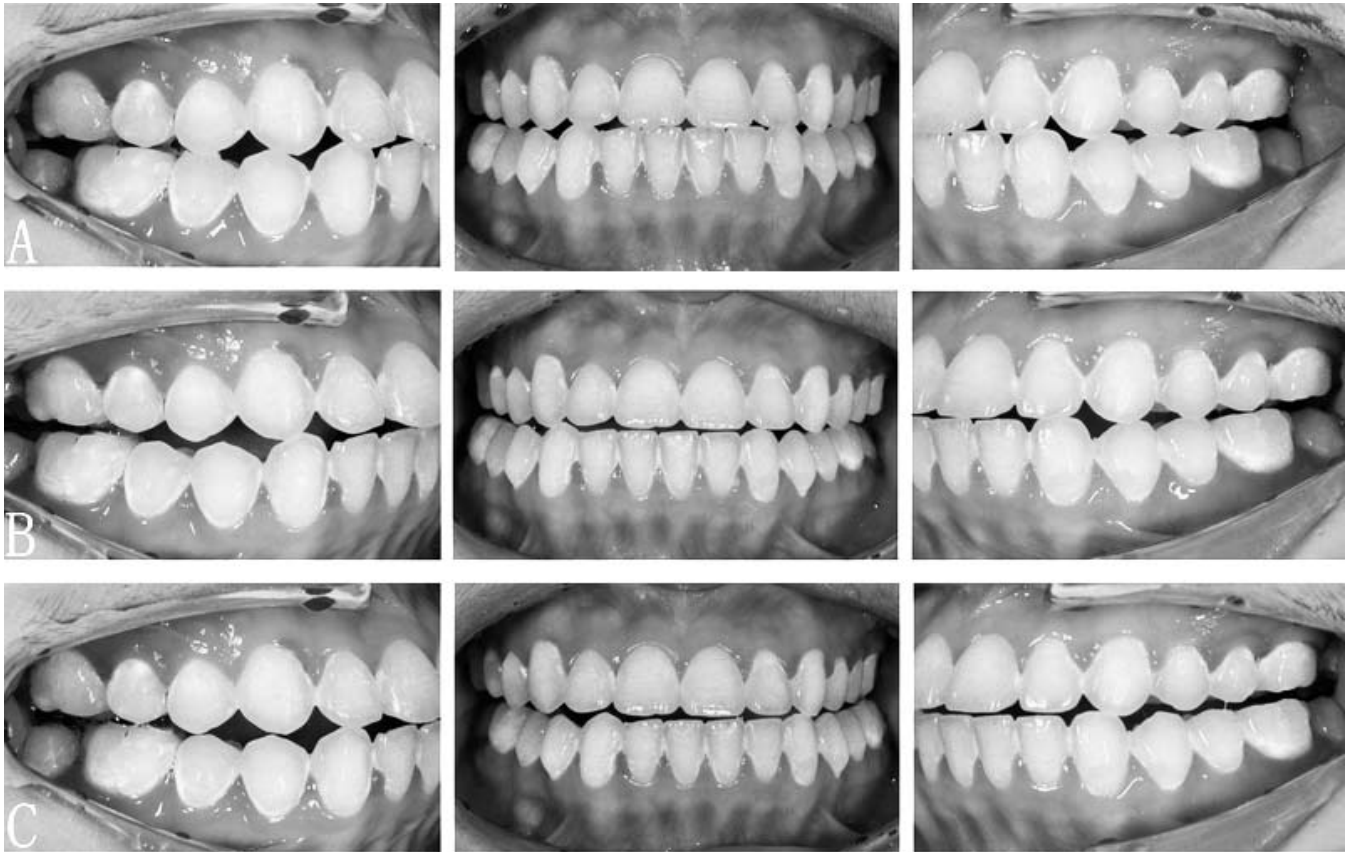


Figure 13. Favorable anterior and canine guidance: (A) protrusive movement; (B) right laterotrusion; (C) left laterotrusion.

21. Tanne K, Tanaka E, Sakuda M. Association between malocclusion and temporomandibular disorders in orthodontic patients before treatment. *J Orofac Pain.* 1993;7: 156–162.
22. Seligman DA, Pullinger AG. The role of functional occlusal relationships in temporomandibular disorders: a review. *J Craniomandib Disord.* 1991;5:265–279.
23. Roth RH. Functional occlusion for the orthodontist. *J Clin Orthod.* 1981;15:32–51.
24. Williamson EH. Occlusion: understanding or misunderstanding. *Angle Orthod.* 1976;46:86–93.
25. He SS, Deng X, Wamalwa P, Chen S. Correlation between centric relation–maximum intercuspation discrepancy and temporomandibular joint dysfunction. *Acta Odontol Scand.* 2010;68:368–376.
26. Gray RJ, Davies SJ. Occlusal splints and temporomandibular disorders: why, when, how? *Dent Update.* 2001;28: 194–199.

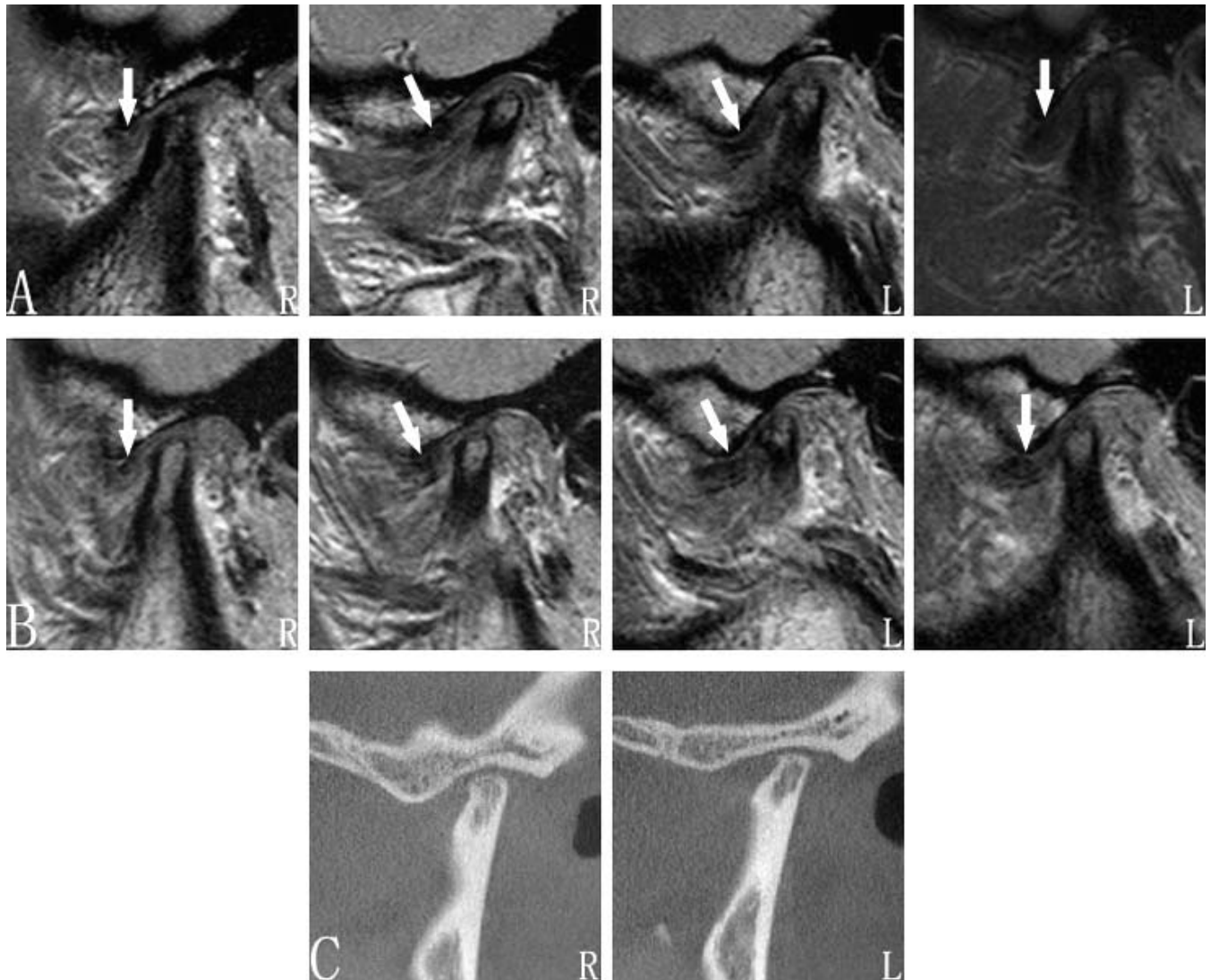


Figure 14. Posttreatment MRI (proton density-weighted images) and CBCT of TMJs: (A) disc (arrow) at both TMJs in oblique sagittal view of closed-mouth position on MRI; (B) disc (arrow) at both TMJs in oblique sagittal view of open-mouth position on MRI; (C) CBCT of both TMJs (R indicates the right TMJ; L, the left TMJ).

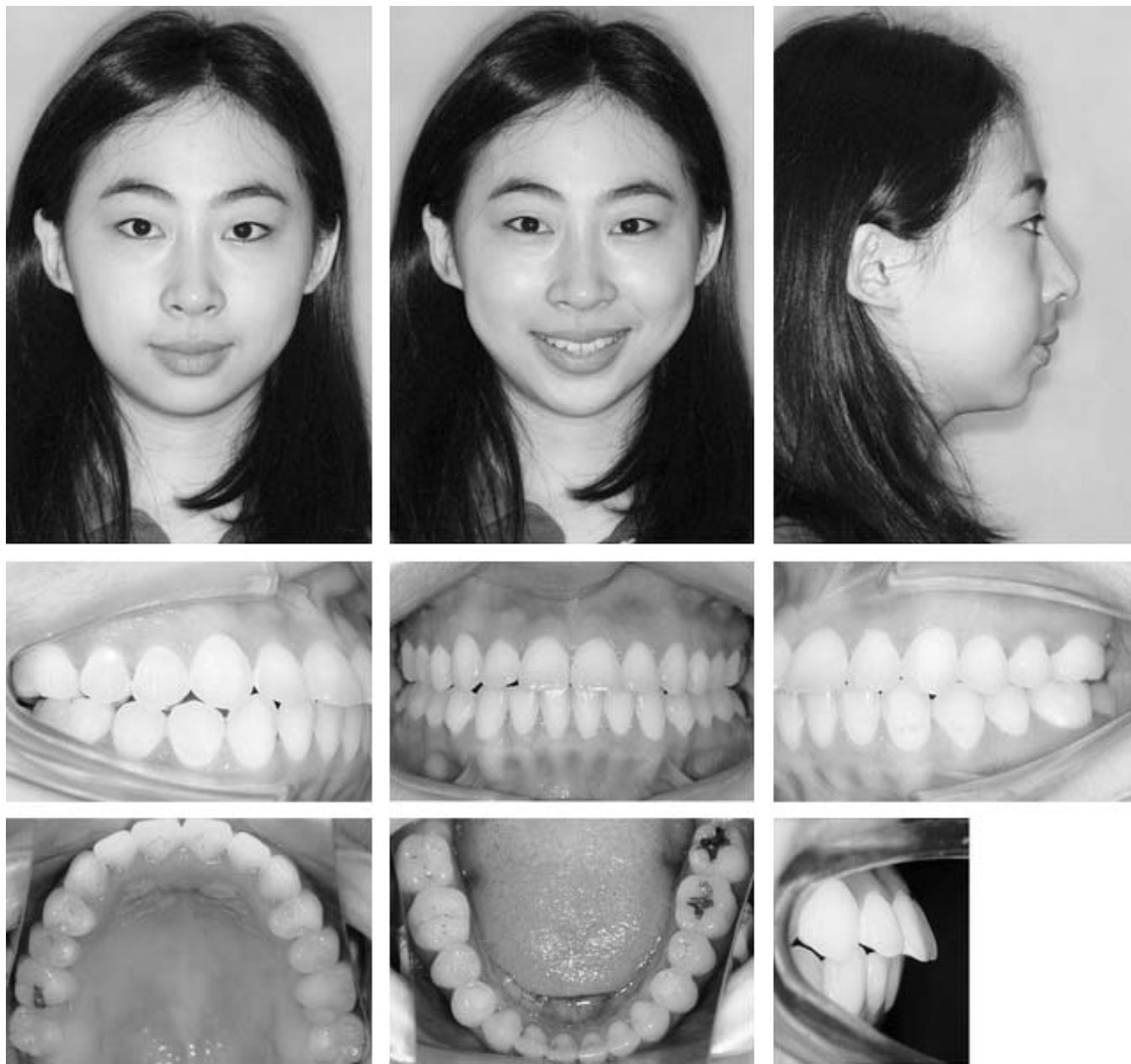


Figure 15. One-year retention facial and intraoral photographs.