

## Evaluation of miniscrew-supported rapid maxillary expansion in adolescents:

### *A prospective randomized clinical trial*

Tugce Celenk-Koca<sup>a</sup>; Aslihan Ertan Erdinc<sup>b</sup>; Serpil Hazar<sup>a</sup>; Lacey Harris<sup>c</sup>; Jeryl D. English<sup>d</sup>; Sercan Akyalcin<sup>e</sup>

#### ABSTRACT

**Objectives:** To evaluate and compare the dental and skeletal changes with conventional and miniscrew-supported maxillary expansion appliances in adolescents.

**Materials and Methods:** Forty patients were divided into two groups, with one group receiving a tooth-borne expander and the other group receiving an expander supported by four miniscrews (bone-borne). Multiplanar coronal and axial slices obtained from cone-beam computed tomography images were used to measure the changes in transverse skeletal widths, buccal bone thickness, tooth inclination, and root length. Paired *t*-tests and independent-sample *t*-tests were used to compare the two expansion methods.

**Results:** Bone-borne expansion increased the maxillary suture opening more than 2.5 times than tooth-borne expansion both anteriorly and posteriorly. Between the maxillary first premolars, sutural expansion accounted for 28% and 70% of the total transverse width increase in the tooth-borne and bone-borne expander groups, respectively. Similarly, 26% and 68% of the total expansion was of skeletal nature in the tooth-borne and bone-borne expander groups between the maxillary first molars. The pattern of expansion was variable, with most of the patients in both groups demonstrating a triangular-shaped sutural opening that was wider anteriorly. Subjects in the conventional group experienced significantly more buccal bone reduction and greater buccal inclination of the teeth. No significant differences were observed for root length measurements between the two groups.

**Conclusion:** Use of bone-borne expansion in the adolescent population increased the extent of skeletal changes in the range of 1.5 to 2.8 times that of tooth-borne expansion and did not result in any dental side effects. (*Angle Orthod.* 2018;88:702–709.)

**KEY WORDS:** RME; Miniscrew-supported expansion; Hyrax; Dentoskeletal changes

<sup>a</sup> Private practice, Rotterdam, Netherlands.

<sup>b</sup> Professor, Department of Orthodontics, Faculty of Dentistry, Ege University, Izmir, Turkey.

<sup>c</sup> Assistant Professor, Department of Orthodontics, School of Dentistry, The University of Texas Health Science Center at Houston, Houston, Tex.

<sup>d</sup> Professor and Chair, Department of Orthodontics, School of Dentistry, The University of Texas Health Science Center at Houston, Houston, Tex.

<sup>e</sup> Associate Professor and Graduate Program Director, Department of Orthodontics, School of Dental Medicine, Tufts University, Boston, Mass.

Corresponding author: Dr Sercan Akyalcin, Tufts University School of Dental Medicine, Department of Orthodontics, Tufts University School of Dental Medicine, 1 Kneeland Street, Boston, MA 02111

(e-mail: sercan.akyalcin@tufts.edu)

Accepted: May 2018. Submitted: January 2018.

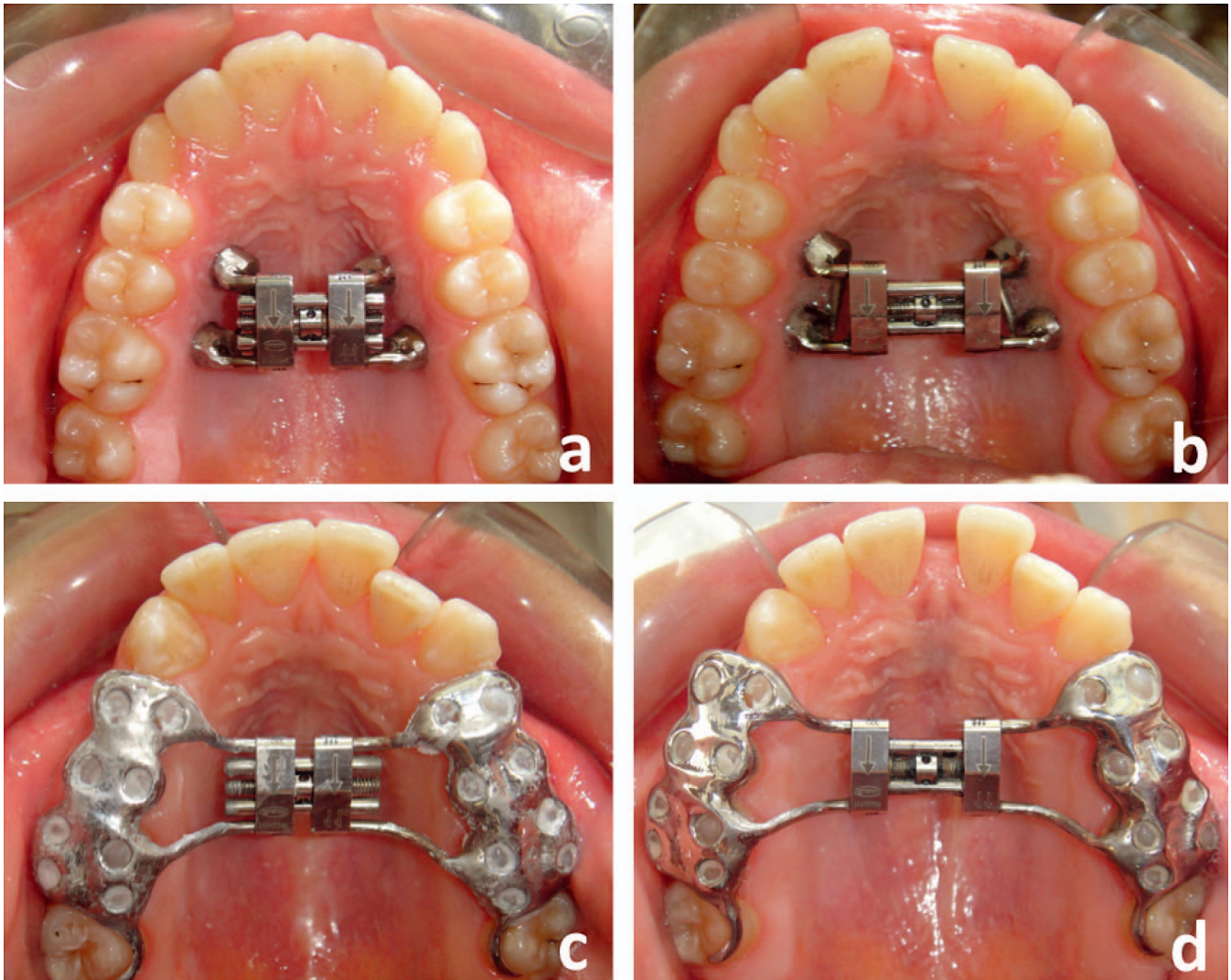
Published Online: August 13, 2018

© 2018 by The EH Angle Education and Research Foundation, Inc.

#### INTRODUCTION

Rapid maxillary expansion (RME) is the most efficient procedure to resolve transverse maxillary deficiency in adolescents. With increasing skeletal maturity, heavy interdigitation of the suture makes the separation of the two halves of the maxilla unfeasible using conventional tooth-borne RME appliances. Therefore, bone-borne RME appliances were originally developed for patients in whom conventional RME was contraindicated.<sup>1</sup>

Three-dimensional investigations demonstrated that conventional RME induces a highly variable individual response in skeletal structures.<sup>2</sup> Although opening of the midpalatal suture is the main goal of RME, the expansion force acting on the palatal aspect of the tooth crowns causes undesired dental effects, such as buccal tipping,<sup>3–6</sup> decrease in buccal bone thickness



**Figure 1.** Pre- (a) and postexpansion (b) occlusal photographs of a patient from the miniscrew-supported (bone-borne) RME group. Pre- (c) and postexpansion (d) occlusal photographs of a patient from the conventional RME group.

and marginal bone levels,<sup>4,7-9</sup> and volume loss and thinning of the anchor teeth.<sup>10,11</sup> Changes related to the buccal bone thickness<sup>7</sup> and root morphology<sup>11,12</sup> are mostly reversible. However, these side effects may be prevented from occurring in the first place by using miniscrews as anchorage units in bone-borne RME applications.

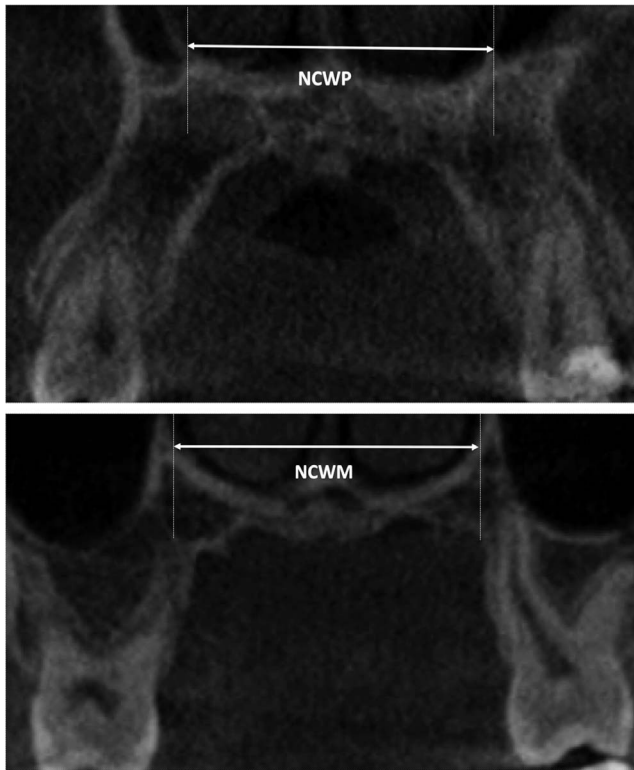
Bone-borne or miniscrew-supported maxillary expansion is still a relatively new introduction into orthodontics. The variable nature of skeletal expansion and the extent of undesired dental changes that occur following the use of conventional appliances might be the key factors to rationalize the use of miniscrew-supported maxillary expansion in adolescents. Although some studies<sup>13-16</sup> have been previously published, prospective clinical studies using identical samples are warranted to justify the common use of

bone-borne maxillary expansion in the adolescent population.

This prospective randomized clinical trial was designed to investigate the differences between conventional and miniscrew-supported RME appliances in an adolescent study sample. The null hypothesis was that miniscrew-supported RME would not offer any significant advantage over traditional expansion appliances in adolescents.

## MATERIALS AND METHODS

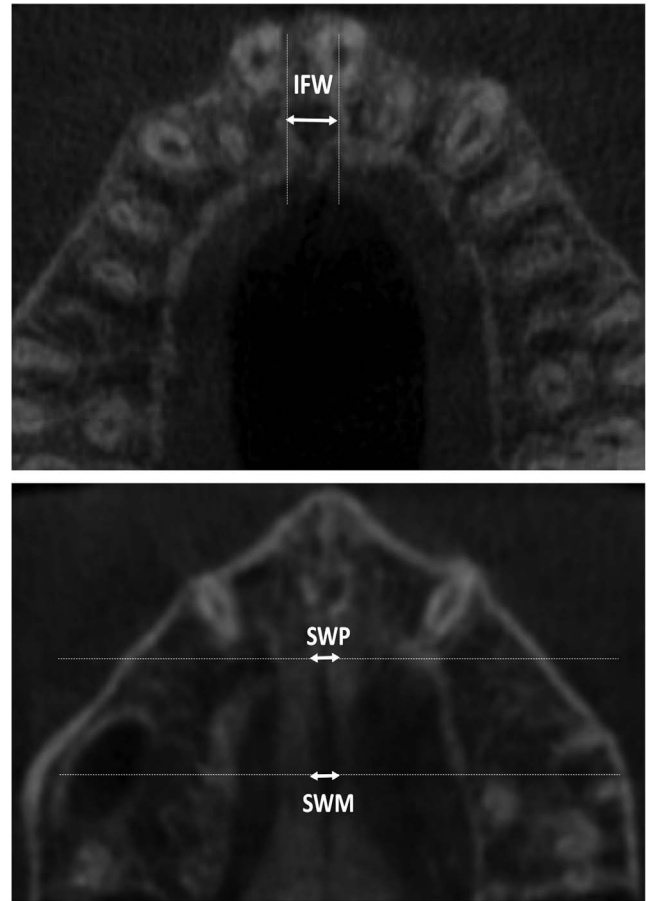
The present study followed the two-arm, parallel, randomized clinical trial design with a 1:1 allocation ratio. Approval for the study was granted by the Institutional Review Board of Ege University (11-10.1/76). Transverse maxillary constriction was diagnosed according to the intermaxillary width measured at the



**Figure 2.** Nasal cavity width measurement performed on the nasal floor between the maxillary first premolars (NCWP) and maxillary first molars (NCWM).

gingival border of the maxillary first molars at the mesiolingual cusp.<sup>17</sup> Inclusion criteria included individuals presenting with well-balanced facial ratios and normal growth pattern who were planned to have an 8-mm screw activation and had their first molars and premolars completely erupted at pretreatment. Individuals who had craniofacial anomalies, compliance problems, need for surgically assisted RME, and previous orthodontic treatment history were excluded. The sample size was determined by using the mean skeletal expansion measured at the level of first molars using a preliminary study. The effect size was calculated with the G\*Power 3.1 statistical program (Heinrich Heine Universität Dusseldorf Institute für Experimentelle Psychologie, Dusseldorf, Germany). It was estimated that to detect significant differences ( $P < .05$ , effect size  $d = 0.94$ , and with 80% power) between the two groups, 15 individuals would be required in each group. Twenty individuals were recruited for each group to ensure the power in case of any dropouts.

Patients were randomly assigned to one of the two treatment groups via a block randomization procedure with a block size of four, using a computer-generated list of random numbers. The allocation sequence was concealed from the orthodontist, researchers, and the



**Figure 3.** The widest intercortical distance of the incisive foramen as measured perpendicular to the intermaxillary suture (IFW). Intermaxillary suture width measured between the right and left cortical border at the anteroposterior position of maxillary first premolars (SWP) and first molars (SWM).

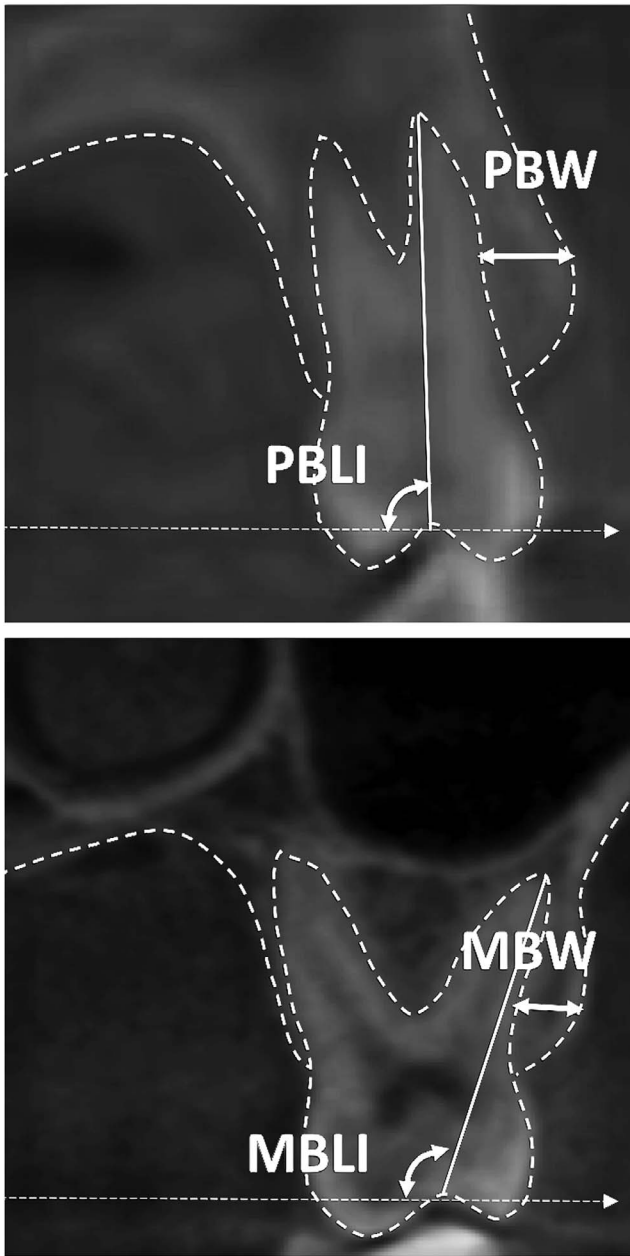
patients. When a patient was deemed as eligible for enrollment, the patient was assigned to a treatment group using opaque and sealed envelopes containing the allocation number. The mean age and sex distribution of the sample groups are presented in Table 1. All individuals were treated by a single practitioner (Dr Celenk-Koca). The primary outcome of the study was the correction of crossbite with the palatal cusp of the maxillary first molar touching the buccal cusp tips of the mandibular first molar.

Conventional and study groups were treated with Hyrax-type and miniscrew-supported RME devices, respectively (Figure 1). Four miniscrews (1.8 mm × 9 mm, Orlus, Ortholution Co, Seoul, Korea) were placed

**Table 1.** Sex and Age Distribution in the Study Groups

	Group 1 (Conventional RME)	Group 2 (Miniscrew-Supported RME)
Age, y	13.84 ± 1.36	13.81 ± 1.23
Sex	12 female, 8 male	13 female, 7 male





**Figure 4.** Buccal width measurements obtained at the level of the maxillary first premolar bifurcation (PBW) and maxillary first molar trifurcation (MBW). Buccolingual inclinations of the maxillary first premolars (PBLI) and first molars (MBLI) measured using the inclinations of the buccal and mesiobuccal roots, respectively, to the horizontal plane projected from the nasal floor.

6–8 mm palatal to the gingival margin of the teeth with a perpendicular insertion into the alveolar bone between the roots using a contra-angle driver (Unitek REF 504-315, 3M Unitek, Monrovia, Calif). Anterior implants were placed bilaterally between the roots of the first and second premolars, and posterior implants were placed between the roots of the second premolars and first molars. Using an indirect impression technique, extension arms of the Hyrax expansion screws were fitted and laser welded on the copings in the laboratory. During delivery, appliances were inserted mechanically on the miniscrew heads and friction retained. Appliances in both groups were activated by two turns a day. The average activation time was  $19.7 \pm 3.8$  days for the study sample. Since it was impossible to blind the patient and orthodontist to the treatment groups, the researcher who traced the cone-beam computed tomography (CBCT) images and the statistician who evaluated the data were blinded.

The CBCT images were acquired at pretreatment (T1) and at 6 months (T2) following a passive retention period using the same appliances. No fixed appliances were used between T1 and T2. Images were captured with exposure parameters of 70 kV, 10 mA, 32.5 seconds, 76- $\mu$ m voxel size, and with volume dimensions of 8 cm  $\times$  8 cm (CS 9000 3D, Carestream Health, Inc, Rochester, NY). DICOM files were opened with OsiriX Imaging Software version 6.5 (Pixmeo SARL, Bernex, Switzerland). CBCT scans were reoriented as perpendicular to the midpalatal suture (axial slice), parallel to the palatal plane (ANS-PNS, sagittal slice), and tangent to the nasal floor at its most inferior level (coronal slice). Coronal slices were used to measure the nasal cavity width at the base between the maxillary first premolar and first molar roots (Figure 2). Axial slices were used to measure the incisive foramen width at its widest sectional view and intermaxillary suture width between the right and left cortices at the anteroposterior positions of the maxillary first premolars and first molars (Figure 3). In addition, coronal slices were obtained by registering the multiplanar sections on the bifurcation and trifurcation of the maxillary first premolars and maxillary first molars, respectively. These slices were used to assess the premolar and molar buccal width and premolar and molar buccolingual inclination for the maxillary first

**Table 2.** Comparison of Total Maxillary Expansion Between the Groups

Variable	Expansion Group	T1, mm (Mean $\pm$ SD)	T2, mm (Mean $\pm$ SD)	<i>P</i> (T1-T2)	$\Delta$ (Expansion), mm (Mean $\pm$ SD)	<i>P</i>
Premolar width	Conventional	23.7 $\pm$ 3.0	28.2 $\pm$ 2.6	<.001*	4.5 $\pm$ 2.5	.51
	Bone-borne	21.8 $\pm$ 2.5	27.0 $\pm$ 2.2	<.001*	5.1 $\pm$ 3.2	
Molar width	Conventional	30.3 $\pm$ 4.2	34.6 $\pm$ 4.6	<.001*	4.2 $\pm$ 1.7	.52
	Bone-borne	29.7 $\pm$ 2.7	34.3 $\pm$ 2.8	<.001*	4.5 $\pm$ 1.3	

\* *P* < .05.

**Table 3.** Comparison of Skeletal Differences Between Groups

Variable	Expansion Group	T1, mm (Mean ± SD)	T2, mm (Mean ± SD)	P (T1-T2)	Δ (Expansion), mm (Mean ± SD)	P Value
NCWP	Conventional	14.7 ± 3.1	16.5 ± 3.3	<.001*	1.8 ± 1.7	.078
	Bone-borne	13.7 ± 3.7	16.5 ± 3.7	<.001*	2.8 ± 1.8	
NCWM	Conventional	20.9 ± 3.2	22.2 ± 3.0	<.001*	1.2 ± 1.1	.001*
	Bone-borne	20.3 ± 2.1	23.2 ± 2.3	<.001*	2.9 ± 1.7	
IFW	Conventional	3.3 ± 1.0	4.7 ± 1.0	<.001*	1.4 ± 0.8	.000*
	Bone-borne	3.4 ± 0.6	6.6 ± 1.2	<.001*	3.2 ± 0.9	
SWP	Conventional	1.2 ± 0.5	2.5 ± 0.7	<.001*	1.3 ± 0.7	.000*
	Bone-borne	0.9 ± 0.2	4.6 ± 1.2	<.001*	3.6 ± 1.2	
SWM	Conventional	0.9 ± 0.6	2.0 ± 0.6	<.001*	1.1 ± 0.4	.000*
	Bone-borne	0.8 ± 0.2	3.9 ± 1.3	<.001*	3.1 ± 1.3	

\* P < .05.

premolar and molars (Figure 4). Buccal width measurements were made from the outermost point of the bone to the roots at the level of furcation point. Buccolingual inclination measures of the maxillary first premolars and first molars were performed using the inclinations of buccal and mesiobuccal roots, respectively, to a horizontal line parallel to the nasal floor.

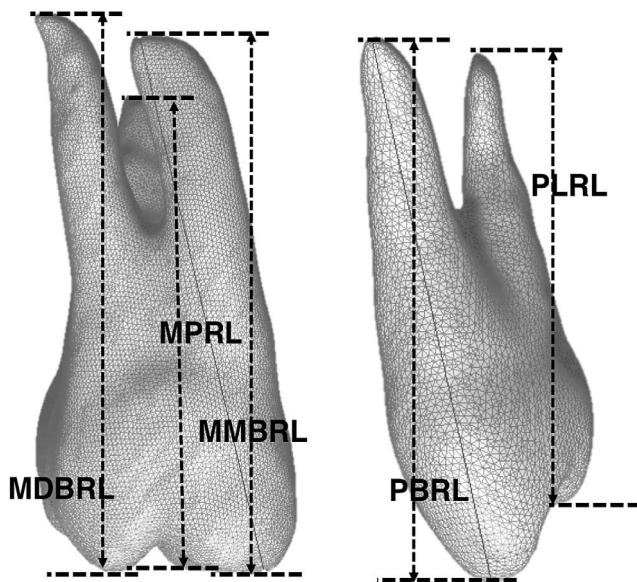
The CBCT scans were sectioned to view the roots of the maxillary first premolars and molars individually. Root length measurements were made for maxillary first premolar buccal and lingual and maxillary first molar mesial-buccal, distal-buccal, and palatal roots from the cusp tip to the apex (Figure 5). One investigator (Dr Harris) was responsible for all the measurements. The CBCT scans of 10 randomly selected patients were reexamined at 4-week intervals to calculate the error study using Dahlberg’s formula. Statistical analysis was performed using IBM SPSS

Statistics version 25 (IBM Corp, Armonk, NY). According to the Shapiro-Wilk test, the data had normal distribution ( $P > .05$ ). Levene’s test verified that the group variances were equal ( $P > .05$ ). The changes in each group were evaluated with paired *t*-tests. In addition, the mean differences for each variable were compared using an independent-sample *t*-test between the study groups. The level of significance was set at  $P < .05$ .

**RESULTS**

The method error ranged from 0.1–0.4 mm and 0.2°–0.6° for the linear and angular measurements, respectively. Right- and left-side measurements of molars and premolars did not show any significant difference and were averaged for the rest of the statistical analysis. Although the bone-borne RME group produced slightly greater increases of 0.6 mm and 0.3 mm in both interpremolar and intermolar dental widths, no significant differences were noted between the two groups (Table 2).

Differences between the bone-borne RME and conventional RME groups were significant for nasal cavity width measured at the base between the maxillary first molars ( $P < .05$ ), incisive foramen width ( $P < .05$ ), and sutural width measured between the maxillary first premolars and maxillary first molars ( $P < .05$ ; Table 3). Between the maxillary first premolars, the ratios of sutural expansion to the total increase in maxillary width were 28% and 70% in the tooth-borne and bone-borne expander groups, respectively. Similarly, 26% and 68% of the total expansion was of skeletal nature in the tooth-borne and bone-borne expander groups between the maxillary first molars. Most of the patients in both groups demonstrated a



**Figure 5.** Individual length measurements made for maxillary first premolar buccal (PBRL) and lingual (PLRL), and maxillary first molar mesial-buccal (MMBRL), distal-buccal (MDBRL), and palatal (MPRL) roots from the cusp tip to the apex.

**Table 4.** Shape Evaluation of the Intermaxillary Suture Opening in the Sample

Shape	Wider Posteriorly	Parallel	Wider Anteriorly
Tooth-borne group	7 (35%)	2 (10%)	11 (55%)
Bone-borne group	6 (30%)	5 (25%)	9 (45%)

**Table 5.** Comparison of Buccal Bone Width Differences Between Groups

Variable	Expansion Group	T1, mm (Mean ± SD)	T2, mm (Mean ± SD)	<i>P</i> (T1–T2)	Δ (Expansion), mm (Mean ± SD)	<i>P</i> Value
PBW	Conventional	0.9 ± 0.5	0.6 ± 0.5	<.001*	–0.29 ± 0.2	.003*
	Bone-borne	0.9 ± 0.5	0.8 ± 0.6	.41	–0.04 ± 0.2	
MBW	Conventional	1.2 ± 0.7	1.0 ± 0.8	<.001*	–0.24 ± 0.2	.046*
	Bone-borne	1.0 ± 0.6	0.9 ± 0.5	.01*	–0.10 ± 0.1	

\* *P* < .05.

triangular-shaped opening of the suture that was wider anteriorly (Table 4).

Both study groups showed decreases in buccal bone width at the level of maxillary first premolars and first molars (Table 5). However, the bone-borne RME group experienced significantly less buccal bone loss than the conventional group for both the premolars and molars (*P* < .05). Premolar root inclination measurements from the conventional RME group demonstrated a mean buccal crown tipping of 4.5° (Table 6), whereas the bone-borne RME group produced 0.6° of lingual crown tipping. Molar root angulation changes revealed 3.9° buccal and 1.3° of lingual crown tipping in the conventional and bone-borne RME groups, respectively. The differences between the two groups were significant (*P* < .05). Premolar and molar root lengths remained virtually stable for the duration of expansion in both groups, and no significant differences were observed between the two groups (Table 7).

## DISCUSSION

In a group of adolescents, similar increases in premolar and molar interdental widths were achieved using tooth-borne and bone-borne RME appliances. However, the nature of skeletal and dental changes was notably different between the groups. Bone-borne expanders significantly increased the skeletal separation of the midpalatal suture. Therefore, the null hypothesis was rejected.

Significant differences were observed between the two groups for all skeletal variables, except the nasal cavity width measurement at the level of maxillary first premolars. The conventional Hyrax group had a greater width increase at the incisive foramen and a smaller one at the level of the maxillary first molar, confirming the commonly documented wedge-shaped

opening of the suture.<sup>18</sup> Conversely, the bone-borne RME had the greatest gain in the premolar region and very similar width increases in the incisive foramen and molar suture, revealing a more parallel sutural opening. However, most of the subjects in both groups had a more triangular opening of the suture that was wider anteriorly. This behavior of the suture was originally noted in the classic work of Haas<sup>19</sup> with expansion forces being directed closer to the bone. The bone-borne RME group in the current study produced more skeletal separation, following suit to previously introduced miniscrew-supported RME appliances facilitating the direct transfer of expansion forces to the palate.<sup>14,15,20,21</sup> This is an ideal outcome because a true increase in transverse width of the basal bone in cases with maxillary transverse deficiency is essential to the ideal finishing of the case. Heavy stainless-steel wires used in the final stages of comprehensive orthodontic treatment would introduce negative torque to the posterior teeth, restoring the ideal buccolingual inclinations of the teeth and possibly decreasing the amount of expansion previously gained by tipping of the posterior teeth buccally.<sup>7</sup>

Decreased buccal bone and bony dehiscence are commonly documented as a result of RME due to osteoclastic resorption as teeth move through the buccal plate.<sup>3,7,22,23</sup> The current results indicated that changes in the buccal bone occurred significantly less frequently in the miniscrew-supported appliance group than in the tooth-borne group. Considering the error study, it could be concluded that the buccal bone widths remained virtually stable in the bone-borne group. As previous reports already hypothesized, the differences between the two groups were most likely due to the absence of direct force application to the tooth crowns in the miniscrew-supported RME group.<sup>20,21</sup>

**Table 6.** Comparison of Buccolingual Inclination (Tipping) Changes Between Groups

Variable	Expansion Group	T1, ° (Mean ± SD)	T2, ° (Mean ± SD)	<i>P</i> (T1–T2)	Δ (Tipping), ° (Mean ± SD)	<i>P</i> Value
PBLI	Conventional	92.2 ± 5.8	87.7 ± 6.4	<.001*	–4.5 ± 3.0	.000*
	Bone-borne	91.4 ± 4.9	92.1 ± 4.7	.25	0.6 ± 2.4	
MBLI	Conventional	98.8 ± 5.0	94.8 ± 5.2	<.001*	–3.9 ± 3.4	.000*
	Bone-borne	100.0 ± 5.0	101.4 ± 4.1	.01*	1.3 ± 2.1	

\* *P* < .05.



**Table 7.** Comparison of Root Length Differences Between Groups

Variable	Expansion Group	T1, mm (Mean ± SD)	T2, mm (Mean ± SD)	P (T1–T2)	Δ (Root Length), mm (Mean ± SD)	P Value
PBRL	Conventional	20.8 ± 2.1	20.7 ± 2.1	.5	−0.10 ± 0.2	.45
	Bone-borne	20.1 ± 1.6	20.1 ± 1.7	.4	0.03 ± 0.2	
PLRL	Conventional	19.8 ± 1.7	19.7 ± 1.7	.2	−0.11 ± 0.3	.29
	Bone-borne	19.4 ± 1.6	19.3 ± 1.7	.4	−0.02 ± 0.1	
MMBRL	Conventional	19.0 ± 1.6	18.8 ± 1.6	.01*	−0.13 ± 0.2	.28
	Bone-borne	19.0 ± 1.6	18.9 ± 1.6	.03*	−0.07 ± 0.1	
MDBRL	Conventional	18.7 ± 1.4	18.5 ± 1.4	<.001*	−0.19 ± 0.2	.40
	Bone-borne	19.2 ± 1.9	18.9 ± 1.7	<.001*	−0.26 ± 0.2	
MPRL	Conventional	20.8 ± 1.4	20.6 ± 1.5	<.001*	−0.26 ± 0.2	.34
	Bone-borne	21.0 ± 2.0	20.8 ± 1.9	<.001*	−0.19 ± 0.1	

\*  $P < .05$ .

Buccolingual inclination changes of the maxillary first premolar and first molar in the conventional RME group demonstrated buccal crown tipping of 4.5° and 3.9°, respectively. Significant buccal tipping of posterior teeth is a significant hallmark of RME therapy, with dental tipping often outweighing translation from the forces placed upon the teeth.<sup>5,7,24,25</sup> In the current study, tipping of the maxillary first molars in the bone-borne RME group was significantly reduced in comparison with the conventional RME group. The decrease in the amount of buccal tipping of first molars is consistent with previous bone-borne expansion studies.<sup>20,21</sup> Also, maxillary first premolars and first molars were up-righted by a mean of 0.6° and 1.3°, respectively. Uprighting of the maxillary first premolars and first molars could be explained by the absence of a buccal force acting on the crowns and increased apical separation of the maxillary suture in the miniscrew-supported RME group, leading to a more upright crown inclination relative to the nasal floor.

The findings failed to demonstrate any significant changes to the roots of the anchor teeth in the study groups. The mean changes in the length of the maxillary first premolars and molars fell in the range of +0.43 mm to −0.39 mm. In a clinically successful RME application, theoretically, no significant changes should occur to the roots because the orthopedic force used during the expansion procedure is intended to separate the maxillary suture. However, findings from classic<sup>26</sup> and more recent research studies<sup>11,12,27</sup> suggested the increased possibility of root surface changes and resorption following tooth-borne RME therapy as compared with other alternatives. Since RME therapy is composed of using heavy buccally directed forces, most root resorption occurs on the buccal surface of the roots<sup>11,26,28</sup> in the form of small irregularly shaped lacunae. Within the limitations of this study, it may be concluded that RME applications, whether tooth- or bone-borne, had no significant effects on the root length. Further evaluations of the tooth morphology, in this context, are warranted.

## CONCLUSIONS

In an adolescent population:

- The bone-borne expansion group had almost three times greater expansion in the midpalatal suture than did the tooth-borne group.
- Bone-borne expansion resulted in uprighting of the maxillary posterior teeth with significant benefit to the buccal alveolar bone support.
- No difference was observed in root length changes between the bone-borne and tooth-borne expansion groups.

## REFERENCES

1. Hansen L, Tausche E, Hietschold V, Hotan T, Lagravère M, Harzer W. Skeletally-anchored rapid maxillary expansion using the Dresden Distractor. *J Orofac Orthop*. 2007;68:148–158.
2. Bazargani F, Feldmann I, Bondemark L. Three-dimensional analysis of effects of rapid maxillary expansion on facial sutures and bones. *Angle Orthod*. 2013;83:1074–1082.
3. Garib DG, Henriques JF, Janson G, Freitas MR, Coelho RA. Rapid maxillary expansion—tooth tissue-borne versus tooth-borne expanders: a computed tomography evaluation of dentoskeletal effects. *Angle Orthod*. 2005;75:548–557.
4. Rungcharassaeng K, Caruso JM, Kan JY, Kim J, Taylor G. Factors affecting buccal bone changes of maxillary posterior teeth after rapid maxillary expansion. *Am J Orthod Dentofacial Orthop*. 2007;132:428.e1–428.e8.
5. Christie KF, Boucher N, Chung CH. Effects of bonded rapid palatal expansion on the transverse dimensions of the maxilla: a cone-beam computed tomography study. *Am J Orthod Dentofacial Orthop*. 2010;137:S79–S85.
6. Pangrazio-Kulbersh V, Wine P, Haughey M, Pajtas B, Kaczynski R. Cone beam computed tomography evaluation of changes in the naso-maxillary complex associated with two types of maxillary expanders. *Angle Orthod*. 2012;82:448–457.
7. Akyalcin S, Schaefer JS, English JD, Stephens CR, Winkelmann S. A cone-beam computed tomography evaluation of buccal bone thickness following maxillary expansion. *Imaging Sci Dent*. 2013;43:85–90.
8. Pangrazio-Kulbersh V, Jezdimir B, de Deus Haughey M, Kulbersh R, Wine P, Kaczynski R. CBCT assessment of

- alveolar buccal bone level after RME. *Angle Orthod.* 2013;83:110–116.
9. Brunetto M, Andriani Jda S, Ribeiro GL, Locks A, Correa M, Correa LR. Three-dimensional assessment of buccal alveolar bone after rapid and slow maxillary expansion: a clinical trial study. *Am J Orthod Dentofacial Orthop.* 2013;143:633–644.
  10. Baysal A, Karadede I, Hekimoglu S, et al. Evaluation of root resorption following rapid maxillary expansion using cone-beam computed tomography. *Angle Orthod.* 2012;82:488–494.
  11. Akyalcin S, Alexander SP, Silva RM, English JD. Evaluation of three-dimensional root surface changes and resorption following rapid maxillary expansion: a cone beam computed tomography investigation. *Orthod Craniofac Res.* 2015;18(suppl 1):117–126.
  12. Xu X, Zhou J, Yang F, Wei S, Dai H. Using micro-computed tomography to evaluate the dynamics of orthodontically induced root resorption repair in a rat model. *PLoS One.* 2016;11(3):e0150135.
  13. Lagravère MO, Carey J, Heo G, Toogood RW, Major PW. Transverse, vertical, and anteroposterior changes from bone-anchored maxillary expansion vs. traditional rapid maxillary expansion: a randomized clinical trial. *Am J Orthod Dentofac Orthop.* 2010;137:304–305.
  14. Mosleh MI, Kaddah MA, Abd ElSayed FA, ElSayed HS. Comparison of transverse changes during maxillary expansion with 4-point bone-borne and tooth-borne maxillary expanders. *Am J Orthod Dentofacial Orthop.* 2015;148:599–607.
  15. Lin L, Ahn HW, Kim SJ, Moon SC, Kim SH, Nelson G. Tooth-borne vs bone-borne rapid maxillary expanders in late adolescence. *Angle Orthod.* 2015;85:253–262.
  16. Vassar JW, Karydis A, Trojan T, Fisher J. Dentoskeletal effects of a temporary skeletal anchorage device-supported rapid maxillary expansion appliance (TSADRME): a pilot study. *Angle Orthod.* 2016;86:241–249.
  17. English JD, Akyalcin S, Peltomaki T, Litschel K. *Mosby's Orthodontic Review.* 2nd ed. St Louis, Mo: Mosby.
  18. Wertz R, Dreskin M. Midpalatal suture opening: a normative study. *Am J Orthod.* 1977;71:367–381.
  19. Haas AJ. Rapid expansion of the maxillary dental arch and nasal cavity by opening the midpalatal suture. *Angle Orthod.* 1961;31:73–90.
  20. Hansen L, Tausche E, Hietschold V, Hotan T, Lagravère M, Harzer W. Skeletally-anchored rapid maxillary expansion using the Dresden Distractor. *J Orofac Orthop.* 2007;68:148–158.
  21. Tausche E, Hansen L, Hietschold V, Lagravère MO, Harzer W. Three-dimensional evaluation of surgically assisted implant bone-borne rapid maxillary expansion: a pilot study. *Am J Orthod Dentofac Orthop.* 2007;131:S92–S98.
  22. Garib DG, Henriques JF, Janson G, de Freitas MR, Fernandes AY. Periodontal effects of rapid maxillary expansion with tooth-tissue-borne and tooth-borne expanders: a computed tomography evaluation. *Am J Orthod Dentofac Orthop.* 2006;129:749–758.
  23. Melsen B. Biological reaction of alveolar bone to orthodontic tooth movement. *Angle Orthod.* 1999;69:151–158.
  24. Phatouros A, Goonewardene MS. Morphologic changes of the palate after rapid maxillary expansion: a 3-dimensional computed tomography evaluation. *Am J Orthod Dentofac Orthop.* 2008;134:117–124.
  25. Lione R, Franchi L, Cozza P. Does rapid maxillary expansion induce adverse effects in growing subjects? *Angle Orthod.* 2013;83:172–182.
  26. Langford SR, Sims MR. Root surface resorption, repair, and periodontal attachment following rapid maxillary expansion in man. *Am J Orthod.* 1982;81:108–115.
  27. Dindaroğlu F, Doğan S. Evaluation and comparison of root resorption between tooth-borne and tooth-tissue borne rapid maxillary expansion appliances: a CBCT study. *Angle Orthod.* 2016;86:46–52.
  28. Odenrick L, Karlander EL, Pierce A, Kretschmar U. Surface resorption following two forms of rapid maxillary expansion. *Eur J Orthod.* 1991;13:264–270.