

Palatal Bone Density in Adult Subjects: Implications for Mini-Implant Placement

Sung Hee Moon^a; Sun Hyung Park^b; Won Hee Lim^c; Youn Sic Chun^d

ABSTRACT

Objectives: To evaluate palatal bone density to allow for better selection of palatal implant anchorage sites.

Materials and Methods: Computed tomographic (CT) images were obtained from 15 males and 15 females (mean age, 27 years; range, 23–35 years). Bone density was measured in Hounsfield units (HU) at 80 coordinates at regular mediolateral and anteroposterior intervals along the midpalatal suture.

Results: Bone densities ranged from 805 to 1247 HU. A significant difference between male and female groups was noted, although no difference was found between left and right sides of individual palates. Palatal bone densities showed a tendency to decrease laterally and posteriorly. The midpalatal area within 3 mm of the midsagittal suture had the densest bone in the entire palate.

Conclusion: Results suggest that mini-implants for orthodontic anchorage may be effectively placed in most areas with bone density equivalent to the palatal area if they are placed from 3 mm posterior to the incisive foramen and 1 to 5 mm to the paramedian side. (*Angle Orthod.* 2010; 80:137–144.)

KEY WORDS: Bone density; Palate; Mini-implant

INTRODUCTION

Mini-implants are a valuable alternative to extraoral anchorage and offer several advantages. They require minimal compliance on behalf of the patient and provide a simple, convenient, and relatively low-cost method for providing absolute anchorage.¹ Many intraoral sites can be used for mini-implant placement; however, the palate is a frequently used site because it is easily accessible, is relatively safe to work on, is less susceptible to inflam-

mation, and has good bone quantity. In orthodontic treatment, the midpalatal area or the paramedian site is used frequently for mini-implant anchorage.² The paramedian area may be a suitable site in cases where the midpalatal suture is to be avoided.³

The preferred area for mini-implant placement in the palate is the midpalatal area between the first premolars.⁴ Failure of mini-implants due to the presence of thin cortical bone in the posterior part of the midpalate at the level of the second premolars has been reported.⁴ Occasionally, successful anchorage requires reimplantation of mini-implants into the midsagittal palate between the first premolars. Previous studies indicate that a certain amount of bone volume is critical for implant stability.^{5,6} It has also been reported that a suitable bone thickness of the palate for mini-implants should be greater than 4 mm.⁷

The success of mini-implants has been commonly reported to range between 70% and 89%. For mini-implants placed in the palate, however, success rates near 100% have been reported, although the comparison of different studies had its limitations.^{8,9} Bone quality and quantity play important roles in the success of mini-implants.¹⁰ Thus, knowledge of osseous conditions in the area of interest will allow clinicians to

^a Graduate student, Graduate School of Clinical Dentistry, Ewha Womans University, Seoul, Korea.

^b Assistant Professor, Division of Orthodontics, Department of Dentistry, Ewha Womans University, Seoul, Korea.

^c Assistant Professor, Department of Orthodontics, School of Dentistry & Dental Research Institute, Seoul National University, Seoul, Korea.

^d Professor, Division of Orthodontics, Department of Dentistry, Ewha Womans University, Seoul, Korea.

Corresponding author: Dr Youn Sic Chun, Division of Orthodontics, Department of Dentistry, Ewha Womans University, Seoul, Korea. 911-1 Mokdong, Yangcheon-gu, Seoul 158-710 Korea (e-mail: yschun@ewha.ac.kr)

Accepted: March 2009. Submitted: January 2009.

© 2010 by The EH Angle Education and Research Foundation, Inc.

make more informed decisions in mini-implant placement. Many studies have assessed bone quantity in the palate, but only a few have examined palatal bone densities.^{5-7,11} Therefore, the purpose of this study was to quantitatively evaluate bone density in the palate so as to provide guidelines for mini-implant placement that are essential for implant site selection and implant success prediction.

MATERIALS AND METHODS

Thirty subjects (15 men and 15 women; mean age, 27.3 years; range, 23–35 years) volunteered to participate in this study and gave informed consent. Exclusion criteria included severe skeletal abnormalities, facial asymmetry, anomalies, asymmetric occlusions, absence of any permanent teeth except for the third molars, impacted teeth, moderate to severe crowding, and any systemic illness. The study protocol was approved by the Ewha Womans University Mokdong Hospital Ethics Committee, Seoul, South Korea.

Computed tomography (CT) images (SOMATOM Sensation, Siemens AG, Erlangen, Germany) were obtained at 200 mm field of view, 120 kV, 200 mAs, with rotation scanning time of 0.5 s, average radiation exposure dose of 31.32 CTDIvol, and slice thickness of 1.0 mm, in a high-resolution mode. Head posture was maintained without tilting to either side to minimize measurement errors. CT images were saved as Digital Imaging and Communications in Medicine (DICOM) files and then were analyzed with the use of V-works imaging software (Cybermed, Seoul, Korea).

Coordinates for measurement were modified from those used in the previous study.¹¹ Palatal bone density was measured at 90 separate coordinates at intervals of 2 mm mediolaterally (ML) and 3 mm anteroposteriorly (AP). ML intervals on both sides were successively marked ML = 1 to 5 and AP grids as AP = 1 to 9 (Figure 1A). Measurement of the density was performed perpendicular to a horizontal plane that contained a midsagittal reference line through the middle of the distal margin of the incisive foramen and the posterior nasal spine (Figure 1B). V-works imaging software was used to map and display bone density in regions of interest (Figure 1B). The x-coordinate was manually set to the posterior bony margin of the incisive foramen and then was moved in 3-mm increments posteriorly. Increments of 0.5 mm in the x-coordinate were used in this program. For example, if the x-axis is set at the posterior bone margin of the incisive foramen with an x-axis coordinate of 220, the 3-mm level from the incisive foramen will have an x-axis coordinate of 226. At each level, the x-coordinate was held constant and the y-coordinate varied to measure bone density. Bone density was measured using Hounsfield units (HU), which are directly as-

sociated with tissue attenuation coefficients. The center value, among multiple adjacent HU readings, was selected as the cortical bone density value for each point.

During a preliminary study, the center value among multiple adjacent values was close to the mean of the multiple values (data not shown). Based on the outcomes from a preliminary study and those from a previous study where center values were selected, the center value was chosen for use in this study.¹² In addition to determining HU units, the palatal bone was categorized according to the D1–D5 Misch and Kircos bone density classification system. D1 was defined as densities greater than 1250 HU, D2 as 850–1250 HU, D3 as 350–850 HU, D4 as 150–350 HU, and D5 as <150 HU.¹³

To evaluate intraexaminer reproducibility, the same examiner remeasured five randomly selected subjects for all points following a 2-week interval.

Statistical Analysis

After the statistical tests for gender differences and left vs right side differences were performed, two-way analysis of variance (ANOVA) and the Student's-Newman-Keuls test for multiple comparisons were performed. The significance level was set at $P < .05$, so differences at different sites could be identified.

RESULTS

So that intraexaminer reproducibility could be evaluated, five randomly selected sites were remeasured by the same examiner following a 2-week interval. Evaluation with a *t*-test showed no statistically significant difference in measurements between the two time points.

Before site differences were evaluated, gender and side-based differences in bone density were assessed. Evaluation with a *t*-test revealed statistically significant differences between male and female subjects, with greater values found in the female group ($P < .05$); no differences between left and right sides of the palate were found with the use of paired *t*-tests ($P > .05$). Based on the results of these tests, data from left and right sides were combined. Palatal bone density ranged between 805 and 1247 HU (Table 1). Additionally, a large amount of variation between male and female groups was observed at all sites (Tables 2 and 3). Bone density tended to decrease from anterior to posterior areas and from middle to lateral areas of the palate (Figures 2 and 3).

Bone densities increased from AP = 1 to AP = 2 and then decreased at most ML positions. In particular, the increased amount of bone density at ML = 1, from AP = 1 to AP = 2, was significantly greater compared with other ML sites. Bone densities at ML = 2

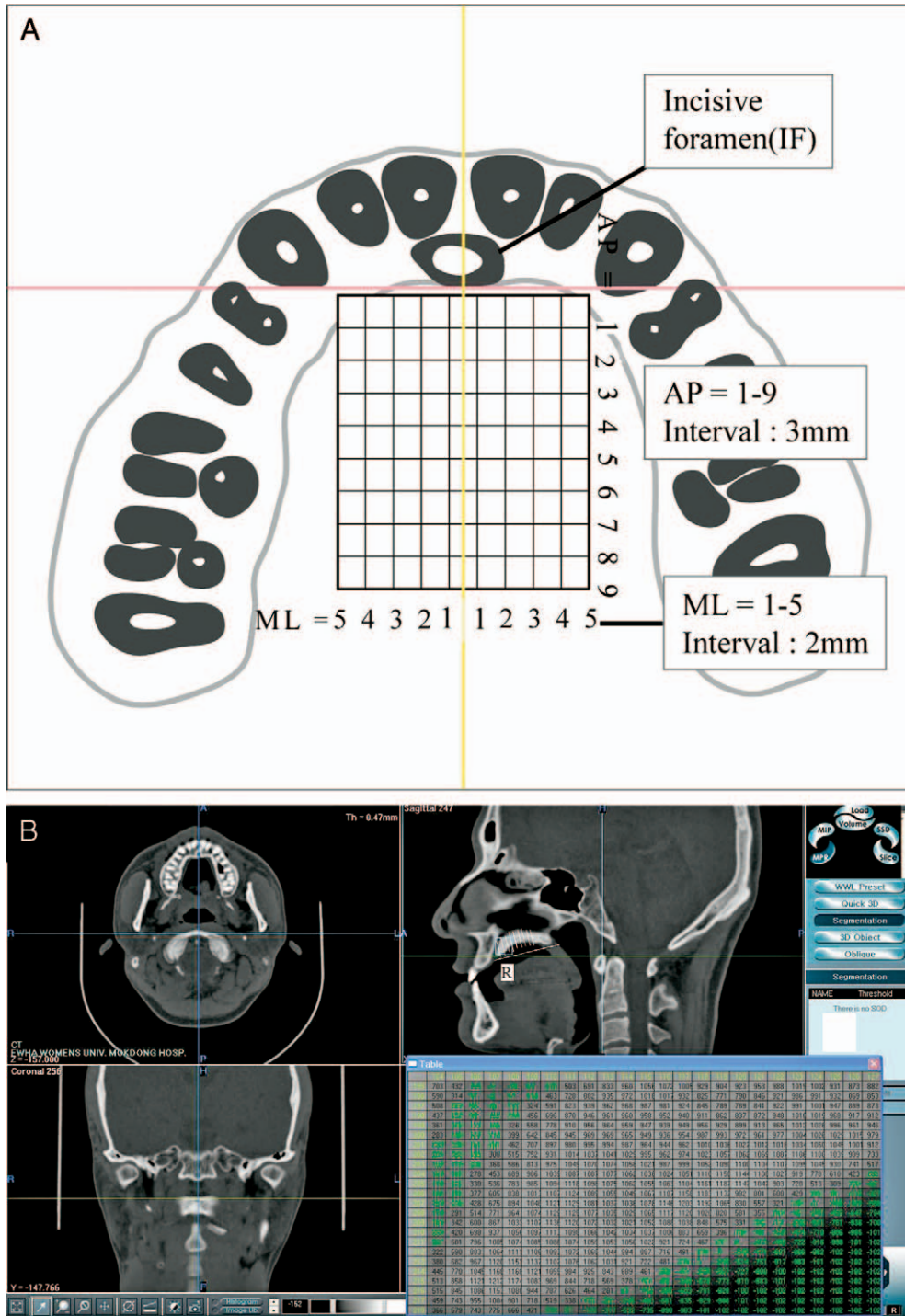


Table 1. Mean Value of Palatal Bone Density (unit: Hounsfield)^a

AP, mm	ML				
	5	4	3	2	1
1	1097.34 ^{b,c,g} (122.40)	1097.86 ^{b,g} (145.70)	1144.88 ^{b,c,g} (139.91)	1206.66 ^h (169.69)	1038.68 ^{b,i} (93.37)
2	1146.67 ^{b,g} (106.85)	1131.07 ^{b,g} (105.87)	1167.52 ^{b,g} (127.97)	1247.02 ^h (113.10)	1214.96 ^{c,h} (114.79)
3	1110.70 ^{b,c,g} (131.50)	1120.93 ^{b,g} (149.45)	1161.79 ^{b,h} (147.69)	1209.30 ⁱ (127.95)	1188.29 ^{c,h,i} (124.22)
4	1073.59 ^{b,c,g} (187.35)	1094.43 ^{b,g} (181.75)	1159.64 ^{b,h} (173.63)	1193.25 ^h (155.12)	1168.29 ^{c,h} (125.34)
5	1008.39 ^{c,d,g} (199.12)	1087.41 ^{b,h} (198.75)	1170.39 ^{b,i} (168.59)	1200.80 ⁱ (143.80)	1160.50 ^{c,i} (104.64)
6	1012.14 ^{c,d,g} (247.92)	1072.11 ^{b,g} (203.88)	1188.64 ^{b,h} (183.86)	1205.80 ^h (134.12)	1161.32 ^{c,h} (107.01)
7	941.44 ^{d,e,g} (257.16)	1038.46 ^{b,h} (229.08)	1170.39 ^{b,i} (220.46)	1200.21 ⁱ (156.74)	1169.04 ^{c,i} (140.16)
8	868.75 ^{e,f,g} (231.69)	961.71 ^{c,h} (231.52)	1132.91 ^{b,c,i} (240.64)	1185.36 ⁱ (202.83)	1147.61 ^{c,i} (148.38)
9	805.17 ^{f,g} (218.80)	895.71 ^{d,h} (209.23)	1083.73 ^{c,i} (180.68)	1184.39 ⁱ (143.10)	1156.86 ^{c,i} (139.29)

^a ML (mediolateral) = 1 to 5 denote sections at distances of 1, 3, 5, 7, and 9 mm from the midsagittal line; AP (anteroposterior) = 1 to 9 denote sections at distances of 3, 6, 9, 12, 15, 18, 21, 24, and 27 mm posterior to the posterior bony margin of the incisive foramen along the incisive foramen–PNS line. Values in parentheses indicate standard deviations.

^{b,c,d,e,f} Difference letters indicate statistically significant differences among AP by two-way analysis of variance and Student's-Newman-Keuls test.

^{g,h,i,j} Difference letters indicate statistically significant differences among ML by two-way analysis of variance and Student's-Newman-Keuls test.

Table 2. Palatal Bone Density of Male Group (unit: Hounsfield)^a

AP, mm	ML				
	5	4	3	2	1
1	1082.21 ^{b,c,f} (149.48)	1064.43 ^{b,c,f} (169.17)	1121.79 ^{c,d,f} (147.58)	1197.57 ^{b,c,g} (174.15)	1065.43 ^{b,f} (92.92)
2	1145.57 ^{b,f} (114.15)	1135.32 ^{b,c,f} (113.30)	1159.46 ^{c,d,f} (127.64)	1268.68 ^b (122.57)	1235.00 ^{c,g} (131.74)
3	1151.00 ^{b,f} (136.93)	1154.89 ^{b,f} (148.50)	1193.68 ^{c,f} (131.52)	1222.46 ^{b,c,f} (134.14)	1219.43 ^{c,f} (146.00)
4	1062.43 ^{b,c,f} (200.08)	1116.89 ^{b,c,f,g} (160.31)	1177.14 ^{c,g} (153.88)	1192.00 ^{b,c,g} (142.93)	1197.57 ^{c,g} (125.02)
5	990.18 ^{c,d,f} (199.12)	1096.89 ^{b,c,g} (193.99)	1171.79 ^{c,g} (168.70)	1194.54 ^{b,c,g} (143.59)	1149.64 ^{b,c,g} (113.88)
6	962.82 ^{c,d,f} (286.75)	1055.39 ^{b,c,f,g} (210.49)	1191.96 ^{c,h} (188.68)	1199.18 ^{b,c,h} (134.94)	1151.71 ^{b,c,g,h} (111.49)
7	910.14 ^{d,f} (304.19)	1000.68 ^{c,d,f} (255.58)	1136.60 ^{c,d,g} (253.60)	1174.50 ^{b,c,g} (179.75)	1176.29 ^{c,g} (155.72)
8	841.25 ^{d,e,f} (293.26)	937.86 ^{d,e,f} (259.26)	1111.25 ^{c,d,g} (275.73)	1142.75 ^{c,g} (221.72)	1131.71 ^{b,c,g} (177.45)
9	754.35 ^{e,f} (234.89)	882.86 ^{e,g} (202.02)	1052.29 ^{c,h} (193.02)	1140.61 ^{c,h} (161.56)	1138.50 ^{b,c,h} (173.28)

^a ML (mediolateral) = 1 to 5 denote sections at distances of 1, 3, 5, 7, and 9 mm from the midsagittal line; AP (anteroposterior) = 1 to 9 denote sections at distances of 3, 6, 9, 12, 15, 18, 21, 24, and 27 mm posterior to the posterior bony margin of the incisive foramen along the incisive foramen–PNS line. Values in parentheses indicate standard deviations.

^{b,c,d,e} Difference letters indicate statistically significant differences among AP by two-way analysis of variance and Student's-Newman-Keuls test.

^{f,g,h} Difference letters indicate statistically significant differences among ML by two-way analysis of variance and Student's-Newman-Keuls test.

Table 3. Palatal Bone Density of Female Group (unit: Hounsfield)^a

AP, mm	ML				
	5	4	3	2	1
1	1112.46 ^{b,c,f} (90.99)	1131.29 ^{b,f} (114.29)	1167.96 ^{b,f,g} (133.14)	1215.75 ^{b,g} (171.17)	1011.93 ^{b,h} (89.07)
2	1147.79 ^{b,f} (103.35)	1126.82 ^{b,f} (101.99)	1175.57 ^{b,f,g} (132.59)	1225.36 ^{b,g} (102.63)	1194.93 ^{c,f,g} (95.65)
3	1070.39 ^{b,c,f} (116.91)	1086.96 ^{b,c,f} (147.84)	1129.89 ^{b,f,g} (160.67)	1196.14 ^{b,h} (125.03)	1157.14 ^{c,g,h} (92.97)
4	1084.75 ^{b,c,f} (180.55)	1071.96 ^{b,c,f} (204.51)	1142.14 ^{b,f,g} (195.65)	1194.50 ^{b,g} (171.89)	1139.00 ^{c,f,g} (123.09)
5	1026.61 ^{b,c,f} (186.20)	1077.93 ^{b,c,f} (210.27)	1169.00 ^{b,g} (174.84)	1207.07 ^{b,g} (149.15)	1171.36 ^{c,g} (97.55)
6	1061.46 ^{b,c,f} (200.48)	1088.82 ^{b,c,f} (203.53)	1185.32 ^{b,g} (185.97)	1212.43 ^{b,g} (135.05)	1170.93 ^{c,g} (105.62)
7	972.75 ^{c,d,f} (206.67)	1076.25 ^{b,c,g} (201.49)	1204.18 ^{b,h} (184.86)	1225.93 ^{b,h} (131.49)	1161.79 ^{c,g,h} (128.23)
8	896.25 ^{d,e,f} (154.47)	985.57 ^{c,d,f} (207.10)	1154.57 ^{b,g} (207.93)	1227.96 ^{b,g} (179.94)	1163.50 ^{c,g} (117.01)
9	856.00 ^{e,f} (196.69)	908.57 ^{d,f} (223.06)	1115.18 ^{b,g} (168.57)	1228.18 ^{b,g} (110.91)	1175.21 ^{c,g} (97.71)

^a ML (mediolateral) = 1 to 5 denote sections at distances of 1, 3, 5, 7, and 9 mm from the midsagittal line; AP (anteroposterior) = 1 to 9 denote sections at distances of 3, 6, 9, 12, 15, 18, 21, 24, and 27 mm posterior to the posterior bony margin of the incisive foramen along the incisive foramen–PNS line. Values in parentheses indicate standard deviations.

^{b,c,d,e} Difference letters indicate statistically significant differences among AP by two-way analysis of variance and Student's-Newman-Keuls test.

^{f,g,h} Difference letters indicate statistically significant differences among ML by two-way analysis of variance and Student's-Newman-Keuls test.

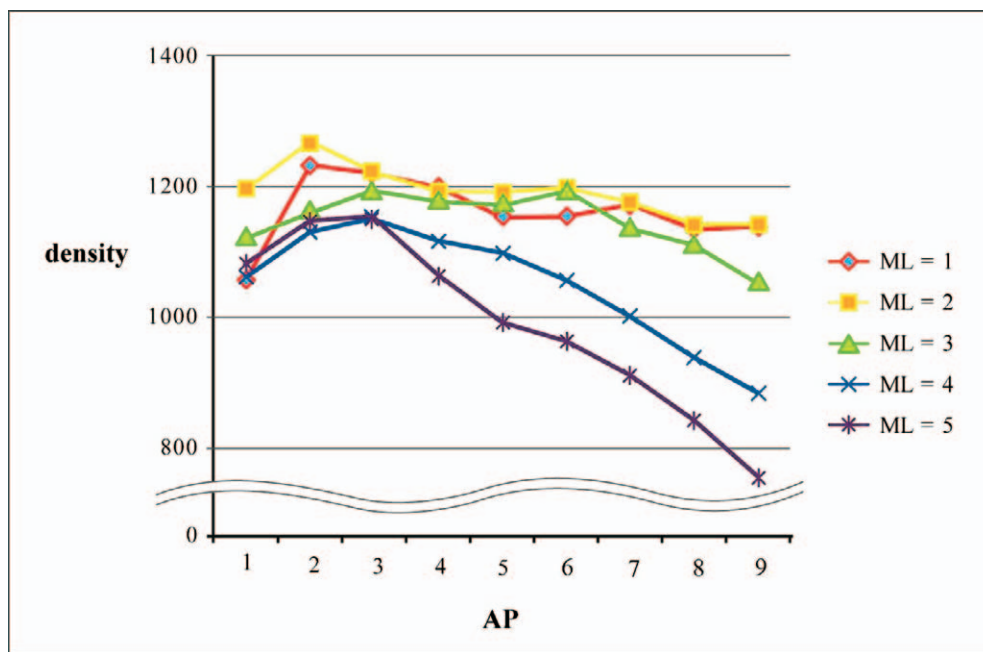


Figure 2. Average bone density in the male group.

chorage has led to expansion of the use of mini-implants. Among other factors related to the stability of mini-implants, anatomic location has been reported to be critical.⁸⁻¹⁰ Clinical evidence of the importance of bone quantity at the implant location has been found,

although insufficient information is available on the effects of bone density.

In the present study, bone density was measured in the midpalatal area and its vicinity posterior to the incisive foramen. Our measurements were performed at

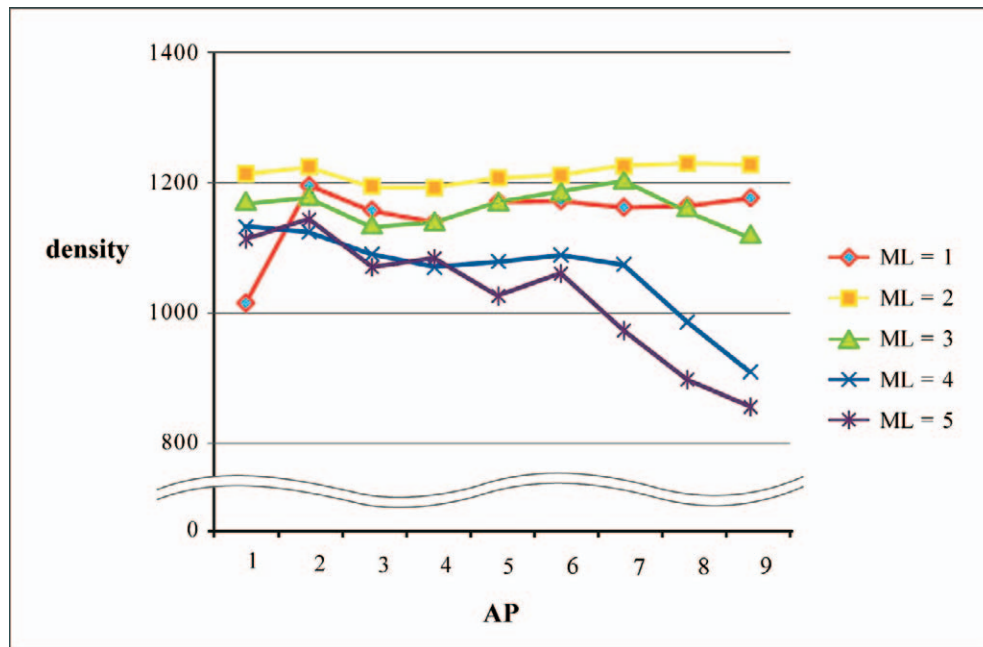


Figure 3. Average bone density in the female group.

locations 1, 3, 5, 7, and 9 mm from the midpalatal suture to each lateral side, and at positions 3, 6, 9, 12, 15, 18, 21, 24, and 27 mm posterior to the posterior margin of the incisive foramen. These locations were chosen because the thickness of palatal cortical bone was measured at these same positions in the previous study.¹¹

This study evaluated whether bone density varies between sexes and between left and right sides of the palate. It is surprising to note that the higher bone density values in the female group were statistically significant at most sites. Consistent with this study, a previous study reported that mean values for bone density of the lumbar spine and the neck of the femur were greater in South Korean females, up to 35 years of age, when compared with those of South Korean males. Bone densities in South Korean females peak at around 35 years of age, slowly decrease until the age of 50, and then rapidly decrease after 50 years of age; bone densities in South Korean males have been observed to decrease at a linear rate.¹⁴ On the other hand, no difference in bone density was observed between left and right sides of the palate in this study. This finding is consistent with observations of bilateral symmetry in bone density reported for the palate of the rhesus monkey.¹⁵ Another study also showed no difference in bone densities between left and right sides.¹²

It is interesting to note that a large amount of variation was seen in palatal bone densities within individuals at all sites in both male and female groups. Some subjects from both male and female groups had less

than 850 HU of bone density at sites posterior to AP = 6 and ML = 4 and ML = 5. Differences in bone density between neighboring sites should be taken into consideration, especially when a second site is selected after an initial mini-implant failure. Similar variation in bone thickness of the palate has been found in other studies.^{7,11} When both bone quantity and the quality of mini-implant placement are taken into account, the posterior and lateral regions of the palate should be considered so the possibility of perforation and loosening of the implant can be reduced.

In our study, bone density decreased with increasing AP in both groups, similar to observations for bone thickness. Bone density at ML = 1 and ML = 2, however, was constant as AP increased. Bone densities at AP = 1 and 2 and ML = 1 were lower than at ML = 2. This can be explained in part by the closeness of the incisive foramen at AP = 1 and 2 and ML = 1. Bone density at ML = 2 was greater than at ML = 1, with particular significance in the female group. This can be explained in part by the fact that the palatal midline gap, formed during the prenatal period, becomes reduced by deposition of bone, and, by the age 21, fibrous tissue with collagen fibers run parallel to the surface.¹⁶ Nevertheless, bone densities at ML = 1 showed denser bone—greater than 1000 HU. Additionally, bone densities in both groups from ML = 1 to ML = 5 up to AP = 5 showed dense bone. This indicates that mini-implants can be placed from 3 mm posterior to the incisive foramen and 1 to 5 mm paramedian without onset of problems related to bone quality if bone quantity is sufficient.

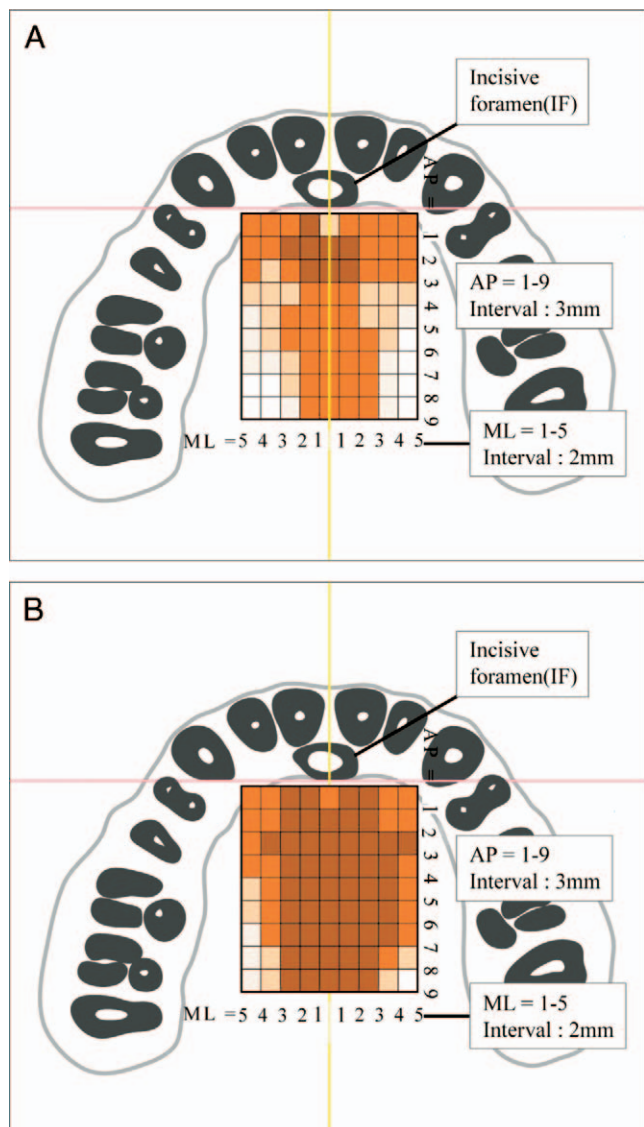


Figure 4. Mean palatal bone density maps. Mean measurement at each point is presented in the adjacent rectangle medial and anterior to it. Areas marked with darker colors represent regions with higher bone density, and bright-colored areas indicate lower-density bone. (A) Findings in the male group. (B) Findings in the female group.

The highest bone density values of all ML positions were observed at AP = 2. Regarding bone thickness, mini-implants are recommended to be placed posterior to AP = 1 at ML = 1 because of issues with bone volume.¹¹ When both bone quantity and bone quality are taken into consideration, mini-implants can be placed safely at sites at least 3 mm posterior to the incisive foramen at ML = 1. Bone density decreases as AP moves posteriorly and ML moves laterally, especially posterior to AP = 6 and ML = 4 and 5, where values lower than 850 HU were observed in some subjects. These areas should be avoided to eliminate possible loosening.¹³

For mini-implants placed in the midpalate posterior

to the second premolars, transferred to this study, those placed at AP = 5 showed higher failure rates than those placed at the first premolars.⁴ This is consistent with a previous study in which sites posterior to AP = 5 and ML = 2 showed insufficient bone volume.¹¹ Moreover, the bone density for most sites at ML = 2 was categorized as D1 (>1250 HU), having dense cortical bone.¹³ It has been reported that placing implants in D1 bone results in increased failure compared with placement in D2 and D3 bones.¹⁷ This may be explained in part by the observation that heat generated during implant placement increases in dense bone, resulting in implant failure due to bone necrosis.¹⁸ Although higher bone density seems to be important for successful placement of mini-implants, water irrigation may be needed to reduce heat generation when one is implanting into dense bone with sufficient volume.¹⁰ Moreover, in situations where bone thickness is similar between sites, site-specific modification of anterior-posterior and mediolateral levels may be helpful when a new site is chosen for placement of a mini-implant after an initial failure.

The present study, based on data from 30 young adult subjects, shows that cortical bone density ranges from 805 to 1247 HU, with bone density being dependent on anterior-posterior and mediolateral location. Our observations indicate that bone density varies between subjects and sites. Additional studies undertaken to examine the success rates of mini-implants related to bone density, bone thickness, and mini-implant length may elucidate the relative importance of each of these factors as contributors to implant failure.

CONCLUSIONS

- Mini-implants used for orthodontic anchorage may be placed successfully in most palatal areas with equivalent bone density to that located 3 mm posterior to the incisive foramen and 1 to 5 mm paramedian.
- Site selection should be adjusted according to bone density measurements.

REFERENCES

1. Clemmer EJ, Hayes EW. Patient compliance wearing orthodontic headgear. *Am J Orthod.* 1979;75:517-524.
2. Kyung HM, Park HS, Bae SM, Sung JH, Kim IB. Development of orthodontic micro-implants for intraoral anchorage. *J Clin Orthod.* 2003;37:321-328.
3. Park YC, Kim CK, Lee JS. *Atlas of Contemporary Orthodontics.* 3rd ed. Seoul, Korea: Shinheung International; 2006:167-170.
4. Wehrbein H, Merz B, Diedrich P, Glatzmaier J. The use of palatal implants for orthodontic anchorage. *Clin Oral Implants Res.* 1996;7:410-416.
5. Kim HJ, Yun HS, Park HD, Kim DH, Park YC. Soft-tissue

- and cortical-bone thickness at orthodontic implant sites. *Am J Orthod Dentofacial Orthop.* 2006;130:177–182.
6. Kyung SH, Lim JK, Park YC. A study on the bone thickness of midpalatal suture area for miniscrew insertion. *Korean J Orthod.* 2004;34:63–70.
 7. Bernhart T, Vollgruber A, Gahleitner A, Dörtbudak O, Haas R. Alternative to the median region of the palate for placement of an orthodontic implant. *Clin Oral Implants Res.* 2000;11:595–601.
 8. Cheng SJ, Tseng IY, Lee JJ, Kok SH. A prospective study of the risk factors associated with failure of mini-implants used for orthodontic anchorage. *Int J Oral Maxillofac Implants.* 2004;19:100–106.
 9. Miyawaki S, Koyama I, Inoue M, Mishima K, Sugahara T, Takano-Yamamoto T. Factors associated with the stability of titanium screws placed in the posterior region for orthodontic anchorage. *Am J Orthod Dentofacial Orthop.* 2003;124:373–378.
 10. Park HS, Jeong SH, Kwon OW. Factors affecting the clinical success of screw implants used as orthodontic anchorage. *Am J Orthod Dentofacial Orthop.* 2006;130:18–25.
 11. Kang S, Lee SJ, Ahn SJ, Heo MS, Kim TW. Bone thickness of the palate for orthodontic mini-implant anchorage in adults. *Am J Orthod Dentofacial Orthop.* 2007;131:S74–S81.
 12. Park HS, Lee YJ, Jeong SH, Kwon TG. Density of the alveolar and basal bones of the maxilla and the mandible. *Am J Orthod Dentofacial Orthop.* 2008;133:30–37.
 13. Misch CE, Kircos LT. Diagnostic imaging and techniques. In: Misch CE, ed. *Contemporary Implant Dentistry.* 2nd ed. St Louis: Mosby; 1999:73–87.
 14. Yong SJ. Bone mineral density of normal Korean adults, PhD thesis, 1989, Yonsei University, Seoul, Korea.
 15. Miller AJ, Cann CE, Nielsen I, Roda G. Craniomandibular bone density in the primate as assessed by computed tomography. *Am J Orthod Dentofacial Orthop.* 1988;93:117–125.
 16. Pritschard JJ, Scott JH, Girgis PG. The structure and development of cranial and facial sutures. *J Anat.* 1956;90:73–86.
 17. Truhlar RS, Morris HF, Ochi S, Winkler S. Second-stage failures related to bone quality in patients receiving endosseous dental implants: DICRG Interim Report No. 7. Dental Implant Clinical Research Group. *Implant Dent.* 1994;3:252–255.
 18. Tehemar SH. Factors affecting heat generation during implant site preparation: a review of biologic observations and future considerations. *Int J Oral Maxillofac Implants.* 1999;14:127–136.