

Case Study: A 44-Year-Old Woman With Type 1 Diabetes and a Recent History of Diabetes “Out of Control”

Deborah Thomas-Dobersen, RD, MS, CDE, and Terri Ryan-Turek, RD, CDE

Presentation

K.P. is a 44-year-old woman who was diagnosed with type 1 diabetes 22 years ago. She has been diagnosed with background retinopathy, which has been stable, and microalbuminuria, which is well-controlled on an angiotensin-converting enzyme (ACE) inhibitor. She has hypercholesterolemia, which is controlled with simvastatin (Zocor), and neuropathy. She has no history of hypertension, tobacco abuse, or cardiovascular disease.

She currently is treated with ultralente insulin and a rapid-acting insulin in boluses before each meal. She has had good control, as determined by HbA_{1c} levels averaging 7% over the past 2 years. Recently, however her HbA_{1c} increased to 9%.

K.P. is 5' 3" tall, and her weight has recently decreased unintentionally from 115 to 110 lb. She works as a special education teacher and drives daily between two schools.

One week ago, she was found to be disoriented and hypoglycemic after her car ran into a curb while she was driving. Her blood glucose level was 26 mg/dl as measured by the paramedics who were called to the scene. After treatment, she stated that she had eaten lunch 2 h before the accident and that her blood glucose before lunch had been 130 mg/dl. She had taken her normal rapid-acting insulin bolus and had no exercise that day or the day before. Her carbohydrate intake for lunch and the amount of rapid-acting insulin that she injected seemed appropriate (1 unit for every 15 g carbohydrate). She was

referred to a dietitian certified in diabetes education for evaluation.

Questions

1. What is causing K.P.'s postprandial hypoglycemia?
2. Why has her diabetes been so difficult to control recently, with unexpectedly high and low blood glucose levels after meals?
3. What is the cause of her unintentional weight loss?

Discussion

The dietitian asked K.P. to fill out a questionnaire at the beginning of her visit. She indicated the following:

- Do you feel full before you've eaten much? Yes.
- Have you had any changes in appetite recently? Yes.
- Have you gained or lost weight recently? Yes.
- Do you have any unexplained trouble controlling your blood sugars? Yes.
- Do you have any of the following symptoms: bloating, heartburn, abdominal cramping? Yes.
- Do you have unexplained nausea? Yes.
- Do you have unexplained vomiting of undigested food, especially in the morning? No.
- Have you had any diarrhea or constipation recently? Is it alternating? No.

K.P. was very upset that she was experiencing blood glucose fluctuations, which did not make any sense to her. The dietitian asked her to keep detailed food, exercise, and self-monitoring of blood glucose (SMBG) records for the next week. (See Figure 1.)

At the next visit, these records were evaluated. They showed low blood glucose levels 1–2 h after meals. The blood glucose levels did not seem to correlate with the expected absorption of nutrient postprandially or with the action of the insulins.

K.P. had some hypoglycemia unawareness, but if she was not very busy, she was able to recognize the subtle cues that she now has with hypoglycemia.

A drug history revealed no use of narcotics, tricyclic antidepressants, or anticholinergics, which might affect stomach motility. Although high-fat meals can cause the same pattern of delayed emptying and later rise in blood glucose, K.P. recorded that she ate low-fat meals. It was suspected that she had diabetic gastroparesis.

The referring physician was consulted and ruled out anemia and celiac disease. He then decided on an empiric trial of a promotility agent and nutrition recommendations as suggested by the dietitian. The nutrition recommendations for mild gastroparesis were as follows:

- Eat six or more meals/day.
- Avoid foods high in fat, and avoid adding too much fat to foods.
- Avoid high-fiber foods.
- Chew food well.
- Sit up after meals; don't recline for 1 h following a meal.
- Walk after meals when possible to enhance stomach emptying.¹

In addition, a new insulin regimen was recommended. K.P. was instructed to increase the frequency of her SMBG,

decrease her ultralente dose by 10% before bed, and give a divided rapid-acting insulin bolus—half immediately after the meal and half 2 h postprandially. The rapid-acting insulin bolus was calculated for the grams of carbohydrate in each meal, with any correction factors for high blood glucose added. Figure 2 shows K.P.'s post-treatment SMBG records.

Many patients with diabetic gastroparesis are asymptomatic or have vague symptoms and therefore go undiagnosed or undertreated. Gastroparesis develops in 40–50% of patients with longstanding type 1 diabetes and in 30–40% of those with longstanding type 2 diabetes.² In addition to the duration of diabetes, the degree of chronic or acute hyperglycemia seems to be associated with

more severe gastrointestinal problems.³ Patients with a history of retinopathy, nephropathy, or neuropathy should be presumed to have gastrointestinal abnormalities until proven otherwise.²

Diabetic gastroparesis results in delayed stomach emptying, leading to retention of stomach contents. Other abnormalities include gastric dysrhythmia, abnormality of fundic relaxation, and antral hypomotility. Symptoms include bloating, early satiety, abdominal pain, nausea, or vomiting. Delayed stomach emptying may lead to gastroesophageal reflux, with symptoms of heartburn and vomiting of undigested food.

Because gastroparesis makes stomach emptying unpredictable, blood glucose levels may be erratic and difficult to control (Figure 3). Because this condi-

tion changes the timing of nutrient absorption, the typical diabetes therapy of matching carbohydrate absorption to insulin action is thrown off, with resultant wide swings in blood glucose levels. Diabetic gastroparesis also puts patients at risk for compromised nutritional status because of dietary inadequacy.⁴

Although there is a lack of evidence-based nutrition interventions for gastroparesis in diabetic patients, the following nutritional guidelines may be effective:⁵

1. Early satiety is one of the hallmarks of gastroparesis. Because larger volume of foods slow gastric emptying, smaller more frequent meals may help.
2. Liquids usually empty from the stomach more easily and rapidly than solids. Solids require normal func-

Name: K.P.		Day:		Date:		MR#																		
COMMENTS: (STRESS, ILLNESS, KETONES, EXERCISE):																								
BG READINGS						160	55					270	45				190	125						
	12A	1	2	3	4	5	6	7	8	9	10	11	12P	1	2	3	4	5	6	7	8	9	10	11
# GRAMS OF CARBS							58						60						90					
ULTRALENTE							6												6					
CARB BOLUS							4						4						6					
HIGH B.G. CORRECTION													2											

Adapted from Pumping Insulin (1994) by Walsh & Roberts, Torrey Pines Press. Produced by: University of Colorado Hospital, Endocrinology Practice, Denver, CO. 11/99

Figure 1. K.P.'s pre-treatment SMBG records. This pattern shows a typical elevated fasting blood glucose level. Two h postprandially, when nutrient absorption is at its peak (assuming a low-fat meal), the blood glucose drops considerably more than the 30–50 mg/dl expected, and yet rises to high levels before the next meal with no additional food intake.

Name: K.P.		Day:		Date:		MR#																		
COMMENTS: (STRESS, ILLNESS, KETONES, EXERCISE):																								
BG READINGS						125	150					100	115				85	120						
	12A	1	2	3	4	5	6	7	8	9	10	11	12P	1	2	3	4	5	6	7	8	9	10	11
# GRAMS OF CARBS							58						60						90					
N, L, UL BASAL INSULIN							6												5					
H or R MEAL INSULIN							1		3				2		2				3		3			
H, R HIGH B.G. CORRECTION																								

Adapted from Pumping Insulin (1994) by Walsh & Roberts, Torrey Pines Press. Produced by: University of Colorado Hospital, Endocrinology Practice, Denver, CO. 11/99

Figure 2. K.P.'s post-treatment SMBG records. This pattern shows a more normalized blood glucose excursion achieved by 1) decreasing ultralente and thus decreasing rebound (one cause of high fasting blood glucose) resulting from low blood glucose levels throughout night, and 2) giving split rapid-acting insulin boluses, one after the meal and another 2 h postprandially.

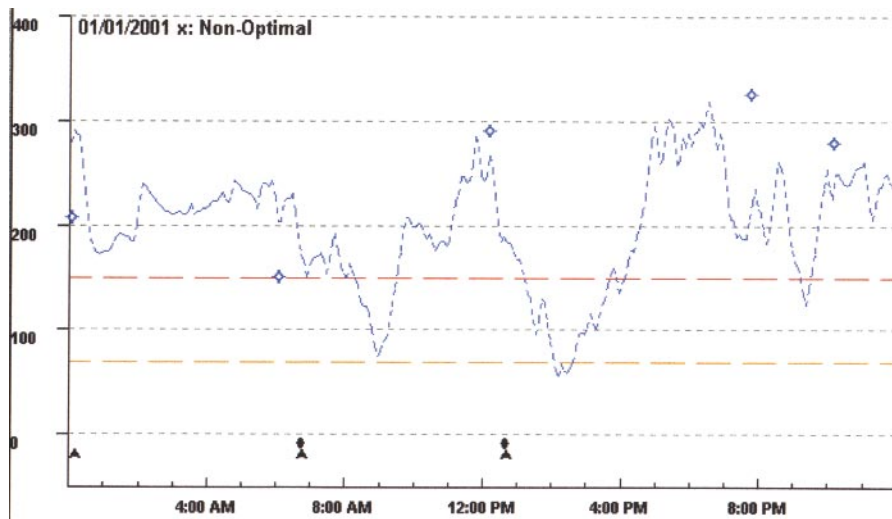


Figure 3. K.P.'s continuous glucose monitoring system (CGMS) tracing. K.P. wore a CGMS monitor for the pre-treatment day shown in Figure 1. The monitor records 288 readings per day of interstitial glucose, which closely corresponds to blood glucose. K.P.'s delayed gastric emptying from gastroparesis wreaked havoc on her blood glucose levels. The symbols at the bottom of the figure (triangle and delta) represent meal and insulin bolus.

tioning of the antrum and fundus for churning, mixing, and exiting.

Because patients often report increased fullness as the day proceeds, consuming mostly liquids toward the end of the day may be considered.

3. Fiber, especially pectin, is known to slow stomach emptying. If bezoar formation is a concern, patients should avoid oranges, persimmons, coconuts, berries, green beans, figs, apples, sauerkraut, brussel sprouts, potato peels, and legumes.
4. Fatty foods or foods with a significant amount of fat added to them exit the stomach more slowly and may be poorly tolerated. However, many patients tolerate fat in liquid form, such as milkshakes, whole milk, and nutritional supplements.

Other methods of insulin treatment may be used to help with gastroparesis. Some

patients benefit from taking a bolus of half rapid-acting and half regular insulin after meals. For patients on an insulin pump, a dual wave may be used to more closely approximate the rise in blood glucose seen with delayed absorption. For patients who use insulin injections, the rapid-acting insulin or regular insulin given with a meal may be divided, with half given as the patient eats and half given 1–2 h postprandially.

Clinical Pearls

- Gastroparesis develops in 40–50% of patients with longstanding type 1 diabetes and 30–40% of those with longstanding type 2 diabetes.
- Symptoms are often vague and may not be expressed at the clinic visit. Early satiety is one of the hallmarks of gastroparesis. Symptoms such as appetite changes and fluctuations in blood glucose are common.
- Hyperglycemia can cause transient

gastroparesis in some patients. Optimal glycemic control is imperative for maximum utilization of nutritional intervention.

- Medical nutrition therapy, patient education, and a change in insulin therapy may give relief.
- Because of the nature of the subject matter discussed (nutrient absorption patterns), dietitians are often the member of the diabetes care team to first suspect a diagnosis of gastroparesis. Dietitians often have the opportunity to discover the presence of gastroparesis in their patients and can be proactive regarding treatment recommendations.

REFERENCES

¹Lipp RW, Schnedl WJ, Hammer HF: Does postprandial walking influence delayed gastric emptying in patients with longstanding IDDM? *Diabetes Care* 19:1306–1310, 1996

²Merio R, Festa A, Bergman H, Eder, T, Eibl N, Stacher-Janotta G, Weber U, Budka C, Heckenberg A, Bauer P, Francesconi M, Scherthaner G, and Stacher G: Slow gastric emptying in type 1 diabetes: relation to autonomic and peripheral neuropathy, blood glucose, and glycemic control. *Diabetes Care* 20:419–423, 1997

³Wolosin JD, Edelman SV: Diabetes and the gastrointestinal tract. *Clinical Diabetes* 18:148–151, 2000

⁴Goldberg KB, Lasichak A, Rock CL: Dietary adequacy in patients with diabetic gastroparesis. *Am Diet Assoc* 97:420–422, 1997

⁵Parrish CR: Gastrointestinal issues in persons with diabetes. In *Handbook of Diabetes Medical Nutrition Therapy*. 2nd ed. Powers M, ed. Gaithersburg, Md., Aspen Publishers, 1996, p 618–637

Deborah Thomas-Dobersen, RD, MS, CDE, is a research coordinator and Terri Ryan-Turek, RD, CDE, is a clinical faculty member in the Endocrinology Department of University of Colorado Health Sciences Center in Denver.

Note of disclosure: Ms. Thomas-Dobersen has received research funding from MiniMed, Inc., which manufactures and markets a continuous glucose monitoring system.

Case Study: A 43-Year-Old Man With Perineal Pain and Swelling

David J. Meier, MD

Presentation

J.T. is a 43-year-old man who presented to his primary care doctor after 4 days of progressive pain and swelling in his genital region, along with a low-grade fever. There was no history of similar symptoms. He denied recent trauma. He had no nausea, vomiting, diarrhea, constipation, abdominal pain, melena, or hematochezia. He also denied dysuria, urgency, and frequency. He was in a monogamous relationship and had no history of sexually transmitted diseases. Notably, he reported a 110-lb weight loss over 6 years.

His medical history was positive only for a urethral stricture treated with a urethral dilation on cystoscopy in 1965. He had no allergies and was taking no medications. He did not smoke or drink alcohol. His family history was significant for his grandmother with type 2 diabetes.

Physical examination showed a mildly ill-appearing man in moderate distress. He was awake and alert. His vital signs included a blood pressure of 115/72 mmHg, heart rate of 110, respiratory rate of 13, and temperature of 99.7 degrees. He was 5'9" and weighed 140 lb. Head, eyes, ears, nose, and throat were normal. Lungs were clear. Heart was tachycardic with a normal s1 and s2 with no murmurs or gallops and no rub. Abdomen was nontender and nondistended with normal bowel sounds. His extremities had no edema, and pulses were normal bilaterally.

J.T.'s genital exam revealed diffuse erythema and edema of his scrotum and perineal area, along with severe tenderness. There were multiple areas of hem-

orrhagic necrosis involving a large part of the scrotum but sparing the penis. His testicles were normal in size and contour and were not tender. His perirectal area was erythematous, but there was no evidence of fissures, ulcerations, or crepitus.

Laboratory data included a normal hemoglobin and hematocrit but a markedly elevated white blood count to 35,000 k/mm³. His chem. 7 panel was also normal except for a mildly decreased sodium of 132 mEq/l and an elevated glucose of 284 mg/dl. His HbA_{1c} concentration was 12.8% with a glycosylated hemoglobin of 17.7%. There were no other laboratory abnormalities. No other laboratory tests or imaging procedures were ordered.

Questions

1. What is the diagnosis?
2. What are the potential sources?
3. How is this patient predisposed to developing this condition?
4. How should this patient be managed?

Commentary

This is a classic presentation of Fournier's gangrene, which is defined as necrotizing cellulitis and fasciitis of the perineum. Originally called "spontaneous fulminant gangrene of the scrotum," Fournier's gangrene was first described by Baurienne¹ in 1764 but named after Jean Alfred Fournier² in 1883, after he characterized the disease as the abrupt onset of fulminating genital gangrene of idiopathic origin in previously healthy young patients.

Since then, our understanding of this disease has changed considerably. Fournier's gangrene is now considered to

have a somewhat more indolent course, to have an identifiable source in 75–100% of cases, to be associated with systemic disease, and to occur throughout a broader age range.^{3,4} The incidence is higher in men than in women, with a ratio of 10:1.⁵

Fournier's gangrene most often affects patients with systemic disease, most commonly diabetes or alcoholism. Studies have shown the prevalence of diabetes in patients with Fournier's gangrene to be 32–60% and the prevalence of alcoholism to be between 25 and 66%.^{3,4} Chronic debilitation and immunosuppression secondary to transplantation, chemotherapy, or HIV infection are also significant risk factors.^{3,4}

Patients often present with genital swelling, erythema, and tenderness, frequently accompanied by fever and systemic toxicity. Swelling quickly increases, and crepitus and gangrene develop.

A rectal, dermal, or urinary source is often found by careful investigation.^{3,4} Rectal sources are suggested by pain, bleeding, and a history of anal fissures or dilatation, hemorrhoid banding, or perforation. Dermal sources are suggested by acute or chronic infections of the scrotum, recurrent hidradenitis suppurativa, balanitis, or recent epesiectomy. Urinary sources are suggested by dysuria, urethral discharge, recent urinary catheterization, or obstructed voiding, especially as a result of urethral strictures from sexually transmitted diseases. Of all the predisposing conditions, urethral strictures and perirectal abscesses are the most common.⁶

In contrast to historical descriptions, the microbiological etiology can often be

determined. The lesions are usually foul smelling, suggesting a polymicrobial infection with anaerobic-aerobic synergy.⁷ Organisms typically isolated include clostridia, klebsiella, streptococci, coliforms, staphylococci, bacteroides, and corynebacteria.⁵ Local infection usually occurs next to the portal of entry. The inflammatory reaction then spreads to the deep fascial planes with resultant obliterative endarteritis. This results in a cascade of cutaneous and subcutaneous vascular necrosis, local ischemia and tissue necrosis, and hypoxia-driven proliferation of anaerobic organisms.³

Despite our knowledge of the etiology of Fournier's gangrene, the diagnosis must remain clinical because it represents a surgical emergency. Often the illness is too fulminant to await the results of diagnostic tests. Skill is required to differentiate Fournier's gangrene from scrotal cellulitis, abscesses, strangulated herniae, pyoderma gangrenosum, and vasculitis.³ If time permits, an abdominal X-ray can be used to evaluate for subcutaneous air in the abdominal wall.

Similarly, a scrotal ultrasound can help to evaluate for subcutaneous air before the clinical detection of crepitus and to rule out other scrotal pathology.³ Proctoscopy can be useful to evaluate for the source of infection and to document rectal and anal involvement.⁴ Likewise, a retrograde urethrogram can demonstrate urinary extravasation, thus documenting the need for suprapubic diversion.⁴

Fournier's gangrene is a surgical emergency. Treatment consists of aggressive, prompt surgical debridement, and intravenous antibiotics and fluids. Most experts recommend treating with a penicillin to cover clostridia, an aminoglycoside or third-generation cephalosporin for gram negative rods, and clindamycin (Cleocin) or metronidazole (Flagyl) for anaerobes.⁵

A wide debridement should be per-

formed until normal fascia is found and repeated debridement is often required.⁶ Although occasionally compromised, the testes are frequently spared because of their independent blood supply.³ A colostomy is performed if there is colonic or rectal perforation. Recently, hyperbaric oxygen has been shown to decrease length of stay, increase wound healing, and decrease the spread of infection.⁸

Mortality is ~16%⁵ and has not improved much since the original description of this disease, likely because of the more complicated patient population and the increased average age of patients at diagnosis.⁷ Interestingly, despite being the highest-risk group for developing Fournier's gangrene, diabetic patients are not at increased risk of death compared to other patients with the disease. However, mortality is increased with advanced age, extensive disease, shock or sepsis, positive blood cultures, anorectal sources, and renal or hepatic dysfunction.^{4,5,9}

J.T. was diagnosed as having type 2 diabetes and Fournier's gangrene and was taken to the operating room for debridement within several hours of being transferred to the emergency room from his primary care physician's office. His testicles were preserved, and he did not require a colostomy. He was hospitalized for 10 days and underwent three surgical debridements and a flap closure of his wound. He remained on ampicillin (Unasyn) until discharge and was then placed on amoxicillin (Augmentin).

He received diabetes education and performed self-monitoring of blood glucose four times a day. He was treated with insulin. His diabetes was then managed as an outpatient with no subsequent readmissions.

Clinical Pearls

- Fournier's gangrene is a rare condition

that requires emergency surgical treatment.

- The clinical presentation can be variable but may consist of genital swelling, erythema, and tenderness, frequently accompanied by fever. Presentation often occurs before the development of crepitus. The disease may be indolent with progression over several days.
- Suspect a systemic disease such as diabetes, alcoholism, or HIV infection in a patient diagnosed with Fournier's gangrene.
- Search for the portal of entry, which typically includes the dermis, rectum, or urethra.
- Mortality is still almost 20% despite advances in modern medicine.

REFERENCES

¹Baurienne H: Sur une plaie contuse qui s'est terminée par le sphacèle de la scrotum. *J Med Chir Pharm* 20:251-256, 1764

²Fournier JA: Gangrene foudroyante de la verge. *Sem Med* 3:345, 1883

³Smith GL, Bunker CB, Dinneen MD: Fournier's gangrene. *Br J Urol* 81:347-355, 1998

⁴Vick R, Carson CC III: Infections in urology Fournier's disease. *Urol Clin North Am* 26:841-849, 1999

⁵Eke N: Fournier's gangrene: a review of 1726 cases. *Br J Surgery* 87:718-728, 2000

⁶Corman JM, Moody JA, Aronson WJ: Fournier's gangrene in a modern surgical setting: improved survival with aggressive management. *BJU Interna* 84:85-88, 1999

⁷Yaghan RJ, Al-Jaberi TM, Bani-Hani I: Fournier's gangrene: changing face of the disease. *Dis Colon Rectum* 43:1300-1308, 2000

⁸Hollabaugh RS, Dmochowski RR, Hickerson WL: Fournier's gangrene: therapeutic impact of hyperbaric oxygen. *Plast Reconstr Surg* 101:94-100, 1998

⁹Olsofka JN, Carrillo EH, Spain DA, Polk HC: The continuing challenge of Fournier's gangrene in the 1990s. *Am Surgeon* 65:1156-1159, 1999

David J. Meier, MD, is a house officer in the Department of Internal Medicine at the University of Michigan in Ann Arbor.

Case Study: Hypertriglyceridemia in a Woman With Insulin Resistance

Liza L. Ilag, MD

Presentation

B.L. is a 24-year-old woman with a history of dermatomyositis diagnosed at age 3. She received treatment with cyclophosphamide (Cytoxan), methotrexate, and prednisone until she was 11 years old with successful remission.

When she was 16 years old, she presented with lipoatrophic facial features, hirsutism, amenorrhea, and acanthosis nigricans in the axillary and groin areas. She was lean and muscular but not virilized. An oral glucose tolerance test showed fasting glucose of 159 mg/dl and insulin of 538 μ u/ml (normal <10 μ u/ml) and 2-h glucose of 300 mg/dl, which is diagnostic of diabetes and suggestive of insulin resistance. Her insulin receptor antibody titers were checked twice and were negative on both occasions. TSH was normal. Testosterone was 1.6 mg/ml (normal 0.10–0.90 mg/ml). Serum cholesterol was 315 mg/dl, and triglycerides were 2,748 mg/dl.

Her mother and maternal grandmother had type 2 diabetes, and her father had dyslipidemia.

B.L. was diagnosed as having type A syndrome of insulin resistance and treated with leuprolide (Lupron), 7.5 mg intramuscularly each month, and advised to follow a low-fat (20%) diet. A year later, her testosterone levels had normalized to 0.17 ng/ml with suppressed gonadotropin levels. Triglyceride and total cholesterol levels had fallen to 2,117 mg/dl and 216 mg/dl, respectively. Her HbA_{1c} concentration was 6.5%.

Given concern for future osteopenia with the use of a GnRH antagonist and the patient's desire to promote female secondary sexual characteristics, she was started on conjugated equine estrogen

(Premarin) at 0.3 mg every other day.

The importance of following the low-fat diet was reinforced.

Over the next several months, triglyceride levels continued to be elevated, while HDL cholesterol was \leq 20 mg/dl. She was started on gemfibrozil (Lopid) 600 mg twice a day, with lowering of triglyceride levels from 1,800 mg/dl to 772 mg/dl. A year later, leuprolide and conjugated equine estrogen were discontinued, and the patient was started on norgestrel/ethinyl estradiol (LoOvral 1/201/20).

Six months later, B.L. presented to the emergency room with sudden onset of right upper quadrant abdominal pain, nausea, and vomiting. Laboratory studies revealed a triglyceride level of 4,638 mg/dl, total cholesterol of 734 mg/dl, white blood count of 20,000, and amylase of 130 mg/dl. She was diagnosed as having pancreatitis and treated accordingly.

Questions

1. What are potential contributing factors to B.L.'s hypertriglyceridemia?
2. What treatment strategies could be employed to lower her triglycerides?

Commentary

Hypertriglyceridemia is the most common lipid abnormality in type 2 diabetes. Insulin resistance and insulin deficiency result in decreased lipoprotein lipase (LPL) activity, leading to slower breakdown of very-low-density lipoproteins (VLDLs) and chylomicrons. Increased hepatic production of triglycerides also occurs.

Most patients with well-controlled type 2 diabetes have normal triglyceride levels. Persistent hypertriglyceridemia or severe elevations in triglycerides usually

indicate an underlying familial hyperlipoproteinemic disorder or the presence of secondary causes for the high triglyceride levels.

At diagnosis, B.L. was not taking any drugs known to cause hypertriglyceridemia, such as alcohol, thiazides, β -blockers, bile acid sequestrants, oral estrogens, retinoids, or steroids. It is likely that she had a familial disorder.

Lifestyle changes are usually implemented as the initial management for elevated triglyceride levels. These changes include adopting a diet that limits saturated fats, losing weight, getting regular physical activity, ceasing cigarette smoking, and avoiding alcohol or consuming it only in moderation. B.L. was able to control her triglyceride levels with a low-fat diet and gemfibrozil while on a very low dose of the conjugated equine estrogen. Because she was taking oral contraceptives when she developed pancreatitis, it is possible that the oral contraceptives contributed to the severe elevations in her triglyceride level. Oral estrogens raise triglycerides by increasing VLDL secretion rates, and her norgestrel/ethinyl estradiol has a higher estrogen potency than the conjugated equine estrogen she was taking. Oral contraceptives were discontinued.

Both hyperglycemia and insulin resistance contribute to hypertriglyceridemia and low HDL cholesterol levels. Efforts should be made to correct hyperglycemia. Studies of pharmacological agents that directly improve insulin resistance, such as the thiazolidinediones, have focused on their lipid-altering potential. These drugs are known to exert a hypotriglyceridemic action via peroxisome proliferator-activated receptor (PPAR) γ -mediated induction of LPL

expression in adipose tissue. Troglitazone (Rezulin) and pioglitazone (Actos) have been shown to decrease triglyceride levels, and all of the drugs in this class appear to increase HDL levels. An increase in LDL levels has been reported, but changes in the size of the LDL cholesterol particles may make the cholesterol less susceptible to oxidation.

B.L. was initially treated with troglitazone for her insulin resistance syndrome. Before treatment, her HbA_{1c} was 5.8%, total cholesterol was 249 mg/dl, triglycerides were 1,563 mg/dl, and HDL was 17 mg/dl. With troglitazone, B.L.'s insulin levels fell, but her triglyceride levels remained high. When troglitazone was withdrawn from the market, she was switched to pioglitazone.

For triglycerides that remain ≥400 mg/dl (and LDL <130 mg/dl), fibrates such as gemfibrozil and fenofibrate (Tricor) are the drugs of first choice. These medications activate PPARs, which are nuclear transcription factors that upregulate LPL transcription and downregulate the LPL inhibitor apolipoprotein C3. Gemfibrozil 600 mg twice daily was prescribed, lowering the triglyceride levels substantially although not to <400 mg/dl.

Because their mechanisms of action are different, fibrates and nicotinic acid may be used in combination and should be considered in patients with severe hypertriglyceridemia or high risk for pancreatitis. Niacin works primarily by inhibiting adipose tissue lipases, thus reducing the substrate for hepatic lipoprotein synthesis. While relatively contraindicated in patients who have diabetes, in whom it may worsen hyperglycemia, there are few data to support such a recommendation. Niacin may worsen hyperglycemia by increasing insulin resistance, but it may still be used with caution to treat hyperlipidemia in diabetic patients. Results of the Arterial Disease Multiple Intervention Trial (ADMIT) showed unchanged HbA_{1c} levels among participants with diabetes treated with niacin for up to 48 weeks, although glucose levels were modestly increased in participants with and with-

out diabetes.

When B.L.'s triglyceride levels were fluctuating between 682 and 5,764 mg/dl, niacin was added to gemfibrozil and troglitazone. She continued to have HbA_{1c} levels ≤7%. Her triglyceride levels decreased to 317 mg/dl. Unfortunately, B.L. developed hives, and niacin was discontinued.

Combining statins (HMG-CoA reductase inhibitors) with fibrates or nicotinic acid is usually safe and effective but requires judicious use and careful monitoring because severe myopathy and rhabdomyolysis have been reported in ~1% of patients on such combination therapy. Statins act by preventing cholesterol synthesis and lower triglycerides by inhibiting the assembly and secretion of VLDL. B.L.'s history of dermatomyositis was a concern, but after discontinuing niacin, her triglyceride levels increased to >1,000 mg/dl. She was then started on atorvastatin (Lipitor), 20 mg daily.

For resistant hypertriglyceridemia inadequately controlled by diet and drugs, fish oil supplements (ω-3 fatty acids) may also play a role. Interest in ω-3 fatty acids started in the 1970s with studies on Greenland Eskimos whose diets were high in fat, cholesterol, and ω-3 fatty acids but who had low rates of coronary artery disease. The ω-3 fatty acids in fish oil reduce hepatic synthesis of triglyceride and VLDL and shorten the turnover of VLDL in plasma. The triglyceride response is dose-dependent with a decrease of 30% at a daily dose of 3 g and up to 50% at 9 g. No change in total or HDL cholesterol has been reported, but LDL may increase by 7%.

B.L.'s triglycerides were in the 1,000s while on gemfibrozil and atorvastatin. She was then started on fish oil supplements (500 mg eicosapentaenoic acid [EPA] and 300 mg docosahexaenoic acid [DHA]) with meals. Her triglyceride level decreased from 1,000 to 700 mg/dl.

Most recently, while on pioglitazone, 30 mg daily, gemfibrozil, 600 mg twice daily, atorvastatin, 40 mg daily, and EPA/DHA three times a day with meals, her total cholesterol was 174 mg/dl,

triglyceride levels were 329 mg/dl, HDL was 25 mg/dl, and LDL was 83 mg/dl.

Clinical Pearls

- Persistent hypertriglyceridemia in well-controlled diabetes warrants review of modifiable risk factors. Abrupt and massive elevation in triglycerides to >2,000 mg/dl can precipitate pancreatitis.
- Diet and improved glycemic control can often ameliorate moderate hypertriglyceridemia.
- Fibrates and nicotinic acid are potent triglyceride-lowering medications that may be needed to effectively manage severe hypertriglyceridemia. Used with caution, they can help in the management of hypertriglyceridemia in diabetic patients.
- Fish oil is an option to lower triglyceride levels in resistant hypertriglyceridemia inadequately controlled by diet and medications.

SUGGESTED READINGS

American Diabetes Association: Management of dyslipidemia in adults with diabetes (Position Statement). *Diabetes Care* 24 (Suppl. 1):S58–S61, 2001

Ballantyne CM, Grundy SM, Oberman A, Kreisberg RA, Havel RJ, Frost PH, Haffner SA: Hyperlipidemia: diagnostic and therapeutic perspectives. *J Clin Endocrinol Metab* 85:2089–2112, 2000

Connor WE, DeFrancesco CA, Connor SL: Ω-3 fatty acids from fish oil: effects on plasma lipoproteins and hypertriglyceridemic patients. *Ann NY Acad Sci* 683:16–34, 1993

Elam MB, Hunninghake DB, Davis KB, Garg R, Johnson C, Egan D, Kostis JB, Sheps DS, Brinton EA: Effect of niacin on lipid and lipoprotein levels and glycemic control in patients with diabetes and peripheral arterial disease: the ADMIT study: a randomized trial. Arterial Disease Multiple Intervention Trial. *JAMA* 284:1263–1270, 2000

Harris WS: Nonpharmacologic treatment of hypertriglyceridemia: focus on fish oils. *Clin Cardiol* 22 (Suppl. II):II-40–II-43, 1999

Miller M: Current perspectives on the management of hypertriglyceridemia. *Am Heart J* 140:232–240, 2000

Liza L. Ilag, MD, is a lecturer and research fellow in the Division of Endocrinology and Metabolism at the University of Michigan in Ann Arbor.

Downloaded from http://diabetesjournals.org/clinical/article-pdf/19/4/183/497690/0183.pdf by guest on 04 October 2024