

# Unusual Extraction Treatment in Class II division 1 Using C-Orthodontic Mini-Implants

Kyu-Rhim Chung<sup>a</sup>; Jae-Hee Cho<sup>b</sup>; Seong-Hun Kim<sup>c</sup>; Yoon-Ah Kook<sup>d</sup>; Mauro Cozzani<sup>e</sup>

**Abstract:** This paper describes the treatment of a female patient, aged 23 years and 5 months, with a Class II division 1 malocclusion, who showed severe anterior protrusion and lower anterior crowding. Specially-designed orthodontic mini-implants were placed bilaterally in the interdental space between both the upper and the lower posterior teeth. Both lower first molars showed severe apical lesions. Therefore, the treatment plan consisted of extraction of both upper first premolars and lower first molars, en masse retraction of the upper six anterior teeth, lower anterior alignment, and protraction of all the lower molars. C-implants<sup>®</sup> were used as substitutes for maxillary posterior anchorage teeth during anterior retraction and as hooks for mandibular molar protraction. The correct overbite and overjet were obtained by intruding and retracting the upper six anterior teeth into their proper positions. The dentition was detailed using conventional orthodontic appliances. The upper C-implants contributed to an improvement in facial balance, and the lower C-implants made it possible to protract the lower second and third molars with less effect on the axis of the lower anterior teeth. The active treatment period was 29 months and the patient's teeth continued to be stable 11 months after debonding.

**Key Words:** Osseointegration; En masse retraction; Class II malocclusion; Mini-implant; Molar protraction

## INTRODUCTION

Class II malocclusion has conventionally been corrected by means of intermaxillary elastics and headgear, both of which demand patient compliance.<sup>1</sup> Without adequate patient compliance, Class II molar and canine relationships are not corrected.<sup>2</sup> Intraoral skeletal anchorage provides absolute anchorage, eliminates the need for patient cooperation and anchorage preparation, and gets predictable treatment results more rapidly.<sup>3-5</sup> The orthodontic mini-implant has the

advantages of low cost, easy placement and removal, and small size, and it can be implanted in any location in the oral cavity.<sup>6-10</sup> When treating a Class II division 1 anterior protrusion case that requires moderate lower anchorage, temporary anchorage devices are used as a nonextraction method, and distalization can be achieved in the lower posterior teeth.<sup>11</sup>

Recently, sandblasted, large-grit, acid-etched (SLA) surface-treated orthodontic mini-implants (C-implants<sup>®</sup>; Cimplant Co, Seoul, Korea), which utilize osseointegration as the main source of retention, were introduced (Figure 1A).<sup>10,12,13</sup> The screw part of the C-implant is designed to endure heavy forces, and the head part, which has a 0.032-inch-diameter hole, is designed to accommodate arch wires for anterior retraction.<sup>14</sup> Therefore, the number of teeth employed for leveling is reduced, preventing damage caused by prolonged wearing of appliances. Upper posterior C-implants also can be used as hooks for intermaxillary elastics to retract the lower dentition.

Conventional mini-implants that are self-drilling and have a machine surface can hardly withstand the dynamic force from Class III intermaxillary elastics.<sup>15</sup> The force from the elastics is dynamic because the opening and closing of the jaw shifts the amount and direction of force.

<sup>a</sup> Private practice, Seoul, South Korea.

<sup>b</sup> Research Assistant, Department of Orthodontics, The Catholic University of Korea, Seoul, South Korea.

<sup>c</sup> Assistant Professor, Department of Orthodontics, The Catholic University of Korea, Seoul, South Korea.

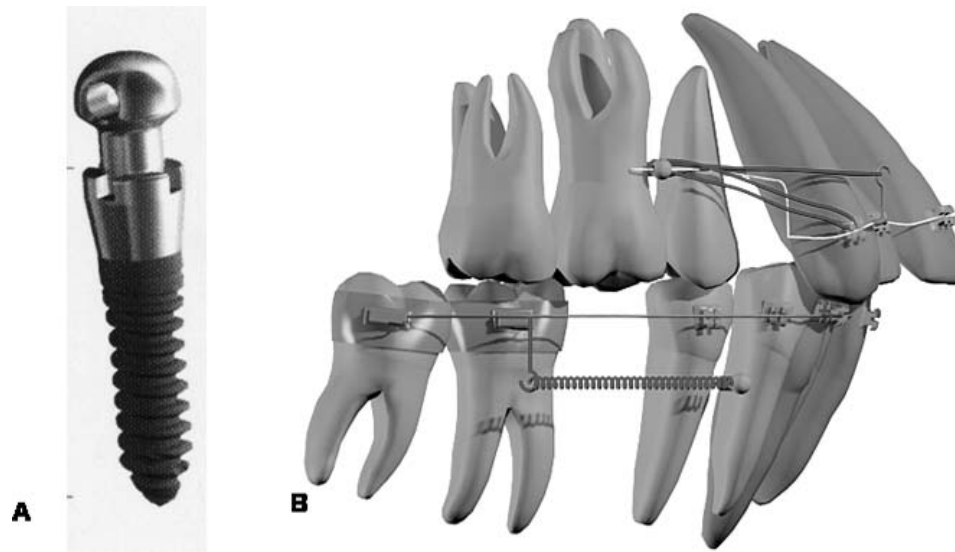
<sup>d</sup> Associate Professor and Department Chair, Department of Orthodontics, The Catholic University of Korea, Seoul, South Korea.

<sup>e</sup> Adjunct Professor, Department of Orthodontics, University of Ferrara, LaSpezia, Italy.


Corresponding author: Seong-Hun Kim, DMD, MS, Department of Orthodontics, The Catholic University Korea, Uijongbu St Mary's Hospital, 65-1 Kumoh-dong Uijongbu Kyonggi-do 480-130, South Korea (e-mail: bravortho@catholic.ac.kr)

Accepted: March 2006. Submitted: February 2006.

© 2006 by The EH Angle Education and Research Foundation, Inc.



**Figure 1.** Schematic illustrations. (A) C-implant®. (B) C-implant–dependent en masse retraction mechanics for treatment of Class II division 1 malocclusion and lower molar protraction.



**Figure 2.** Pretreatment extraoral photographs.

This case report documents a new approach for Class II division 1 malocclusion with hopeless teeth using C-implants. The treatment employs en masse retraction of the anterior teeth while avoiding the extension of unnecessary orthodontic appliances to posterior segments during the retraction period.<sup>16</sup> This alternative approach uses partially osseointegrated mini-implants that can endure multidirectional heavy forces even while they support the orthodontic arch wires.

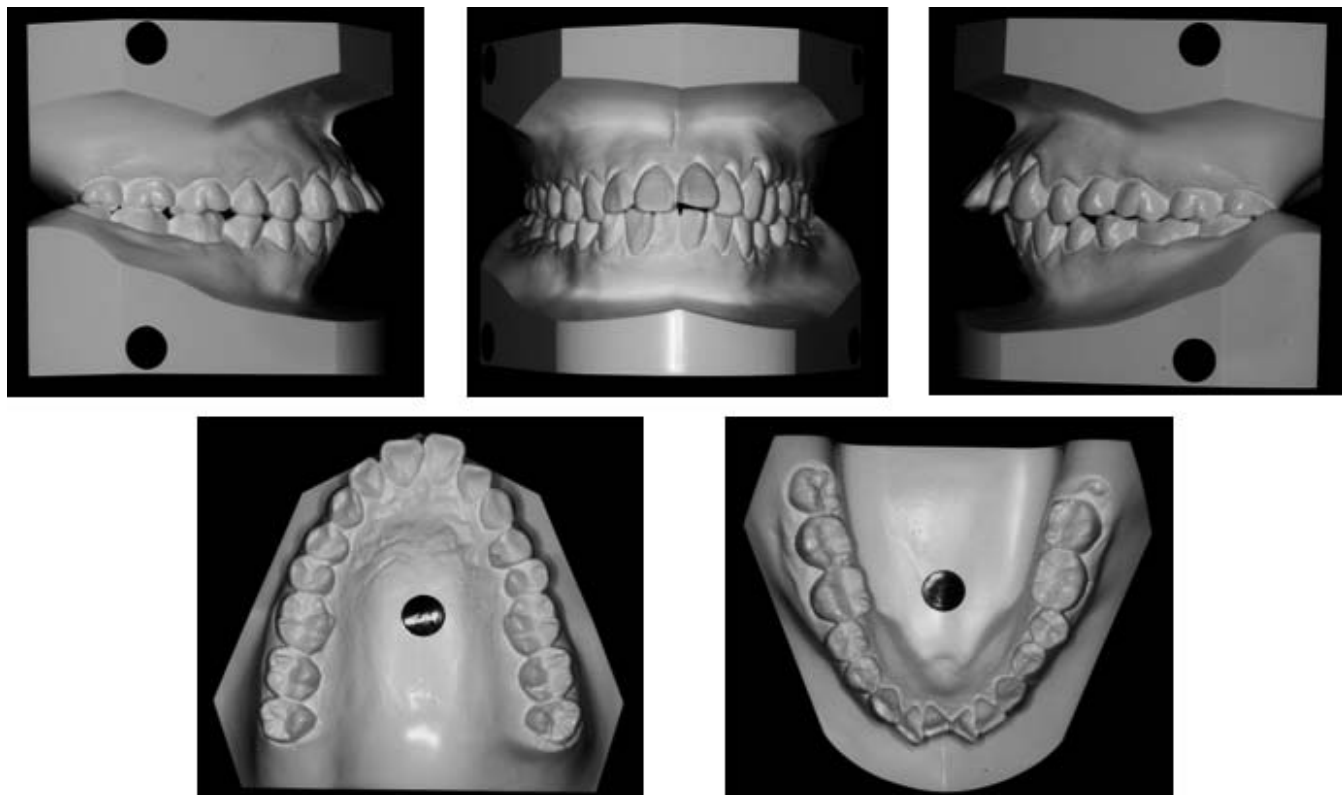
## CASE REPORT

### Pretreatment Evaluation

A female aged 23 years and 5 months presented with a chief complaint of lip protrusion and a desire for a more esthetic smile. There was no remarkable med-

ical history, and temporomandibular joint function was normal. The pretreatment facial photographs revealed the facial characteristics typical of a Class II anterior protrusion patient, with a short anterior facial height, a deep labiomental sulcus, a prominent upper and lower lip, a convex profile, and hypermental activity with closed lips (Figure 2). The pretreatment study models demonstrate bilateral Class II molar and canine relationships, a flat occlusal plane, severely protruded upper incisors, and slightly procumbent lower incisors (Figure 3). Both dental midlines coincided with the facial midline.

A panoramic radiograph revealed seriously compromised mandibular first molars, and the left lower third molar was tipped mesially (Figure 12A). The cephalometric analysis showed a skeletal Class II relationship (ANB angle, 7°) with a normal mandibular plane



**Figure 3.** Pretreatment study models.

angle (FMA,  $26^\circ$ ) and protrusive incisors (interincisal angle,  $95^\circ$ ; maxillary incisor to NA angle,  $37.5^\circ$ ; maxillary incisor to NA distance, 12 mm; mandibular incisor to NA angle,  $40^\circ$ ; mandibular incisor to NB distance, 12 mm; Figure 4; Table 1).

### Treatment Plan

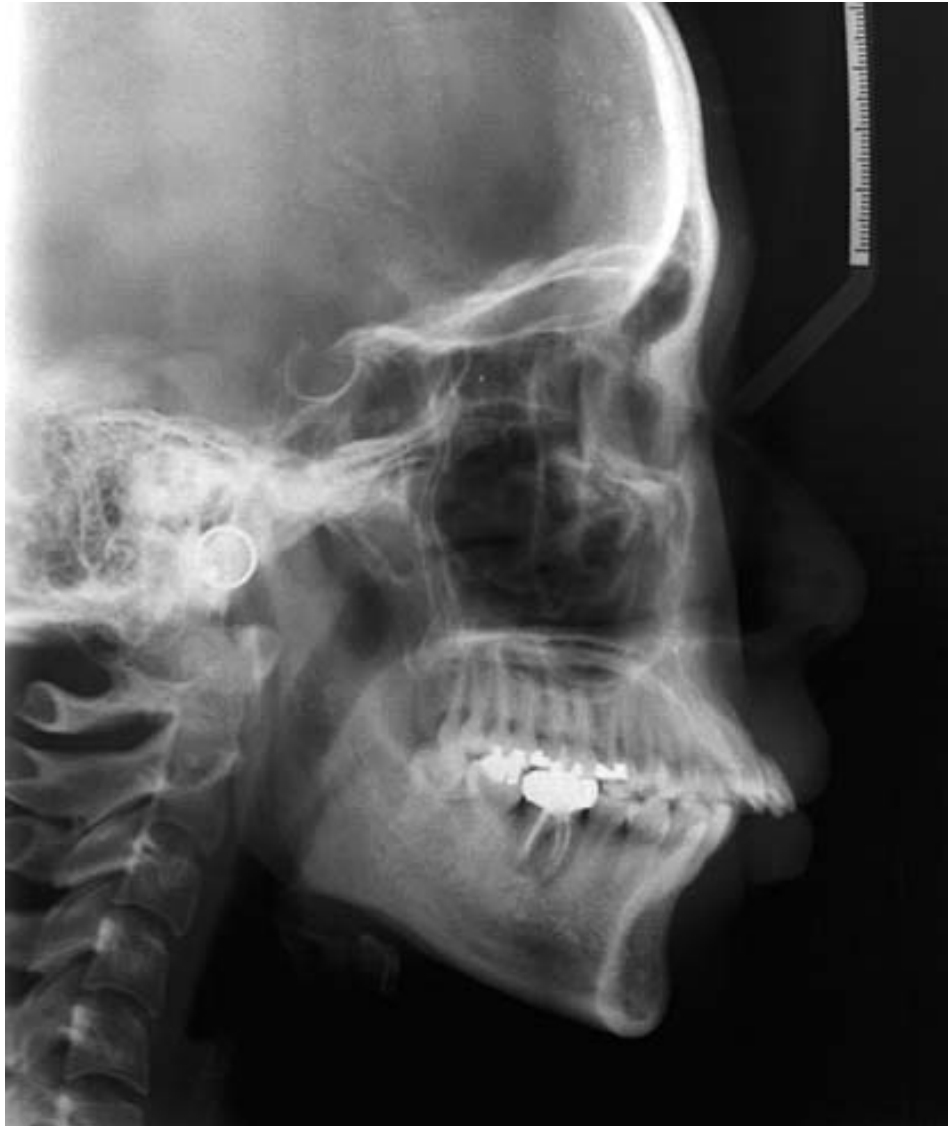The malocclusion was diagnosed as a Class II with anterior protrusion and mild lower anterior crowding. The patient requested full retraction of the upper and lower anterior teeth using the first premolar extraction spaces. However, the intraoral clinical examination revealed an abscess on the right lower first molar and secondary caries on the left first molar. The treatment objectives were to extract two upper first premolars and two mandibular teeth, retract the anterior teeth, improve the interincisal angle, decrease the lip protrusion, achieve a bilateral Class I canine occlusion, and improve the facial balance.

First, a treatment plan involving headgear for maximum anchorage was offered, but the patient declined this treatment option. Two alternatives, both involving en masse retraction of upper dentition with mini-implants, were presented: (1) use conventional mini-implants as direct or indirect anchorage to reinforce the bonded or banded posterior anchorage teeth during anterior retraction, or (2) use specially-designed ortho-

dontic mini-implants (C-implants) as independent appliances for anterior retraction without the assistance of bonded or banded posterior anchorage teeth.

Also, three treatment approaches involving correction of the lower dentition were presented: (1) extract both the lower first premolars with moderate anchorage treatment and do the necessary restorative treatment on the lower first molars; (2) distalize a nonextraction mandibular dentition using intermaxillary elastics; or (3) extract the compromised mandibular first molars, retract the lower anterior dentition to the normal range, and protract both the second and third molars using lower C-implants.

A treatment plan combining the second approach for en masse retraction in the maxillary arch and the third approach in the mandibular arch was selected (Figure 1B). This plan allowed maximum retraction of upper anterior teeth without affecting the molar occlusal relationship and minimized adverse periodontal effects. After en masse retraction of the upper and lower anterior teeth, full fixed appliances would be used to finish the orthodontic treatment. However, both the lower second molars and the third molars showed underdeveloped shapes in the panoramic radiograph. Therefore, the patient accepted the plan of additional restorative treatment on the lower posterior teeth after orthodontic treatment for better occlusal relationships.



**Figure 4.** Pretreatment cephalometric radiograph.

### Treatment Progress

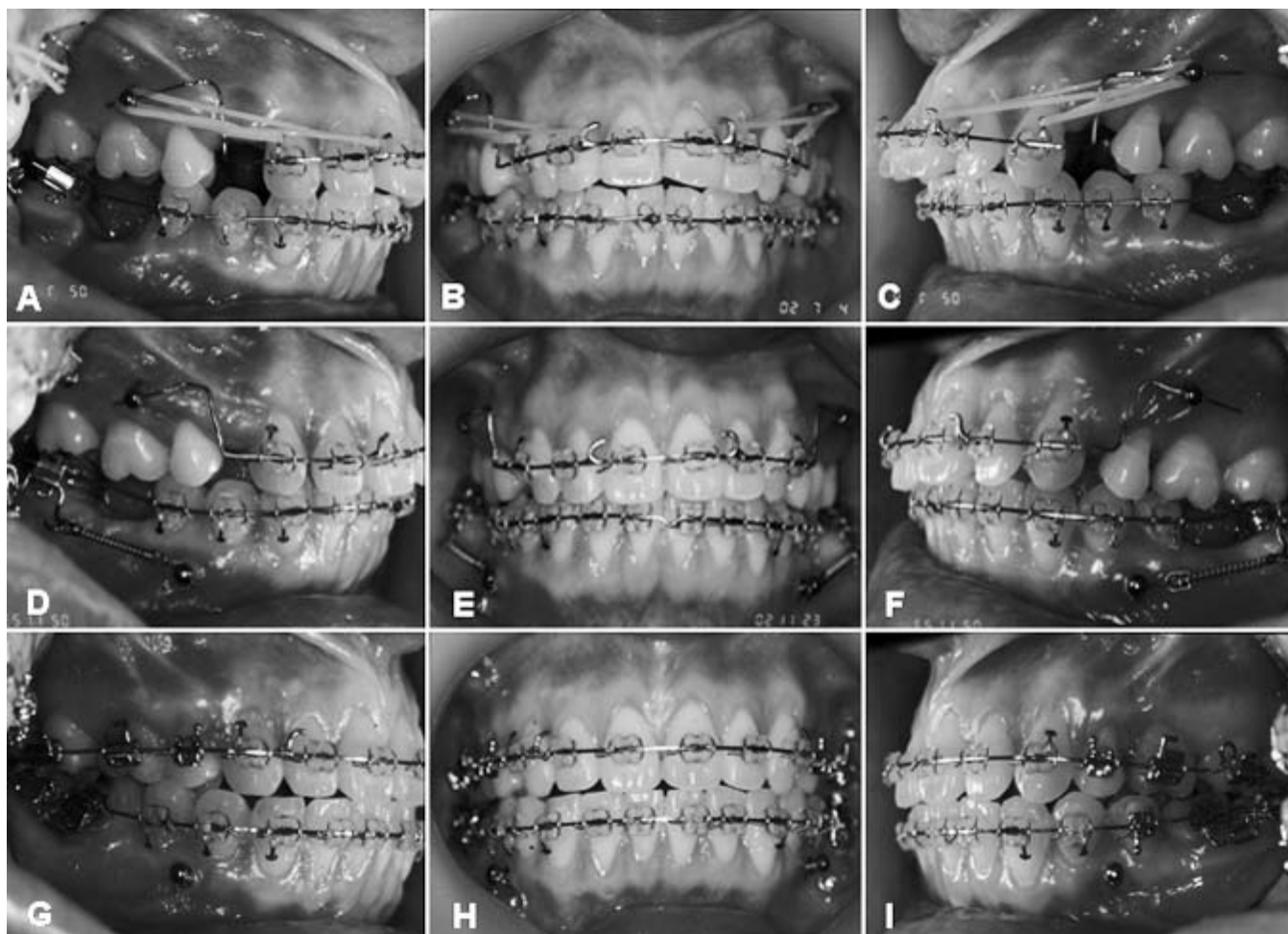
Treatment was initiated with the placement of upper C-implants in the maxilla and leveling of the lower anterior dentition. Two C-implants (1.8 mm in diameter and 8.5 mm in length) were implanted on the upper alveolar bone between the maxillary second premolar and the first molar. The maxillary first premolars were removed to create space for the intrusion and retraction of the maxillary anterior teeth, and the compromised lower first molars were extracted.

After a 4-week healing period, en masse retraction was started on the upper anterior dentition with the insertion of a 0.016 × 0.022-inch stainless steel utility arch wire in the C-implants. In the maxillary arch, 3/16-inch, 3.5-oz Class I elastics were used between the

canines and the C-implants. and 1/4-inch, 3.5-oz Class I elastics between the soldered hook of the arch wire and the C-implants (Figure 5A through C). Gingival recession on the lower anterior teeth was shown during leveling and aligning.

Two additional C-implants were placed on the lower alveolar bone between the lower first premolars and the second premolars 6 months after beginning active orthodontic treatment. Seven months after the start of active orthodontic treatment, dental crowding and severe protrusion of the lower dentition were almost resolved (Figure 5D through F). Even though the above problems were improved using the lower extraction space, the remaining extraction space for molar protraction was too large for maintaining the long axes of the lower incisors. Therefore, lower molar protraction





**Figure 5.** Progress intraoral photographs. (A–C) En masse retraction of 6 anterior teeth with 0.016 × 0.022-inch stainless steel utility arch wire with soldered hook inserted in the C-implant® hole and Class I elastics were placed between the extended wire of the hole, the cuspid bracket, and the soldered hook. (D–F) Two C-implants were placed additionally in the alveolus between lower first bicuspid and second bicuspid, and NiTi closed-coil springs were applied between the extended hook of buccal tube of lower second molars and the holes of C-implants for molar protraction. (G–I) Upper and lower conventional orthodontic treatment used for finishing. Protraction of both lower second molars was completed and leveling of the lower third molar was performed. Upper C-implants were removed during this stage.

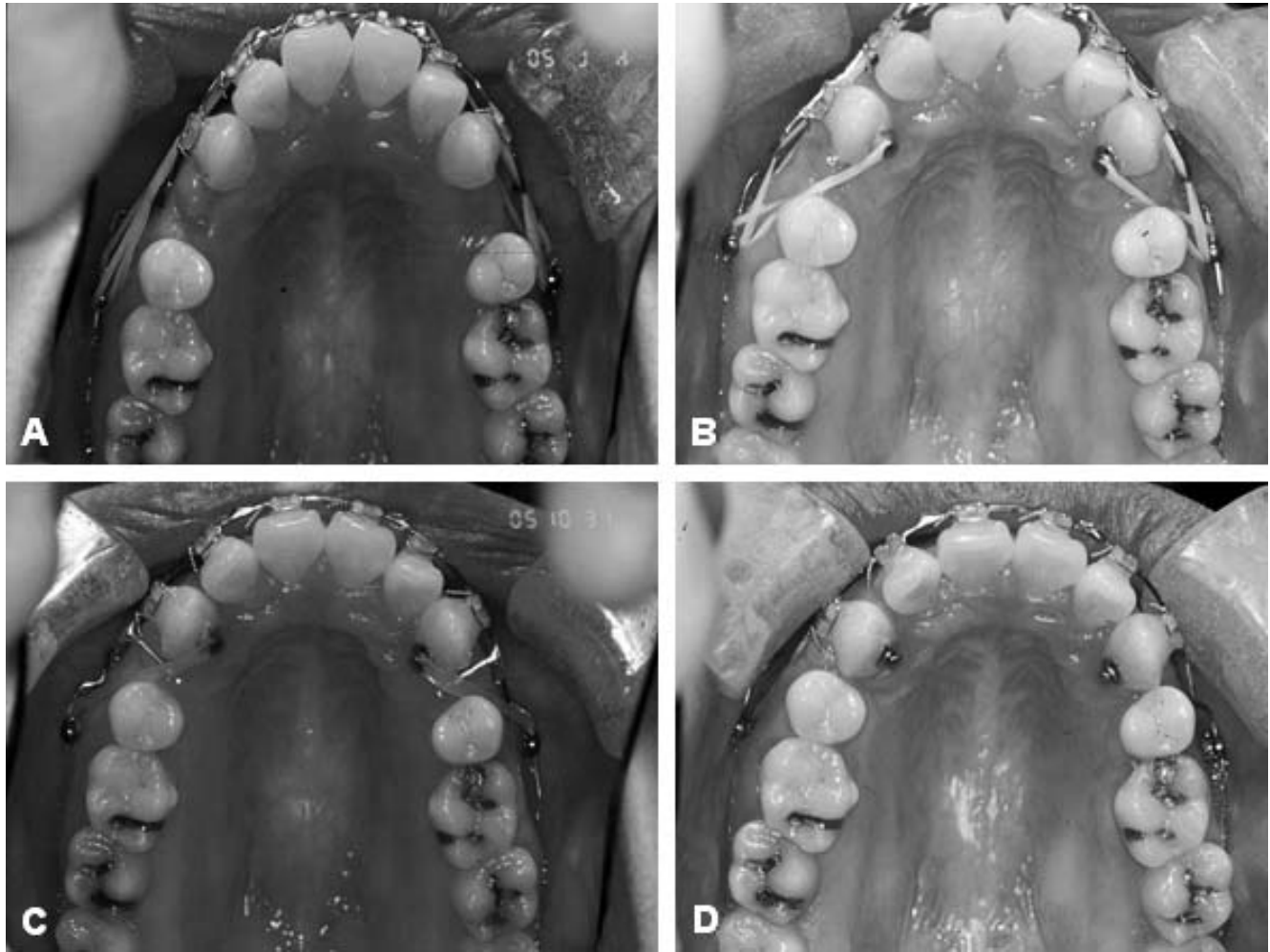
was applied by means of nickel titanium (NiTi) closed-coil springs (Jinsung Co, Seoul, Korea). Each spring exerted 100 g of force from the neck of the C-implant to the hooks on the lower second molar tubes. The mesial tipping on the second molars was controlled by sliding mechanics on a rectangular arch wire. After 12 months of en masse retraction of the maxillary anterior dentition, the dentition was fully bonded and detailed. The upper two C-implants were used as auxiliaries for intrusion of extruded upper first molars and residual space closure for 4 months.

The upper C-implants were removed after 16 months of treatment. After the implant site was anesthetized topically, the head from the screw was removed using the tip of the explorer and rotated counterclockwise using the screwdriver. The soft tissue healed within a few days. Even though osteointegra-

tion is part of the anchorage with a C-implant, a two-component design of the head part and screw part prevents the fracture of an implant during the removal procedure.

The protraction of the mandibular molars required 22 months. The molars moved forward approximately 10 mm, and space closure was achieved by bodily movement of the second molars with no additional retraction of the lower incisors (Figures 5G through I and 12B, C). The lower third molars were protracted and uprightened simultaneously.

The active treatment period with fixed appliances lasted 29 months. Retention was provided by upper and lower lingual fixed-type retainers and wraparound retainers during the night. The changes of the maxillary dentition during the treatment period are shown in Figure 6.



**Figure 6.** Occlusal changes during C-implant-dependent en masse retraction period. (A) July 4, 2002. (B) August 5, 2002. (C) October 31, 2002. (D) February 20, 2003.



**Figure 7.** Posttreatment extraoral photographs.

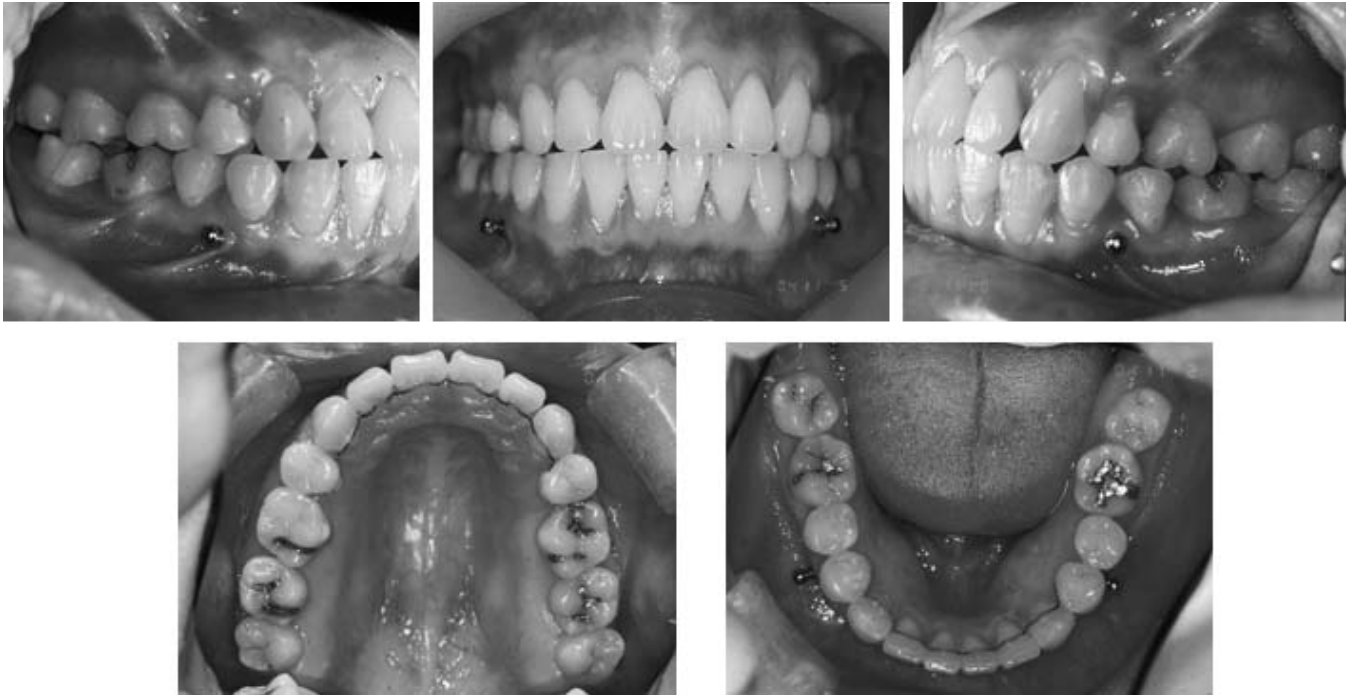

Figure 8. Posttreatment intraoral photographs.

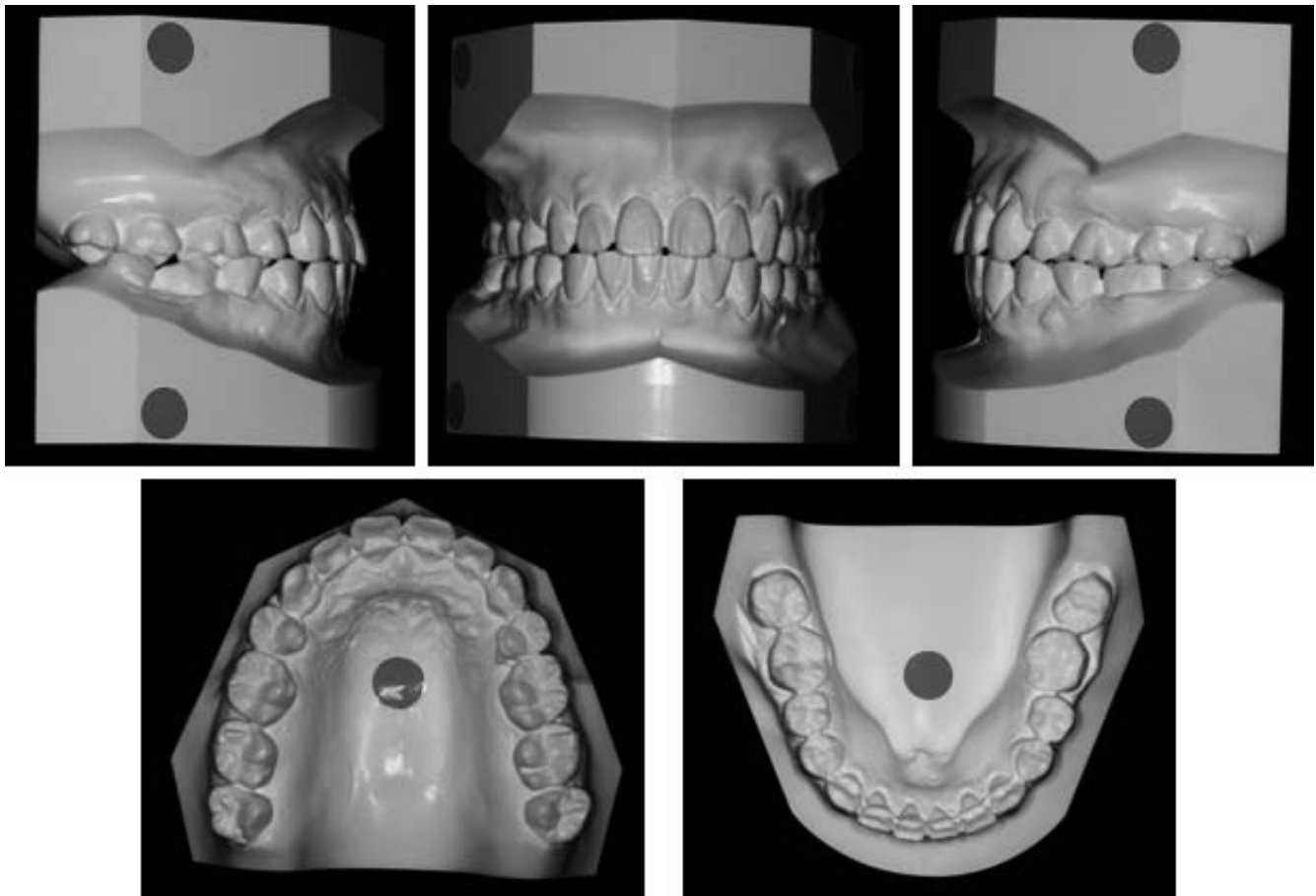
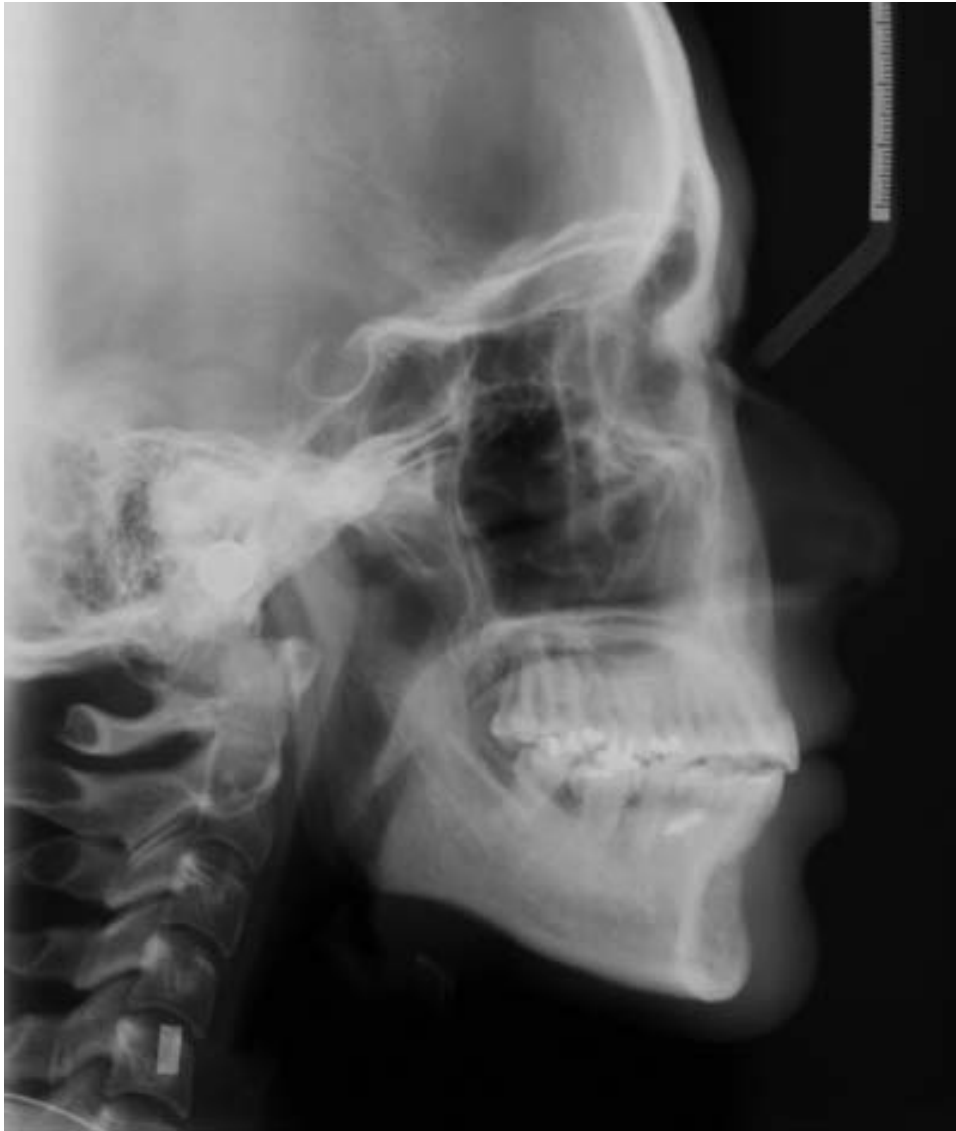

Figure 9. Posttreatment study models.





**Figure 10.** Posttreatment cephalometric radiograph.

## DISCUSSION

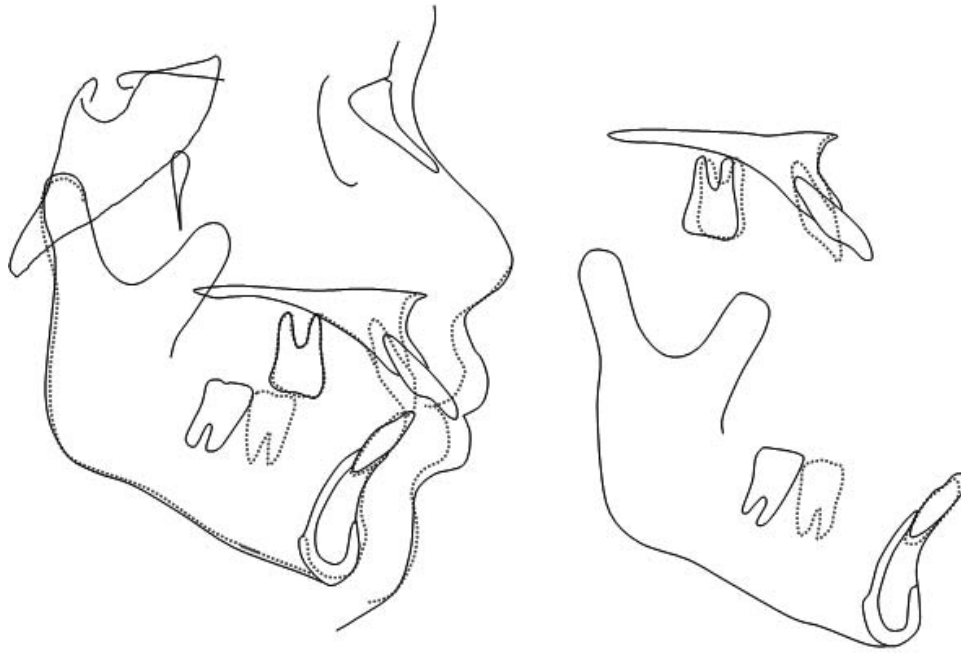
The posttreatment facial photographs showed an improvement in the facial esthetics, and the incisors were no longer procumbent (Figure 7). After treatment, a Class I canine relationship (not solid in the left side) and a full Class II molar relationship, plus coincidence of the facial and dental midlines, improved overjet and overbite, corrected tooth position, and proper alignment were achieved. However, some malalignment in the mandibular molar regions and an overcorrection in the right second molar inclination were present (Figures 8 and 9). Both upper third molars were not well aligned because they were not included in the treatment plan.

Cephalometric analysis (Figure 10; Table 1) showed maintenance of the FMA. The occlusal plane de-

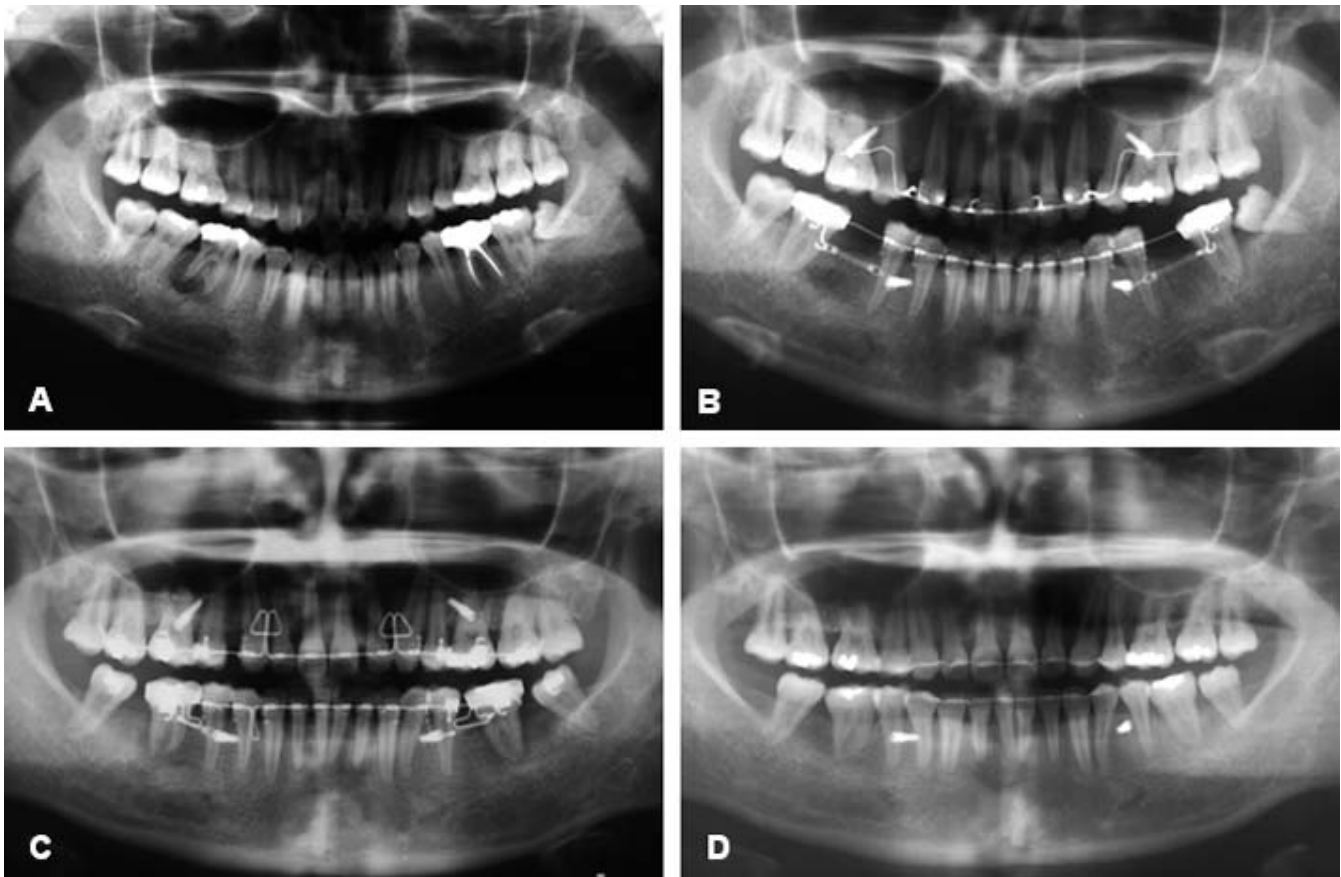
creased a little after treatment because of the intrusion of the maxillary anterior teeth. The maxillary incisors were retracted. The ANB decreased during treatment and the mandibular incisors were uprighted and retracted. The lips were competent in repose and the interincisal angle was improved to a normal range. The posterior facial height/anterior facial height ratio changed a little after treatment. Even though the upper posterior teeth were not used as anchorage during en masse retraction, a slight mesial movement of the maxillary molars was observed on the cephalometric superimposition (Figure 11). Although excessive anchorage loss is considered to be negative in conventional treatments, minimal physiologic drifting may be positive for the closure of extraction spaces.

The panoramic radiographs showed that root par-





**Figure 11.** Superimpositions of lateral cephalograms: pretreatment (solid line) to posttreatment (dotted line).

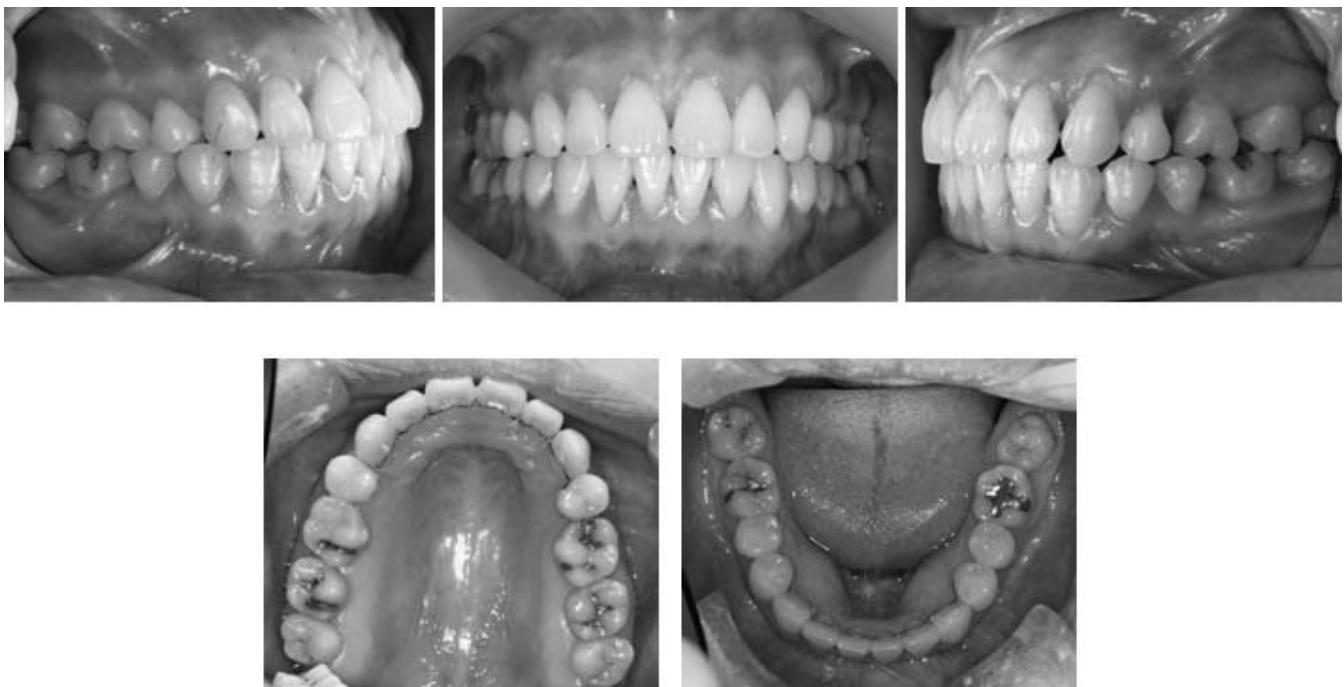

**Figure 12.** Panoramic radiographs. (A) Pretreatment. (B) During en masse retraction period. Lower molars protraction began. (C) After en masse retraction: lower second molar protraction was almost completed and third molar uprighting and protraction were performed. (D) Post-treatment.

**Table 1.** Cephalometric Survey<sup>a</sup>

	Average (Female)	Pretreatment	Posttreatment
SNA (°)	81.6	87	85.5
SNB (°)	79.2	80	80
ANB (°)	2.4	7	5.5
PFH/AFH (%)	85.1/127.4 (66.8%)	92/132 (69.7%)	93/133 (69.9%)
SN-OP (°)	17.9	16	15
FH-UI (°)	116.0	130	109
FMA (°)	24.3	26	26
IMPA (°)	95.9	109	101
FMIA (°)	59.8	45	53
UL-E plane (mm)	-0.9	3.5	-2
LL-E plane (mm)	0.6	4.5	0
Interincisal angle (°)	123.8	95.5	124
Mx 1 to NA (mm)	7.3	12	2
Mx 1 to NA (°)	25.3	37.5	18
Mn 1 to NB (mm)	7.9	12	9
Mn 1 to NB (°)	28.4	40	32
SN to PP (°)	10.2	7	7

<sup>a</sup> Korea J Orthod. 1997 (suppl).

**Figure 13.** Eleven-month postretention intraoral photographs.

allelism had been attained, and there were no side effects such as root resorption. Sequential protraction of the lower second molars and uprighting of the mandibular third molars were present (Figure 12D). The patient was pleased with the final treatment result. The treatment result was acceptable even though the protracted mandibular molars were not aligned well because of their malformed shape. After 11 months, the treatment results were still maintained (Figure 13), but

the patient elected not to undergo the restorative treatment on the underdeveloped lower molars.

Oyonarte et al<sup>17,18</sup> reported that loaded, porous-surfaced implants had significantly higher marginal bone levels and greater bone-to-implant contact and showed higher resistance to orthodontic loading than did machine-threaded implants. Unlike the conventional machined mini-screws, the SLA surface-treated retention portion of the C-implant shows a higher os-

seointegration potential, and is better able to resist the rotational tendency of heavy dynamic loads and to control three-dimensional tooth movement.<sup>11,14</sup>

In the treatment of Class II division 1 malocclusion, the required space in the lower arch is usually small enough so that no extractions are necessary.<sup>11</sup> With nonextraction treatment, the lower teeth can be aligned and leveled, which was relevant to the position of the lower incisors and point B. Therefore, if C-implants are placed on the posterior maxilla, Class III intermaxillary elastics can be used to successfully distalize the lower dentition. However, in cases with severely defective lower first molars such as this patient, this tooth can be extracted for the sake of the adjacent teeth and alveolar bone. Still, it is not easy to close the approximately 13-mm lower first molar extraction space with minimal retraction of the lower anteriors.

This patient showed lower third molar underdevelopment, and the lower left third molar in particular had a tendency to become horizontally impacted. The restoration of the remaining space of the lower first molar after treatment using prosthetic implants was recommended, but the patient preferred to protract the second and third molars and have restorative treatment on them.

There have been several reports on protracting the lower posterior teeth using mini-implants.<sup>19,20</sup> Kyung et al<sup>19</sup> showed the use of lingual microscrews to protract mandibular second molars. However, lingually placed mini-screws may cause discomfort because of chronic inflammation around the micro screw sites and restricted tongue movement. Giancotti et al<sup>20</sup> used mini-screws placed distally to the second premolar for molar protraction. However, the mini-screws were removed during space closure (before the space was completely closed) because of their proximity to the second premolar, which did not permit total space closure.

In this case, the protraction of mandibular molars was achieved without any detrimental effect on facial balance. Two C-implants were placed in the buccal cortical bone of the mandibular arch to achieve the protraction of mandibular second and third molars after the extraction of first molars. The minimal variation in incisor position and the extensive molar protraction confirmed the excellent anchorage control provided by these mini-implants.

Even though the buccal alveolar bone available for placement of the C-implant is commonly placed in the mobile mucosa and shows the curvature of the mandibular arch, the unique two-component design and the long neck of the C-implant make it possible to prevent soft tissue coverage. In this case, plaque accumulation in the upper posterior dentition was prevented and posterior periodontal treatment was performed

simultaneously with orthodontic treatment, resulting in better periodontal health.

The period for molar protraction was relatively long. After 7 months of en masse retraction, the C-implant inserted between the lower first premolar and the second premolar was used to protract the lower second molar and the third molar for 22 months. However, the upper C-implants were removed after 16 months of treatment.

The mandibular third molars showed underdevelopment, and, in particular, the lower left third molar showed a tendency to become impacted horizontally. During the protraction of the lower second molar, the third molar drifted spontaneously forward. Afterwards, a fixed appliance was bonded and leveling was performed.

However, the posterior teeth were rotated, arch form in this area was slightly deformed, and the posterior occlusion was not well finished, with the posterior teeth not in contact on the right side (Figure 9). The planned restorative treatment of the malformed lower posterior teeth would have improved the occlusal relationship and stability during the retention period. Because the patient did not undergo the restorative treatment because of her personal circumstances, the alignment of the lower dentition is not ideal. However, the intercuspation with the corresponding upper dentition was acceptable. This occlusal relationship was maintained after 11 months of retention.

## CONCLUSIONS

- The C-implant was able to withstand multidirectional heavy forces required for this patient's treatment. Its unique two-component design and long neck helped avoid soft tissue irritation.

## REFERENCES

1. Dermaut LR, De Pauw G. Biomechanical aspects of Class II mechanics with special emphasis in deep bite correction as part of the treatment goal. In: Nanda R, editor. *Biomechanics in Clinical Orthodontics*. Philadelphia, PA: WB Saunders Co; 1997:86–98.
2. Melsen B, Verna C. A rational approach to orthodontic anchorage. *Prog Orthod*. 1999;1:10–22.
3. Arbuckle GR, Nelson CL, Roberts WE. Osseointegrated implants and orthodontics. *Oral Maxillofac Surg Clin North Am*. 1991;3:903–919.
4. Wehrbein H, Diedrich P. Endosseous titanium implants during and after orthodontic loading an experimental study. *Clin Oral Implants Res*. 1993;4:76–82.
5. Umemori M, Sugawara J, Mitani H, Nagasaka H, Kawamura H. Skeletal anchorage system for open-bite correction. *Am J Orthod Dentofacial Orthop*. 1999;115:166–174.
6. Kanomi R. Mini-implant for orthodontic anchorage. *J Clin Orthod*. 1997;31:763–767.
7. Costa A, Raffaini M, Melsen B. Microscrews as orthodontic

- anchorage: a preliminary report. *Int J Adult Orthod Orthognathic Surg.* 1998;13:201–209.
8. Maino BG, Bednar J, Pagin P, Mura P. The spider screw for skeletal anchorage. *J Clin Orthod.* 2003;37:90–97.
  9. Kyung HM, Park HS, Bae SM, Sung JH, Kim IB. Development of orthodontic micro-implants for intraoral anchorage. *J Clin Orthod.* 2003;37:321–328.
  10. Chung KR, Kim SH, Kook YA. C-orthodontic micro implant as a unique skeletal anchorage. *J Clin Orthod.* 2004;38:478–486.
  11. Chung KR, Kim SH, Mo SS, Kook YA, Kang SG. Severe Class II division 1 malocclusion treated by orthodontic miniplate with tube. *Prog Orthod.* 2005;6:172–186.
  12. Chung KR, Kim SH, Kook YA. C-orthodontic microimplant for distalization of mandibular dentition in class III correction. *Angle Orthod.* 2005;75:119–128.
  13. Lee SJ, Chung KR. The effect of early loading on the direct bone-to-implant surface contact of the orthodontic osseointegrated titanium implant. *Korea J Orthod.* 2001;31:173–185.
  14. Chung KR, Nelson G, Kim SH, Kook YA. Severe bidentalveolar protrusion treated with orthodontic microimplant dependent en masse retraction. *Am J Orthod Dentofacial Orthop.* In press.
  15. Cope JB. Temporary anchorage devices in orthodontics: a paradigm shift. *Semin Orthod.* 2005;11:3–9.
  16. Chung KR, Kim SH, Kook YA. *The C Implant.* In: Cope JB, ed. *Temporary anchorage devices in orthodontics.* 1st ed. Dallas, Texas: Under Dog Media. In Press, April 2006.
  17. Oyonarte P, Pilliar RM, Deporter D, Woodside DG. Peri-implant bone response to orthodontic loading: part 1. A histomorphometric study of the effects of implant surface design. *Am J Orthod Dentofacial Orthop.* 2005;128:173–181.
  18. Oyonarte P, Pilliar RM, Deporter D, Woodside DG. Peri-implant bone response to orthodontic loading: part 2. Implant surface geometry and its effect on regional bone remodeling. *Am J Orthod Dentofacial Orthop.* 2005;128:182–189.
  19. Kyung SH, Choi JH, Park YC. Miniscrew anchorage used to protract lower second molars into first molars extraction sites. *J Clin Orthod.* 2003;37:575–579.
  20. Giancotti A, Greco M, Mampieri G, Arcuri C. The use of titanium miniscrews for molar protraction in extraction treatment. *Prog Orthod.* 2004;5:236–245.