

## Bone tissue amount related to upper incisors inclination

Ana Carla Raphaelli Nahás-Scocate<sup>a</sup>; Aluana de Siqueira Brandão<sup>b</sup>; Mayara Paim Patel<sup>c</sup>; Michel Eli Lipiec-Ximenez<sup>d</sup>; Israel Chilvarquer<sup>e</sup>; Karyna Martins do Valle-Corotti<sup>a</sup>

### ABSTRACT

**Objective:** To evaluate the amount of buccal and lingual supporting bone tissue of 60 upper central incisors and the relationship with their inclination.

**Materials and Methods:** Thirty healthy adult patients with no previous orthodontic treatment were evaluated using cone-beam computed tomography. Cross-sectional views were analyzed to check the amount of the bone tissue on the cervical (cervical buccal thickness/CBT; lingual/CLT), middle (middle buccal thickness/MBT; lingual/MLT), and apical regions (apical buccal thickness/ABT; lingual/ALT). The Pearson correlation, linear regression, and analysis of variance tests were used ( $P < .05$ ).

**Results:** The values of ABT of both teeth (11, right upper central incisor; 21, left upper central incisor) were significantly increased with the increase in the angle between the axis of the upper central incisor and the palatal plane (1/PP) (tooth 11  $P = .034$ ; tooth 21  $P = .009$ ), yet without a strong linear correlation. At the buccal and lingual surfaces, the mean apical supporting bone tissue was significantly greater than the other areas, and the middle region significantly greater than the cervical ( $P < .001$ ).

**Conclusions:** For both surfaces (buccal and lingual), the amount of bone tissue in the apical region was significantly higher than the middle and cervical regions, and the middle region was significantly higher than the cervical region. In relation to the upper central incisor's inclination, the higher the 1/PP the higher was ABT. However, the coefficient values for both teeth were low. (*Angle Orthod.* 2014;84:279–285.)

**KEY WORDS:** Tomography; Bone Tissue; Orthodontics; Periodontics

### INTRODUCTION

Orthodontists need to take into consideration the appropriate biomechanics according to the patient's bone condition.<sup>1</sup> This is because any bone anatomic variation can be a limiting factor, therefore requiring

higher precautions during dental movements as in the case of bone dehiscence for instance.<sup>2,3</sup>

Gingival recession is the apical movement of the marginal soft tissue surrounding the tooth, exposing the root surface. This etiology is multifactorial, which includes bone dehiscence and inappropriate induced tooth movement. According to some studies, irreversible recession can be caused by fixed appliance therapy in 1.3% to 10.0% of treated cases.<sup>4,5</sup> Other studies affirm that the inclination of teeth does not interfere with the presence of gingival recession.<sup>6–8</sup> The relationship of root apex position and the amount of cortical alveolar bone is one other factor that may contribute to bone dehiscence.<sup>3</sup>

As a result of the imaging evolution in dentistry, diagnostic devices have become more precise and more reliable with three-dimensional detailed structures.<sup>9,10</sup> Cone-beam computed tomography (CBCT) is, nowadays, an excellent diagnostic tool for analysis of bone tissue amount.<sup>11</sup> CBCT demonstrates high accuracy and precise measurements related to the sharpness and resolution of images.<sup>12</sup> The spatial

<sup>a</sup> Associate Professor of Orthodontics, School of Dentistry, University of São Paulo City, São Paulo, Brazil.

<sup>b</sup> Orthodontic Graduate Student, School of Dentistry, University of São Paulo City, São Paulo, Brazil.

<sup>c</sup> Orthodontic Graduate Student, School of Dentistry, University of São Paulo, Bauru, Brazil.

<sup>d</sup> Specialist in Radiology, Bauru Dental School, University of São Paulo, Bauru, Brazil. Clinical director, INDOR, São Paulo, Brazil.

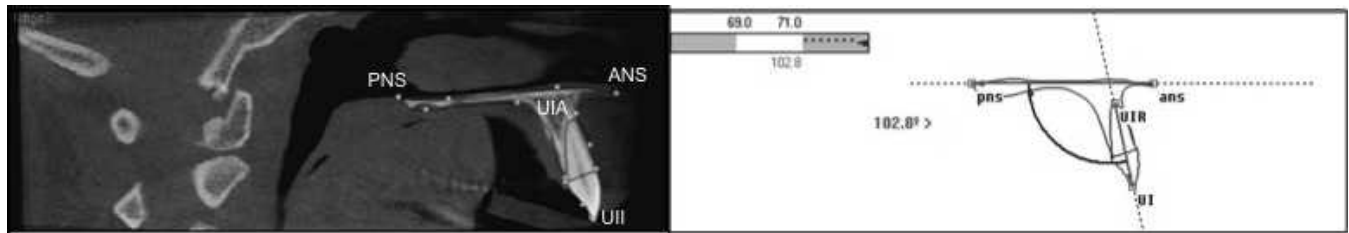
<sup>e</sup> Associate Professor of Radiology, School of Dentistry, University of São Paulo, São Paulo, Brazil.

Corresponding author: Dr Mayara Paim Patel, Rua Francisco Leitão, 115 Pinheiros, São Paulo, São Paulo 05414-025, Brazil (e-mail: mayarapaim@hotmail.com)

Accepted: June 2013. Submitted: March 2013.

Published Online: July 24, 2013

© 2014 by The EH Angle Education and Research Foundation, Inc.



**Figure 1.** 1/PP measurement (tooth 11) determined by the axis of the incisor (UII, upper incisor incisal; UIA, upper incisor apex) and the palatal plane (ANS, anterior nasal spine; PNS, posterior nasal spine).

resolution of the image depends on, among other factors, the size of the voxel, which represents the smallest unit of the image. The lower the voxel size, the greater the resolution image,<sup>13</sup> despite the high radiation dose.<sup>14</sup>

Important goals of orthodontic treatment are to maximize desired tooth movements and minimize undesirable consequences to the bone. It is of utmost importance to analyze meticulously the bone tissue in order to determine the most appropriate treatment procedures. The amount and quality of the bone tissue around the root as well as the position of the tooth apex need to be evaluated accurately to avoid periodontal complications and to prevent existing problems from worsening during orthodontic treatment.<sup>3</sup> Therefore, we aimed to evaluate and compare, through CBCT, the bone tissue amount in each area (cervical, middle, and apical) of buccal and lingual surfaces of the upper central incisors and to relate the bone tissue amount to the inclination in patients with no previous orthodontic treatment. We used images obtained with low voxel size of 0.25 mm to enhance the quality of the measurements.

## MATERIALS AND METHODS

This study was developed according to established precepts by the National Research Ethics Committee, approved under 13503809. Questionnaires were designed for patients who went to the Oral Radiology and Orthodontic Documentation Institute (INDOR), Sao Paulo, Brazil, to have maxillary and mandibular tomographic images. The inclusion criteria were: (1) skeletal Class I patients over 20 years of age, (2) both genders, (3) no previous history of orthodontic treatment, and (4) tomographs with a voxel size of 0.25 mm. The exclusion criteria were: (1) missing upper incisors or agenesis, (2) bone pathologies, (3) prosthesis or root canal treatment, (4) patients submitted to orthodontic treatment, (5) patients less than 20 or over 50 years of age and, (6) images suggesting periodontal disease. From 98 documentations, only 30 white Brazilian patients were selected to be part of the sample group with a mean age of 35.5 years (range 20 to 47 years of age), of which 18 were female (60%) and 12 were male (40%), with a total of 60 upper central incisors.

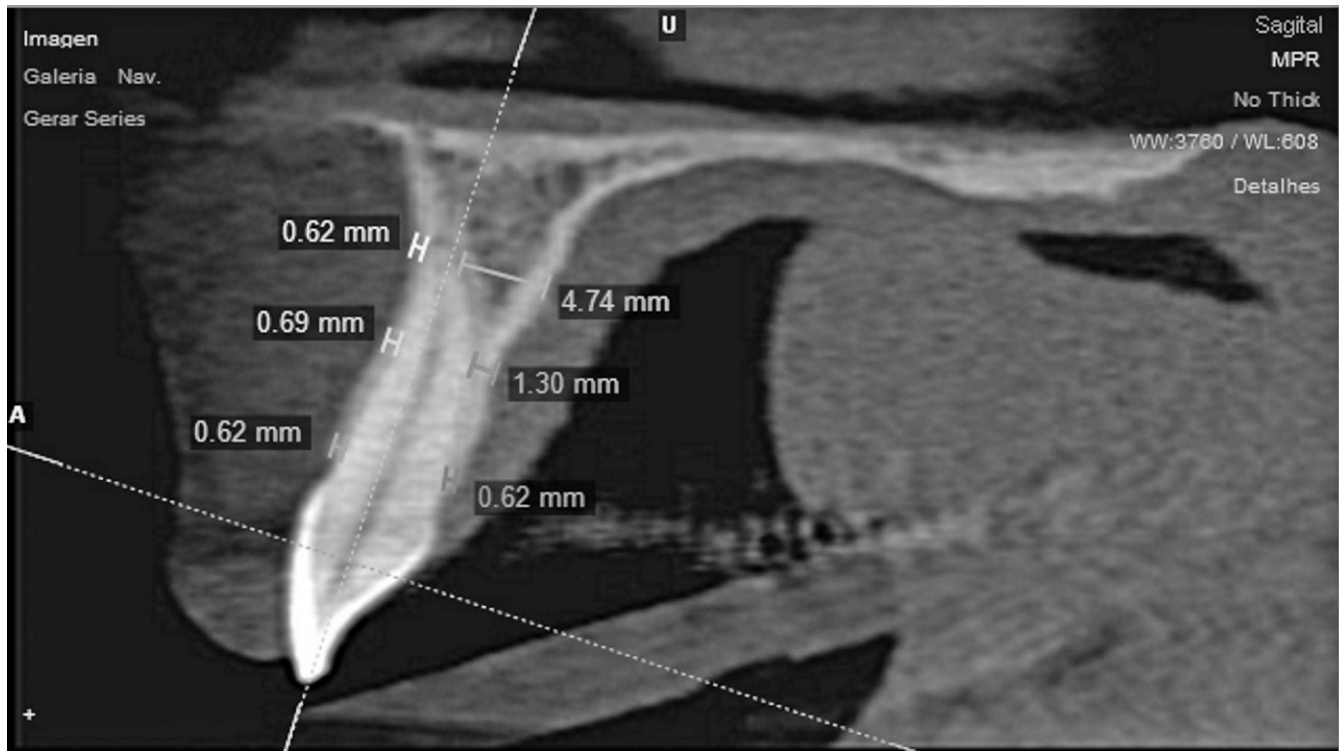
All images used in the study were obtained from the i-CAT tomography (Imaging Sciences International, Hatfield, Pa), with 8 mA, 120 kV, 40-second exposure time, isotropic voxel size of  $0.25 \times 0.25 \times 0.25$  mm, and 6-inch field of view. The files were acquired in Digital Imaging and Communications in Medicine (DICOM) format, and the images were processed and reconstructed by using NemoScanNxPro software (Nemotec SL, Madrid, Spain). Maxillary volumetric reformatting was performed and from this, sagittal images of teeth 11 and 21 (right upper central incisor and left upper central incisor) were obtained, and the most central slice of each element was used.

A trained investigator performed the measurements after having saved the sagittal images. The angle between the axis of the upper central incisor and the palatal plane was determined (1/PP) (Figure 1).

The measurements of the bone tissue amounts, buccal and lingual, of the 11 and 21 teeth were performed using their tomography images, in sagittal section, in the cervical, middle, and apical regions. To determine the “middle level,” the program’s measurement tool (ruler) was positioned parallel to the long axis of the incisor and perpendicular to the reference line (perpendicular line to the incisor long axis), thus identifying half of the distance from the marginal bone crest to the incisor apex. The measurements were calculated using the ruler in the three levels of evaluation, in both surfaces. The ruler was positioned parallel to the reference line and perpendicular to the tooth long axis, from the root surface to the most external limit of the cortical bone (Figure 2). The following abbreviations were created and applied: CBT, cervical buccal thickness; MBT, middle buccal thickness; ABT, apical buccal thickness; CLT, cervical lingual thickness; MLT, middle lingual thickness; and ALT, apical lingual thickness.

## Statistical Analysis

After 30 days, the examiner repeated the analysis of 15 randomly selected tomographs (half of the sample) to verify the reliability of the method. Student’s *t*-test, Bland-Altman plot agreement analysis, and Lin coefficient agreement were calculated.



**Figure 2.** Buccal and lingual bone tissue amounts of the upper central incisor (tooth 11).

To obtain the statistical analysis, first a descriptive analysis was performed to show the mean amount of the bone tissue on the cervical, middle, and apical regions of the buccal and lingual surfaces of the upper central incisors and of the 1/PP. The Pearson correlation coefficient, linear regression models (simple and multiple), were applied to evaluate the linear association of the variables CBT, MBT, ABT, CLT, MLT, and ALT with the 1/PP. Second, the Student's *t*-test was applied to compare the measurements between genders. Third, an analysis of variance (ANOVA) was used to compare the bone tissue amounts, followed by the Tukey multiple comparison test. An analysis was carried out for buccal and lingual surfaces. The software Minitab 14 was used to carry out these analyses, and the level of reliability established was 95%.

## RESULTS

According to the reproducibility tests, the intraobserver agreement was good, which represented acceptable method (Table 1).

Table 2 presents the descriptive statistics related to the variables of teeth 11 and 21, respectively.

Table 3 shows the Pearson correlation between each one of the variables CBT, MBT, ABT, CLT, MLT, and ALT and the 1/PP for both teeth studied.

In Table 3, the Pearson correlation between 1/PP and the amount of bone tissue illustrated a significant positive linear correlation for the ABT variable in both teeth. The findings showed that the higher the 1/PP value the higher the ABT value. However, the coefficient value was low, suggesting that although there was a significant linear correlation, this correlation was not persuasive.

In Tables 4 and 5, a model of simple linear regression for each variable was carried out using 1/PP as a dependent variable and ABT, MBT, CBT, ALT, MLT, and CLT as explanatory variables. The formula used was  $1/PP = b_0 + b_1X$ , with X being the explicative variables. From this analysis, it was evident that the ABT variables for teeth 11 ( $P = .034$ ) and 21 ( $P = .009$ ) were significant with a positive coefficient. However, the low coefficient values (12% for tooth 11 and 19.2% for tooth 21) indicate that this ABT variable was not sufficient to explain the variability of the 1/PP.

A multiple linear regression model was carried out for each tooth (11 and 21), using 1/PP as a dependent variable and the amount of bone tissue as the explicative variables. The formula used was  $1/PP = b_0 + b_1CBT + b_2MBT + b_3ABT = b_4CLT + b_5MLT + b_6ALT$ . By using this formula, no explicative variables were significant for tooth 11 ( $P > .056$ ). For tooth 21, the ABT variable ( $P = .019$ ) was significant in the presence of the other variables (Tables 6 and 7).

**Table 1.** Student's *t*-test, Bland-Altman Plot Agreement Analysis, and Lin Coefficient Agreement

Variable <sup>a</sup>	Measurement 1		Measurement 2		Bias	SE	P Value*	RI*	AL <sup>b</sup>	CC <sup>b</sup>
	Mean	SD	Mean	SD						
1/PP11	109.70	7.73	109.61	7.19	0.09	0.56	0.877	[-1.19; 1.37]	[-3.48; 3.66]	0.971
ABT11	1.38	0.68	1.28	0.69	0.10	0.06	0.105	[-0.03; 0.23]	[-0.26; 0.46]	0.954
MBT11	0.96	0.34	0.93	0.27	0.03	0.04	0.532	[-0.07; 0.12]	[-0.24; 0.29]	0.907
CBT11	0.73	0.32	0.78	0.23	-0.04	0.06	0.475	[-0.17; 0.09]	[-0.4; 0.31]	0.788
ALT11	6.87	1.52	6.76	1.20	0.10	0.20	0.622	[-0.35; 0.55]	[-1.16; 1.37]	0.891
MLT11	2.62	0.74	2.72	0.82	-0.11	0.08	0.221	[-0.29; 0.08]	[-0.62; 0.41]	0.937
CLT11	0.89	0.23	0.84	0.18	0.05	0.04	0.295	[-0.05; 0.15]	[-0.22; 0.32]	0.757
1/PP21	110.66	5.50	110.77	5.05	-0.11	0.71	0.881	[-1.72; 1.5]	[-4.62; 4.4]	0.909
ABT21	1.17	0.77	1.16	0.79	0.02	0.04	0.706	[-0.08; 0.12]	[-0.26; 0.29]	0.984
MBT21	0.77	0.21	0.78	0.18	-0.01	0.05	0.863	[-0.12; 0.11]	[-0.33; 0.31]	0.665
CBT21	0.63	0.40	0.61	0.35	0.02	0.03	0.444	[-0.04; 0.09]	[-0.17; 0.21]	0.966
ALT21	6.48	1.59	6.46	1.78	0.03	0.27	0.924	[-0.59; 0.65]	[-1.71; 1.76]	0.868
MLT21	2.49	0.82	2.41	0.83	0.08	0.05	0.188	[-0.04; 0.2]	[-0.26; 0.41]	0.975
CLT21	0.79	0.20	0.80	0.22	-0.01	0.06	0.870	[-0.14; 0.12]	[-0.39; 0.37]	0.597

<sup>a</sup> 1/PP indicates angle between the axis of the upper central incisor and the palatal plane; ABT, apical buccal thickness; MBT, middle buccal thickness; CBT, cervical buccal thickness; ALT, apical lingual thickness; MLT, middle lingual thickness; and CLT, cervical lingual thickness.

<sup>b</sup> AL, indicates Bland-Altman agreement limit; CC, Lin correlation coefficient.

\* P value, comparison between two repetitions,  $P < .05$  indicates statistical difference; RI, 95% reliable interval for the bias.

Table 8 shows the mean and standard deviation of bone tissue amount in each region (apical, middle, and cervical) on both surfaces for both teeth. Table 9 shows the results of one-way ANOVA and Tukey tests.

Considering the buccal surface, significant differences were found between the regions ( $P < .001$ ) in both teeth. The average amount of bone tissue was significantly higher in the apical region compared to the other two regions. In the cervical region, the amount of bone tissue was significantly lower than the other two regions (Tables 8 and 9).

**Table 2.** Descriptive Statistics Related to Teeth 11 and 21, Respectively<sup>a</sup>

Variable	Mean	SD	Minimum	Median	Maximum
1/PP tooth 11, degrees	106.81	8.00	90.80	107.30	124.50
ABT, mm	1.23	0.62	0.46	1.05	3.05
MBT, mm	0.97	0.39	0.34	0.95	2.28
CBT, mm	0.80	0.32	0.00	0.78	1.60
ALT, mm	6.43	1.75	2.38	6.65	9.53
MLT, mm	2.67	0.92	0.97	2.70	4.51
CLT, mm	0.83	0.27	0.29	0.88	1.44
1/PP tooth 21, degrees	107.38	7.81	92.10	105.95	128.30
ABT, mm	0.99	0.59	0.19	0.97	3.01
MBT, mm	0.83	0.30	0.32	0.83	1.48
CBT, mm	0.68	0.36	0.00	0.70	1.27
ALT, mm	6.51	1.68	3.24	6.40	9.52
MLT, mm	2.85	0.94	1.32	2.74	4.39
CLT, mm	0.79	0.25	0.40	0.74	1.42

<sup>a</sup> 1/PP indicates angle between the axis of the upper central incisor and the palatal plane; ABT, apical buccal thickness; MBT, middle buccal thickness; CBT, cervical buccal thickness; ALT, apical lingual thickness; MLT, middle lingual thickness; and CLT, cervical lingual thickness.

Considering the lingual surface, no significant differences were found between the teeth ( $P = .457$ ). However, there were significant differences between the regions ( $P < .001$ ) showing similar results as described in the buccal surface (Tables 8 and 9).

Table 10 shows Student's *t*-test considering the seven variables for both teeth, respectively, comparing genders. Significant differences were observed for MLT related to tooth 11 ( $P = .013$ ) and ALT ( $P = .011$ ), MLT ( $P = .008$ ), and CLT ( $P = .031$ ) to tooth 21 with values being higher in the male group. In relation to the other variables, no significant differences were found between genders.

## DISCUSSION

Even though there have been numerous publications about the orthodontic movement of the lower incisors and the related periodontal effects,<sup>1,6-9</sup> surprisingly no studies have been published on the quantitative relationship between the maxillary anterior bone support and the inclination of the upper incisors. The only scientific paper correlating the alveolar bone to the buccal-lingual inclination was published by Yamada et al.<sup>3</sup>; however, the study took into consideration only the lower central incisors in adults with untreated mandibular prognathism. Thus, this study, of 30 untreated adult patients, is the first effort to evaluate the bone tissue amount of buccal and lingual surfaces of the upper central incisors and to relate the bone tissue quantity to the inclination of the incisors.

As periodontal problems may arise due to orthodontic treatment, this issue has been a constant concern for orthodontists.<sup>15</sup> Therefore, several factors need to be taken into account when this subject is discussed.



**Table 3.** Pearson Correlation Between 1/PP and the Amount of Bone Tissue Variables<sup>a</sup>

Tooth	ABT	MBT	CBT	ALT	MLT	CLT
11	0.388 <i>P</i> = .034	0.180 <i>P</i> = .340	0.129 <i>P</i> = .497	-0.163 <i>P</i> = .389	0.105 <i>P</i> = .580	-0.171 <i>P</i> = .711
21	0.469 <i>P</i> = .009	-0.035 <i>P</i> = .856	0.182 <i>P</i> = .335	-0.141 <i>P</i> = .456	0.214 <i>P</i> = .257	0.087 <i>P</i> = .648

<sup>a</sup> ABT indicates apical buccal thickness; MBT, middle buccal thickness; CBT, cervical buccal thickness; ALT, apical lingual thickness; MLT, middle lingual thickness; and CLT, cervical lingual thickness.

Some of these important factors are the direction of movement, the frequency and magnitude of orthodontics forces, and the volume and anatomic integrity of the periodontal supporting tissues.<sup>16,17</sup> Under certain circumstances, excessive buccal and lingual tooth movements might contribute to a future periodontal problem such as bone dehiscence with an unfavorable mucogingival aspect, mainly in the anterior superior region. The need for a multidisciplinary approach and appropriate diagnostic tools are essential to determining the most appropriate orthodontic treatment procedures in order to contain undesirable long-term outcomes.<sup>18</sup>

As a result of the imaging evolution in dentistry, diagnostic tools have become more precise and more reliable with three-dimensional detailed structures.<sup>10</sup> The CBCT offers a realistic representation of the patient's anatomy; hence, it is an ideal tool to evaluate the characteristics and alveolar bone alterations. These images, in addition to being three-dimensional, are not subject to distortion or superimposition.

Furthermore, computerized reconstructions facilitate quantitative and qualitative evaluation of the alveolar bone surfaces as well as quantitative evaluation of the relationship between teeth and alveolar bone through the selection of desired sections.<sup>19</sup> Nauert and Berg<sup>1</sup> stated that accurate assessment of the bone support

of the lower incisors is only possible through the use of computed tomography.

Our study followed the voxel size protocol used by Evangelista et al.,<sup>17</sup> affirming that the accuracy of the data also depends on the high-resolution image, which is related to small voxel size in the CBCT.<sup>20</sup> In this study, computed tomography obtained with a 0.25-mm voxel was recommended because it resulted in greater accuracy of images, with a more detailed assessment of the buccal and lingual bone tissues. This technical parameter choice must be balanced between the clinical objectives of the examination and the dose of radiation exposure.

The inclination of the upper central incisors in subjects examined in this study showed significant positive linear correlation with the apical buccal thickness (tooth 11, *P* < .034; tooth 21, *P* < .009). In other words, ABT values increase when increasing 1/PP. Judging from these results, the amount of bone tissue in the apical buccal region seems to correspond to the inclination of the incisors.

No correlation was found for all other measurements of bone thickness with inclination of the incisors. These findings are consistent with those of Nauert and Berg<sup>1</sup> who documented no relationship between the amount of bone tissue and tooth inclination of the lower incisors. As there was no correlation between 1/PP

**Table 4.** Simple Linear Regression of ABT, MBT, CBT, ALT, MLT, and CLT Variables for Tooth 11<sup>a</sup>

Variable	Coefficient	Standard Error	<i>P</i> Value
Constant	100.60	3.11	.034*
ABT	5.05	2.28	
Constant	103.24	3.96	.340
MBT	3.69	3.80	
Constant	104.27	3.98	.497
CBT	3.18	4.62	
Constant	111.62	5.68	.389
ALT	-0.75	0.85	
Constant	104.37	4.61	.580
MLT	0.91	1.63	
Constant	108.57	4.92	.711
CLT	-2.11	5.63	

<sup>a</sup> ABT indicates apical buccal thickness; MBT, middle buccal thickness; CBT, cervical buccal thickness; ALT, apical lingual thickness; MLT, middle lingual thickness; and CLT, cervical lingual thickness.

\* Statistically significant at *P* < .001.

**Table 5.** Simple Linear Regression of ABT, MBT, CBT, ALT, MLT, and CLT Variables for Tooth 21<sup>a</sup>

Variable	Coefficient	Standard Error	<i>P</i> Value
Constant	101.28	2.52	.009*
ABT	6.18	2.20	
Constant	108.14	4.42	.856
MBT	-0.92	5.00	
Constant	104.68	3.10	.335
CBT	4.00	4.08	
Constant	111.66	5.84	.456
ALT	-0.66	0.87	
Constant	102.30	4.61	.257
MLT	1.78	1.54	
Constant	105.22	4.88	.648
CLT	2.74	5.94	

<sup>a</sup> ABT indicates apical buccal thickness; MBT, middle buccal thickness; CBT, cervical buccal thickness; ALT, apical lingual thickness; MLT, middle lingual thickness; and CLT, cervical lingual thickness.

\* Statistically significant at *P* < .001.

**Table 6.** Multiple Linear Regression for Tooth 11: 1/PP With ABT, MBT, CBT, ALT, MLT, and CLT Variables<sup>a</sup>

Variable	1/PP 11		
	Coefficient	Standard Error	P Value
Constant	100.30	8.60	<.001
ABT	6.49	3.23	.056
MBT	-1.26	4.62	.788
CBT	-0.59	4.79	.903
ALT	-0.48	1.15	.679
MLT	3.00	2.00	.146
CLT	-5.66	6.66	.405

<sup>a</sup> 1/PP indicates angle between the axis of the upper central incisor and the palatal plane; ABT, apical buccal thickness; MBT, middle buccal thickness; CBT, cervical buccal thickness; ALT, apical lingual thickness; MLT, middle lingual thickness; and CLT, cervical lingual thickness.

angle and most of the bone tissue amount variables, we perhaps have to consider that the 1/PP angle did not vary considerably between the patients in the sample group. Additionally, these patients have not been submitted to orthodontic treatment that might have contributed to excessive buccal or lingual tooth inclination movements beyond biologic limits.

The results of this study appear to support the assumption that individual anatomic variation has to be taken into consideration when assessing potential iatrogenic treatment effects. Before initiating orthodontic treatment, careful analysis of the bone prerequisite is of importance in determining the type of biomechanics to be used. Especially in the treatment of adults with possible periodontically induced bone loss in the upper incisor area, careful treatment planning is essential. Furthermore, in patients needing more extensive orthodontic movements, and those who have a less favorable gingival biotype such as thin attached gingival, a three-dimensional diagnosis of alveolar bone is recommended to preserve periodontal health during and after treatment.<sup>17</sup>

**Table 7.** Multiple Linear Regression for Tooth 21: 1/PP With ABT, MBT, CBT, ALT, MLT, and CLT Variables<sup>a</sup>

Variable	1/PP 21		
	Coefficient	Standard Error	P Value
Constant	102.43	9.08	<.001
ABT	6.39	2.54	.019*
MBT	-2.94	5.21	.578
CBT	-1.26	4.25	.769
ALT	-1.32	1.14	.261
MLT	3.17	1.78	.088
CLT	1.90	6.32	.766

<sup>a</sup> 1/PP indicates angle between the axis of the upper central incisor and the palatal plane; ABT, apical buccal thickness; MBT, middle buccal thickness; CBT, cervical buccal thickness; ALT, apical lingual thickness; MLT, middle lingual thickness; and CLT, cervical lingual thickness.

\* Statistically significant at  $P < .05$ .

**Table 8.** Mean and Standard Deviation of Bone Tissue Amount on Buccal and Lingual Surfaces in Each Region, Considering Both Teeth

Region	Buccal		Lingual	
	Mean	SD	Mean	SD
Apical	1.11	0.61	6.47	1.70
Middle	0.90	0.35	2.76	0.93
Cervical	0.74	0.34	0.81	0.26

The current study also showed that in the buccal and lingual surface, significant differences were found between regions ( $P < .001$ ) for both teeth. The average amount of alveolar bone was significantly higher for the apical region compared to the other two regions and significantly higher for the middle region compared to the cervical. Once again, the clinical relevance of our results is to alert orthodontic specialists about the necessity to regard the individual biologic characteristics and to be attentive during the biomechanics throughout the treatment. The buccal movement of the incisors has traditionally been considered a risk factor due to the smaller amount of alveolar bone in the cervical region compared with the middle and apical regions. This can predispose the patient to periodontal problems such as the bone dehiscence and fenestration and may lead to gingival recession.

Significant differences were found between genders for MLT related to tooth 11 ( $P = .013$ ) and ALT ( $P = .011$ ), MLT ( $P = .008$ ), and CLT ( $P = .031$ ) for tooth 21. These values show that in male patients there is a greater amount of lingual bone tissue. According to Uysal et al.,<sup>19</sup> men generally have larger bone dimensions than women. The differences of the thickness in relation to gender can be explained by a bony compensatory phenomenon (remodeling). The bone remodels by physiologic load (strain) such as bite force (190 N in men and 50 N in women).

## CONCLUSIONS

- For both teeth, the higher the 1/PP value, the higher the ABT bone tissue amount; however, the coefficient value was low.

**Table 9.** ANOVA and Tukey Tests<sup>a</sup>

Buccal Surface	P Value
A vs M	.003
A vs C	<.001
C vs M	.023
Lingual Surface	P Value
A vs M	<.001
A vs C	<.001
C vs M	<.001

<sup>a</sup> A indicates apical; M, middle; and C, cervical.

**Table 10.** Student's *t*-test to Show the Results Between Genders for Both Teeth (18 Female; 12 Male)<sup>a</sup>

	Female		Male		<i>P</i> Value
	Mean	SD	Mean	SD	
1/PP 11	105.46	7.19	110.26	8.12	.112
ABT	0.88	0.45	1.14	0.75	.299
MBT	0.81	0.29	0.88	0.31	.164
CBT	0.75	0.33	0.56	0.38	.183
ALT	5.92	1.69	7.40	1.27	.011*
MLT	2.48	0.82	3.39	0.85	.008*
CLT	0.70	0.20	0.91	0.27	.031*
1/PP 21	105.41	7.36	108.93	8.78	.265
ABT	1.20	0.60	1.28	0.66	.750
MBT	0.88	0.32	1.10	0.46	.164
CBT	0.80	0.29	0.80	0.38	.956
ALT	6.05	1.75	7.00	1.65	.144
MLT	2.35	0.88	3.17	0.78	.013*
CLT	0.76	0.24	0.95	0.27	.059

<sup>a</sup> 1/PP indicates angle between the axis of the upper central incisor and the palatal plane; ABT, apical buccal thickness; MBT, middle buccal thickness; CBT, cervical buccal thickness; ALT, apical lingual thickness; MLT, middle lingual thickness; and CLT, cervical lingual thickness.

\* Statistically significant at  $P < .05$ .

- Both surfaces in both teeth, the amount of bone tissue in the apical region was significantly higher than the middle and cervical regions. In the middle region, the amount of bone tissue was significantly higher than the cervical region.
- There was a significant difference between genders in relation to the MLT for tooth 11 and ALT, MLT, and CLT for tooth 21. The values were higher in the male group compared to the female group.

## REFERENCES

- Nauert K, Berg R. Evaluation of labio-lingual bony support of lower incisors in orthodontically untreated adults with the help of computed tomography. *J Orofac Orthop.* 1999;60:321–334.
- Gracco A, Lombardo L, Mancuso G, Gravina V, Siciliani G. Upper incisor position and bony support in untreated patients as seen on CBCT. *Angle Orthod.* 2009;79:692–702.
- Yamada C, Kitai N, Kakimoto N, Murakami S, Furukawa S, Takada K. Spatial relationships between the mandibular central incisor and associated alveolar bone in adults with mandibular prognathism. *Angle Orthod.* 2007;77:766–772.
- Alstad S, Zachrisson BU. Longitudinal study of periodontal condition associated with orthodontic treatment in adolescents. *Am J Orthod.* 1979;76:277–286.
- Dorfman HS. Orthodontic aspects of occlusion. *J Ala Dent Assoc.* 1978;62:58–63.
- Djeu G, Hayes C, Zawaideh S. Correlation between mandibular central incisor proclination and gingival recession during fixed appliance therapy. *Angle Orthod.* 2002;72:238–245.
- Melsen B, Allais D. Factors of importance for the development of dehiscences during labial movement of mandibular incisors: a retrospective study of adult orthodontic patients. *Am J Orthod Dentofacial Orthop.* 2005;127:552–561; quiz 625.
- Yared KF, Zenobio EG, Pacheco W. Periodontal status of mandibular central incisors after orthodontic proclination in adults. *Am J Orthod Dentofacial Orthop.* 2006;130:6.e1–8.
- Patcas R, Muller L, Ullrich O, Peltomaki T. Accuracy of cone-beam computed tomography at different resolutions assessed on the bony covering of the mandibular anterior teeth. *Am J Orthod Dentofacial Orthop.* 2012;141:41–50.
- Timock AM, Cook V, McDonald T, et al. Accuracy and reliability of buccal bone height and thickness measurements from cone-beam computed tomography imaging. *Am J Orthod Dentofacial Orthop.* 2011;140:734–744.
- Cevitanes LH, Franco AA, Scanavini MA, Vigorito JW, Enlow DH, Proffit WR. Clinical outcomes of Frankel appliance therapy assessed with a counterpart analysis. *Am J Orthod Dentofacial Orthop.* 2003;123:379–387.
- Ludlow JB, Laster WS, See M, Bailey LJ, Hershey HG. Accuracy of measurements of mandibular anatomy in cone beam computed tomography images. *Oral Surg Oral Med Oral Pathol Oral Radiol Endod.* 2007;103:534–542.
- Molen AD. Considerations in the use of cone-beam computed tomography for buccal bone measurements. *Am J Orthod Dentofacial Orthop.* 2010;137(4 suppl):S130–135.
- Farman AG, Scarfe WC. Development of imaging selection criteria and procedures should precede cephalometric assessment with cone-beam computed tomography. *Am J Orthod Dentofacial Orthop.* 2006;130:257–265.
- Turpin DL. Periodontal screening: a basic part of the orthodontic examination. *Angle Orthod.* 1994;64:163–164.
- Boyd RL, Leggott PJ, Quinn RS, Eakle WS, Chambers D. Periodontal implications of orthodontic treatment in adults with reduced or normal periodontal tissues versus those of adolescents. *Am J Orthod Dentofacial Orthop.* 1989;96:191–198.
- Evangelista K, Vasconcelos Kde F, Bumann A, Hirsch E, Nitka M, Silva MA. Dehiscence and fenestration in patients with Class I and Class II Division 1 malocclusion assessed with cone-beam computed tomography. *Am J Orthod Dentofacial Orthop.* 2010;138:133.e1–7; discussion 134–136.
- Nahás-Scocate AC. The importance of knowledge and the benefits of interdisciplinary treatment. *Orthodontics (Chic).* 2011;12:285–286.
- Uysal T, Yagci A, Ozer T, Veli I, Ozturk A. Mandibular anterior bony support and incisor crowding: is there a relationship? *Am J Orthod Dentofacial Orthop.* 2012;142:645–653.
- Ballrick JW, Palomo JM, Ruch E, Amberman BD, Hans MG. Image distortion and spatial resolution of a commercially available cone-beam computed tomography machine. *Am J Orthod Dentofacial Orthop.* 2008;134:573–582.