

A Novel Method for the Assessment of Three-Dimensional Tooth Movement during Orthodontic Treatment

Insan Jang^a; Motohiro Tanaka^b; Yoshiyuki Koga^c; Seiko Iijima^b;
Joseph H. Yozgatian^d; Bong Kuen Cha^e; Noriaki Yoshida^f

ABSTRACT

Objective: To (1) evaluate the stability of palatal rugae as landmarks for superimposition of dental casts and (2) establish a three-dimensional superimposition method of maxillary dental casts for analyzing orthodontic tooth movement.

Materials and Methods: The sample consisted of dental casts obtained from 10 patients treated with extraction of bilateral maxillary first premolars and placement of three palatal miniscrews as anchorage for retraction of the anterior teeth. Dental casts were measured by means of laser surface scanning system, and three-dimensional images were reconstructed. Serial dental casts were superimposed on the three miniscrews as registration landmarks (miniscrew-superimposition method), and the displacement of each palatal ruga point during the closure of extraction spaces was measured. Displacement of the central incisors was measured by the miniscrew-superimposition method and the proposed superimposition technique (ruga-palate-superimposition method). Correlation analysis and paired *t*-tests were performed to determine whether a significant difference existed between the measurements of the two superimposition methods.

Results: The medial points of the third palatal rugae and the shape of the palatal vault were stable throughout the treatment. The displacement of the central incisors measured using the ruga-palate-superimposition method showed no significant difference with that measured using the miniscrew-superimposition method.

Conclusion: The maxillary dental casts can be reliably superimposed on the medial points of the third palatal rugae and the palatal vault as reference landmarks. (*Angle Orthod.* 2009;79:447–453.)

KEY WORDS: Palatal rugae; Superimposition; Miniscrew; Stability; Dental cast; Landmark

INTRODUCTION

Superimposition of serial cephalometric radiographs has been a widely used method to evaluate orthodon-

tic tooth movement. However, a cephalometric radiograph is a two-dimensional (2D) projection of three-dimensional (3D) structures, and it has certain limitations and disadvantages, such as blurring, overlapping of anatomic structures, magnification, as well as inevitably subjecting patients to radiation exposure. With the development of 3D measuring devices, some investigators have performed 3D superimposition of dental casts to analyze orthodontic tooth movement.^{1–5} Nevertheless, a stable reference area for superimpo-

^a PhD Graduate Student, Department of Orthodontics and Dentofacial Orthopedics, Nagasaki University Graduate School of Biomedical Sciences, Nagasaki, Japan.

^b Assistant Professor, Department of Orthodontics and Dentofacial Orthopedics, Nagasaki University Graduate School of Biomedical Sciences, Nagasaki, Japan.

^c Senior Assistant Professor, Department of Orthodontics and Dentofacial Orthopedics, Nagasaki University Graduate School of Biomedical Sciences, Nagasaki, Japan.

^d Former Postgraduate Student, Department of Orthodontics and Dentofacial Orthopedics, Nagasaki University Graduate School of Biomedical Sciences, Nagasaki, Japan, and Orthodontic private practice, Beirut, Lebanon

^e Professor and Chair, Department of Orthodontics, College of Dentistry, Kangnung National University, Gangneung, South Korea.

^f Professor and Chair, Department of Orthodontics and Den-

tofacial Orthopedics, Nagasaki University Graduate School of Biomedical Sciences, Nagasaki, Japan.

Corresponding author: Dr Noriaki Yoshida, Department of Orthodontics and Dentofacial Orthopedics, Nagasaki University, Sakamoto1-7-1, Nagasaki City, 852-8588, Japan
e-mail: nori@nagasaki-u.ac.jp)

Accepted: June 2008. Submitted: April 2008.

© 2009 by The EH Angle Education and Research Foundation, Inc.

sition of dental casts remains unclear. Superimposition of serial cephalometric radiographs uses skeletal structures such as the cranial base, the maxilla, or the mandible as reference points or lines.⁶ On the other hand, superimposition of dental casts has inherent limitations due to lack of anatomic reference points or areas for superimposition.

Some investigators have evaluated the stability of the palatal rugae during orthodontic treatment.⁷⁻¹⁰ In patients treated with a functional appliance or head-gear, the medial ruga points appeared more stable than the lateral ruga points.⁸ In the comparison of tooth movement measured by cephalometric superimposition relative to the ruga points on study models, the medial points of the third palatal rugae are suggested to be suitable reference points for the assessment of anteroposterior tooth movement.¹⁰ Conversely, another study reported that the lateral points of the third rugae are the most stable.⁷ Thus, identification of the most stable area is still controversial.

To our knowledge, no study has determined 3D displacement of individual ruga points during orthodontic treatment. The present study is the first attempt to evaluate the stability of each palatal ruga point in three dimensions by means of laser surface scanning system. This study was composed of two experiments. The purposes of the two investigations were (1) to evaluate the stability of palatal rugae as landmarks for superimposition of dental casts and (2) to establish a 3D superimposition method of maxillary dental casts.

EXPERIMENT 1: EVALUATION OF THE STABILITY OF THE PALATAL RUGAE

Materials and Methods

The sample consisted of dental casts obtained from 10 patients (4 males and 6 females) who were undergoing orthodontic treatment after a diagnosis of maxillary protrusion at the Orthodontic Department, Nagasaki University Hospital of Medicine and Dentistry. Their ages ranged from 15 years 7 months to 27 years (mean = 20 years). Subjects were given informed consent forms, and the research protocol was examined and approved by the Ethical Committee of Nagasaki University Graduate School of Biomedical Sciences. As part of the orthodontic treatment, bilateral maxillary first premolars were extracted, and three miniscrews were implanted onto the palate by an oral surgeon. Two were placed on the palatal slopes bilaterally between the second premolar and the first molar, and another one was placed on the paramedian region of the hard palate. These three miniscrews were ligated with a transpalatal arch by ligature wires to reinforce orthodontic anchorage (Figure 1), and used as landmarks for superimposition.

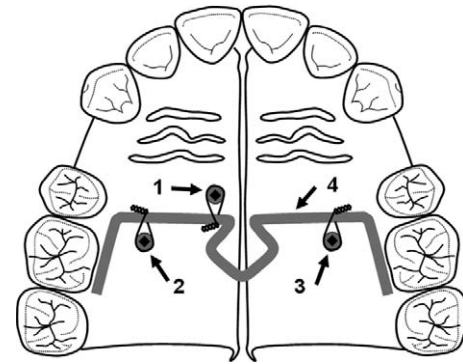


Figure 1. Three miniscrews were implanted onto the palate and ligated with a transpalatal arch by ligature wires. 1–3, miniscrews; 4, transpalatal arch.

Individual trays were fabricated with resin (Tray resin, Shofu Inc, Kyoto, Japan) and impressions for maxillary dental cast were taken using hydrophilic vinyl polysiloxane impression material (Examixfine, GC Corporation, Tokyo, Japan) at every visit after the miniscrews were placed until the extraction spaces were closed. Dental casts were made with improved dental stone (New fujirock, GC Corporation, Tokyo, Japan) and then scanned by a laser surface scanning system (VMD-25, UNISN, Osaka, Japan). The measuring pitch in the x and y directions was 0.25 mm, and the resolution in the z direction was within the range of ± 0.05 mm. Based on scanned data, reconstruction and analysis of 3D images was performed using a commercial software (Imageware 9, UGS PLM Solutions, Plano, Tex).

The rugae were identified as the first, second, and third rugae sequentially from anterior to posterior.¹¹ The most medial and lateral ends of each ruga on the right and left sides were marked on 3D images of dental casts and registered as palatal ruga points, as illustrated in Figure 2.

To evaluate the stability of the palatal ruga points, the 3D images of the serial dental casts were super-

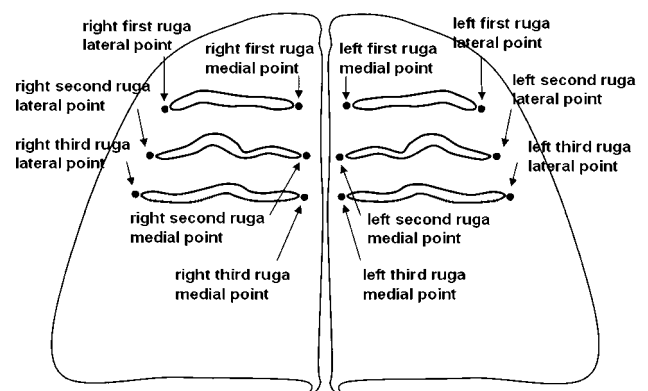


Figure 2. Twelve palatal ruga points.

Table 1. Displacement of the palatal ruga points from the initial to final dental casts (n = 10)^a

Palatal Ruga Point	Displacement in 3D Space					CV, %	X (Mesiodistal Direction)		Y (Vertical Direction)		Z (Transverse Direction)	
	Mean	SD	95% Confidence Interval		Mean		SD	Mean	SD	Mean	SD	
			Lower	Upper								
R1L	1.64	0.78	1.15	2.13	48	-0.55	1.53	0.43	0.55	-0.22	0.60	
L1L	1.75	0.83	1.23	2.26	48	-1.11	1.27	0.26	0.59	-0.34	0.73	
R1M	1.02	0.73	0.57	1.47	71	-0.62	0.98	0.16	0.19	-0.03	0.48	
L1M	1.26	1.01	0.63	1.88	81	-0.63	1.23	0.25	0.61	-0.04	0.60	
R2L	0.79	0.36	0.57	1.01	45	-0.31	0.59	0.16	0.33	-0.02	0.48	
L2L	1.04	0.53	0.71	1.37	51	-0.60	0.66	0.12	0.45	-0.13	0.65	
R2M	0.60	0.25	0.45	0.75	41	0.05	0.35	0.16	0.45	0.03	0.31	
L2M	0.55	0.24	0.40	0.70	43	-0.09	0.33	0.19	0.29	-0.12	0.36	
R3L	0.59	0.27	0.42	0.76	46	0.08	0.35	0.19	0.36	-0.01	0.40	
L3L	0.61	0.21	0.48	0.75	35	-0.23	0.27	0.02	0.34	-0.12	0.45	
R3M	0.28	0.08	0.23	0.33	30	-0.04	0.16	0.14	0.13	0.05	0.16	
L3M	0.37	0.13	0.29	0.45	34	-0.06	0.22	0.17	0.20	-0.03	0.23	

^a SD indicates standard deviation; CV, coefficient of variation; R1L, right first ruga lateral point; R2L, right second ruga lateral point; R3L, right third ruga lateral point; R1M, right first ruga medial point; R2M, right second ruga medial point; R3M, right third ruga medial point; L1M, left first ruga medial point; L2M, left second ruga medial point; L3M, left third ruga medial point; L1L, left first ruga lateral point; L2L, left second ruga lateral point; L3L, left third ruga lateral point. Positive values indicate the mesial, extrusive, and lateral direction in the x, y, and z axes, respectively.

imposed with best-fitting method on the three miniscrews as stationary landmarks for superimposition using the least-squares method. This superimposition method was referred to as the miniscrew-superimposition method. The displacement of each palatal ruga point from the initial to final dental casts was measured. To evaluate the direction of displacement the coordination system of Cha et al¹ was used.

The reproducibility of the method. To evaluate the reproducibility of the method, impressions for 10 patients were taken twice on the same day, and 10 pairs of dental casts were made. After the 3D images were reconstructed, one ruga point was selected arbitrarily and marked on the 3D images. Each pair of dental cast images was superimposed on the miniscrews, and the distance between respective rugae points was measured. The mean error of the method was 0.29 mm (range = 0.19 mm to 0.55 mm; standard deviation = 0.11 mm). Random error,¹² calculated by the Dahlberg formula, was 0.22 mm.

Results

Displacement of the palatal ruga points from the initial to final dental cast images is presented in Table 1. Displacements of the lateral points were larger than those of the medial points for the first, second, and third palatal rugae, respectively. Among the lateral points of the palatal rugae, the largest amount of displacement was observed for the first palatal rugae, followed by the second palatal rugae; the third palatal rugae showed the smallest amount of displacement. The medial points of the palatal rugae also had the same tendency as the lateral points of palatal rugae.

Mean displacement of the medial points of the third rugae was smaller than that of the other ruga points (Table 1). Also, the standard deviation and coefficient of variation of the medial points of the third rugae were the smallest. The direction and amount of displacement of each ruga point in the x, y, and z axes are also shown in Table 1. Interestingly, the rugae points had a tendency to be displaced to the distal, extrusive, and medial direction during the closure of extraction spaces.

The scattergrams presented in Figure 3 show the relationship between the displacement of the rugae points and the central incisor movement. Displacement of the first ruga point was increased as the central incisor moved further. The slope of the regression lines of the medial points of the third ruga was close to zero, which indicates that these points were rarely affected by the central incisor movement.

Figure 4 represents the 3D superimposing image of the initial and final dental casts of a sample patient. The contour of the anterior region of the palate located adjacent to retracted anterior teeth was displaced distally, as shown in Figure 4B. The contour of the posterior region of the palatal vault was not considerably changed during closure of the extraction spaces, as shown in sagittal and coronal sectional views of the superimposing images (Figure 4B,C).

Discussion

By using three miniscrews as stationary landmarks for superimposition, we could evaluate the stability of each palatal ruga point during the closure of extraction spaces. The third rugae points, which were located

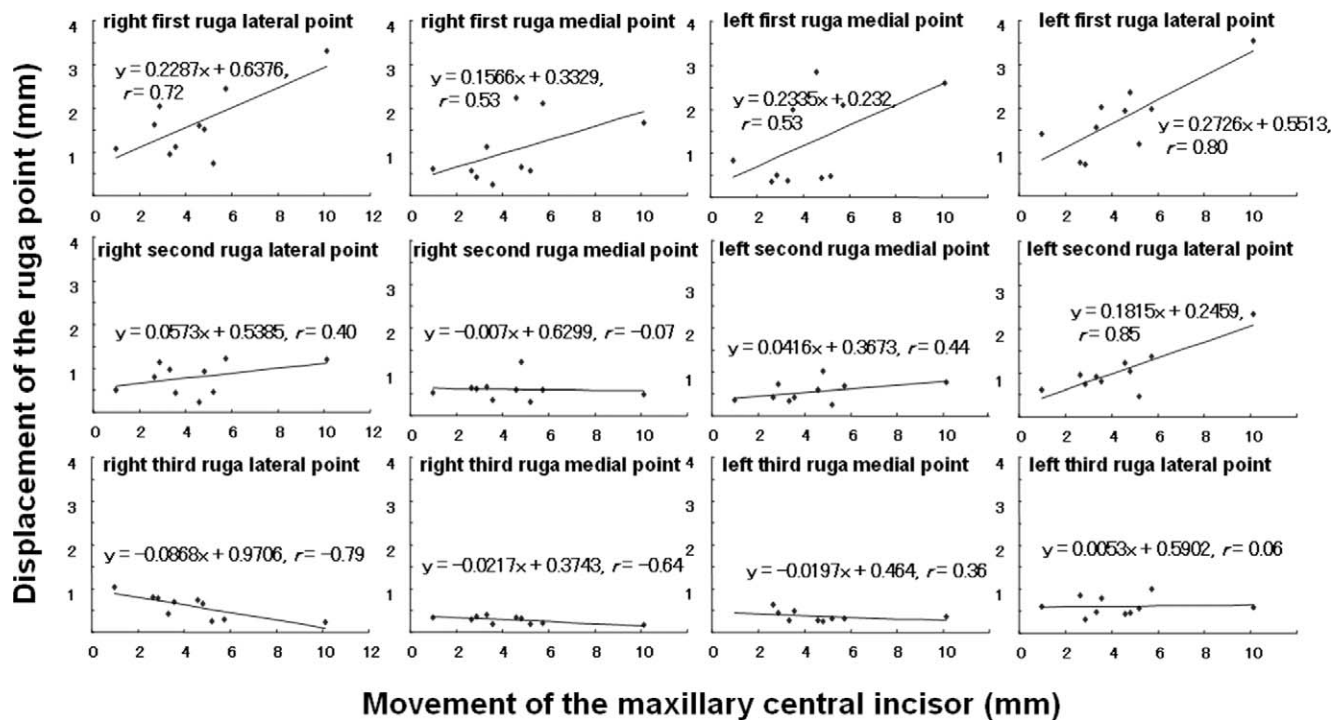


Figure 3. Scattergrams of the central incisor movement versus displacements of the rugae points. Regression lines were drawn and the equations with correlation coefficients (r) were determined.

farther from the retracted anterior teeth were more stable than the first and second rugae points. This result supports the earlier study by van der Linden,¹³ which noted that the closer the ruga point is located to the displaced teeth, the more the ruga point will be affected. In addition, there was a tendency for medial ruga points to be displaced less substantially than lateral ruga points. The medial points of the third palatal rugae were the least influenced from the tooth movement (Table 1).

The amount of tooth movement may affect the stability of the palatal rugae.⁹ As presented in Figure 3, the displacement of the ruga points increased gradually as the tooth moved farther. The medial points of the third rugae seemed not to be affected, because no increase in the displacement was found in the medial points of the third palatal rugae.

The reproducibility of the method was estimated by measuring two different dental casts taken twice from the same patient instead of repeatedly measuring a single cast. The mean error of the method was 0.29 ± 0.11 mm, which may be due to the dimensional change of impression material, thermal expansion of dental casts, and human error when marking the ruga points on 3D images and performing superimposition on the miniscrews as registration landmarks. The mean displacement of the medial points of the right and left third rugae, which were 0.28 mm and 0.37

mm, respectively, are not considered actual displacement, but error of the method.

Therefore, our results lead us to conclude that the medial points of the third rugae are stable enough to be used as landmarks for superimposition of dental casts. Our findings support the earlier reports^{10,14} that suggested the possibility of using the medial points of the third palatal rugae as reference points for assessing orthodontic tooth movement. The superimposing images using the miniscrew superimposition method also showed that the posterior region of the palatal vault is least affected by tooth movement (Figures 4B,C).

EXPERIMENT 2: ESTABLISHMENT OF THE 3D SUPERIMPOSITION METHOD

Materials and Methods

The 3D images of serial dental casts for each patient were superimposed without using the three miniscrews as registration landmarks. Instead, the following superimposition landmarks were identified on the 3D images (Figure 5):

- Point A: the midpoint on the line connecting the medial points of the right and left third palatal rugae.
- Surface B: the surface of the palatal vault surrounded by two transverse and two anteroposterior lines. One of the transverse lines is 10 mm away distally

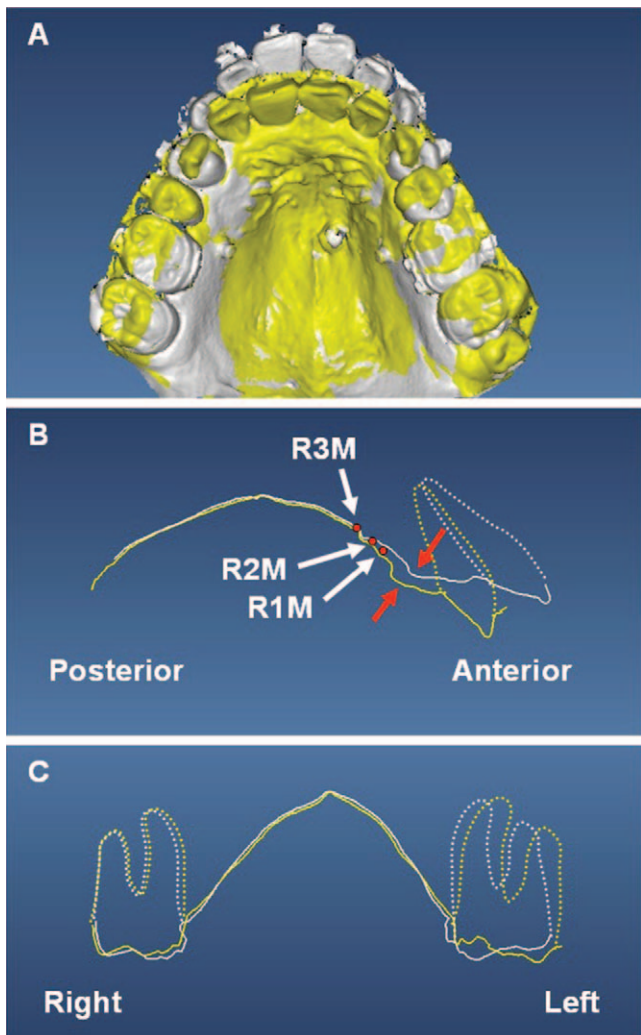


Figure 4. Superimposed images of the initial (white) and final (yellow) dental casts registered at three miniscrews for a sample patient. Outlines of the roots of the right central incisor and bilateral first molars are depicted with dotted lines. (A) Occlusal view of the 3D image. (B) Sagittal sectional view at the level of the maxillary right central incisor. The contour of the anterior region of the palate displaced distally (red arrows). R1M, right first ruga medial point; R2M, right second ruga medial point; R3M, right third ruga medial point; C, coronal sectional view at the level of the first molars.

from the third palatal rugae, and the other is 5 mm away mesially from the line in contact with the distal surfaces of the bilateral maxillary second molars. On the palatal side, the anteroposterior lines are 10 mm from the lines in contact with the palatal gingival margins of the posterior teeth bilaterally.

Registered at point A, the surface B of the subsequent dental cast was best-fitted to that of the initial dental cast using the least-square method. This superimposition method was referred to as ruga-palate-superimposition method.

The midpoints of the right central incisor edges were marked on the initial and final dental casts, and su-

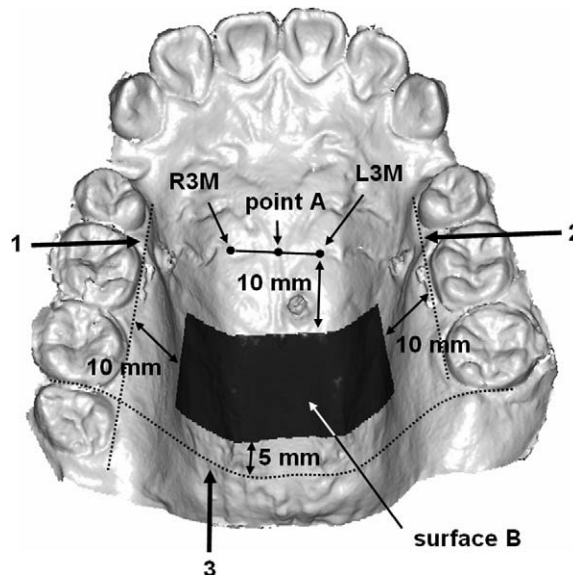


Figure 5. Landmarks for superimposition of dental casts. Point A and surface B were constructed from the right and left third ruga medial points (R3M and L3M, respectively) and the surface of the palatal vault. 1, 2 indicates the lines in contact with the palatal gingival margins of the posterior teeth bilaterally; 3, the line in contact with the distal surfaces of the bilateral maxillary second molars.

perimposition was performed using the miniscrew-superimposition method and the ruga-palate-superimposition method. Displacement of the midpoint of the right central incisor edge was measured, and correlation analysis and paired *t*-test were performed to determine whether a significant difference existed between the measurements according to the two superimposition methods. The null hypothesis was that the difference between the measurements of the two superimposition methods was zero. $P < .01$ was considered statistically significant.

The reproducibility of the superimposition method. To evaluate the reproducibility of the miniscrew-superimposition method and the rugae-palate-superimposition method, the initial and final dental cast images of 10 patients were superimposed five times and the displacement of the midpoints of the right central incisor edges was measured. The reproducibility, expressed as the intraclass correlation coefficient, was 0.997 for the miniscrew-superimposition method and 0.998 for the ruga-palate-superimposition method, which indicates that the two superimposition methods were successfully reproduced.

Results

Descriptive statistics of the measurements using the miniscrew-superimposition method and the ruga-palate-superimposition method are presented in Table 2. The displacement of the central incisor measured by

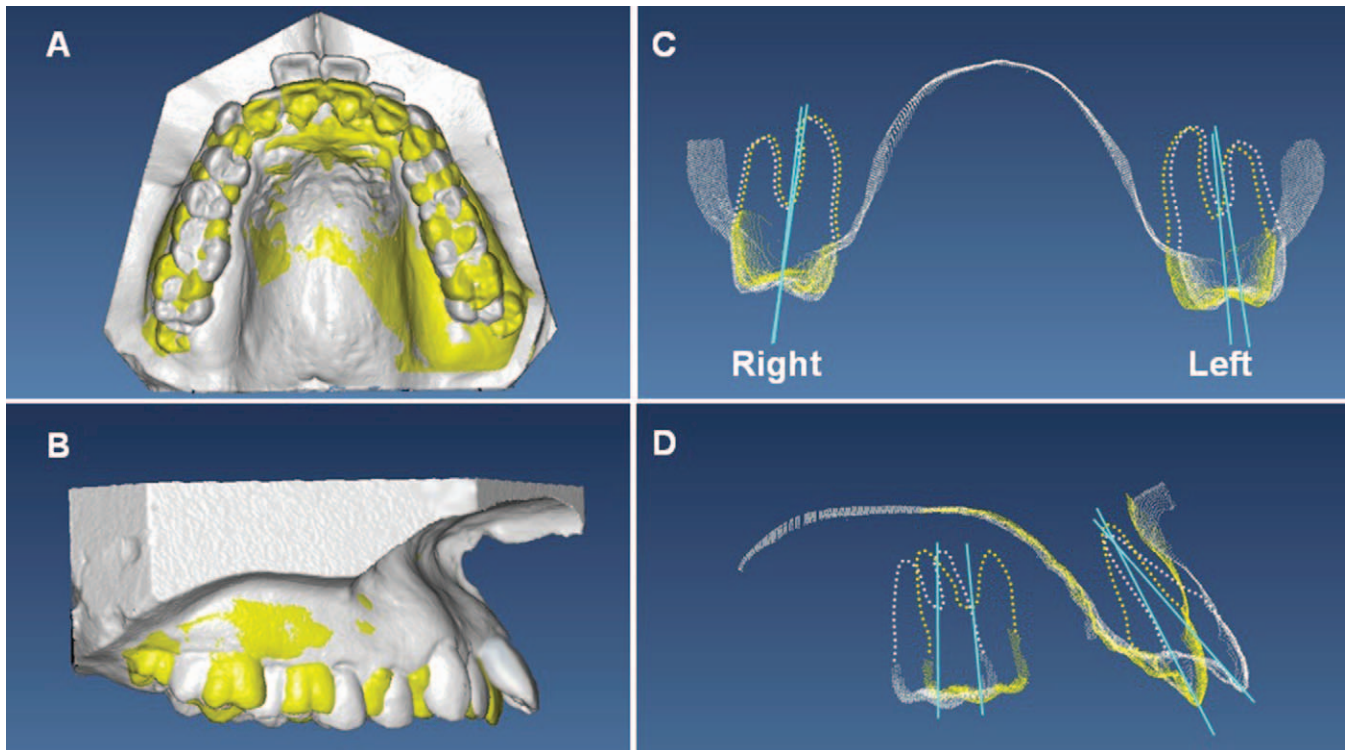


Figure 6. The 3D superimposing image of maxillary dental casts before (white) and after (yellow) orthodontic treatment for a sample patient by means of the ruga-palate-superimposition method. The axes (blue solid lines) and the outlines of the roots (dotted lines) of the central incisor and the first molar are depicted. (A) Occlusal view; (B) Lateral view from the right side; (C) Coronal sectional view at the level of the maxillary first molars; (D) Sagittal sectional view of the maxillary central incisor and the first molar on the right side.

the ruga-palate-superimposition method was not significantly different from that measured by the miniscrew-superimposition method ($P < .01$, paired t -test). The Pearson correlation coefficient between the measurements obtained using the two superimposition methods was 0.99.

Discussion

Based on the experiment 1, which showed that the medial points of the third palatal rugae and the posterior region of the palatal vault are stable throughout the closure of the extraction spaces, we performed a superimposition using these areas as registration landmarks in experiment 2. The displacement of the central incisor measured using the ruga-palate-superimposition method was not significantly different from that measured using the miniscrew-superimposition

method (Table 2), which indicated that maxillary dental casts can be superimposed reliably using the ruga-palate-superimposition method. Consequently, the 3D superimposition method can even be applied to patients who are not candidates for using skeletal anchorage such as miniscrews. This superimposition method is available, not only as an additional tool of cephalometric radiographs but also as a principal method for determining progress of treatment using dental casts taken at required intervals during the treatment (thus avoiding unnecessarily exposing the patients to radiation). Furthermore, the 3D evaluation of orthodontic tooth movement, such as the changes in angulation of the posterior teeth and the central incisors, which was not possible with cephalometric superimposition, can now be accomplished using this superimposition method of dental casts.

The 3D images cannot be superimposed only on the right and left medial points of the third rugae as registration landmarks, because more than three registration points are required to establish an individually specific 3D coordinate system for conducting 3D superimposition. To overcome this problem, we used the posterior region of the palatal vault, together with the medial points of the third palatal rugae, to construct landmarks for superimposition; thus, we could suc-

Table 2. Displacement of the central incisors measured on the superimposing images by means of the miniscrew-superimposition method and the ruga-palate-superimposition method^a

Method	Mean (mm)	SD	r	t	P
Miniscrew-superimposition	3.22	1.94	0.99	1.21	0.26
Ruga-palate-superimposition	3.14	2.04			

^a SD indicates standard deviation.

cessfully superimpose dental casts with high accuracy. The use of the palatal vault area alone to obtain registration landmarks is also considered undesirable. This area has insufficient shape characteristics; as a result, the registration rotates from its true registration position.

The samples in the present study were obtained from patients who were not expected to have an apparent growth. The height and breadth of alveolar processes of children increase with craniofacial growth,¹⁵ and the shape or direction of rugae can possibly change.^{2,16} Thus, there is a limitation in applying this superimposition method to the dental casts of growing children.

Clinical application. To demonstrate a clinical application of the developed 3D superimposition method, we selected one sample patient, a 24-year-old woman who underwent orthodontic treatment with extraction of maxillary first premolars and in whom no skeletal anchorage, such as miniscrews, was used. Maxillary dental casts taken before and after treatment were superimposed according the ruga-palate-superimposition method. As presented in Figure 6, the displacement of individual teeth during orthodontic treatment could be visualized in three dimensions. The displacement of the central incisors, as measured by the distance between the midpoints of their edges, was 5.9 mm (right), 5.6 mm (left). The displacement of the first molars, as measured by the distance between the mesial contact points, was 3.7 mm (right), 4.4 mm (left). We projected the bilateral maxillary first molars onto the coronal plane (Figure 6C) and calculated the change in angulation. The crown of the right first molar tipped palatally by 1.0°, and that of the left first molar tipped palatally by 3.5° during treatment. The axis of the central incisor projected on the sagittal plane was retroclined by 19° during treatment (Figure 6D).

CONCLUSIONS

- The medial points of the third palatal rugae are stable enough to be used as landmarks for superimposition of maxillary dental casts.
- The maxillary dental casts can be superimposed reliably using the medial points of the third rugae and the palatal vault for constructing landmarks for superimposition.

REFERENCES

1. Cha BK, Lee JY, Jost-Brinkmann PG, Yoshida N. Analysis of tooth movement in extraction cases using three-dimensional reverse engineering technology. *Eur J Orthod.* 2007; 29:325–331.
2. Ashmore JL, Kurland BF, King GJ, Wheeler TT, Ghafari J, Ramsay DS. A 3-dimensional analysis of molar movement during headgear treatment. *Am J Orthod Dentofacial Orthop.* 2002;121:18–29.
3. Hayashi K, Araki Y, Uechi J, Ohno H, Mizoguchi I. A novel method for the three-dimensional (3-D) analysis of orthodontic tooth movement-calculation of rotation about and translation along the finite helical axis. *J Biomech.* 2002; 35(1):45–51.
4. Hayashi K, Uechi J, Murata M, Mizoguchi I. Comparison of maxillary canine retraction with sliding mechanics and a retraction spring: a three-dimensional analysis based on a midpalatal orthodontic implant. *Eur J Orthod.* 2004;26:585–589.
5. Yao CC, Lee JJ, Chen HY, Chang ZC, Chang HF, Chen YJ. Maxillary molar intrusion with fixed appliances and mini-implant anchorage studied in three dimensions. *Angle Orthod.* 2005;75:754–760.
6. Proffit WR, Fields HW, Sarver DM. Orthodontic diagnosis: the development of a problem list. In: *Contemporary Orthodontics*. 4th ed. St Louis, Mo: Mosby Elsevier; 2007: 167–233.
7. Abdel-Aziz HM, Sabet NE. Palatal rugae area: a landmark for analysis of pre- and post-orthodontically treated adult Egyptian patients. *East Mediterr Health J.* 2001;7(1–2):60–66.
8. Almeida MA, Phillips C, Kula K, Tulloch C. Stability of the palatal rugae as landmarks for analysis of dental casts. *Angle Orthod.* 1995;65:43–48.
9. Bailey LT, Esmailnejad A, Almeida MA. Stability of the palatal rugae as landmarks for analysis of dental casts in extraction and nonextraction cases. *Angle Orthod.* 1996;66: 73–78.
10. Hoggan BR, Sadowsky C. The use of palatal rugae for the assessment of anteroposterior tooth movements. *Am J Orthod Dentofacial Orthop.* 2001;119:482–488.
11. Lysell L. Plicae palatinae transversae and papilla incisiva in man; a morphologic and genetic study. *Acta Odontol Scand.* 1955;13(suppl 18):5–137.
12. Houston WJ. The analysis of errors in orthodontic measurements. *Am J Orthod.* 1983;83:382–390.
13. van der Linden FP. Changes in the position of posterior teeth in relation to ruga points. *Am J Orthod.* 1978;74:142–161.
14. Christou P, Kiliaridis S. Vertical growth-related changes in the positions of palatal rugae and maxillary incisors. *Am J Orthod Dentofacial Orthop.* 2008;133:81–86.
15. Le Bret L. Growth changes of the palate. *J Dent Res.* 1962; 41:1391–1404.
16. Simmons JD, Moore RN, Erickson LC. A longitudinal study of anteroposterior growth changes in the palatine rugae. *J Dent Res.* 1987;66:1512–1515.