

Contact of the incisive canal and upper central incisors causing root resorption after retraction with orthodontic mini-implants: A CBCT study

Yichen Pan^a; Si Chen^b

ABSTRACT

Objectives: To explore risk factors for contact between the incisive canal (IC) and upper central incisors (U1) and to evaluate the relationship between contact and root resorption using cone-beam computer tomography (CBCT).

Materials and Methods: This retrospective study used CBCT data of 33 patients treated by a senior orthodontist. Anterior teeth were retracted with mini-implants, and CBCT scans were taken before and after retraction. IC height and width, U1 lingual movement, and U1-IC distance and root length decrease were compared between contact and noncontact groups.

Results: Sixteen U1 roots in 11 patients touched the IC. The contact group had lower positioned ICs (2.86 ± 1.10 mm) than the noncontact group (4.07 ± 1.72 mm). The middle of the U1 roots showed more lingual movement to ICs in the contact group (2.30 ± 1.20 mm) than in the noncontact group (1.07 ± 1.16 mm). Right central incisors were closer to the IC than were the left. Root length decreased significantly more in the contact group (2.63 ± 0.93 mm) than in the noncontact group (1.14 ± 0.83 mm).

Conclusions: There is a risk for the U1 root to contact the IC during anterior retraction when the IC is lower positioned. This contact might cause external apical root resorption. (*Angle Orthod.* 2019;89:200–205.)

KEY WORDS: Incisive canal; Upper central incisors; Root resorption; CBCT

INTRODUCTION

The position of the upper anterior teeth is closely related to the lower third of the facial profile. In orthodontics, facial esthetics can be improved through retraction of the upper anterior teeth for patients with the chief complaint of protrusion. The wide application of mini-implants has enabled orthodontists to retract the anterior teeth to the greatest extent by providing maximum anchorage.¹

Limits of orthodontic treatment have long been questioned. Moving the teeth out of the cortical bone may cause complications such as fenestration, dehiscence, or root resorption.^{2,3} The limit of retracting maxillary anterior teeth has commonly been considered the palatal cortical plate.² In recent years, however, craniofacial anatomical studies have shown that the distance from upper central incisors (U1) to the incisive canal (IC) was smaller than that to the palatal cortical plate.⁴ The IC connects the oral cavity and nasal cavity with two openings: the incisive foramen and nasal foramen.^{5,6} In addition, the IC morphology and position may greatly influence the angulation and position for dental implant placement.^{7,8}

Approximation of the IC and U1 should also affect orthodontic retraction of the anterior teeth. Nakada et al.⁹ found that mesial movement of the root apex during orthodontic retraction might lead to its contact with the IC cortical plate and cause apical root resorption. Chung et al.¹⁰ noticed in two cases that in conducting en masse retraction with the help of orthodontic mini-implants, the root of one of the U1 made direct contact with the cortical plate of the IC and extensive root

^a Postgraduate Student, Department of Orthodontics, Peking University School and Hospital of Stomatology, Beijing, China.

^b Associate Professor, Department of Orthodontics, Peking University School and Hospital of Stomatology, Beijing, China.

Corresponding author: Dr Si Chen, associate professor, Department of Orthodontics, Peking University School and Hospital of Stomatology, No. 22 Zhongguancun S Ave, Haidian District, Beijing 100081, China
(e-mail: elisa02@163.com)

Accepted: October 2018. Submitted: April 2018.

Published Online: November 28, 2018

© 2019 by The EH Angle Education and Research Foundation, Inc.

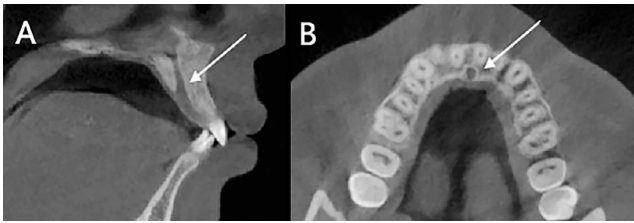


Figure 1. Sagittal (A) and axial (B) image of the IC (arrow) by CBCT.

resorption was observed. Cho et al.¹¹ analyzed the proximity of U1 and the IC using computed tomography and found the IC width larger than the inter-root distance in more than 60% of subjects and that the “safety zone” of orthodontic retraction was smaller than previously believed.

Routine 2D X-ray examinations do not reveal whether U1 roots meet the IC cortical plate but cone-beam computer tomography (CBCT) enables visualization of the spatial morphology of the IC.¹² The present study explored the risk factors for contact between the IC and U1 and evaluated, using CBCT, the relationship between this contact and root resorption in patients who received maximum anterior tooth retraction with orthodontic mini-implants.

MATERIALS AND METHODS

Materials

This retrospective study included data from 33 patients (20 adults and 13 teenagers), retrieved from the archive of National Engineering Laboratory for Digital and Material Technology of Stomatology collected from 2009 to 2012.¹³ These patients were treated by one orthodontist, and the anterior teeth of these patients were retracted with mini-implants using the same mechanics.¹³ CBCT scans (DCT pro; Vatech & EWO Group, Seoul, South Korea) were taken immediately after placement of miniscrews and after the completion of retraction using the following protocol: field of view, $200 \times 190 \text{ mm}^2$; 90 KVp; 144 mA; scan time, 24 seconds; and voxel size, 0.3 mm^3 . The average retraction period was 11.8 months. Informed consent of all patients was obtained and the protocol was approved by the Institutional Review Board (IRB00001052-09010).

The study included patients (1) with CBCT data before and after the retraction period; (2) without obvious root resorption and root morphology variation before retraction; (3) with extraction of at least two upper premolars to provide space for retraction; (4) with a convex facial profile; (5) with a Class I or II skeletal or molar relationship; (6) with retraction of the upper anterior teeth with mini-implants for maximum anchorage; and (7) without missing teeth or extra teeth

in the anterior maxillary region. All the data from the archive that met the criteria of this study were included.

The patients' data were saved in Digital Imaging and Communication in Medicine (DICOM) format and imported into Dolphin software (version 11.8 premium, Dolphin Imaging and Management Solutions, Chatsworth, CA). Head position was standardized to ensure that axial sections were parallel to the Frankfort plane, and sagittal sections were vertical to the axial plane and parallel to the connection of the anterior nasal spine (ANS) and posterior nasal spine (PNS). Coronal sections were then vertical to both the axial and sagittal sections.

CBCT Measurements

Axial and sagittal sections used for this study were collected from each sample (Figure 1 is shown as an example). The 3D measurement function of Dolphin was used to conduct the following measurements:

The ANB angle before retraction was measured from the lateral view of the 3D reconstruction of the CBCT scans.

IC height was defined as the vertical distance between the incisive foramen plane and the cemento-enamel junction (CEJ) (Figure 2A). The incisive foramen plane was defined as the horizontal plane passing through the lowest point of the buccal wall of the IC.

IC width was defined as the transverse distance parallel to coronal sections between the most distal points of the IC (Figure 2B). The IC width was measured at three horizontal levels determined in the sagittal view (Figure 2C). To ensure the consistency of the observed levels, the vertical distance between each level and the horizontal line passing through ANS in the preretraction images was recorded and then transferred to postretraction images. In each patient, the average width of the three levels was calculated.

U1-IC distances were measured at the same horizontal levels mentioned already and were defined as the anteroposterior distance from the most mesial point of the U1 to the cortical plate of the IC (Figure 2B). Left and right values were recorded separately. U1-IC distances were unmeasurable when the inter-root distance was wider than the IC width, in which case they were not analyzed. U1-IC decrease was defined as the difference between the pre- and post-treatment U1-IC distance. When the root contacted (including invading into) the IC, the distance was recorded as 0 mm.

The root length of left and right U1 before and after retraction were measured in the sagittal view (Figure 2D).

Pre- and post-retraction CBCT images were superimposed on the miniscrews¹³ (Figure 3A). Inclination

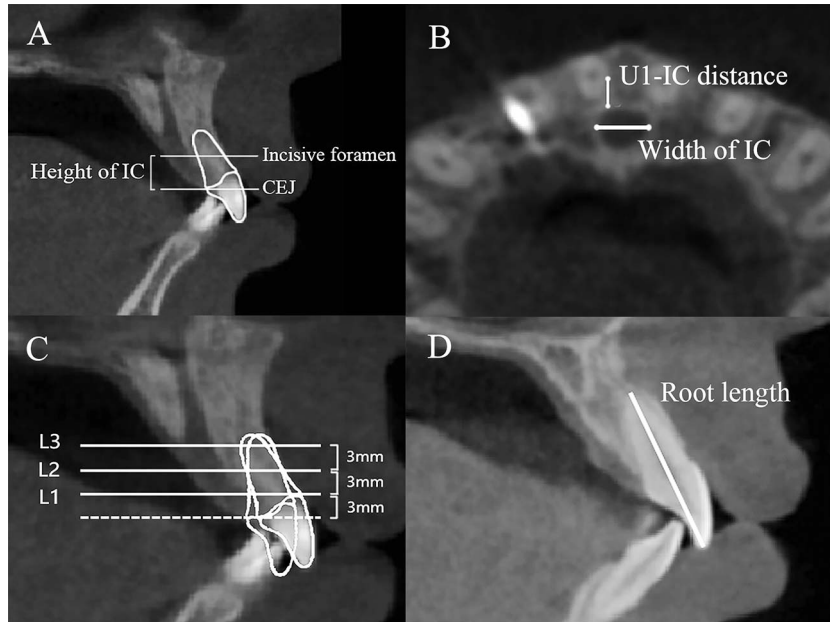


Figure 2. (A) Incisive foramen plane, the horizontal plane passing through the lowest point of the buccal wall of the IC; IC height, the vertical distance between the incisive foramen plane and CEJ; (B) IC width, the transverse distance between the most distal point of the IC; U1-IC distance, the anteroposterior distance from the most mesial point of U1 to the cortical plate of the IC; (C) Three observed horizontal levels, 3 mm, 6 mm, and 9 mm above the palatal CEJ (dotted line); (D) Root length, the distance from the incisal edge to the root apex.

change of U1 ($\Delta U1/FH$) and horizontal retraction distance (HRD) of U1 were measured from the superimpositions (Figure 3B).

Statistical Analysis

All measurements were conducted by two trained examiners. The intraclass correlation (ICC) was 0.98. The measurement error¹⁴ for linear and angular measurement were 0.22 mm and 0.26°. To compare the IC heights and widths, patients were divided into

contact and noncontact groups. To compare the HRD and $\Delta U1/FH$, U1-IC decreases and root length decreases, all the U1 roots were divided into the two groups. When the data showed a normal distribution, *t* tests were used; otherwise, Mann-Whitney *U*-tests were used to compare the measurements between groups. Wilcoxon’s test was used to compare the U1-IC distance between left and right sides. The statistical analyses were performed with SPSS 27.0 (IBM, Armonk, NY), with a significance level of 0.05.

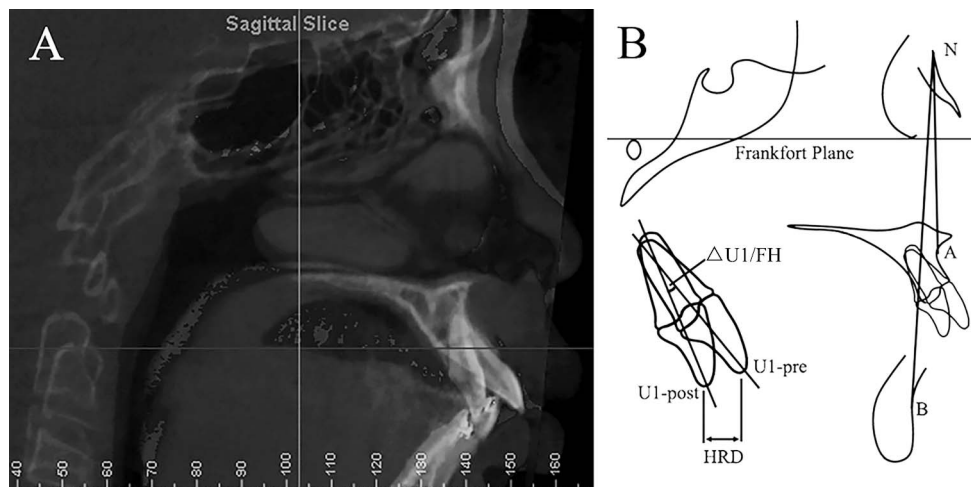


Figure 3. (A) Superimposition of pre- and postretraction CBCT; (B) Measurements: ANB, the angle between NA and NB; U1/FH, the angle between the long axis of U1 and the Frankfort plane; HRD (horizontal retraction distance), horizontal distance between the pre- and post-retraction incisal edge of U1.

Table 1. Preretraction Descriptive Measurements of the Patients

	Adult	Teenager	P Value
Gender			
Male	6	4	
Female	14	9	
Age	25.35 ± 5.12	12.76 ± 1.09	
ANB, °	5.77 ± 1.74	5.44 ± 1.42	.57
IC Height, mm	3.90 ± 1.71	3.42 ± 1.46	.45
Average IC width, mm	5.57 ± 0.54	5.48 ± 0.63	.65

RESULTS

Descriptive Statistics

Preretraction information is listed in Table 1. Thirty-three patients were included. The age was 12.76 ± 1.09 years for teenagers and 25.38 ± 5.09 years for adults at the start of treatment. The ANB angle was 5.53° and 5.25° in the adult and teenage group, respectively, before retraction. No significant gender difference (data not shown) or age difference was found in any measurement. Therefore, adults and teenagers were analyzed as a whole. In total, 16 U1 roots in 11 patients touched the IC.

IC Height

There was no significant difference in the IC height between adults (3.90 mm) and teenagers (3.42 mm) (Table 1). However, it was significantly lower in the contact group (2.86 mm) than in the noncontact group (4.07 mm) (Table 2), which indicated that the U1 tended to touch an IC that was positioned lower.

IC Width

No significant difference was found in the IC width between adults and teenagers (Table 1). There was no significant difference in the average IC width between the noncontact and contact groups (Table 2).

Distances Between U1 and IC

In a total of 66 U1, the decrease in U1-IC distance was significantly larger in the contact group than in the noncontact group at L2 (Table 2), indicating more lingual root movement of U1 to the IC in the contact group; whereas, at L3, the U1-IC distance increased in some patients, indicating buccal movement of the root apex.

U1-IC distances in the right U1 were smaller than those in the left, either before ($P = .04$) or after ($P < .01$) retraction (data not shown).

Retraction of U1

No significant difference was found in retraction of the incisal edge (HRD) and $\Delta U1/FH$ of U1 between the noncontact and contact groups (Table 2).

Decreases in Root Length

Ten right and six left incisor roots in 11 patients touched the IC (Table 3). In the axial view, the canal wall cortex became discontinuous and, in the sagittal view, the incisor root apparently entered the IC, with or without significant root resorption (Figure 4).

The root length decrease was significantly greater in the contact group than in the noncontact group (Table 3), showing that U1-IC contact might cause excessive apical root resorption.

In some cases, tipping of the U1 (with more buccal movement of the root apex) made the cervical area of the root more prone to invade the IC (Figure 5), but cervical root resorption was difficult to measure in those cases.

DISCUSSION

The IC connects the incisive foramen and the nasal foramen;¹⁵ its morphology and position was shown to vary from person to person and was also affected by age¹⁶ and gender.^{5,6} Reportedly, adults had smaller ICs and thinner labial alveolar bones than teenagers,¹⁷ and

Table 2. Comparisons of the Risk Factors Causing U1-IC Contact Between Noncontact and Contact Groups^a

	Non-contact	Contact	P Value
No. of patients	N = 22	N = 11	
IC Height, mm	4.07 ± 1.72	2.86 ± 1.10	.04*
IC Width, mm	5.46 ± 0.58	5.68 ± 0.55	.29
No. of U1 roots	N = 50	N = 16	
HRD of U1, mm	5.21 ± 1.95	6.21 ± 2.37	.09
$\Delta U1/FH$, °	13.84 ± 5.91	12.63 ± 5.34	.45
U1-IC decrease, mm			
L1	1.25 ± 1.91 (n=17)	2.24 ± 1.43 (n = 7)	.12
L2	1.07 ± 1.16 (n=44)	2.30 ± 1.20 (n = 14)	<.01**
L3	1.34 ± 1.79 (n=43)	1.99 ± 1.74 (n = 14)	.26

* $P < .05$; ** $P < .01$.

^a N refers to total number of patients or U1 roots, n refers to number of roots at the specific level.

Table 3. Root Length Decrease in Noncontact and Contact Groups

	Noncontact N = 50	Contact N = 16	P Value
Root length decrease, mm	1.14 ± 0.83	2.63 ± 0.93	<.01**

** $P < .01$.

men had wider^{5,6} and longer^{18,19} ICs than women; but no significant gender and age difference was found in the current study, probably because of the relatively small sample size. For now, it is still uncertain how intrusion of a tooth root into the IC would influence the function of internal nerves or vessels,⁴ but it was reported that, in a surgery extracting a supernumerary tooth, that intrusion into the IC caused a hematoma one week after the operation.⁷ It was emphasized in prosthodontics and oral implantology that image diagnoses should be conducted before restoration⁷ but, in orthodontics, few studies have paid attention to the approximation of U1 and the IC.¹¹

In past studies, the opening of the IC (the incisive foramen) was defined as the lowest point of the palatal wall.^{9,11} However, in the present investigation, it was found that the concavity could be seen at the lowest point of the buccal wall. Therefore, the horizontal levels selected in this study were more incisal relative to U1s than in past studies. The current study suggested that IC height was a risk factor for U1-IC contact, which meant that, in patients with a lower incisive foramen, U1s were more susceptible to touching the IC during retraction.

IC width in this study was similar to that in the study of Zhou et al.²⁰ and slightly larger than that in the study of Cho et al.,¹¹ possibly due to the different selection of measurement levels. Although IC width was not found to be a risk factor in the current study, an excessively wide IC should also be a warning for increased risk because Cho et al.¹¹ found a wider IC than inter-root distance in over 60% of subjects.

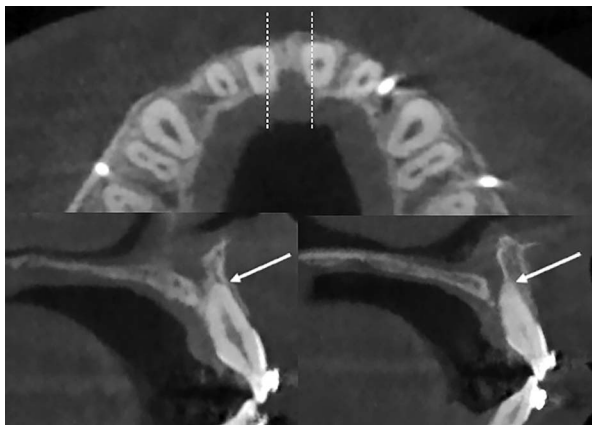


Figure 4. Apical root resorption (arrow) related to contact between the U1 apex and the IC.

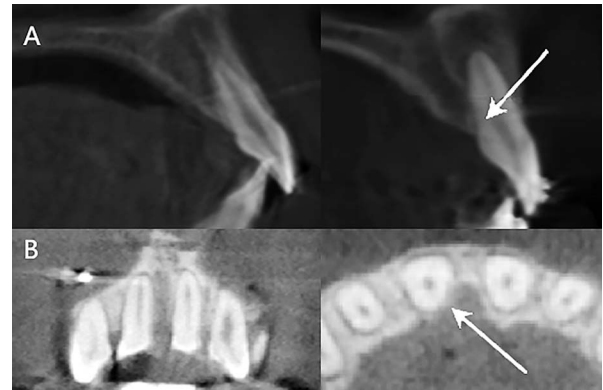


Figure 5. Cervical root resorption (arrow) caused by contact between the U1 root neck and the IC.

Nakada et al.⁹ believed that midline drift during orthodontic treatment may cause apical root resorption related to the IC but that lingual movement of the central incisors was also a contributing factor. Because of the oval shape of the IC and the tooth roots, the U1-IC distances were larger than the shortest distance between the two structures. However, since it is very difficult to set a standard definition for the shortest distance from U1 roots to the IC, anteroposterior distances were used.¹¹ In the current study, measurements were conducted at three horizontal levels because the root apex and tooth neck could move in opposite directions. For example, at L3, an increased U1-IC distance was found in some of the patients, implying buccal movement of the root apex, which could also explain the statistically insignificant difference between the contact and noncontact groups. At L2, a position closer to the middle of the root, the decrease in the U1-IC distance was considerably larger in the contact group, making it a risk factor for contact between U1 and the IC. Jia et al.⁸ found that perforation caused by implant insertion into the IC usually occurred in the right central incisor site. That was supported by their anatomical study showing that the IC location tended to be toward the right side at both the incisive foramen level and the apical level.⁸ In the current study, similarly, a significantly smaller right U1-IC distance before and after retraction and more right central incisors intruding into the IC, might indicate that extra concern should be given to right upper central incisor during retraction even without a midline shift.

Though not significant, a tendency toward a greater horizontal retraction of the incisal edge (HRD) and less lingual tipping of the U1 ($\Delta U1/FH$) were seen in the contact group. However, significant differences between root length decrease in U1s between the contact and noncontact groups indicated that U1-IC contact was very likely to contribute to significant root resorption, which was a similar finding to that of Chung et al.¹⁰ and Nakada et al.⁹ It was noted that, in some

cases, lingual tipping of the incisors during retraction caused contact of the root apex with the labial cortical bone. However, the root apex was not necessarily the most susceptible to meeting the IC. Even without a significant root length decrease, palatal cervical root resorption resulting from excessive lingual tipping and lingual movement of the incisal edge of U1 were revealed by CBCT examination, which might have been neglected in 2D examinations.

In the current study, the safety rate of unmonitored retraction by mini-implants was approximately 66.7% (22 in 33). The actual risk might be lower because this study included only patients undergoing retraction with maximum anchorage provided by mini-implants. A larger sample size might be able to provide more detailed information for the relationship between U1-IC contact and root resorption. In conventional cephalometric radiographs, orthodontists cannot evaluate the relationship between the IC and U1. Therefore, it is suggested that CBCT be prescribed during treatment planning to confirm the limit and type of tooth movement to avoid IC-related root resorption in patients who planned to have extensive retraction of the anterior teeth using maximum anchorage.

CONCLUSIONS

- A lower-positioned IC and decreases in the distances between U1 and the IC significantly contribute to the contact between U1 and the cortical plate of the IC.
- Contact between U1 and the IC cause significantly more apical root resorption.
- CBCT might be of greater help than cephalometric radiographs for evaluating the relationship between the IC and U1.

ACKNOWLEDGMENTS

This work is supported by the National Natural Science Foundation of China [grant number 81200806]. The authors declare no conflicts of interest related to this study.

REFERENCES

1. Sebastian B. Mini-implants: new possibilities in interdisciplinary treatment approaches. *Case Rep Dent*. 2014;2014:140760.
2. Sarikaya S, Haydar B, Ciger S, et al. Changes in alveolar bone thickness due to retraction of anterior teeth. *Am J Orthod Dentofacial Orthop*. 2002;122:15–26.
3. Akin M, Baka ZM, Ileri Z, et al. Alveolar bone changes after asymmetric rapid maxillary expansion. *Angle Orthod*. 2015;85:799–805.
4. Al-Amery SM, Nambiar P, Jamaludin M, et al. Cone beam computed tomography assessment of the maxillary incisive canal and foramen: considerations of anatomical variations when placing immediate implants. *PLoS One*. 2015;10:e0117251.
5. Guncu GN, Yildirim YD, Yilmaz HG, et al. Is there a gender difference in anatomic features of incisive canal and maxillary environmental bone? *Clin Oral Implants Res*. 2013;24:1023–1026.
6. Tozum TF, Guncu GN, Yildirim YD, et al. Evaluation of maxillary incisive canal characteristics related to dental implant treatment with computerized tomography: a clinical multicenter study. *J Periodontol*. 2012;83:337–343.
7. Asaumi R, Kawai T, Sato I, et al. Three-dimensional observations of the incisive canal and the surrounding bone using cone-beam computed tomography. *Oral Radiol*. 2010;26:20–28.
8. Jia X, Hu W, Meng H. Relationship of central incisor implant placement to the ridge configuration anterior to the nasopalatine canal in dentate and partially edentulous individuals: a comparative study. *PeerJ*. 2015;3:e1315.
9. Nakada T, Motoyoshi M, Horinuki E, et al. Cone-beam computed tomography evaluation of the association of cortical plate proximity and apical root resorption after orthodontic treatment. *J Oral Sci*. 2016;58:231–236.
10. Chung CJ, Choi YJ, Kim KH. Approximation and contact of the maxillary central incisor roots with the incisive canal after maximum retraction with temporary anchorage devices: report of 2 patients. *Am J Orthod Dentofacial Orthop*. 2015;148:493–502.
11. Cho EA, Kim SJ, Choi YJ, et al. Morphologic evaluation of the incisive canal and its proximity to the maxillary central incisors using computed tomography images. *Angle Orthod*. 2016;86:571–576.
12. Engstrom CM, Loeb GE, Reid JG, et al. Morphometry of the human thigh muscles. A comparison between anatomical sections and computer tomographic and magnetic resonance images. *J Anat*. 1991;176:139–156.
13. Chen G, Chen S, Zhang XY, et al. Stable region for maxillary dental cast superimposition in adults, studied with the aid of stable miniscrews. *Orthod Craniofac Res*. 2011;14:70–79.
14. Houston WJ. The analysis of errors in orthodontic measurements. *Am J Orthod*. 1983;83:382–390.
15. Drake R, Vogl AW, Mitchell AWM. *Gray's Anatomy for Students*. London, UK: Elsevier Health Sciences; 2009.
16. Chatriyanuyoke P, Lu CI, Suzuki Y, et al. Nasopalatine canal position relative to the maxillary central incisors: a cone beam computed tomography assessment. *J Oral Implant*. 2012;38:713–717.
17. Sekerci AE, Buyuk SK, Cantekin K. Cone-beam computed tomographic analysis of the morphological characterization of the nasopalatine canal in a pediatric population. *Surg Radiol Anat*. 2014;36:925–932.
18. Etoz M, Sisman Y. Evaluation of the nasopalatine canal and variations with cone-beam computed tomography. *Surg Radiol Anat*. 2014;36:805–812.
19. Fernandez-Alonso A, Suarez-Quintanilla JA, Muinelo-Lorenzo J, et al. Three-dimensional study of nasopalatine canal morphology: a descriptive retrospective analysis using cone-beam computed tomography. *Surg Radiol Anat*. 2014;36:895–905.
20. Zhou Z, Chen W, Shen M, et al. Cone beam computed tomographic analyses of alveolar bone anatomy at the maxillary anterior region in Chinese adults. *J Biomed Res*. 2014;28:498–505.