

**Mini-implants vs fixed functional appliances for treatment of young adult
Class II female patients
A prospective clinical trial**

Madhur Upadhyay^a; Sumit Yadav^b; K. Nagaraj^c; Flavio Uribe^d; Ravindra Nanda^e

ABSTRACT

Objective: To compare the treatment effects of maxillary anterior teeth retraction with mini-implant anchorage in young adults with Class II division 1 malocclusion undergoing extraction of the maxillary first premolars with similar patients treated by a fixed functional appliance.

Materials and Methods: Thirty-four young adult female patients (mean age 16.5 ± 3.2 years, overjet ≥ 6 mm) with a Class II division 1 malocclusion were divided into two groups: group 1 (G1), in which overjet correction was obtained with a fixed functional appliance (FFA), and group 2 (G2), in which upper first premolars were extracted, followed by space closure with MIs as anchor units. Dentoskeletal and soft tissue changes were analyzed on lateral cephalograms taken before (T1) and after (T2) correction of the overjet.

Results: Both methods were useful in improving the overjet and interincisal relationships. Extrusion and mesial movement of the lower molar, together with lower incisor proclination, were noted in G1. G2 showed distalization and intrusion of the upper molar. The nasio-labial angle became more obtuse in G2, while lower lip protrusion was seen for G1.

Conclusions: The two treatment protocols provided adequate dental compensation for the Class II malocclusion, but did not correct the skeletal discrepancy. There were significant differences in the dental and soft tissue treatment effects between the two treatment protocols. (*Angle Orthod.* 2012;82:294–303.)

KEY WORDS: Class II; Extractions; Mini-implants; Fixed functional appliance

INTRODUCTION

Class II malocclusions are characterized by an incorrect relationship between the maxillary and mandibular arches due to skeletal or dental problems or a combination of both. Mandibular retrusion is its most common characteristic, with 80% of the White population displaying this trait as opposed to only 20% expressing excessive maxillary development.^{1,2} Treatment techniques like upper premolar extractions and distalization focus on the maxillary arch in treating Class II malocclusions, whereas functional appliances are specifically used to reposition the mandible and/or the mandibular arch in an anterior direction in order to correct the same problem. The latter also includes fixed functional appliances (FFAs), which are welcome aids especially when patient compliance is declining. Because their primary effects are on the teeth and the adjoining dentoalveolar structures, they can be used in young adults with minimal growth.^{3,4}

Extraction of either two maxillary premolars or two maxillary and two mandibular premolars also helps in compensating a Class II malocclusion. Extraction of

^a Assistant Professor, Division of Orthodontics, Department of Craniofacial Sciences, University of Connecticut, Health Center, Farmington, Conn.

^b Clinical Instructor, Division of Orthodontics, Department of Craniofacial Sciences, University of Connecticut, Health Center, Farmington, Conn.

^c Reader, Department of Orthodontics, KLE University, Belgaum, India.

^d Associate Professor, Division of Orthodontics, Department of Craniofacial Sciences, University of Connecticut, Health Center, Farmington, Conn.

^e Professor and Head, Division of Orthodontics, Department of Craniofacial Sciences, University of Connecticut, Health Center, Farmington, Conn.

Corresponding author: Dr Madhur Upadhyay, Division of Orthodontics, Department of Craniofacial Sciences, University of Connecticut, Health Center, Farmington, CT 06030 (e-mail: maupadhyay@uchc.edu; madhurup@yahoo.com)

Accepted: July 2011. Submitted: April 2011.

Published Online: August 26, 2011

© 2012 by The EH Angle Education and Research Foundation, Inc.

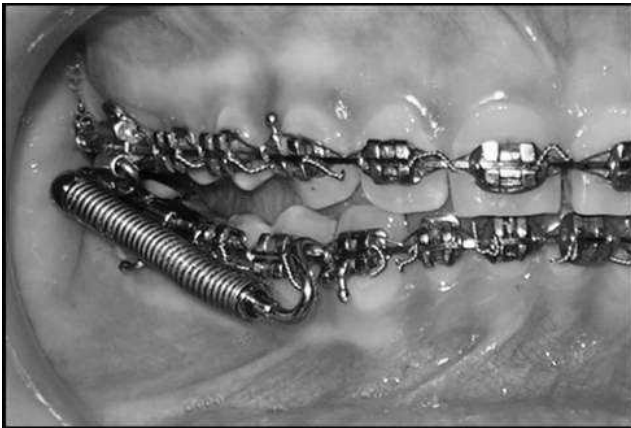

Figure 1. Clinical set up for a G1 patient.

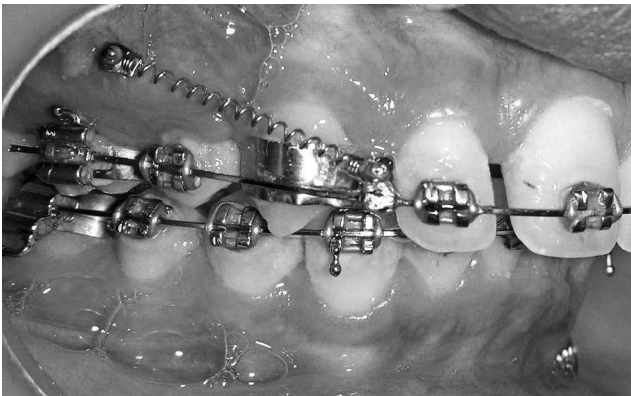


Figure 2. Clinical set up for a G2 patient.

only two maxillary premolars and anterior teeth retraction are generally indicated when there is no crowding or cephalometric discrepancy in the mandibular arch^{5,6} However, retracting anterior teeth in a full-cusp Class II malocclusion can be an arduous task because anchorage control becomes critical.⁷ With the introduction of skeletal anchorage, it has become possible to obtain absolute anchorage and close the extraction spaces completely by anterior tooth retraction.⁷

Considering that the treatment protocols discussed above have the same treatment objectives, ie, compensation of the exaggerated overjet either by retraction of maxillary teeth or proclination/mesial movement of mandibular teeth or by a combination thereof, it would be interesting to compare the treatment differences between these techniques, as they might have a bearing on the overall treatment plan

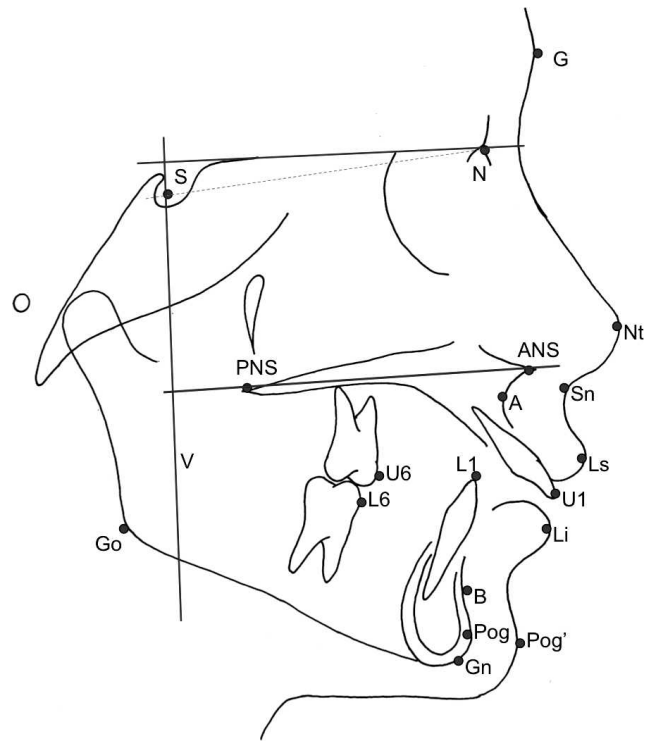


Figure 3. Cephalometric landmarks (select): Go indicates a point on the curvature of the angle of the mandible located by bisecting the angle formed by lines tangent to the posterior ramus and the inferior border of the mandible; Nt, most anterior point on the sagittal contour of the nose; U6, mesial cusp tip of maxillary first molar; L6, mesial cusp tip of mandibular first molar; U1, incisal tip of the maxillary central incisor; L1, incisal tip of the mandibular central incisor.

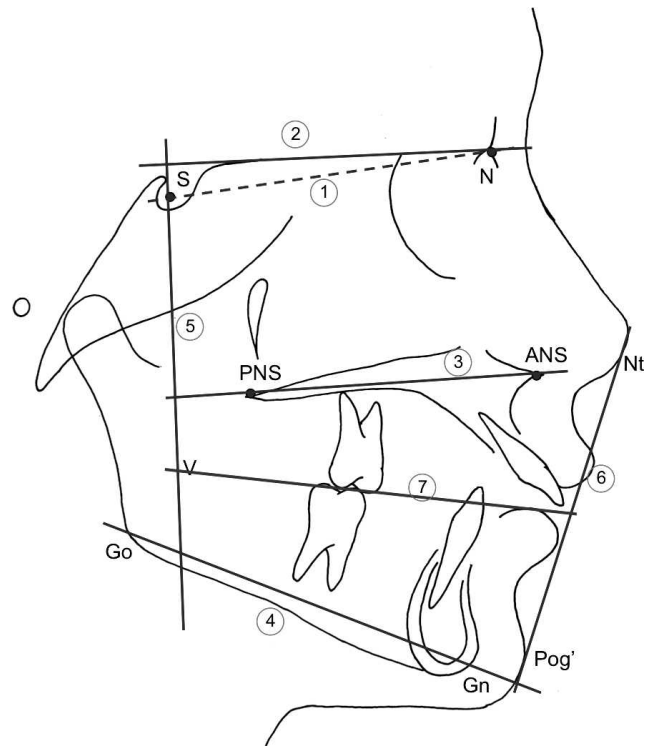


Figure 4. Cephalometric planes. 1: S-N plane; 2: Sella horizontal (Sh or Constructed FH plane or x axis); 3: palatal plane (ANS-PNS); 4: mandibular plane (Go-Gn); 5: Sella vertical (Sv or y axis); 6: Rickett's esthetic plane (Nt-Pog'); 7: occlusal plane (OP).

Table 1. Details of the Study Sample (n = 32)^a

Measurement	G1 (n=18)		G2 (n=14)		P Value	Sign
	Mean	SD	Mean	SD		
Age at T1, y	16.51	3.51	17.38	2.85	.64	NS
Intervention (T2-T1), mo	5.2	1.3	9.94	2.44	.00	*
Total treatment time, mo	21.6	6.7	25.4	5.5	.00	*

^a G1 indicates group 1; G2, group 2; T1, FFA insertion; T2, FFA removal; SD, standard deviation; NS, not significant; * P < .05.

for Class II patients. The purpose of this prospective study was to examine the dentoskeletal and soft tissue treatment effects of maxillary anterior tooth retraction with mini-implant anchorage in Class II division I patients undergoing extraction of only the maxillary first premolars in comparison to similar patients undergoing treatment with a nonextraction approach using an FFA.

MATERIALS AND METHODS

The study was carried out at two different centers. Formal approval was obtained from the ethical committee at KLE University’s Institute of Dental Sciences,

Belgaum, India, and from the Institutional Review Board at the University of Connecticut Health Center. The first 88 consecutive female subjects with a Class II dental malocclusion in the permanent dentition were screened for this study over a period of 14 months. Only 34 patients met the following inclusion criteria:

- Cervical vertebrae maturation stage IV or higher.⁸
- Class II molar relation with no subdivision malocclusion.
- Overjet ≥ 6 mm.
- Permanent dentition with all the teeth present, except third molars.
- Minimal crowding of the dental arches (≤3 mm).

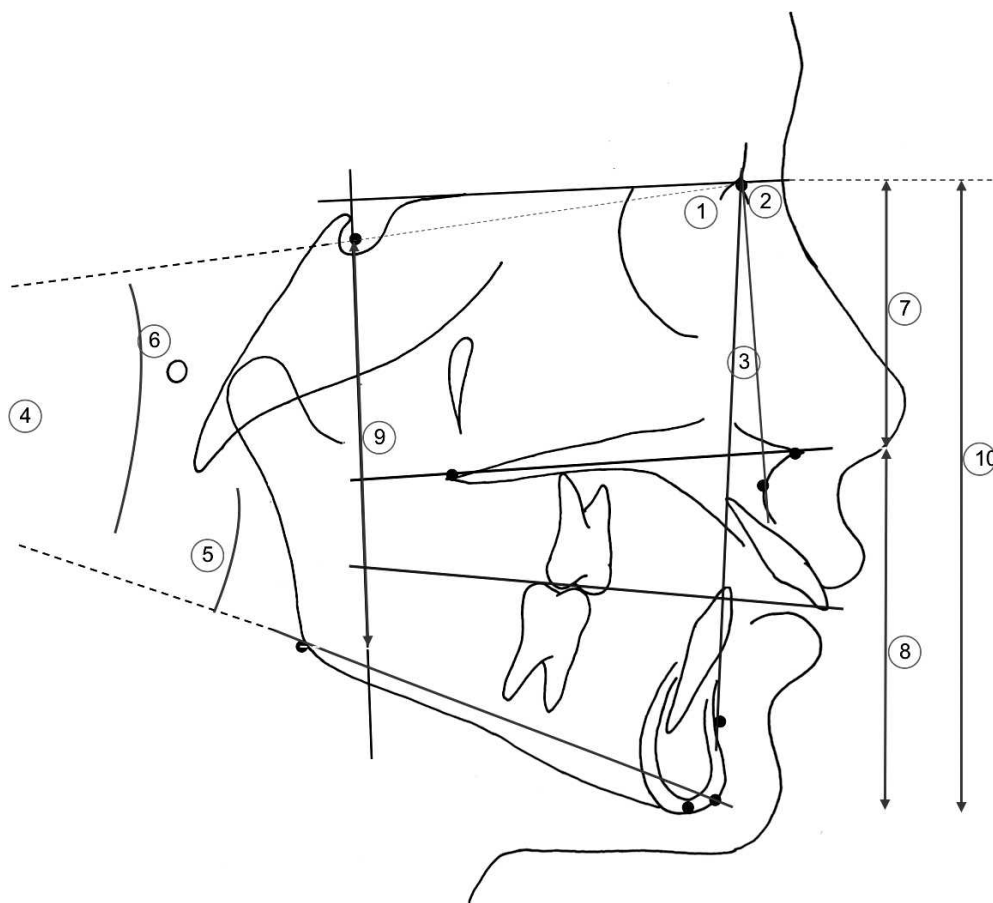


Figure 5. Skeletal parameters. (A) Angular measurements (°): 1, SNA; 2, SNB; 3, ANB; 4, Go-Gn-SN; 5, PP-MP; 6, OP-SN. (B) Linear measurements (in mm): 7, UFH; 8, LFH; 9, PFH; 10, AFH.

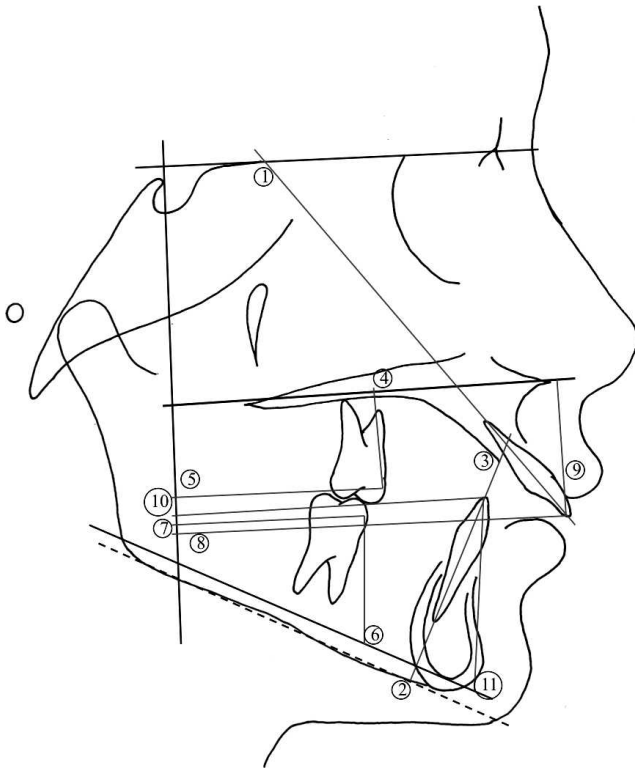


Figure 6. Dental parameters. (A) Angular measurements (°): 1, U1-SN; 2, IMPA; 3, U1-L1. (B) Linear measurements (in mm): 4, U6-PP; 5, U6-Sv; 6, L6-MP; 7, L6-Sv; 8, U1-Sv; 9, U1-PP; 10, L1-Sv; 11, L1-MP.

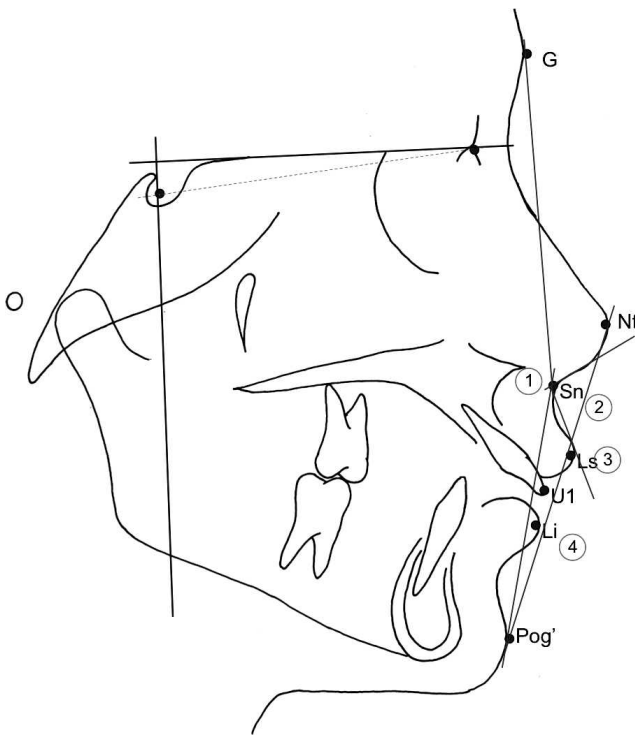


Figure 7. Soft-tissue parameters. (A) Angular measurements (°): 1, G-Sn-Pg; 2, Nasolabial angle. (B) Linear measurements (in mm): 3, E line-Ls; 4, E line-Li.

All patients and/or their parents were advised of the purpose of this study, and the patient and/or one parent or guardian signed a consent form. Two patients did not agree to participate and were, therefore, not included. The patients were divided into two groups based on the treatment protocol for Class II correction. Group I (G1) subjects were treated using a nonextraction method, ie, with a FFA (mean age 16.51 ± 3.51 years). In group II (G2) patients, upper first premolars were extracted, and mini-implants were used for anchorage (mean age 17.38 ± 2.85 years; Table 1). Except for the method of Class II correction employed, the treatment for both the groups was similar, consisting of full, fixed orthodontic appliances (Roth prescription, slot size 0.022×0.028 inches). By limiting the sample to three experienced clinicians performing either of the treatment procedures, variation in treatment technique was minimized. Patients were randomly assigned to the three operators who followed a well-designed treatment protocol.

Table 2. Comparison of the Morphologic Characteristics of the Patients in Both the Groups (in mm)^a

	G1 (n = 18)		G2 (n = 14)		P Value	Sig
	Mean	SD	Mean	SD		
Skeletal parameters						
SNA, °	80.46	3.26	82.86	3.09	.22	NS
SNB, °	74.96	3.72	76.55	3.53	.68	NS
ANB, °	5.5	1.99	6.32	1.65	.21	NS
Go-Gn-SN, °	27.38	5.47	29.91	6.26	.1	NS
PP-MP, °	26.38	5.55	26.77	6.25	.41	NS
UFH (N-ANS)	52.12	3.66	51.41	2.62	1.00	NS
LFH (ANS-Me)	62.92	3.9	65.09	4.91	.68	NS
UFH/LFH, %	82.96	6.97	79.37	6.19	1.00	NS
PFH (S-Go)	77.73	6.71	76.95	7.1	1.00	NS
AFH (N-Me)	114.58	5.69	116.32	6.25	.41	NS
PFH/AFH, %	67.73	5.55	66.16	4.84	1.00	NS
Dental parameters						
U1-SN, °	110.58	7.33	108.55	6.83	1.00	NS
IMPA, °	99.15	8.32	97.91	4.95	1.00	NS
U1-L1, °	116.62	7.81	119.59	.68	NS	
U6-PP	21.58	2.05	21.91	2.12	1.00	NS
U6-Sv	44.62	5.48	46.82	6.54	.12	NS
L6-MP	33.92	2.86	27.45	2.62	.00	*
L6-Sv	41.69	5.88	47.82	7.61	.10	NS
U1-Sv	74.81	6.9	76.91	8.35	1.00	NS
U1-PP	28.27	3.21	30.45	2.07	.21	NS
L1-Sv	65.96	6.7	68.5	10.55	.22	NS
OP-SN, °	19.42	5.5	19.35	4.9	.88	NS
Overjet	7.79	1.76	7.44	1.12	1.00	NS
Soft tissue parameters						
G-Sn-Pg, °	18.62	3.4	19.64	4.86	.41	NS
Nasolabial angle, °	93.85	11.89	92.18	17.33	.44	NS
E line-Ls	-0.73	2.39	0.55	1.72	.22	NS
E line-Li	-0.31	3.54	2.55	4.24	.22	NS

^a G1 indicates group 1; G2, group 2; SD, standard deviation; NS, not significant; * $P < .05$.

Table 3. Comparison of the Treatment Changes (T2–T1) Between G1 and G2 (in mm)^a

	G1 (n = 18)		G2 (n = 14)		P Value	Sig
	Mean	SD	Mean	SD		
Skeletal parameters						
SNA, °	-0.58	1.3	-0.18	1.23	.36	NS
SNB, °	0.96	1.55	0.45	1.19	.68	NS
ANB, °	-1.54	1.05	-0.64	0.98	.18	NS
Go-Gn-SN, °	-0.31	1.09	-0.5	1.26	.41	NS
PP-MP, °	-0.81	1.75	-0.41	1.26	.68	NS
UFH (N-ANS)	0.46	1.16	-0.14	0.84	.11	NS
LFH (ANS-Me)	0.96	2.46	0.36	0.95	1.00	NS
UFH/LFH, %	0.03	2.58	-4.41	5.73	.41	NS
PFH (S-Go)	1.96	2.6	1.59	0.94	1.00	NS
AFH (N-Me)	1.5	2.61	0.18	1.17	.12	NS
PFH/AFH, %	0.84	1.71	1.23	0.92	.41	NS
Dental parameters						
U1-SN, °	-7.31	5.07	-12.41	5.76	.01	*
IMPA, °	10.69	5.36	-4.82	5.36	.00	*
U1-L1, °	-2.35	6.97	16.59	6.67	.00	*
U6-PP	-1.08	1.08	-0.64	0.78	1.00	NS
U6-Sv	-0.62	1.73	-0.45	0.79	1.00	NS
L6-MP	1.15	0.72	0.82	0.75	.39	NS
L6-Sv	3.42	2.62	0.64	1.1	.00	*
U1-Sv	-3.12	1.93	-5.18	2.74	.12	NS
U1-PP	1.5	0.98	-1.32	1.08	.00	*
L1-Sv	3.96	1.97	-1.77	2.16	.00	*
OP-SN, °	0.68	3.2	0.48	2.23	.35	NS
Soft tissue parameters						
G-Sn-Pg, °	-0.77	2.26	-2.18	1.33	.12	NS
Nasolabial angle, °	8.19	8.06	11.55	6.4	.01	*
E line-Ls	-1.19	1.3	-2.41	1.22	.07	NS
E line-Li	1.85	1.39	-2.73	2.4	.00	*

^a T2 indicates FFA removal; T1, FFA insertion; G1, group 1; G2, group 2; SD, standard deviation; NS, not significant; * $P < .05$.

Clinical Setup

FFA group. This group (Figure 1) had 18 patients. Leveling and aligning were done with nickel-titanium and stainless steel (SS) archwires. The FFA used for all the patients was the Forsus Fatigue-Resistant Device (3M Unitek, Monrovia, CA). It was placed only when the 0.021×0.025 -inch archwires had been in place for at least 2 weeks. The mandibular arch was tied back to the first or second molars. The appliance was used until complete correction of the overjet was obtained.

Extraction group. This group (Figure 2) had 14 patients. Once the initial leveling and aligning were over, 0.017×0.025 -inch SS arch wire, with crimpable hooks placed distal to the lateral incisors, was inserted into the upper arch. Titanium mini-implants (1.3 mm in diameter and 8 mm in length) were inserted between the roots of the first molar and second premolar in the maxillary arch. The implants were checked for mobility (primary stability) and were immediately loaded with precalibrated nickel-titanium

Table 4. Comparison of the Treatment Changes (T2–T1) (in mm) for the Patients in the Nonextraction Group (G1)^a

	T1		T2		P Value	Sig
	Mean	SD	Mean	SD		
Skeletal parameters						
SNA, °	80.46	3.26	79.88	2.85	.12	NS
SNB, °	74.96	3.72	75.92	3.1	.05	*
ANB, °	5.5	1.99	3.96	1.86	.00	*
Go-Gn-SN, °	27.38	5.47	27.08	5.45	.36	NS
PP-MP, °	26.38	5.55	25.58	5.35	.13	NS
UFH (N-ANS)	52.12	3.66	52.58	3.14	.14	NS
LFH (ANS-Me)	62.92	3.9	63.88	5.1	.39	NS
UFH/LFH, %	82.96	6.97	83	5.94	.94	NS
PFH (S-Go)	77.73	6.71	79.69	6.46	.03	*
AFH (N-Me)	114.58	5.69	116.08	7.34	.09	NS
PFH/AFH, %	67.73	5.55	68.58	5.09	.12	NS
Dental parameters						
U1-SN, °	110.58	7.33	103.27	7.65	.00	*
IMPA, °	99.15	8.32	109.85	11.13	.00	*
U1-L1, °	116.62	7.81	114.27	6.6	.25	NS
U6-PP	21.58	2.05	20.5	1.84	.01	*
U6-Sv	44.62	5.48	44	5.96	.26	NS
L6-MP	33.92	2.86	35.08	2.85	.00	*
L6-Sv	41.69	5.88	45.12	6.19	.01	*
U1-Sv	74.81	6.9	71.69	6.39	.00	*
U1-PP	28.27	3.21	29.77	3.08	.00	*
L1-Sv	65.96	6.7	69.92	6.48	.00	*
OP-SN, °	19.42	5.5	20.05	4.8	.36	NS
Soft tissue parameters						
G-Sn-Pg, °	18.62	3.4	17.85	3.11	.25	NS
Nasolabial angle, °	93.85	11.89	100.04	10.35	.01	*
E line-Ls	-0.73	2.39	-1.92	3.05	.01	*
E line-Li	-0.31	3.54	1.54	3.21	.00	*

^a T2 indicates FFA removal; T1, FFA insertion; G1, group 1; SD, standard deviation; NS, not significant; * $P < .05$.

closed coil springs (150 g; GAC International Inc, Bohemia, NY) extending from the implant head to the crimpable hooks for en masse retraction of the upper anterior teeth. Conventional mechanics were used for the lower arch.

Cephalometric Records

Lateral cephalograms for each patient were taken at two different time points: insertion of the FFA/initiation of en masse retraction (T1) and removal of the FFA/completion of en masse retraction (T2).

All lateral cephalometric radiographs for each subject were taken with the same Planmeca cephalometer (PM 2002 EC Proline; Planmeca, Helsinki, Finland), ensuring minimal errors due to magnification. For measuring cephalometric values, a coordinate system was constructed. A Frankfort horizontal plane was constructed on the cephalograms by subtracting 7° from the sella-nasion line. This served as the x-axis, a perpendicular through sella as the y-axis. Linear and

Table 5. Comparison of the Treatment Changes (T2–T1) (in mm) for the Patients in the Extraction Group (G2)^a

	T1		T2		P Value	Sig
	Mean	SD	Mean	SD		
Skeletal parameters						
SNA, °	82.86	3.09	82.68	3.36	.57	NS
SNB, °	76.55	3.53	77	3.38	.16	NS
ANB, °	6.32	1.65	5.68	1.91	.04	*
Go-Gn-SN, °	29.91	6.26	29.41	5.87	.21	NS
PP-MP, °	26.77	6.25	26.36	5.97	.35	NS
UFH (N-ANS)	51.41	2.62	51.27	2.11	.74	NS
LFH (ANS-Me)	65.09	4.91	69.45	4.92	.17	NS
UFH/LFH, %	79.37	6.19	74.96	7.81	.02	*
PFH (S-Go)	76.95	7.1	78.55	7.05	.00	*
AFH (N- Me)	116.32	6.25	116.5	6.13	.76	NS
PFH/AFH, %	66.16	4.84	67.39	4.51	.00	*
Dental parameters						
U1-SN, °	108.55	6.83	96.14	5.07	.00	*
IMPA, °	97.91	4.95	93.09	6.63	.00	*
U1-L1, °	119.59	7.22	136.18	5.6	.00	*
U6-PP	21.91	2.12	21.27	1.78	.04	*
U6-Sv	49.82	6.54	49.36	6.25	.10	NS
L6-MP	27.45	2.62	28.27	2.45	.01	*
L6-Sv	47.82	7.61	48.45	7.51	.07	NS
U1-Sv	76.91	8.35	71.73	6.97	.00	*
U1-PP	30.45	2.07	29.14	2.18	.01	*
L1-Sv	68.5	10.55	66.73	10.12	.02	*
OP-SN, °	19.35	4.9	19.83	3.8	.18	NS
Soft tissue parameters						
G-Sn-Pg, °	19.64	4.86	17.45	4.41	.00	*
Nasolabial angle, °	92.18	17.33	103.73	14.42	.00	*
E line-Ls	0.55	1.72	-1.86	1.32	.00	*
E line-Li	2.55	4.24	-0.18	2.72	.01	*

^a T2 indicates FFA removal; T1, FFA insertion; G2, group 2; SD, standard deviation; NS, not significant; * $P < .05$.

angular measurements were performed to the nearest 0.5 mm and 0.5°, respectively (Figures 3–7). An intention-to-treat analysis was carried out so that the data from all patients, regardless of treatment outcome, were included.

Statistical Methods

For a clinical trial with a power of 85% and an alpha level of .05, a sample size of 30 patients was considered suitable. The data were analyzed using a commercially available statistical software package (SPSS Inc, Chicago, Ill). Kolmogorov-Smirnov tests and Q-Q plots were used to assess the normality of the data. Comparisons between the groups were undertaken using a two-tailed Mann-Whitney *U*-test. Pairwise comparison between related assessments made at the two time intervals were performed using a two-tailed Wilcoxon signed rank test. A confidence level less than 5% was considered statistically significant ($P < .05$). Systematic errors were estimated by paired *t*-tests, and causal errors were calculated using Dahlberg's formula, $Se^2 = \Sigma d^2/2n$, where *d* is the difference between duplicate measurements,

and *n* is the number of double measurements. The investigator who retraced all the cephalograms was blinded. The method errors were found to vary between 0.47 (Pog-Sv) and 0.92 (U6-Sv) and were within acceptable limits.

RESULTS

The treatment changes for each measurement were calculated by subtracting the measurements taken at T1 from T2. Linear measurements that show a negative (–) sign are synonymous with a distal, backward, or intrusive movement to a relevant reference line, while a positive value indicates a forward, mesial, or extrusive movement. A positive value for a change in an angular measurement indicates that the measurement became more obtuse during treatment.

Patient ages and pretreatment differences among the variables for the groups are shown in Tables 1 and 2. Both methods were useful in correcting the overjet and improving the interincisal relationships. Correction of the overjet in G1 was achieved by retraction of the upper incisors and lower incisor

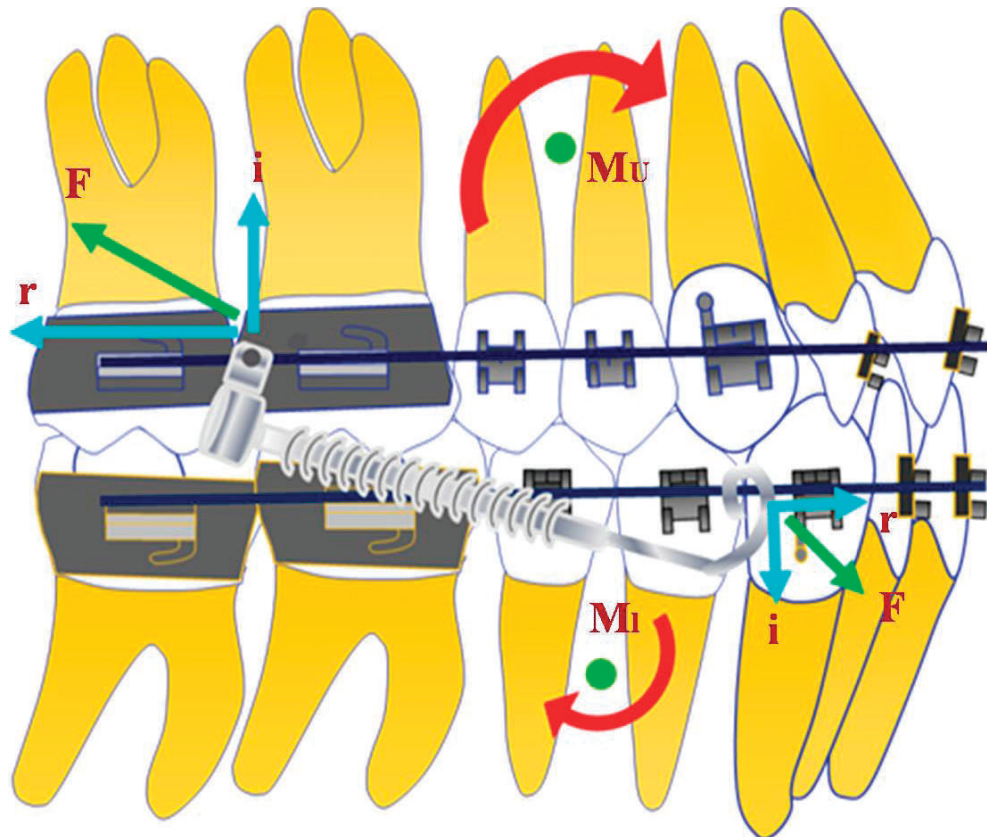


Figure 8. Force system involved in G1 patients. Here, F = Total force, i = vertical (intrusive) component, r = horizontal component, M_u = Moment created on the upper arch, M_l = moment created on the lower arch.

flaring, whereas in G2 the overjet was corrected by complete retraction of maxillary anterior teeth only. Additionally, the maxillary molars showed slight intrusion in both the groups (Table 3–5). The total treatment time was significantly less for G1 ($P < .05$).

DISCUSSION

The investigated cases were selected primarily on the basis of presenting a bilateral Class II malocclusion independent of the associated cephalometric characteristics. In spite of the strict inclusion and exclusion criteria consistent with other studies,^{9,10} large individual variations were found in the hard and soft tissue measurements within each group (Table 2).

The force exerted by the functional appliance on the upper molars was distal to the center of resistance of the upper arch; hence, in addition to the intrusive and distal force, there was a moment that tipped the molar back (Figure 8). This might be beneficial in counteracting a tendency for posterior rotation of the mandible.^{11–13} Another factor, which can indirectly reduce the risk of posterior rotation, is intrusion of the incisors during the leveling and aligning phase.

This adjustment of the curve of Spee makes it possible to jump the mandible forward to an edge-to-edge incisor relationship, with a small or negligible concomitant rotation of the mandible and opening of the bite in the lateral segments. Distal movement of the maxillary molars has also been previously reported with similar appliances.^{14–16} However, studies showing the greatest distal movements of the maxillary molars measured the effects immediately after appliance removal.^{14,17,18} Mesial movement with growth and anchorage loss might occur during finishing and detailing, but strictly speaking do not qualify as treatment effects of the FFA.

In G2, the retraction force on the upper arch was directed upward and backward, producing a small intrusive and a larger distal force on the anterior segment (Figure 9A). During space closure, the intrusive force (i) increased because of an increase in the angulation of the applied forces to the occlusal plane. This increase in the vertical component of the total force can cause binding of the archwire with the brackets or tubes, thereby preventing sliding and transmitting the force to the entire archwire. This might have produced the distal and intrusive force on the posterior teeth (Figure 9B).^{7,19,20} Consequently, some

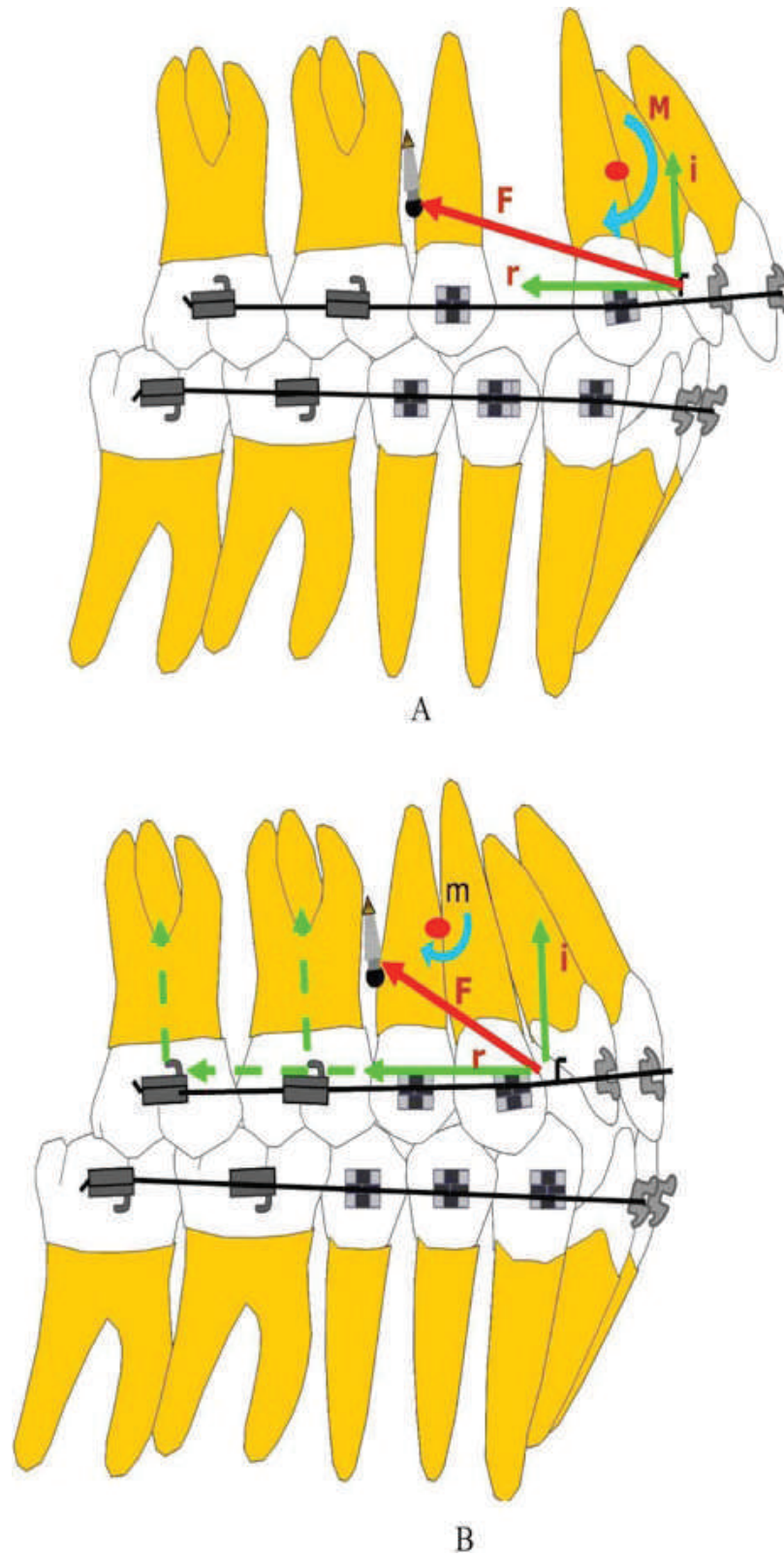


Figure 9. Force system involved in G2 patients. (A) Force system before space closure (F = total force, i = vertical (intrusive) component, r = horizontal component, M = moment around the center of resistance of the maxillary anterior teeth). (B) Force system after space closure (m = total moment around the center of resistance of the maxillary arch).

cases in this group required the application of Class III elastics during the finishing stages so that a full-cusp Class II molar relationship could be obtained. Contrary to the intrusive movement of the upper molars, mandibular molars were extruded in both the groups (Tables 4 and 5). However, no increase in the mandibular plane angle was noted. This can be explained by two factors. Firstly, the extrusion of the lower molars compensated for the intrusion of their counterparts in the upper arch. Secondly, and more importantly for G1, besides the extrusive movement, the lower molars showed a significant mesial drift, suggesting that the mesial movement might have cancelled the opening rotation of the mandible.^{21,22} Nonetheless, the PFH/AFH (posterior facial height and anterior facial height) ratio increased for both groups. Previously it has been shown that in successfully treated Class II patients there is a significant increase in the PFH/AFH ratio due to a greater increase in PFH than in AFH.²³

Analysis of the soft tissue changes showed a decrease in lower lip projection for G2, whereas an increase was noted for G1 (Tables 3–5). With a deep overbite, excessive overjet, and a Class II dental relationship, the lower lip may be artificially held in a forward position trapped in the space between the upper and lower incisors. As the bite opens and the maxillary incisors are retracted, the lip returns to its normal position, resulting in a decreased lower lip projection. In comparison G1 showed flaring of the lower incisors during treatment, causing an increased lower lip protrusion. The lower incisor flaring was a matter of concern as this could lead to gingival recession in the long term²⁴; however, soft tissue contacts were not evaluated in this study. The nasolabial angle also increased significantly for both the groups, with G2 showing a greater increase than G1 ($P < .05$). This was most likely because of the strict retraction requirements for G2, which translated into larger mean maxillary incisor retraction. A greater retraction of the incisors gives more opportunity for the soft tissue between subnasale and labrale superius to move posteriorly. Consequently, the upper lip showed more retraction for G2. However despite the extensive retraction, mean scores for the upper and lower lips were well within the ideal. This perhaps shows that lip response as a proportion of incisor retraction decreases as the amount of incisor retraction increases, indicating that lips have some inherent support.²⁵

The overall treatment as well as the time spent on overjet reduction was significantly less for G1 (Table 1). This can be explained by two factors. Firstly, overjet reduction in G1 was obtained by simultaneous retraction and flaring of the upper and lower incisors, respectively, whereas in G2 the same

was obtained by upper incisor retraction only. Secondly, fewer side effects were noted in G1 during overjet reduction as compared to G2, consequently less time was spent in finishing. However, this phase of treatment was not evaluated in this study. Also, our results do not apply to other age ranges, ie, patients showing active growth. These are some areas that need further investigation.

CONCLUSIONS

- The two treatment protocols provided adequate dental compensation for the Class II malocclusion, but did not affect the skeletal discrepancy.
- There were significant differences in the dental and soft tissue treatment effects between the groups. In particular, the lower incisors showed significant flaring in the FFA group.
- The treatment time was significantly less with FFAs.

REFERENCES

1. McNamara JA. Components of Class II malocclusion in children 8–10 years of age. *Angle Orthod.* 1981;51:177–202.
2. Proffit WR. *Contemporary Orthodontics*. 2nd ed. St Louis, Mo: CV Mosby; 1996:2–16.
3. Bock NC, von Bremen J, Ruf S. Occlusal stability of adult Class II division 1 treatment with the Herbst appliance. *Am J Orthod Dentofacial Orthop.* 2010;138:146–151.
4. Siara-Oldsa NJ, Pangrazio-Kulbershb, Bergerc VJ, Bayirli B. Long-term dentoskeletal changes with the Bionator, Herbst, Twin Block, and MARA functional appliances. *Angle Orthod.* 2010;80:18–29.
5. Bishara SE, Cummins DM, Jakobsen JR, Zaher AR. Dentofacial and soft tissue changes in Class II div 1 cases treated with and without extractions. *Am J Orthod Dentofacial Orthop.* 1995;107:28–37.
6. Rock WP. Treatment of Class II malocclusions with removable appliances. Part 4. Class II div 2 treatment. *Br Dent J.* 1990;168:298–302.
7. Upadhyay M, Yadav S, Nagaraj K, Patil S. Treatment effects of mini-implants for en-masse retraction of anterior teeth in bialveolar dental protrusion patients: a randomized controlled trial. *Am J Orthod Dentofacial Orthop.* 2008;134:18–29.
8. Baccetti T, Franchi L, McNamara JA Jr. An improved version of cervical vertebral maturation (CVM) method for the assessment of mandibular growth. *Angle Orthod.* 2002;72:316–323.
9. Finnoy JP, Wisth PJ, Boe OE. Changes in soft tissue profile during and after orthodontic treatment. *Eur J Orthod.* 1987;9:68–78.
10. Drobocky OB, Smith RJ. Changes in facial profile during orthodontic treatment with extraction of four first premolars. *Am J Orthod Dentofacial Orthop.* 1989;95:220–230.
11. Schaefer AT, McNamara JA Jr, Franchi L, Baccetti T. A cephalometric comparison of treatment with the Twin-block and stainless steel crown Herbst appliances followed by fixed appliance therapy. *Am J Orthod Dentofacial Orthop.* 2004;126:7–15.

12. Du X, Hägg U, Rabie ABM. Effects of headgear Herbst and mandibular step-by-step advancement versus conventional Herbst appliance and maximal jumping of the mandible. *Eur J Orthod*. 2002;24:167–174.
13. Wong GWK, So LLY, Hägg U. A comparative study of sagittal correction with the Herbst appliance in two different ethnic groups. *Eur J Orthod*. 1997;19:195–204.
14. Cope JB, Buschang PH, Cope DD, Parker J, Blackwood HO. Quantitative evaluation of craniofacial changes with Jasper Jumper therapy. *Angle Orthod*. 1994;64:113–122.
15. Pangarzio-Kulberesh V, Berger JL, Chermak DS, Kaczynski R, Simon ES, Haerian A. Treatment effects of the mandibular anterior repositioning appliance on patients with Class II malocclusion. *Am J Orthod Dentofacial Orthop*. 2003;123:286–295.
16. Weiland FJ, Bantleon HP. Treatment of Class II malocclusions with the Jasper Jumper appliance—a preliminary report. *Am J Orthod Dentofacial Orthop*. 1995;108:341–350.
17. Jasper JJ, McNamara JA Jr. The correction of interarch malocclusions using a fixed force module. *Am J Orthod Dentofacial Orthop*. 1995;108:641–650.
18. Stucki N, Ingervall B. The use of the Jasper Jumper for the correction of Class II malocclusion in the young permanent dentition. *Eur J Orthod*. 1998;20:271–281.
19. Yao CC, Lai EH, Chang JZ, Chen I, Chen YJ. Comparison of treatment outcomes between skeletal anchorage and extraoral anchorage in adults with maxillary dentoalveolar protrusion. *Am J Orthod Dentofacial Orthop*. 2008;134:615–624.
20. Upadhyay M, Yadav S, Nanda R. Vertical-dimension control during en-masse retraction with mini-implant anchorage. *Am J Orthod Dentofacial Orthop*. 2010;138:96–108.
21. Staggers JA. A comparison of results of second molar and first premolar extraction treatment. *Am J Orthod Dentofacial Orthop*. 1990;98:430–436.
22. Cusimano C, McLaughlin RP, Zernik JH. Effects of first bicuspid extractions on facial height in high-angle cases. *J Clin Orthod*. 1993;27:594–598.
23. Vaden JL, Harris EF, Sinclair PM. Clinical ramifications of posterior and anterior facial height changes between treated and untreated Class II samples. *Am J Orthod Dentofacial Orthop*. 1994;105:438–443.
24. Alstad S, Zachrisson B. Longitudinal study of periodontal condition associated with orthodontic treatment in adolescents. *Am J Orthod*. 1979;76:277–285.
25. Wisth PJ. Soft tissue response to upper incisor retraction in boys. *Br J Orthod*. 1974;1:199–204.