

## Changes in CT cerebral blood flow and volume associated with rapid maxillary expansion in a rabbit model

Qingyi Li<sup>a</sup>; Wei Wang<sup>b</sup>; Qingbo Zhang<sup>c</sup>; Lin Wang<sup>d</sup>

### ABSTRACT

**Objective:** To evaluate hemodynamic changes of the brain under the high forces of a rapid maxillary expansion (RME) appliance in a rabbit model.

**Materials and Methods:** Twenty-four male New Zealand white rabbits were selected (12 weeks old, mean weight  $3.01 \pm 0.22$  kg). A modified acrylic resin bonded RME appliance was used for expansion. A series of perfusion computed tomography examinations was performed before expansion (T0), on the fifth day of expansion (T1), at the end of the expansion process (T2), and after 10 days of retention (T3). Cerebral blood flow, cerebral blood volume, and mean transit time maps were recorded and parameters evaluated. Statistical analyses were performed with analysis of variance with post hoc tests.

**Results:** Mean cerebral blood flow showed an increase from T0 to T2 and then a decrease from T2 to T3, but the change was not statistically significant. Mean cerebral blood volume and mean transit time increased significantly from T0 to T2, and all perfusion parameters increased from T0 to T3.

**Conclusions:** RME is a safe orthopedic method despite the high expansion force. Perfusion computed tomography is effective for evaluating the hemodynamic changes of the brain caused by some orthopedic therapies. The increase in both cerebral blood volume and cerebral blood flow may help to explain why RME could alleviate the symptoms of enuretic children. (*Angle Orthod.* 2012;82:418–423.)

**KEY WORDS:** Rapid maxillary expansion; Perfusion computed tomography; Cerebral blood flow; Nocturnal enuresis

### INTRODUCTION

Dynamic perfusion computed tomography (p-CT) has recently gained widespread application in the study of brain hemodynamics. With its ability to provide quantitative measurements of cerebral blood flow

(CBF) and cerebral blood volume (CBV), p-CT has been proven to be an efficient and reliable imaging tool in the assessment of cerebral perfusion.<sup>1</sup> Most clinical applications of p-CT are in the diagnosis and treatment of acute ischemic stroke, chronic ischemic cerebral disease, brain tumors, etc.<sup>2–4</sup>

Rapid maxillary expansion (RME), invented in 1860 by Angell,<sup>5</sup> is used for the orthopedic treatment of transverse maxillary deficiency. RME exerts high forces that can easily split the midpalatal suture in young patients, forcing the maxillary halves apart.<sup>6</sup> Because the maxilla is connected to neighboring bones by sutures, RME therapy appears to involve an ample portion of the craniofacial complex. With the help of multislice computed tomography, Leonard<sup>7</sup> found that early treatment with RME produced a significant bony displacement by opening the circummaxillary suture. Opening of the sphenoid-occipital synchondrosis was found in both animal models and in growing patients.<sup>8–10</sup> Several finite element analyses of the effect of RME found signs of high stress around the circummaxillary sutures.<sup>11–16</sup>

According to Holberg,<sup>13</sup> the superior orbital fissure, the lacerated foramen, and the carotid sulcus are particularly affected by RME. Close to these sutures are some important and vulnerable vascular structures

<sup>a</sup> Associate Chief Physician, Institute of Stomatology, Nanjing Medical University, Department of Orthodontics, Affiliated Hospital of Stomatology, Nanjing, PR China.

<sup>b</sup> Undergraduate Student, Institute of Stomatology, Nanjing Medical University, Department of Orthodontics, Affiliated Hospital of Stomatology, Nanjing, PR China.

<sup>c</sup> Associate Chief Physician, Department of Radiology, The First Affiliated Hospital of Nanjing Medical University, Nanjing, PR China.

<sup>d</sup> Professor and Dean, Department of Orthodontics, School of Stomatology, Nanjing Medical University, Nanjing, PR China.

Corresponding author: Dr Lin Wang, Professor and Dean, Institute of Stomatology, Nanjing Medical University, Department of Orthodontics, Affiliated Hospital of Stomatology, Nanjing Medical University, 136 Hanzhong Road, Nanjing (210029), China  
(e-mail: nydwkltz@gmail.com)

Accepted: July 2011. Submitted: May 2011.

Published Online: September 7, 2011

© 2012 by The EH Angle Education and Research Foundation, Inc.

that play essential roles in the blood supplying the brain. There are several publications reporting on vascular complications in adults after RME. One concern is whether the high stress distribution in the cranial base (foramina) caused by RME will influence brain hemodynamics. With the introduction of p-CT to evaluate RME, this speculation can be verified.

The aim of this study was to evaluate both treatment and posttreatment changes produced by RME in brain hemodynamics on a rabbit model.

## MATERIALS AND METHODS

### RME Model

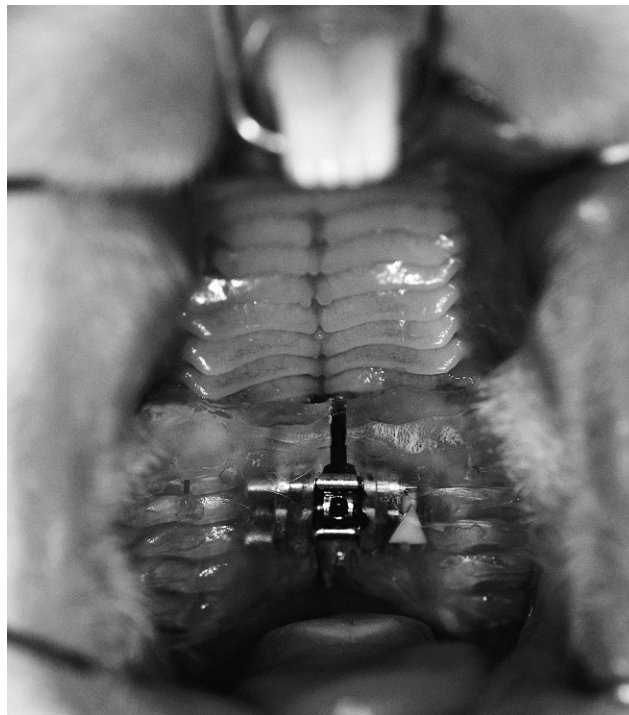
Twenty-four male New Zealand white rabbits (12 weeks old; 2.8–3.2 kg each, mean weight,  $3.01 \pm 0.22$  kg) were bred at Nanjing Medical University Animal Center. The rabbits were all fed with commercial pellet food and water ad libitum, and they were housed in cages under standardized laboratory conditions of a regular light and dark schedule and relative humidity. The rabbits were randomized into two groups: an experimental group (12 rabbits with RME treatment) and a control group (12 rabbits, no treatment). Approval for the study was obtained from the Animal Ethics Committee of Nanjing Medical University.

The acrylic resin bonded appliance used in this study has been described by Memikoğlu and Iseri<sup>19</sup> as a device in which a Hyrax-type screw (Dentaurum, ref 600-300, Ispringen, Germany) was embedded in acrylic resin between the first premolars as close as possible to the palate, with the resin covering the occlusal and labial surfaces of the teeth (Figure 1). The resin was trimmed thin enough to preserve the interocclusal space while allowing maximum occlusal contact bilaterally. The activation protocol included two turns per day and lasted for 10 days. Then the acrylic splint remained in situ for retention for another 10 days. In the control group the screw was not embedded in acrylic.

### P-CT Imaging Procedures

P-CT examination was performed on a 16-slice CT scanner (SOMATOM Sensation 64, Siemens, Munich, Germany). Baseline p-CT imaging was performed immediately after the RME appliance was bonded. In all, four serial p-CT scans were performed on each rabbit: on day 0 (T<sub>0</sub>, which was selected as baseline), on day 5 of the activation period (T<sub>1</sub>), on day 10 (T<sub>2</sub>, at the end of the activation period), and on day 20 (T<sub>3</sub>, day 10 of the retention period).

Anesthesia was induced with intravenous pentobarbital (3%, 30 mg/kg) through the auricular vein.



**Figure 1.** The RME appliance in the rabbit.

Animals were placed in a prone position on a custom device with their heads secured stationary and parallel to the CT couch. A low-radiation, noncontrast CT head scan was performed before perfusion to determine the scope of the cerebrum (80 kV, 100 mA, matrix  $512 \times 512$ , slice thickness 2 mm). For perfusion imaging, a fixed 5-mm-thick slice was selected to cover the whole brain. The contrast material (Omnipaque, 300 mg/mL; 1.5 mL/kg) was injected at a rate of 0.3 mL/s through the auricular vein with an automatic injector (Meorao). After 5 seconds, a cine (continuous) scan was initiated with the following parameters: 130 kV and 160 mA, 1 second per rotation for a duration of 50 seconds, and a  $512 \times 512$  image matrix. Four 5-mm-thick axial sections were acquired with the 16-section CT scanner, and approximately 70 images were collected with a section thickness of 5 mm.

All the images were transferred to an imaging workstation (Syngo MultiModality Workplace, Siemens), where functional analyses were conducted on the images with p-CT software (Syngo Neuro Perfusion CT, Siemens). To obtain time density curves, the larger caliber superior sagittal sinus is traditionally used as the reference vessel. A region of interest (ROI) was manually drawn on each functional map of CBF, including the entire cerebral cortex area bilaterally, while ROIs were automatically positioned onto the corresponding CBV and mean transit time (MTT) maps. The ROIs were drawn on a representative transverse plane.

**Table 1.** Statistical Comparison of the Measurements at T0, T1, T2, and T3<sup>a</sup> with One-Way ANOVA and the Least Significant Difference Post Hoc Test

Time <sup>a</sup>	CBF (mL/100 g/min)		CBV (mL/100 g)		MTT (s)	
	RME	Control	RME	Control	RME	Control
T0	37.10 ± 11.10	45.27 ± 12.51	18.48 ± 4.38	22.21 ± 7.35	74.21 ± 13.25	76.05 ± 10.93
T1	39.88 ± 13.39	46.79 ± 10.81	20.24 ± 7.95	23.84 ± 4.96	77.49 ± 22.92	81.75 ± 10.43
T2	46.87 ± 13.83	49.81 ± 9.82	24.46 ± 5.34*	24.95 ± 6.38	87.75 ± 14.38*	81.22 ± 8.09
T3	43.68 ± 9.92	48.65 ± 11.11	23.61 ± 7.53	24.98 ± 7.58	78.20 ± 10.11	80.23 ± 10.55

<sup>a</sup> T0 indicates day 0 (baseline); T1, day 5 after activation; T2, day 10 (activation finished); and T3, day 20 of treatment (day 10 of retention).

\* Statistically significant versus T0.

## Data and Statistical Analysis

CBF, CBV, and MTT maps were generated by Syngo Neuro Perfusion software (Siemens) for each time point. Each color perfusion map was measured by two doctors. Parametric values of the ROIs representing the cerebral cortex were obtained from the CBF, CBV, and MTT maps. Bilateral brain values were averaged.

All analyses were performed with SPSS for Windows (version 13, SPSS Inc, Chicago, Ill), and significant differences were defined as  $P < .05$ . Data were represented by means ± standard deviations. The Kolmogorov-Smirnov test was used at baseline to determine whether the values were normally distributed. Two-way analysis of variance (ANOVA) was used as an omnibus test to identify main significant differences between the experimental and control group. Differences within groups were assessed by one-way ANOVA, with post hoc analysis between different time points.

## RESULTS

The measurement results from the p-CT studies in the two groups are given in Table 1. The serial pixel-based color-coded parametric p-CT maps showing the CBV, CBF, and MTT data are shown in Figure 2.

Normal distribution was confirmed with the Kolmogorov-Smirnov test ( $P < .05$ ) at baseline.

The mean CBF within the RME group increased from 37.10 to 46.87 mL/100 g/min from T0 to T2 and then decreased to 43.68 mL/100 g/min at T3; however, these changes were not statistically significantly different. From T0 to T2, a similar tendency was found for CBV and MTT: mean CBV and MTT increased significantly, from 18.48 to 24.46 mL/100 g and from 74.21 to 87.75 seconds, respectively (Figure 3).

From T0 to T3, all perfusion parameters showed increases in the RME group. CBF grew from 37.10 mL/100 g/min at T0 to 43.68 mL/100 g/min at T3, CBV increased from 18.48 mL/100 g to 23.61 mL/100 g, and MTT increased from 74.21 to 78.20 seconds; however, these differences were not statistically significantly different.

In the control group, no parameters changed significantly at any time points. Two-way analysis of variance indicated significant differences with respect to time and treatment on CBF, CBV, and MTT ( $P = .20$ ).

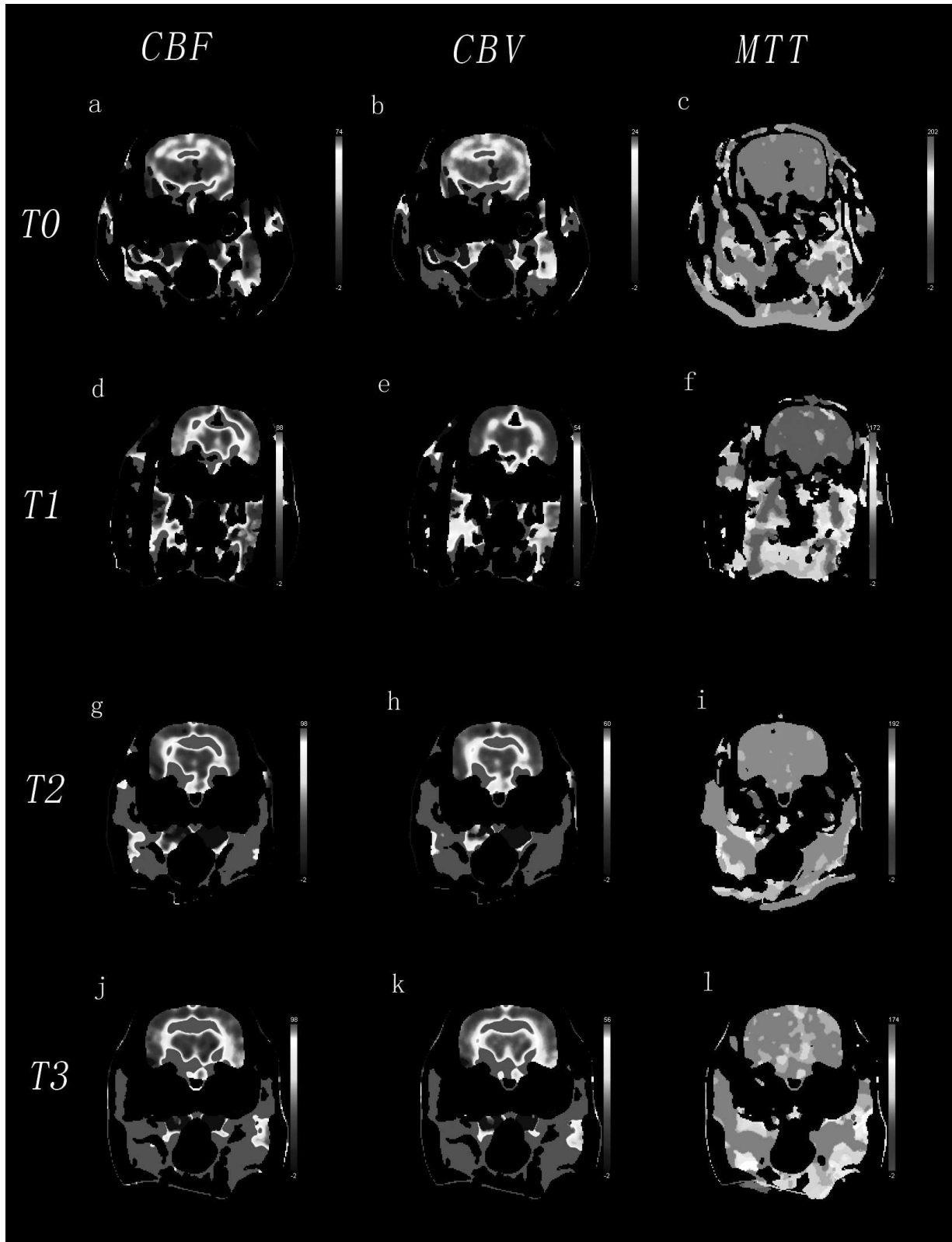
## DISCUSSION

P-CT has always played an important role in detecting and treating many types of cerebrovascular diseases. However, the orthodontic application of p-CT is rarely seen. As an efficient and noninvasive application, p-CT may be suitable for monitoring the follow-up treatment responses caused by some orthopedic therapies on the hemodynamic changes of the brain. Through the use of quantitative parameters, p-CT can analyze the hemodynamic changes caused by RME.

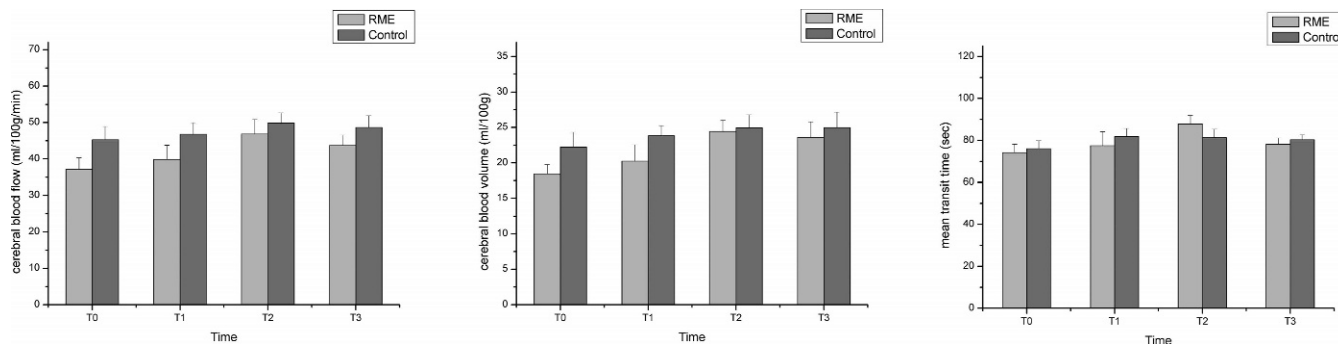
Although dynamic contrast-enhanced imaging can be obtained by both magnetic resonance imaging and CT, p-CT is more available and efficient and less expensive than magnetic resonance.<sup>20</sup> Unlike the technique proposed by Feng et al.,<sup>21</sup> which requires the removal of a section of the skull to place an ultrasonic flow probe, p-CT is a noninvasive method that can be measured repeatedly in vivo, and no surgery is needed.

RME has been used routinely to correct maxillary transverse deficiency. Although the RME force is concentrated on widening the maxilla, the transverse forces are transmitted via the pterygomaxillary connection to the unpaired sphenoid bone. Therefore, high stresses are observed in the sphenoid bone, particularly the greater wing and the superior orbital fissure, as confirmed by a number of finite element analyses<sup>11-16</sup> and two photoelastic analyses.<sup>22,23</sup> Through the use of fresh pig heads, Sun et al.<sup>24</sup> recently proved that RME can induce significant physiologic-level strains at the circummaxillary sutures. However, the extent to which the RME forces affect brain hemodynamics has not yet been studied extensively.

In this study, although an increase in CBF was seen from T0 to T2 during the activation period, this difference was not significant between the two time points. As we know, a decrease in CBF always indicates an



**Figure 2.** Image impressions of parametric p-CT maps. a, d, g, j indicate CBF at T0, T1, T2, and T3, respectively; b, e, h, k, CBV at T0, T1, T2, and T3, respectively; and c, f, i, l, MTT at T0, T1, T2, and T3, respectively.



**Figure 3.** Changes in (a) mean CBF, (b) mean CBV, and (c) MTT.

insufficient blood supply, sometimes to the point of ischemia. The absence of a decrease in CBF indicates the safety of the RME therapy as an orthopedic method in accordance with the long-term stability of clinical application. The relatively stable CBF values seen here might be a result of the cerebral circulation reserve and the autoregulatory ability of the brain.

In the RME group, the CBV showed a statistically significant increase during the activation period; the CBV also increased after the retention period, although insignificantly. The increases in both CBV and CBF may help to explain why RME might alleviate some symptoms of enuretic children. Children ages 4–6 years who wet their beds more than two nights per month are diagnosed with nocturnal enuresis (NE). Several studies have investigated the effects of RME on NE.<sup>25–28</sup> These studies showed that NE was greatly reduced or had ceased completely within a few months of maxillary expansion. A 10-year follow-up study showed that nearly 50% of the positive effects were still stable 10 years after the end of orthodontic treatment.<sup>29</sup> One of the main features of the children with NE is high arousal thresholds during sleep.<sup>30</sup> The high stress distribution focused on several foramina in the cranial base caused by RME may cause the nearby blood vessels to dilate. As a result of the vasodilator effect, manifested as increased CBV and CBF, the blood and oxygen supply to the brain is also increased, which might make children with NE sleep less “deeply.” According to Foltán et al.,<sup>31</sup> the respiratory disturbance index and obstructive apneas of patients during sleep improved significantly when treated with surgically assisted RME. In a recent study, Schütz et al.<sup>32</sup> analyzed, through polysomnography, the nocturnal breathing of 16 adolescents who underwent maxillary expansion and mandibular advancement with a Herbst appliance. The number of respiratory effort-related arousals and the respiratory disturbance index decreased after treatment. Foltán et al.<sup>31</sup> and Schütz et al.<sup>32</sup> attributed these changes to an increased nasal volume. But according to Deeb et al.,<sup>33</sup> Langer et al.,<sup>34</sup> and Giuca et al.,<sup>35</sup> there was no significant correlation between the increase in nasal volume and transverse

expansion. Therefore, there may be some connection between the increased CBV and the examined sleep parameters.

In his work, Nevéus<sup>36,37</sup> pointed out that RME as a presumptive sleep-oriented therapy still needs further research. As we know, with an increase in age, NE children self-heal at a rate of about 15% per year. Herein lies the hypothesis that as children grow, their cranio-cerebral size and CBV also increase, leading to the 15% self-healing rate. Carotenuto et al.<sup>38</sup> also found a higher prevalence of a dolico-facial pattern in primary NE children, which correlated cranio-cerebral size with NE.

Also, as a result of the vasodilator effect, MTT increased from baseline to T2 during the activation period and then decreased slightly after retention, in accordance with the change in the expansion force. Because the activation lasted for 10 days, the cumulative strength of maxillary arch expansion achieved its peak at T2.

## CONCLUSIONS

- Our results suggest that for the treatment of transverse maxillary deficiency, RME is a safe method despite its high orthopedic expansion force.
- In addition to its common use in cerebrovascular diseases, the application of p-CT in orthodontics also proved effective in evaluating the follow-up hemodynamic changes of the brain caused by therapy with RME.
- The fact that there is such an increase in both CBV and CBF may help to explain why RME could alleviate the symptoms of enuretic children.

## ACKNOWLEDGMENTS

We gratefully appreciate the support of the subjects who participated in this study. This study was supported in part by the National Natural Science Foundation of China (30973361).

## REFERENCES

1. Cianfoni A, Colosimo C, Basile M, et al. Brain perfusion CT: principles, technique and clinical applications. *Radiol Med.* 2007;112(8):1225–1243.

2. Suzuki K, Morita S, Masukawa A, et al. Utility of CT perfusion with 64-row multi-detector CT for acute ischemic brain stroke. *Emerg Radiol.* 2011;18(2):95–101.
3. Hanson EH, Roach CJ, Ringdahl EN, et al. Developmental venous anomalies: appearance on whole-brain CT digital subtraction angiography and CT perfusion. *Neuroradiology.* 2011;53(5):331–341.
4. Ren G, Chen S, Wang Y, et al. Quantitative evaluation of benign meningioma and hemangiopericytoma with peritumoral brain edema by 64-slice CT perfusion imaging. *Chin Med J (Engl).* 2010;123(15):2038–2044.
5. Angell EH. Treatment of irregularity of the permanent or adult teeth. *Dent Cosmos.* 1860;1:540–544.
6. Deeb W, Hansen L, Hotan T, et al. Changes in nasal volume after surgically assisted bone-borne rapid maxillary expansion. *Am J Orthod Dentofacial Orthop.* 2010;137:782–789.
7. Leonardi R, Sicurezza E, Cutrera A, et al. Early post-treatment changes of circumaxillary sutures in young patients treated with rapid maxillary expansion. *Angle Orthod.* 2011;81(1):36–41.
8. Gardner GE, Kronman JH. Cranioskeletal displacements caused by rapid palatal expansion in the rhesus monkey. *Am J Orthod.* 1971;59:146–155.
9. Baydas B, Yavuz I, Uslu H, et al. Nonsurgical rapid maxillary expansion effects on craniofacial structures in young adult females: a bone scintigraphy study. *Angle Orthod.* 2006;76:759–767.
10. Leonardi R, Cutrera A, Barbato E. Rapid maxillary expansion affects the spheno-occipital synchondrosis in youngsters. *Angle Orthod.* 2010;80:106–110.
11. Boryor A, Geiger M, Hohmann A, Wunderlich A, Sander C, Martin Sander F, Sander FG. Stress distribution and displacement analysis during an intermaxillary disjunction—a three-dimensional FEM study of a human skull. *J Biomech.* 2008;41:376–382.
12. Provatidis C, Georgiopoulos B, Kotinas A, McDonald JP. On the FEM modeling of craniofacial changes during rapid maxillary expansion. *Med Eng Phys.* 2007;29:566–579.
13. Holberg C. Effects of rapid maxillary expansion on the cranial base—an FEM analysis. *J Orofac Orthop.* 2005;66:54–66.
14. Jafari A, Shetty KS, Kumar M. Study of stress distribution and displacement of various craniofacial structures following application of transverse orthopedic forces—a three-dimensional FEM study. *Angle Orthod.* 2003;73:12–20.
15. Iseri H, Tekkaya AE, Oztan O, Bilgic S. Biomechanical effects of rapid maxillary expansion on the craniofacial skeleton, studied by the finite element method. *Eur J Orthod.* 1998;20:347–356.
16. Lee H, Ting K, Nelson M, Sun N, Sung SJ. Maxillary expansion in customized finite element method models. *Am J Orthod Dentofacial Orthop.* 2009;136:367–374.
17. Mehra P, Cottrell DA, Caiazzo A, et al. Life-threatening delayed epistaxis after surgically assisted rapid palatal expansion. A case report. *J Oral Maxillofac Surg.* 1999;57:201–204.
18. Lanigan DT, Mintz SM. Complications of surgically assisted rapid palatal expansion: review of the literature and report of a case. *J Oral Maxillofac Surg.* 2002;60:104–110.
19. Memikoğlu TU, Iseri H. Nonextraction treatment with a rigid acrylic, bonded rapid maxillary expander. *J Clin Orthod.* 1997 Feb;31(2):113–118.
20. Jain R. Perfusion CT imaging of brain tumors: an overview. *AJNR Am J Neuroradiol.* 2010 Nov 24. Epub ahead of print.
21. Feng SY, Samarasinghe T, Phillips DJ, et al. Acute and chronic effects of endotoxin on cerebral circulation in lambs. *Am J Physiol Regul Integr Comp Physiol.* 2010 Mar;298(3):R760–766.
22. Júnior SM, Asprino L, Moraes MD. Photoelastic analysis of stress distribution of surgically assisted rapid maxillary expansion with and without separation of the pterygomaxillary suture. *J Oral Maxillofac Surg.* 2011 Jun;69(6):1771–1775.
23. Kusakabe T, Caputo AA, Shetty V, Iida J. Biomechanical rationale for surgically facilitated expansion of the maxilla in the cleft palate patient. *World J Orthod.* 2007 Summer;8(2):167–173.
24. Sun Z, Hueni S, Ching B, et al. Mechanical strain at alveolar bone and circummaxillary sutures during acute rapid palatal expansion. *Am J Orthod Dentofacial Orthop.* 2011;139:e219–e228.
25. Freeman RD. Psychopharmacology and the retarded child. In: Menolascino FJ, ed. *Psychiatric Approach to Mental Retardation.* New York: Basic Books; 1970:294–368.
26. Timms DJ. Rapid maxillary expansion in the treatment of nocturnal enuresis. *Angle Orthod.* 1990;60:229–233.
27. Kurol J, Modin H, Bjerkhoel A. Orthodontic maxillary expansion and its effect on nocturnal enuresis. *Angle Orthod.* 1998;68:225–232.
28. Usumeş S, İşeri H, Orhan M, Basciftci FA. Effect of rapid maxillary expansion on nocturnal enuresis. *Angle Orthod.* 2003;73:532–538.
29. Schütz-Fransson U, Kurol J. Rapid maxillary expansion effects on nocturnal enuresis in children. *Angle Orthod.* 2008;78:201–208.
30. Nevéus T. Nocturnal enuresis—theoretic background and practical guidelines. *Pediatr Nephrol.* 2011 Aug;26(8):1207–1214.
31. Foltán R, Hoffmannová J, Pavlíková G. The influence of orthognathic surgery on ventilation during sleep. *Int J Oral Maxillofac Surg.* 2011 Feb;40(2):146–149.
32. Schütz TC, Dominguez GC, Hallinan MP. Class II correction improves nocturnal breathing in adolescents. *Angle Orthod.* 2011 Mar;81(2):222–228.
33. Deeb W, Hansen L, Hotan T. Changes in nasal volume after surgically assisted bone-borne rapid maxillary expansion. *Am J Orthod Dentofacial Orthop.* 2010;137:782–789.
34. Langer MR, Itikawa CE, Valera FC. Does rapid maxillary expansion increase nasopharyngeal space and improve nasal airway resistance? *Int J Pediatr Otorhinolaryngol.* 2011 Jan;75(1):122–125.
35. Giuca MR, Pasini M, Galli V, et al. Correlations between transversal discrepancies of the upper maxilla and oral breathing. *Eur J Paediatr Dent.* 2009;10(1):23–28.
36. Nevéus T. Diagnosis and management of nocturnal enuresis. *Curr Opin Pediatr.* 2009 Apr;21(2):199–202.
37. Nevéus T. Nocturnal enuresis—theoretic background and practical guidelines. *Pediatr Nephrol.* 2011 Aug;26(8):1207–1214.
38. Carotenuto M, Esposito M, Pascotto A. Facial patterns and primary nocturnal enuresis in children. *Sleep Breath.* 2011 May;15(2):221–227.