

## Long-Term Stability of Surgical Mandibular Setback

Heon Jae Cho<sup>a</sup>

### ABSTRACT

**Objective:** To test the relationship between positional changes of the proximal segments during surgery and the positional rebound of the mandible during the postsurgical period of orthodontic treatment.

**Materials and Methods:** The sample included records for 34 patients who had received sagittal split surgery for the correction of mandibular prognathism. Data were collected from standardized cephalometric radiographs taken immediately prior to surgery (T2), immediately following surgery (T3), and following the completion of orthodontic treatment (T4). Linear and angular changes in the orientation of the posterior border of the ascending ramus between time points T2, T3, and T4 were measured relative to superimposition on the anterior cranial base. In addition, linear changes in the position of pogonion between T3 and T4 were measured.

**Results:** The magnitude of linear displacement of the posterior border of the proximal segment during surgery (T2 to T3) was statistically significantly correlated ( $r = .61$ ) with the magnitude of linear displacement of pogonion during the postsurgical phase of orthodontic treatment (T3 to T4). There was a strong relationship between the magnitude of angular ( $r = .67$ ) displacement of the posterior border of the proximal segments during surgery (T2 to T3) and the magnitude of angular rebound of the posterior border of the proximal segments that occurred during the postsurgical phase of orthodontic treatment (T3 to T4).

**Conclusions:** When rigid fixation procedures alter the position of the proximal segments during sagittal split osteotomy of the mandible, the proximal segments tend to go back toward their presurgical positions following surgery.

**KEY WORDS:** Stability; Surgical mandibular setback

### INTRODUCTION

The correction of Class III skeletal malocclusions has been one of the most difficult problems confronting orthodontics. Combined orthodontic and surgical approaches appear to be the only appropriate treatment options for severe mandibular prognathism in adults.<sup>1</sup> Mandibular setback surgery is usually the surgical procedure of choice for most patients with severe mandibular prognathism, but the results of orthognathic surgery are frequently unstable even with rigid fixa-

tion.<sup>2-6</sup> Most relapse after orthognathic surgery seems to occur in the immediate postsurgical period.<sup>7-9</sup>

Sinclair<sup>6</sup> summarized the previous stability studies in 1993. According to his summary, in mandibular setback surgery the severity of the relapse is about 20%–30% of the surgical changes in the anterior direction using either wire or rigid fixation in both short- and long-term follow-up of the surgery.

Eggersperger et al<sup>9</sup> reported on the short- and long-term skeletal changes after mandibular setback using bilateral sagittal split ramus osteotomy with rigid screw fixation. During the first postoperative year, there was a skeletal relapse of 14% of the initial skeletal setback at B-point and pogonion.

Bailey<sup>10</sup> reported a study of stability based on the University of North Carolina dentofacial database which contains over 1400 patients with at least a 1-year follow-up. According to her paper, mandibular setback surgery is one of the three procedures which can be grouped in the “problematic category,” which was defined as a 40%–50% chance of 2–4 mm postsurgical change and a significant chance of more than a 4-mm change.

<sup>a</sup> Associate Professor, Department of Orthodontics, Arthur A. Dugoni School of Dentistry, University of the Pacific, San Francisco, Calif.

Corresponding author: Dr Heon Jae Cho, Associate Professor, Department of Orthodontics, Arthur A. Dugoni School of Dentistry, University of the Pacific, 2155 Webster St, San Francisco, CA 94115 (e-mail: hcho@pacific.edu)

Accepted: November 2006. Submitted: May 2006.  
© 2007 by The EH Angle Education and Research Foundation, Inc.

**Table 1.** Time Points at Which Records Are Obtained

T1	Start of presurgical orthodontic treatment
T2	Immediately before surgery
T3	Immediately after surgery
T4	End of active orthodontic treatment

However, even with this information it is still not possible to determine which patients will show significant surgical relapse. Komori<sup>11</sup> reported a positive relationship between the positional changes of the proximal segment during surgery and postoperative relapse of the surgery. This is so far, one of very few studies possibly suggesting a main causative factor for the postoperative relapse of mandibular setback surgery.

The purpose of this study is to determine any relationship between positional changes of the proximal segments during surgery and the positional rebound of the mandible during the postsurgical period.

## MATERIALS AND METHODS

The sample consisted of the records of 59 patients who had mandibular setback surgery for the correction of mandibular prognathism between 1992 and 1998. All subjects are from the author's practice and had an initial chief complaint of excessive chin prominence. The inclusion criteria were:

- Diagnosis of severe Class III skeletal malocclusion with prominent mandibular prognathism in a non-growing adult.
- Treatment involving bilateral split osteotomy followed by rigid fixation of the proximal and distal segments.
- Availability of technically satisfactory lateral cephalograms at time points immediately prior to surgery (T2), immediately after surgery (T3), and at the end of active orthodontic treatment (T4) (Table 1).

The present investigation involved a comparison of measurements on the lateral cephalograms made at T2, T3, and T4 for all patients who met the criteria for inclusion in the experimental sample.

Of the 59 sagittal split osteotomy patients whose records were originally identified, 25 subjects were dropped because the quality of one or more of their cephalograms was deemed technically unsatisfactory for precise measurements. The final sample, therefore, included 34 patients (20 female and 14 male). The mean age of the patients at the time of surgery

was 22 years 7 months. Presurgical decompensation was achieved in most of the subjects. For the presurgical orthodontic treatment, maxillary teeth were extracted in 18 subjects to eliminate maxillary crowding and to reduce upper incisor proclination. A total of 36 maxillary teeth were removed. Among these, 25 were bicuspids, 10 were molars, and one was an incisor. In the mandibular arch, alignment and proclination of incisors were accomplished mostly without extraction. There was only one subject who was treated with presurgical extraction of mandibular teeth (two bicuspids). The mean initial mandibular incisor plane angle (IMPA) was 81.9° (SD 8.36°), and mean presurgical IMPA was 89.0° (SD 6.17°). Average overall treatment duration (T1–T4) was 30.3 months (Table 2). The average interval between immediate presurgical records and immediate postsurgical records was six days. The average duration of postsurgical treatment (T3–T4) was 10.9 months. All orthodontic treatment was performed by the author; surgical procedures were performed by one of six experienced surgeons.

## Measurements and Data Collection

Cephalograms taken at time points T2, T3, and T4 were traced and superimposed by the author using Björk's<sup>12,13</sup> structural cranial base method. Midlines were drawn for the double images in the inferior and posterior borders of the mandible. Five measurements were designed. All measurements were made to the nearest 0.5 mm and 1°. All linear measurements were made parallel to the Frankfort horizontal plane.

Measures A and B were made with the T2 and T3 films superimposed on the anterior cranial base, as shown in Figure 1. Measures C, D, and E were made with the T3 and T4 films superimposed on the anterior cranial base in the same manner, as shown in Figure 2.

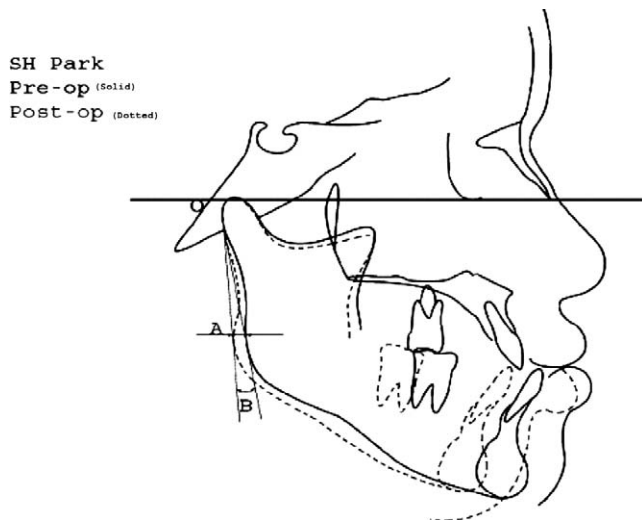
A scatterplot and correlation test was used to check any relationship between the positional changes of the proximal segments of the mandible during surgery and the positional changes of the proximal and distal segments of the mandible during the postsurgical phase of orthodontic treatment.

## RESULTS

All the measurements are summarized in Table 3.

**Table 2.** Intervals Between Different Time Points

Duration of presurgical orthodontic treatment (T1–T2)	19.3 ± 5.9 months
Interval between immediate presurgical records and immediate postsurgical records (T2–T3)	~6 days
Duration of postsurgical orthodontic treatment (T3–T4)	10.9 ± 4.1 months
Duration of overall orthodontic treatment (T1–T4)	30.3 ± 7.7 months



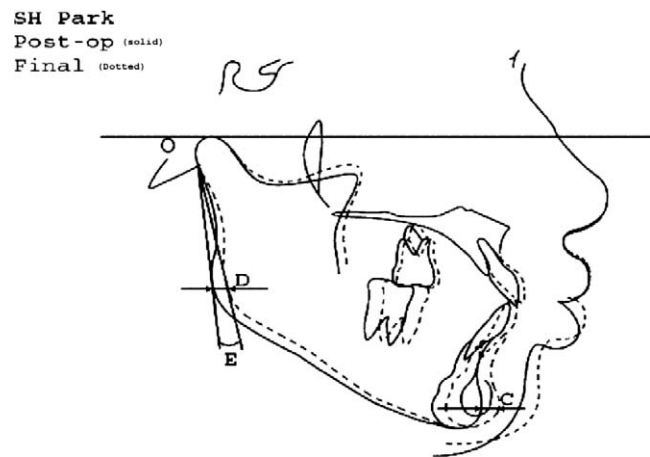
**Figure 1.** Measure A ( $\Delta$ Ram-mm T3–T2): The amount of linear changes at the distal border of proximal segments that occurred during surgery (T2–T3). Measure A was a measurement of the most displaced distance between two images of T2 and T3 tracings at the distal border of the proximal segments on the line parallel to FH plane in superimposition between T2 and T3 tracings. Measure B ( $\Delta$ Ram-deg T3–T2): The amount of angular changes at the distal border of proximal segments that occurred during surgery (T2–T3). Measure B was a measurement of the angle made by a tangent line at the distal border of proximal segments at T2 and a tangent line at the distal border of proximal segments at T3 in superimposition between T2 and T3 tracings.

### Analysis 1

Figure 3 shows a general tendency for the recovery in the position of the posterior border of the ascending ramus in the postsurgical phase (Measure D,  $\Delta$ Ram-mm T4–T3) to be greater in cases in which its posterior displacement during surgery (Measure A,  $\Delta$ Ram-mm T3–T2) was greater. The strength of the correlation between these two variables is  $r = .65$ ,  $P = .0001$ . This means that, in this sample, the amount of linear displacement of the posterior border of the proximal segments during surgery (T3–T2) is closely related to the amount of linear rebound of the posterior border of the proximal segment during the postsurgical phase of orthodontic treatment (T4–T3).

### Analysis 2

Figure 4 shows that Measure B ( $\Delta$ Ram-deg T3–T2) and Measure E ( $\Delta$ Ram-deg T4–T3) are very highly correlated,  $r = .67$ ,  $P = .0001$ . This means that the amount of angular displacement of the posterior border of the proximal segments during surgery (T2–T3) is highly related to the amount of angular rebound of the posterior border of the proximal segments during the postsurgical phase of orthodontic treatment (T3–T4).



**Figure 2.** Measure C ( $\Delta$ Pog-mm T4–T3): The amount of linear change at the pogonion that occurred during the postoperative phase of orthodontic treatment (T3–T4). Measure C was a measurement of the most displaced distance between two images of T3–T4 at the pogonion on the line parallel to FH plane in superimposition between T3 and T4 tracings. Measure D ( $\Delta$ Ram-mm T4–T3): The amount of linear change at the distal border of proximal segments that occurred during postoperative phase of orthodontic treatment (T3–T4). Measure D was a measurement of the most displaced distance between two images of T3 and T4 tracings at the distal border of proximal segments on the line parallel to FH plane in superimposition between T3 and T4 tracings. Measure E ( $\Delta$ Ram-deg T4–T3): The amount of angular change at the distal border of proximal segments that occurred during postoperative phase of orthodontic treatment (T3–T4). Measure E was a measurement of the angle made by a tangent line at the distal border of proximal segments at T3 and a tangent line at the distal border of proximal segments at T4 in superimposition between T3 and T4 tracings.

### Analysis 3

A scatterplot and Pearson correlation ( $r$ ) were used to investigate the relationship between the amount of linear displacement of the posterior border of the proximal segments during surgery (Measure A,  $\Delta$ Ram-mm T3–T2), and the amount of linear displacement of pogonion during the postsurgical phase of orthodontic treatment (Measure C,  $\Delta$ Pog-mm T4–T3). Figure 5 shows that there is a general tendency for the anterior displacement of pogonion in the postsurgical phase (T4–T3) to be greater in cases in which the posterior displacement of the posterior border of the proximal segment was greater during surgery (T3–T2). The strength of the correlation between the two variables is  $r = .61$ ,  $P = .0001$ . This means that, in this sample, the amount of linear displacement of the posterior border of the proximal segments during surgery is closely related to the amount of linear rebound of pogonion during the postsurgical phase of orthodontic treatment.

### DISCUSSION

Rivera et al<sup>14</sup> reported that patients underwent orthognathic surgery to improve esthetic, functional, and

**Table 3.** Measurements (See Figures 1 and 2)

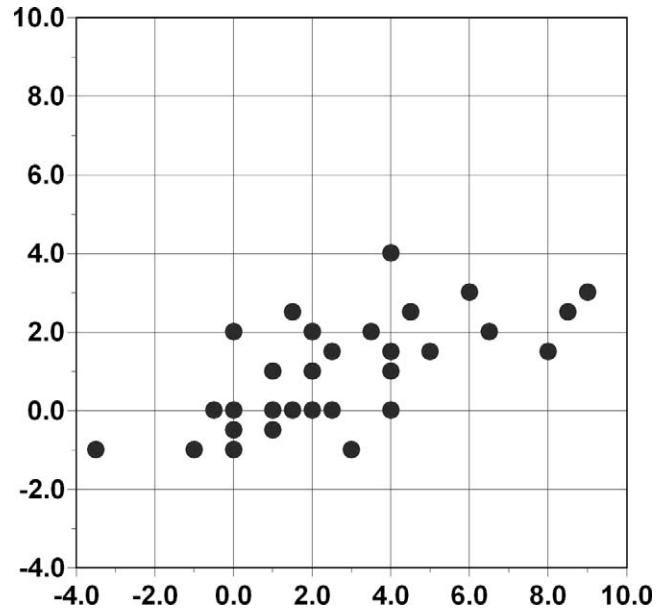
Patient	A	B	C	D	E	Age at Surgery (Years-Months)
1	2.5	2.5	2.0	1.5	0.0	23-6
2	-3.5	-1.5	1.0	-1.0	-0.5	21-9
3	-1.0	-1	1.5	-1.0	0.0	20-5
4*	6.0	6	4.0	3.0	4.0	16-4
5*	4.0	5	2.0	1.0	1.0	14-8
6	8.0	9.5	2.0	1.5	4.0	24-6
7	0.0	1.5	0.0	0.0	0.0	23-5
8	4.0	2	4.0	0.0	-2.0	21-11
9	5.0	3	3.5	1.5	2.0	25-5
10	1.5	1.5	0.0	0.0	0.5	21-7
11	9.0	8	5.0	3.0	2.0	21-9
12	1.0	0.5	0.0	0.0	0.0	26-0
13	8.5	4	2.5	2.5	1.5	25-1
14*	1.0	4	0.5	1.0	1.0	18-5
15	2.5	4.5	3.0	0.0	2.5	25-8
16	6.5	8	2.0	2.0	2.0	24-1
17	2.0	3.5	2.5	2.0	3.5	26-3
18	4.0	5.5	3.0	4.0	5.5	20-6
19	2.0	1.5	1.0	1.0	1.0	22-2
20	2.0	2.5	0.0	0.0	-0.5	26-10
21	4.5	7	2.0	2.5	4.0	24-8
22	2.0	1	1.5	1.0	1.0	27-10
23	4.0	3.5	3.0	1.5	1.0	23-10
24*	2.0	2.5	2.5	2.0	2.5	19-2
25	3.5	3	2.0	2.0	2.0	25-7
26*	1.0	2	1.0	1.0	2.0	19-8
27	1.5	1.5	-2.5	2.5	2.0	21-9
28	0.0	1.5	-1.0	-1.0	1.0	20-11
29	3.0	6	-0.5	-1.0	2.5	22-3
30	-0.5	1	0.0	0.0	1.0	24-2
31*	0.0	1.5	2.0	2.0	2.5	18-6
32	0.0	0	0.0	-0.5	0.0	27-1
33	1.0	2	0.0	-0.5	0.0	23-3
34	4.5	7.5	1.5	2.5	3.5	20-3

\* Patient less than 20 years of age at the time of surgery.

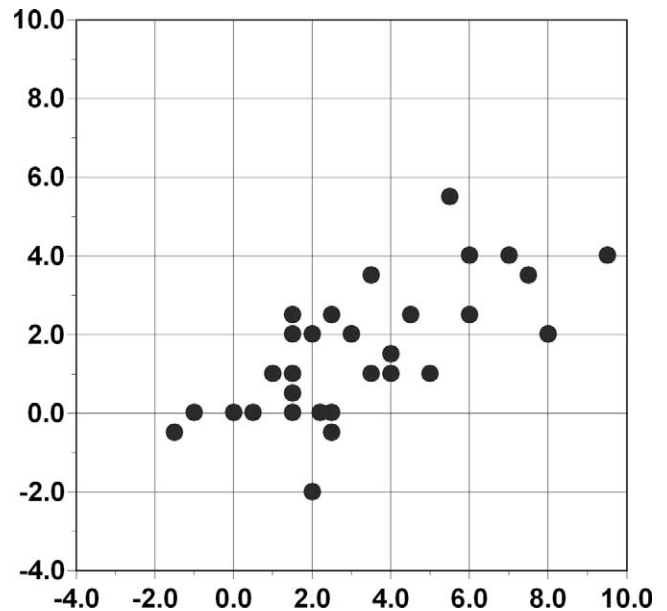
temporomandibular joint (TMJ) problems. However, these benefits from the orthognathic surgery are not always realized. One of main reasons for an unsatisfactory treatment outcome could be the frequently observed relapse of surgical changes. It also has been reported that the relapse rates following mandibular setback surgery are among the highest for any surgical procedure.<sup>2,3,10</sup>

According to the author's clinical observation, most relapse after mandibular setback surgery seems to occur during the immediate postsurgical phase within the first two months following surgery. Mobarak<sup>12</sup> reported similar findings. There seems to be additional minor relapse during the period from two months to one year after surgery. This author also has observed minimal relapse beyond the first post-postoperative year, similar to that reported by Eggenesperger et al.<sup>9</sup>

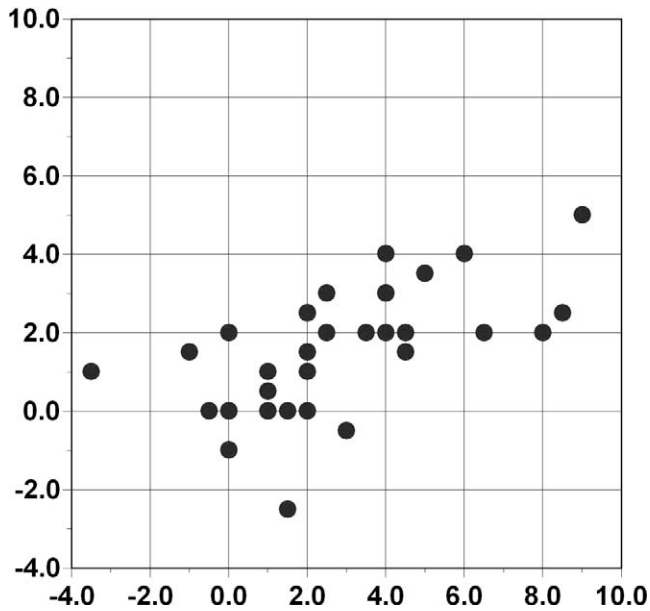
According to Analyses 1 and 2, a strong relationship exists between the amount of positional change of the proximal segment during surgery and the amount of



**Figure 3.** Correlation between the amount of linear displacement at the posterior border of proximal segments during surgery (Measure A,  $\Delta$ Ram-mm T3-T2) and the amount of linear rebound at the posterior border of proximal segments during postsurgical phase of orthodontic treatment (Measure D,  $\Delta$ Ram-mm T4-T3),  $r = .65$ , and  $P = .0001$ .



**Figure 4.** Correlation between the amount of angular displacement at the posterior border of proximal segments during surgery (Measure B,  $\Delta$ Ram-deg T3-T2) and the amount of angular rebound at the posterior border of proximal segments during postsurgical phase of orthodontic treatment (Measure E,  $\Delta$ Ram-deg T4-T3),  $r = .67$ ,  $P = .0001$ .



**Figure 5.** Correlation between the amount of linear displacement at the posterior border of proximal segments during surgery (Measure A,  $\Delta$ Ram-mm T3-T2) and the amount of linear displacement at the pogonion during postsurgical phase of orthodontic treatment (Measure C,  $\Delta$ Pog-mm T4-T3),  $r = .61$ , and  $P = .0001$ .

positional relapse of the proximal segments of the mandible during the postsurgical phase of orthodontic treatment. This rebound of the proximal segment can affect the final position of the distal segment of the mandible which holds the dentition and pogonion, Analysis 3. Thus, this rebound tendency definitely affects the final occlusion and facial esthetics. In Class III mandibular setback surgery, surgeons tend to push proximal segments backward during the fixation procedure. This seems to be the main reason for the forward rebound of mandible in the majority of the mandibular setback surgery subjects. Infrequently, the opposite situation may occur. In some of the mandibular setback surgery subjects, unusual postsurgical changes involving backward displacement of mandible can occur when the surgeon brings the proximal segments forward during the fixation procedure.

In nine of the 34 subjects, genioplasty was performed in order to achieve optimal esthetic results. The measurements of pogonion in this study were made at T3 and T4. Both of these time points followed surgery. Since the surgical fixation following genioplasty was performed with rigid plates and surgical screws, there could be little or no change in the relationship between the pogonion area and the mandibular body between these time points.

The correlation between the amount of surgical correction and the amount of relapse needs more thorough study. Sinclair<sup>6</sup> reported that the mean severity of the relapse of mandibular setback surgery is about 20%–

30% of the total surgical change and is in the anterior direction. The percent of change varies greatly in different individuals and in some cases it is in the posterior direction. Bailey<sup>10</sup> said, "It is quite misleading to describe, in terms of the percentage of treatment, change that was retained at some follow-up time, as was done in many early articles on stability after orthognathic surgery. Reporting such percentages implies that the more we change, the more relapse would occur. In dentofacial patients, that almost never is the case." She also pointed out that it is hard to predict which patients will experience severe relapse after surgery.

In the present sample, six patients received maxillary surgery in addition to a mandibular setback. It is possible that postsurgical restriction of the space available for the tongue may have been a factor in mandibular relapse and that the alternative of maxillary advancement surgery would have provided more space for the tongue. Kawakami<sup>15</sup> and associates examined the effect of partial glossectomy on skeletal stability and postoperative change after mandibular setback surgery. They reported adaptations in hyoid bone position and tongue mass to the altered environment after setback surgery, but found no significant difference between the tongue reduction group and control group in the horizontal and vertical changes of incisor position one year after surgery.

Another possible factor in relapse after mandibular setback surgery is an expression of some remaining mandibular growth potential. Wolford et al<sup>4</sup> reported the efficacy of high condylectomy for management of condylar hyperplasia. In his study, the patients in group I ( $n = 12$ ; average age at surgery 17.5 years) were treated only with orthognathic surgery, including bilateral sagittal split osteotomy (BSSO), while the patients in group II ( $n = 25$ ; average age at surgery 16.7 years) had high condylectomy, articular disc repositioning, and orthognathic surgery including BSSO. All patients in group I grew back into skeletal and occlusal Class III relationships and required additional treatment. Only one patient in group II required secondary surgery. Wolford et al<sup>4</sup> also reported a statistically significant difference between groups in terms of stability at long-term follow-up. The patients in his sample were obviously growing at the time of surgery since patients with mandibular prognathism tend to have more mandibular growth and a longer growth period.

The protocol for this study, in terms of treatment timing for the patients with mandibular prognathism, is to check mandibular growth in serial lateral cephalometric radiographs taken at 6-month intervals. Presurgical orthodontic treatment is usually started after the completion of mandibular growth, defined as the absence of observable growth in the last three cephalograms. In the present sample, there were six patients who

were younger than 20 years of age at the time of surgery (asterisk in Table 3). Interestingly, three of these patients showed very stable results.

The presurgical position of proximal segments relative to adjacent anatomic structures seems to be very critical in each person's stomatognathic system. Its position may be related to other important physiologic functions such as respiration, chewing, swallowing, and speech. So, if the presurgical position of proximal segments is changed during a treatment procedure, such as mandibular setback surgery, there is a strong tendency for the structure to return to its original position. Therefore, this strong return tendency of the proximal segment of the mandible can be a driving force for change of the distal segments of the mandible during the postsurgical phase of orthodontic treatment.

## CONCLUSIONS

- If the position of the proximal segment of the mandible is changed during the fixation procedure during mandibular setback surgery, the proximal segment has a tendency to move back toward its presurgical position in the period following surgery.
- In the present sample, there were few or no changes in the mandibular position during the postsurgical phase of orthodontic treatment when the surgeon had maintained the presurgical positions of proximal segments during mandibular setback surgery.
- Maintaining the presurgical position of the proximal segments during surgery seems to be a major determinant of postsurgical stability.

## ACKNOWLEDGMENT

The author would like to extend his gratitude to Professor Yun Bae Kim, Sungkyunkwan University, South Korea, for his guidance in research design and data analysis and Dr. Sheldon Baumrind for his editorial advice. The author would also like to acknowledge Dr. Robert R. Boyd, Chairman of the Department of Orthodontics, University of the Pacific, Arthur A. Dugoni School of Dentistry, for his administrative support.

## REFERENCES

1. Cho HJ. Patient with severe skeletal Class III malocclusion and severe open bite treated by orthodontics and orthognathic surgery—a case report. *Am J Orthod Dentofacial Orthop.* 1996;110:155–162.
2. Proffit WR, Phillips C, Dann C, Turvey TA. Stability after surgical orthodontic correction of skeletal Class III malocclusion. I. Mandibular setback. *Int J Adult Orthodon Orthognath Surg.* 1991;6:7–18.
3. Proffit WR, Phillips C, Turvey TA. Stability after surgical orthodontic correction of skeletal Class III malocclusion. III. Combined maxillary and mandibular procedures. *Int J Adult Orthodon Orthognath Surg.* 1991;4:211–225.
4. Wolford LM, Mehra P, Reiche-Fischel O, Morales CA, Garcia-Morales P. Efficacy of high condylectomy for management of condylar hyperplasia. *Am J Orthod Dentofacial Orthop.* 2002;121:136–151.
5. Fuselier JC, Freitas RZ, Wolford LM. Stability of mandibular setback procedures with sagittal split osteotomies in nongrowing patients. *J Oral Maxillofac Surg.* 1999;57(suppl 1):94–95.
6. Sinclair PM. The long-term stability of orthognathic surgery. AAO audiotape, *PROD.* 1993; October:5–6.
7. Mobarak KA, Krogstad O, Espeland L, Lyberg T. Long-term stability of mandibular setback surgery: a follow-up of 80 bilateral sagittal split osteotomy patients. *Int J Adult Orthodon Orthognath Surg.* 2000;15:83–95.
8. Busby BR, Bailey LJ, Proffit WR, Phillips C, White RP. Long-term stability of surgical Class III treatment: a study of 5-year postsurgical results. *Int J Adult Orthodon Orthognath Surg.* 2002;17:159–170.
9. Eggensperger N, Raditsch T, Taghizadeh F, Iizuka T. Mandibular setback by sagittal ramus osteotomy: a 12-year follow-up. *Acta Odontol Scan.* 2005;63:183–188.
10. Bailey LJ, Cevidanes LH, Proffit WR. Stability and predictability of orthognathic surgery. *Am J Orthod Dentofacial Orthop.* 2004;126(3):273–277.
11. Komori E, Aigase K, Sugisaki M, Tanabe H. Cause of early skeletal relapse after mandibular setback. *Am J Orthod Dentofacial Orthop.* 1989;95:29–36.
12. Björk A, Skieller V. Normal and abnormal growth of the mandible. A synthesis of longitudinal cephalometric implant studies over a period of 25 years. *Eur J Orthod.* 1983;5:41–43.
13. Solow B. The dentoalveolar compensatory mechanism: background and clinical implications. *Br J Orthod.* 1980;7:145–161.
14. Rivera SM, Hatch JP, Dolce C, Bays RA, Van Sickels JE, Rugh JD. Patients' own reasons and patient-perceived recommendations for orthognathic surgery. *Am J Orthod Dentofacial Orthop.* 2000;118:134–141.
15. Kawakami M, Yamamoto K, Noshi T, Miyawaki S, Kirita T. Effect of surgical reduction of the tongue on dentofacial structure following mandibular setback. *J Oral Maxillofac Surg.* 2004;62:1188–1192.