

## Treatment and Posttreatment Effects of Quad-Helix/Crib Therapy of Dentoskeletal Open Bite

Paola Cozza<sup>a</sup>; Manuela Mucedero<sup>b</sup>; Tiziano Baccetti<sup>c</sup>; Lorenzo Franchi<sup>d</sup>

### ABSTRACT

**Objective:** To investigate the effects of the quad-helix/crib (Q-H/C) appliance in subjects with thumb-sucking habits and dentoskeletal open bite at 2 years after the end of active treatment.

**Materials and Methods:** The records of 21 subjects treated with the Q-H/C appliance were compared with a control group of 21 untreated subjects with similar vertical relationships. Lateral cephalograms were obtained before treatment (T1; mean age  $8.4 \pm 1.4$  years) and at about 2 years after treatment (T2; mean age  $11.7 \pm 1.9$  years) and analyzed. Mean treatment duration was 1.5 years  $\pm$  7 months. The T2–T1 changes in the two groups were compared with a non-parametric test for independent samples.

**Results:** The mean increase in overbite during Q-H/C therapy (4.1 mm) represented an overcorrection of the amount of anterior open bite at T2. Both the maxillary and mandibular incisors showed significantly greater extrusion in the Q-H/C group than in the control group. The treated group showed a greater downward rotation ( $1.8^\circ$ ) of the palatal plane than did the control group. This change was associated with a clinically significant reduction in the palatal plane/mandibular plane angle ( $-2.5^\circ$ ) in the Q-H/C group. The upper lip showed significant retraction relative to the E-plane in the treated group (3.6 mm) compared with the controls.

**Conclusions:** The Q-H/C appliance was effective in correcting dental open bite in 85% of the growing subjects with thumb-sucking habits and dentoskeletal open bites. Correction of anterior open bite was associated with a clinically significant improvement in maxillomandibular vertical skeletal relationships.

**KEY WORDS:** Quad-helix; Crib; Thumb-sucking habit; Open bite; Cephalometrics; Orthodontic treatment

### INTRODUCTION

Anterior open bite is a common dentoalveolar component of the craniofacial pattern in patients with in-

creased vertical dimension (also known as facial hyperdivergence or high-angle facial pattern).<sup>1–3</sup> A series of pathogenetic factors (abnormal tongue posture, tongue thrust, and overall sucking habits) can be associated with the formation or maintenance of anterior open bite in hyperdivergent patients during growth,<sup>4–7</sup> as well as with the establishment of transverse discrepancies concurrent with the vertical problems.<sup>7</sup> A recent study has highlighted that both prolonged sucking habits and hyperdivergent vertical relationships are able to increase significantly the probability of occurrence of an anterior dentoalveolar open bite in the mixed dentition.<sup>8</sup>

A proposed treatment protocol aimed at elimination of the thumb-sucking habit and at correction of both the anterior open bite and the maxillary transverse deficiency in growing high-angle subjects is represented by the use of a quad-helix appliance with the addition of a tongue crib (Q-H/C).<sup>9</sup> An investigation of the short-term outcomes of Q-H/C therapy showed clinical ef-

<sup>a</sup>Professor and Head, Department of Orthodontics, The University of Rome "Tor Vergata," Rome, Italy.

<sup>b</sup>Instructor, Department of Orthodontics, The University of Rome "Tor Vergata," Rome, Italy.

<sup>c</sup>Assistant Professor, Department of Orthodontics, The University of Florence, Florence, Italy; Thomas M. Graber Visiting Scholar, Department of Orthodontics and Pediatric Dentistry, School of Dentistry, The University of Michigan, Ann Arbor.

<sup>d</sup>Lecturer, Department of Orthodontics, The University of Florence, Florence, Italy; Thomas M. Graber Visiting Scholar, Department of Orthodontics and Pediatric Dentistry, School of Dentistry, The University of Michigan, Ann Arbor.

Corresponding author: Dr Lorenzo Franchi, Università degli Studi di Firenze, Via del Ponte di Mezzo, 46-48, 50127, Firenze, Italy (e-mail: l.franchi@odonto.unifi.it)

Accepted: August 2006. Submitted: June 2006.

© 2007 by The EH Angle Education and Research Foundation, Inc.

fectiveness in correcting the dental open bite in 90% of patients.<sup>10</sup> This favorable result was associated with clinically significant improvement in vertical skeletal relationships because of a downward rotation of the palatal plane. When compared with the effects of a removable appliance (open bite Bionator), the Q-H/C appliance was shown to be significantly more effective in the improvement of overbite.<sup>11</sup>

The use of a crib in conjunction with either removable or fixed appliances has been advocated often in the past to encourage discontinuation of sucking habits.<sup>5,12,13</sup> However, previous studies<sup>12-17</sup> did not use untreated controls with the same type of dentoskeletal disharmony, and they were confined to short-term observations.

The purpose of the present longitudinal study was to analyze the effectiveness of the Q-H/C appliance in subjects who presented with thumb-sucking habits and with dentoskeletal open bite vs a control group of untreated subjects with high-angle malocclusions. The changes in the treated group consisted of modifications produced during active treatment, followed by the modifications during a posttreatment period of approximately 2 years.

## MATERIALS AND METHODS

### Subjects

**Quad-Helix/Crib Sample.** The Q-H/C sample was obtained from a group of consecutively treated patients from an orthodontic practice. Lateral cephalograms of treated patients were analyzed, regardless of treatment results. The patients presented with the following features:

- Presence of thumb-sucking habits before treatment
- Constricted maxillary arch
- Negative overbite
- Fully erupted permanent first molars and permanent incisors (to avoid patients with "pseudo-open bite" caused by undererupted permanent incisors<sup>4</sup>)
- No permanent teeth extracted prior to or during treatment
- Two consecutive lateral cephalograms of good quality with adequate landmark visualization and with minimal or no rotation of the head, obtained before treatment (T1) and again approximately 2 years after the completion of treatment (T2)
- As derived from the cephalometric analysis at T1, value for mandibular plane angle (MPA) relative to Frankfort horizontal of 25° or greater<sup>7</sup>

The treated sample consisted of 21 subjects (15 female and 6 male subjects). The average age of the Q-H/C group at T1 was  $8.4 \pm 1.5$  years, the mean age

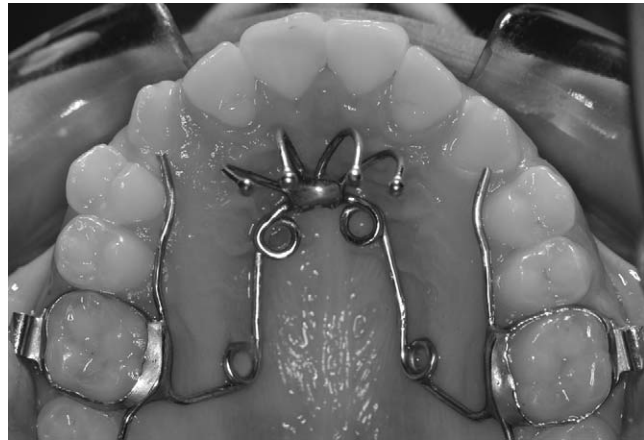


Figure 1. Design of the quad-helix/crib appliance.

at T2 was  $11.7 \pm 1.9$  years, and the mean duration of active treatment was 1.5 years  $\pm$  7 months. The overall observation period was  $3.3 \pm 1.3$  years, which included a period of approximately 2 years during which treated patients either wore no appliance (16 patients) or wore a removable appliance for retention for 1 year (5 patients). Prior to treatment, the mean overbite was  $-2.4 \pm 2$  mm. The sample included 10 subjects with Class I occlusion, 10 subjects with Class II malocclusion, and 1 subject with Class III malocclusion.

The Q-H appliance used in this study was made of 0.036-inch stainless steel wire soldered to bands on the second deciduous molars or the first permanent molars<sup>9</sup> (Figure 1). The lingual arms of the appliance were extended mesially to the deciduous canines or even to the permanent incisors. The anterior helices were brought as far forward on the palate as possible. Spurs to prevent thumb-sucking were formed from three segments of 0.036-inch stainless steel wire soldered to the anterior bridge of the Q-H. The wire segments were inclined lingually to avoid impingement on the sublingual mucosa.<sup>9</sup> Activation of the Q-H was equivalent to the buccolingual width of one molar.

**Control Sample.** Cephalograms representing T1 and T2 for 21 subjects with a hyperdivergent facial pattern ( $MPA \geq 25^\circ$ ) were retrieved from the archives of the University of Michigan Elementary and Secondary School Growth Study.<sup>18</sup> The sample consisted of 11 female and 10 male subjects. The average age at T1 was  $8.6 \pm 11$  months, and the average age at T2 was  $11.5 \pm 1.2$  years. Mean duration of the observation interval was  $3.0 \pm 1.1$  years. The control sample was well-matched to the treatment sample, consisting of 11 subjects with Class I occlusion and 10 subjects with Class II malocclusion. All subjects in both the treated and the control groups were at a prepubertal stage of skeletal maturity (CS1 or CS2) at T1.<sup>19</sup>

## Cephalometric Analysis

The pretreatment (T1) and posttreatment (T2) cephalograms were hand-traced by one investigator and then verified for landmark location by a second investigator. Any disagreements were resolved by retracing the landmark or structure to the satisfaction of both observers. Cephalometric software (Viewbox, version 3.0; dHAL Software, Kifissia, Greece) was used for a customized digitization regimen that included 78 landmarks and 4 fiducial markers. This program allowed for analysis of cephalometric data and superimposition among serial cephalograms according to the specific needs of the current study. Lateral cephalograms for each patient at T1 and T2 were digitized, and 50 variables<sup>10</sup> were generated for each film. The magnification factor of cephalograms was standardized at 8%.

## Statistical Analysis

The baseline values of the treated and control groups were compared by means of a nonparametric test for independent samples (Mann-Whitney *U*-test;  $P < .05$ ). No significant differences were found for any of the dental or skeletal variables, with the exception of a greater upward inclination of the palatal plane in relation to Frankfort horizontal ( $2.5^\circ$ ) and a smaller amount of overbite in the treated sample (1.9-mm difference). Because the two groups were well matched with regard to craniofacial features at T1, mean age at T1, skeletal maturity at T1, mean age at T2 and with regard to mean observation period, the T2–T1 changes were compared directly in the two groups by means of nonparametric tests.

The correction of the anterior open bite at the den-toalveolar level was considered clinically effective when the T2–T1 change in the overbite measurement produced a positive overlap of the incisors at the post-treatment observation. Because of the small sample size of the examined groups, changes in craniofacial dimensions were considered clinically significant if they were at least 1.5 mm or  $1.5^\circ$  in amplitude (statistical power of the study = 0.80 on the basis of the previously reported values of the changes for maxil-lomandibular vertical relationships<sup>10</sup>). The data were analyzed with Statistical Package for the Social Sciences software (Version 12.0; SPSS, Inc, Chicago, Ill).

## Method Error

The error of the method<sup>20</sup> was evaluated on 20 cephalograms that were retraced and remeasured after a 1-month interval. No systematic error was detected. The estimate of random errors was performed by means of Dahlberg's formula. The errors for linear measurements ranged from 0.1 mm for pogonion to

nasion perpendicular to 1.2 mm for condylion-gonion. The errors for angular measurements ranged from  $0.4^\circ$  for ANB to  $1.4^\circ$  for the interincisal angle.

## RESULTS

The results of the comparisons of the T2–T1 changes between treated and control groups are reported in Table 1.

### Skeletal Changes

No significant differences were found between the two groups for any of the measures in the sagittal plane (maxillary, mandibular, or maxillary/mandibular) from T1 to T2.

With respect to vertical measurements, the treated group exhibited a greater downward rotation of the palatal plane when compared to the control group ( $1.8^\circ$ ). This modification was associated with a significant reduction in the palatal plane/mandibular plane angle ( $-2.5^\circ$ ) in the Q-H/C group with respect to the controls.

### Dental Changes

At the end of the posttreatment period, the treated group showed a significantly greater increase in overbite (2.7 mm more than the control group), which was associated with a significantly greater opening of the interincisal angle ( $5.4^\circ$  more than the control group). Both the maxillary and mandibular incisors exhibited significantly greater extrusion (1.3 mm) in the Q-H/C group than in the control group.

### Soft Tissue Changes

The upper lip showed a significant tendency toward retraction relative to the E-plane in the treated group with respect to controls (3.6 mm).

## DISCUSSION

The purpose of the present investigation was to analyze the outcomes of Q-H/C therapy in growing subjects with dentoskeletal open bite and thumb-sucking habits and compared them a control group of untreated subjects with similar baseline vertical relationships. The observation interval included both the active treatment period (on average 17 months) and a posttreatment period (approximately 2 years without the use of any retention appliance in the majority of the patients). All treated subjects presented with thumb-sucking habits and increased vertical dimensions of the face before treatment. These two factors are known to be significantly associated with the presence of an anterior open bite in growing subjects.<sup>8</sup>

**Table 1.** Comparison of Changes from T1 to T2 (Active Treatment Followed by a 2-year Posttreatment Period)

Cephalometric Measures	Quad-Helix/Crib Treatment (n = 21)		Control Group (n = 21)		Difference	Significance <sup>a</sup>
	Mean	SD	Mean	SD		
<b>Maxillary skeletal</b>						
SNA (°)	0.1	2.0	-0.3	1.3	0.4	NS
PtA to NP (mm)	0.4	2.0	-0.3	1.3	0.7	NS
Co-Pt A (mm)	5.0	3.2	3.9	1.9	1.1	NS
<b>Mandibular skeletal</b>						
SNB (°)	0.5	1.4	0.2	1.2	0.3	NS
Pog to NP (mm)	1.9	3.6	0.3	2.1	1.6	NS
Co-Gn (mm)	8.2	3.5	6.4	2.4	1.8	NS
<b>Maxillary/mandibular</b>						
ANB (°)	-0.5	1.3	-0.5	0.9	0.0	NS
Wits (mm)	0.1	1.8	0.0	1.7	0.1	NS
Max/Mand difference (mm)	3.2	1.6	2.5	1.9	0.7	NS
<b>Vertical skeletal</b>						
FH to occlusal plane (°)	-1.1	2.8	-1.6	3.1	0.5	NS
FH to palatal plane (°)	0.8	1.7	-1.0	1.7	1.8	***
MPA (°)	-0.9	1.9	-0.3	1.5	-0.6	NS
PP to MP (°)	-1.8	2.2	0.7	2.8	-2.5	**
N-ANS (mm)	4.2	2.0	4.2	1.7	0.0	NS
ANS to Me (mm)	3.6	2.4	2.5	2.0	1.1	NS
N-Me (mm)	7.5	3.4	6.8	3.2	0.7	NS
Co-Go (mm)	3.6	2.2	2.8	2.5	0.8	NS
Gonial angle (°)	-1.3	1.7	-1.4	2.1	0.1	NS
<b>Interdental</b>						
Overjet (mm)	-1.4	2.3	0.0	1.1	-1.4	NS
Overbite (mm)	4.1	2.1	1.4	2.3	2.7	***
Interincisal angle (°)	6.8	7.7	1.4	5.8	5.4	*
Molar relationship (mm)	0.7	1.6	0.4	1.1	0.3	NS
<b>Maxillary dentoalveolar</b>						
U1 to Pt A vert (mm)	-0.2	1.5	0.8	1.2	-1.0	NS
U1 to FH (°)	-5.0	6.0	-1.6	3.8	-3.4	NS
U1 horizontal (mm)	1.4	2.5	0.6	1.4	0.8	NS
U1 vertical (mm)	3.3	1.5	2.0	1.8	1.3	*
U6 horizontal (mm)	1.8	1.7	0.8	1.6	1.0	NS
U6 vertical (mm)	1.8	1.6	0.7	1.9	1.1	NS
<b>Mandibular dentoalveolar</b>						
L1 to Pt A-Pg (mm)	-0.2	1.5	0.6	1.3	-0.8	NS
L1 to MPA (°)	-0.9	4.8	0.5	3.2	-1.4	NS
L1 horizontal (mm)	0.4	1.2	0.7	1.3	-0.3	NS
L1 vertical (mm)	3.4	1.3	2.1	1.2	1.3	**
L6 horizontal (mm)	0.9	1.4	1.5	1.2	-0.6	NS
L6 vertical (mm)	2.7	1.4	1.8	1.5	0.9	NS
<b>Soft tissue</b>						
UL to E-plane (mm)	1.6	1.5	-2.0	1.5	3.6	***
LL to E-plane (mm)	1.6	4.8	-0.4	1.5	2.0	NS
Nasolabial angle (°)	-0.2	7.9	4.1	6.8	-4.3	NS

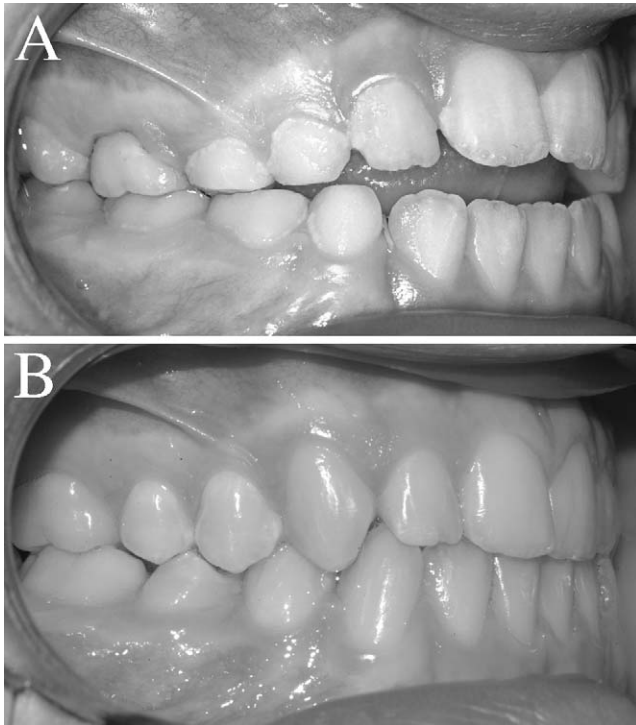
<sup>a</sup> \*  $P < .05$ ; \*\*  $P < .01$ ; \*\*\*  $P < .001$ ; NS, not significant.

A previous short-term study<sup>10</sup> had indicated that all subjects treated with the Q-H/C protocol ceased the thumb-sucking habit. No patient resumed thumb-sucking habits during the posttreatment period.

The initial amount of negative overbite (a measure

of anterior dentoalveolar open bite) was a mean of -2.4 mm in the treated group. The average increase in overbite at the end of the posttreatment period after active Q-H/C therapy (4.1 mm) corrected the pretreatment amount of anterior open bite (Figure 2). This in-





**Figure 2.** Anterior open bite correction in a girl with mixed dentition. (A) At 8 years, 10 months of age, prior to treatment. (B) At 12 years, 8 months of age, at an observation 2 years and 3 months after the end of active treatment (no retention appliance).

crease in overbite showed stability with regard to the value at the end of active therapy as reported previously (4.4 mm).<sup>10</sup> The analysis of individual data revealed that 3 of the 21 subjects did not show a positive overbite at the end of the posttreatment interval. Therefore, the present study assessed clinical effectiveness for the treatment protocol in approximately 85% of patients with dentoalveolar open bite at an observation performed 2 years after the end of active treatment. A statistically significant extrusion of 1.3 mm of both the maxillary and mandibular incisors contributed to the stable correction of overbite.

The Q-H/C therapy produced a clinically significant  $1.8^\circ$  posterior rotation of the palatal plane. The untreated control subjects showed a tendency to upward rotation of the palatal plane vs Frankfort horizontal plane ( $1.0^\circ$ ). As a result, the maxillomandibular divergence, as measured by the angle between the palatal plane and the mandibular plane, exhibited a clinically significant improvement of  $2.5^\circ$  in the treated sample, a value greater than that reported at the end of active Q-H/C treatment ( $1.7^\circ$ ).<sup>10</sup> This favorable outcome deserves to be emphasized because of its clinical impact on dentoskeletal open bite, because it contributes significantly to the overall correction of anterior open bite.

The lingual tipping of the incisors (though not statistically significant) was associated with a mean of 3.6

mm of retrusion of the upper lip to the E-plane. The favorable downward rotation of the palatal plane probably assisted in the significant change of the soft tissue profile of the upper lip.

Previous cephalometric and clinical studies demonstrated the effectiveness of crib wear for the closure of anterior open bite in short-term investigations.<sup>12,13,15,16</sup> The present study of Q-H/C therapy observed good stability for the correction of anterior open bite in conjunction with the permanent elimination of thumb-sucking habits. In addition, a significant continued improvement of vertical relationships was detected in the posttreatment period.

## CONCLUSIONS

- a. The treatment and posttreatment effects of a Q-H/C appliance showed a clinical effectiveness in correcting the dental open bite of 85%.
- b. A clinically significant improvement ( $2.5^\circ$ ) in maxillomandibular vertical skeletal relationships was observed.

## REFERENCES

1. Proffit WR. The development of vertical dentofacial problems: concepts from recent human studies. In: McNamara JA Jr, ed. *The Enigma of the Vertical Dimension*. Craniofacial Growth Series, vol. 36. Ann Arbor, Mich: Center for Human Growth and Development, The University of Michigan; 2000:1–20.
2. Proffit WR, Bailey LJ, Phillips C, Turvey TA. Long-term stability of surgical open-bite correction by LeFort I osteotomy. *Angle Orthod*. 2000;70:112–117.
3. Buschang P, Sankey W, English JD. Early treatment of hyperdivergent open-bite malocclusions. *Semin Orthod*. 2002; 8:130–40.
4. Graber TM, Rakosi T, Petrovic A. *Dentofacial Orthopedics with Functional Appliances*. St Louis: Mosby; 1997:81–91.
5. Parker JH. The interception of the open bite in the early growth period. *Angle Orthod*. 1971;41:24–44.
6. Hanson ML. Oral myofunctional therapy. *Am J Orthod*. 1978;73:59–67.
7. McNamara JA, Jr, Brudon WL. *Orthodontics and Dentofacial Orthopedics*. Ann Arbor, Mich: Needham Press; 2001: 113–115.
8. Cozza P, Baccetti T, Franchi L, Mucedero M, Polimeni A. Sucking habits and facial hyperdivergency as risk factors for anterior open bite in the mixed dentition. *Am J Orthod Dentofac Orthop*. 2005;128:517–519.
9. Cozza P, Giancotti A, Rosignoli L. Use of a modified quad helix in early interceptive treatment. *J Clin Orthod*. 2000;34: 473–476.
10. Cozza P, Baccetti T, Franchi L, McNamara JA Jr. Treatment effects of a modified quad-helix in patients with dentoskeletal open bites. *Am J Orthod Dentofac Orthop*. 2006;129: 734–739.
11. Cozza P, Baccetti T, Franchi L, Mucedero M. Comparison of two early treatment protocols for open bite malocclusions. *Am J Orthod Dentofac Orthop*. In press.
12. Haryett RD, Hansen FC, Davidson PO, Sandilands ML. Chronic thumb-sucking: the psychological effects and the rel-

- ative effectiveness of various methods of treatment. *Am J Orthod.* 1967;53:569–585.
13. Huang GJ, Justus R, Kennedy DB, Kokich VG. Stability of anterior open bite treated with crib therapy. *Angle Orthod.* 1990;60:17–24.
  14. Villa NL, Cisneros GJ. Changes in the dentition secondary to palatal crib therapy in digit-suckers: a preliminary study. *Pediatr Dent.* 1997;19:323–326.
  15. Haryett RD, Hansen FC, Davidson PO. Chronic thumb-sucking: a second report on treatment and its psychologic effects. *Am J Orthod.* 1970;57:164–178.
  16. Justus R. Treatment of anterior open bite: a cephalometric and clinical study [in Spanish]. *ADM.* 1976;33:17–40.
  17. Subtelny JD, Sakuda M. Open bite: diagnosis and treatment. *Am J Orthod.* 1964;50:37–58.
  18. Riolo ML, Moyers RE, McNamara JA Jr, Hunter WS. *An Atlas of Craniofacial Growth: Cephalometric Standards from The University School Growth Study, The University of Michigan.* Craniofacial Growth Series, vol. 2. Ann Arbor, Mich: Center for Human Growth and Development, The University of Michigan; 1974.
  19. Baccetti T, Franchi L, McNamara JA Jr. The cervical vertebral maturation (CVM) method for the assessment of optimal treatment timing in dentofacial orthopedics. *Semin Orthod.* 2005;11:119–129.
  20. Houston WJ. The analysis of errors in orthodontic measurements. *Am J Orthod.* 1983;83:382–390.