

Case Report

Experiencing your own orthognathic surgery:

A personal case report

Gertjan Mensink^a; Peter Gooris^b; Florine Mulder^c; Christel Gooris-Kuipers^d;
Richard van Merkesteyn^e

ABSTRACT

There has been much research on minimizing the side effects of orthognathic surgery. However, there are very few doctors and researchers who themselves have undergone this surgery. This case report describes the findings of a maxillofacial surgeon who underwent combined orthodontic and orthognathic treatment for correction of Class II malocclusion. In March 2012, the surgeon was referred to an orthodontist, and an orthodontic examination revealed a Class II, division 2, malocclusion with a traumatic palatal bite and attrition of the lower front teeth. The patient underwent alignment of the upper and lower arches, followed by a bilateral sagittal split osteotomy. During this treatment, he made many interesting observations and learned much as a patient, which can have implications in improving the outcomes and quality of care for patients receiving such treatment. Thus, this case report aims to provide a critical perspective of the surgical procedure and treatment from the viewpoint of a maxillofacial surgeon who himself experienced the surgery as a patient. (*Angle Orthod.* 2015;85:890–896.)

KEY WORDS: Bilateral sagittal split osteotomy; Doctor-patients; Orthognathic surgery

INTRODUCTION

Orthognathic surgery is a routine procedure performed by many surgeons to correct malocclusions, with predictable results. Clinicians and researchers

^a Consultant in Maxillofacial Surgery, Department of Oral and Maxillofacial Surgery, Amphia Hospital, Breda, The Netherlands, and Senior Researcher, Department of Oral and Maxillofacial Surgery, Leiden University Medical Centre, Leiden, The Netherlands.

^b Consultant in Maxillofacial Surgery, Department of Oral and Maxillofacial Surgery, Amphia Hospital, Breda, The Netherlands; Consultant in Maxillofacial Surgery, Department of Oral and Maxillofacial Surgery, Amsterdam Medical Centre, Amsterdam, The Netherlands; and Affiliate Professor, Department of Oral and Maxillofacial Surgery, University of Washington, Seattle, Wash.

^c Private practice, Tandheelkundig Centrum Dudok, Breda, The Netherlands.

^d Private practice, Orthodontiepraktijk Gooris, Breda, The Netherlands.

^e Professor, Department of Oral and Maxillofacial Surgery, Leiden University Medical Centre, Leiden, The Netherlands.

Corresponding author: Dr Gertjan Mensink, Department of Oral and Maxillofacial Surgery, Amphia Hospital, Molengracht 21, Postbus 90158, 4800 RK, Breda, The Netherlands (e-mail: GMensink1@amphia.nl)

Accepted: September 2014. Submitted: June 2014.

Published Online: November 4, 2014

© 2015 by The EH Angle Education and Research Foundation, Inc.

have sought to minimize unwanted side effects during such an elective procedure.¹ However, very few of these doctors and researchers have undergone the surgical procedure themselves. Presently, many doctors report their own personal experiences.^{2,3} Such reports reveal what we fail to tell our patients and what they fail to tell us.²

This case report aims to describe the findings of a maxillofacial surgeon whose Class II malocclusion was corrected by a surgical-orthodontic procedure. We sought to provide a critical perspective to improve treatment outcomes and the quality of patient care.

CASE REPORT

History

At the age of 12 years, I underwent orthodontic treatment for about 2.5 years. The treatment involved activator and bracket treatment. However, stable results were not achieved. Eight years ago, a dental practitioner referred me because of Class II malocclusion with a traumatic palatal bite. In March 2012, I eventually visited the orthodontist. At that point, my symptoms had worsened: (1) progressive attrition of the lower front teeth, (2) progressive crowding of the upper front teeth, and (3) recurrent traumatization of the palatal gingiva by the lower front teeth with minor

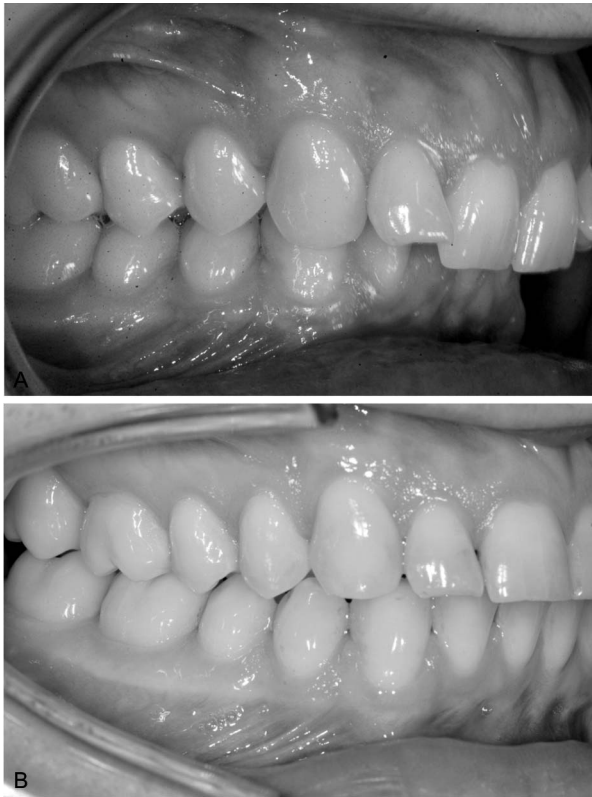

Figure 1. (A) Class II malocclusion with retruded incisors and deep palatal bite. (B) Class I occlusion 1 year after surgery.

complaints of discomfort or pain. Furthermore, there was a history of bruxism and clenching, which was subsequently treated using a night guard splint.

The clinical orthodontic examination revealed a retruded mandibular profile with a deep mental fold in combination with eversion of the lower lip. The positions of the maxilla and upper lip were normal. Lower vertical facial height was reduced. The intraoral examination revealed a Class II, division 2, malocclusion (3/4 pb) with a traumatic palatal bite and attrition of the lower front teeth with an overjet of 6 mm. No other dental pathology was found (Figure 1A). The wisdom teeth had been removed >7 years earlier.

Assessment

Radiologic examination of the lateral cephalogram confirmed the clinical diagnosis of a Class II, division 2, malocclusion. The cephalometric measurements are summarized in Table 1. The orthopantomogram revealed no dental pathology (Figures 2A and 3A).

Treatment

The proposed treatment plan consisted in aligning the upper and lower arches, followed by a bilateral sagittal split osteotomy (BSSO). Because of the proper

Table 1. Cephalometric Measurements

	Preoperative	Postoperative (12 Months)
Sagittal		
SNA	90	89
SNB	82	84
ANB	7	5
Vertical		
SPPL-MPL	12	15
Ans-Me	53	57
Dental		
+1/NA, mm	0	3
+1/NA, <	10	32
-1/NB, mm	2	6
-1/NB, <	25	35
-1/MPL	110	116
Wits	6	5
+1/-1	138	108

horizontal position of the chin in combination with the shortened vertical facial height, special care was taken to preserve the curve of Spee, to allow for more clockwise rotation of the mandible during the surgery (Figures 2, 4–6).

Treatment was started in April 2012. The orthodontic phase of the treatment used self-ligating brackets (In-Ovation, TP Orthodontics, Inc, La Porte, Ind). After 11 months of decompensation through alignment of the upper and lower arches, the upper front teeth were intruded and proclined, and the curve of Spee in the mandible had been preserved. I was deemed ready for surgery (Figure 4). I recorded observations of damage to the cheeks and tongue as well as a dry lower lip, which resolved 1 to 2 weeks after each wire change, in the diary that I kept during my orthodontic treatment. A cone-beam computed tomography was performed to visualize the anatomical position of the inferior alveolar nerve and for three-dimensional planning of the BSSO (Simplant O&O, Leuven, Belgium; Figure 5). The images showed a preserved deep bite, with an overjet and overbite and proper clockwise rotation of the mandible. A final wafer was manufactured.

On March 12, 2013, I underwent BSSO, which was performed according to the modified method of Hunsuck, except for use of chisels. Instead of chisels, splitting forceps (curved Smith Ramus separators; Walter Lorentz Surgical, Jacksonville, Fla) and elevators were used, as described previously.⁴ After mobilization, the mandible was positioned correctly for the new intermaxillary relationship using a wafer, and intermaxillary wires were affixed. A stab incision was made through the skin; using a trans-buccal retractor, three 2-mm bicortical titanium screws (9, 11, and 13 mm in length; Martin GmbH, Tuttlingen, Germany) were placed bilaterally at the upper border of the mandible. The temporary intermaxillary fixation

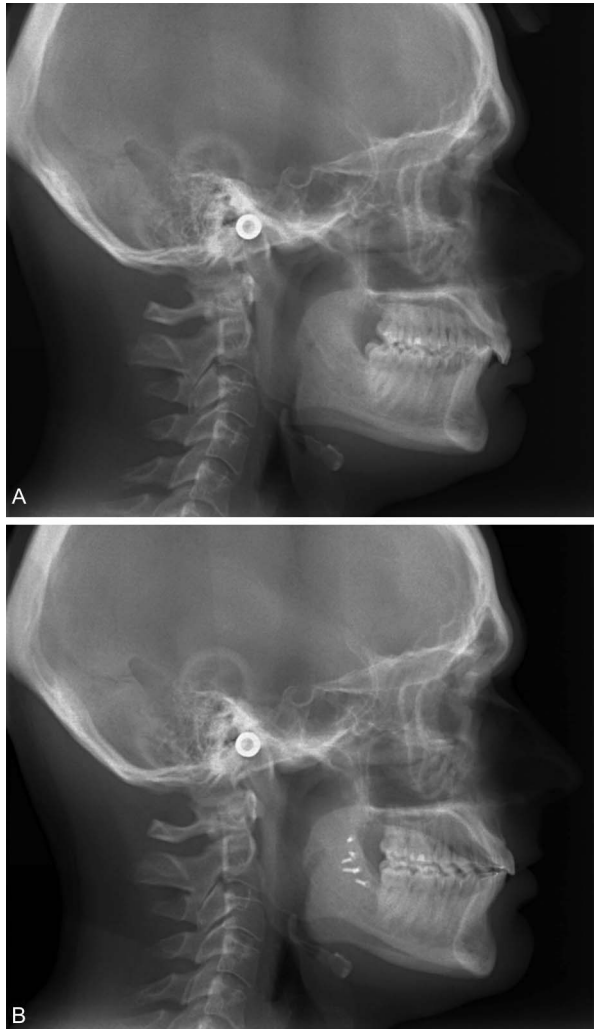


Figure 2. (A) Preoperative lateral cephalogram confirming the retrognathic mandible with a deep bite and a corresponding deep mental fold. (B) Postoperative lateral cephalogram 1 year after surgery. Neutral relationship with a Class I occlusion and adequate overjet and overbite. The fixation screws used are still in place.

was removed, and the occlusion was checked. Elastic bands were not used immediately postoperatively. The postoperative pain protocol prescribed paracetamol, naproxen, and methadone (intramuscularly) if necessary.

RESULTS

After undergoing a 2-hour surgery, I was moved to the recovery room. My discomfort taught me that a patient cannot be expected to comprehend important instructions given during the immediate postoperative period. The first day after surgery was largely unremarkable; I was able to eat soft food and drink cold beverages. Drinking alleviated the xerostomia that resulted from not being able to close my mouth properly. My pain was effectively managed with analgesic oral medication.

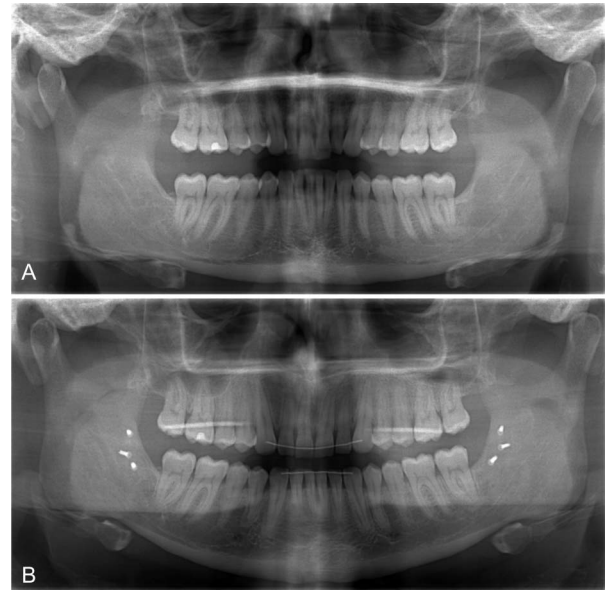


Figure 3. (A) Preoperative orthopantomogram. No pathology is visible. (B) Postoperative orthopantomogram 1 year after surgery. Fixation screws still in place. The joints retain a normal aspect.

Quantitative sensory (pinprick) testing revealed only a small area of hypoesthesia (Figure 7) at the right corner of the mouth on day 2.

Swelling developed within 48 hours (Figure 8). Occlusion was not possible because of the interpositioning of the cheek on both sides. I experienced an unpleasant pressure-like feeling on the joint. Despite my experience as an orthognathic surgeon, the awkwardness of a mandible fixed by six screws gave

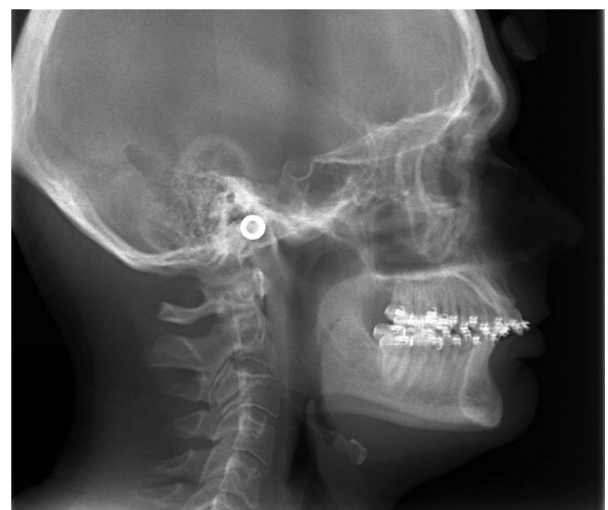

Figure 4. Orthodontic preparation for surgery. The mental fold deepened because of the increased anterior inclination of the upper teeth. The curve of Spee was maintained to promote clockwise rotation of the mandible, to increase vertical dimension, and to minimize horizontal positioning of the chin.

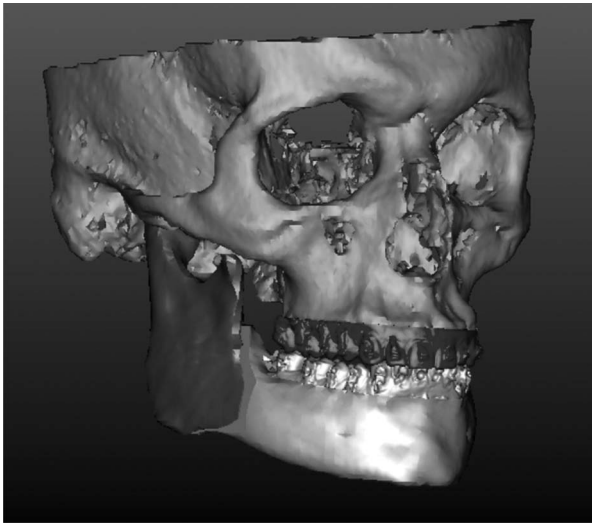


Figure 5. Simplant three-dimensional planning. Clockwise rotation of the mandible is apparent in the difference between the proximal and distal segments (see also Figure 6). Adequate frontal contact, with an open bite in the premolar region due to preservation of the curve of Spee, to enhance clockwise rotation.

me new insight into the patient’s postoperative experience.

After 2 days, I was discharged. I achieved full cognitive capability rapidly, but physical recovery took

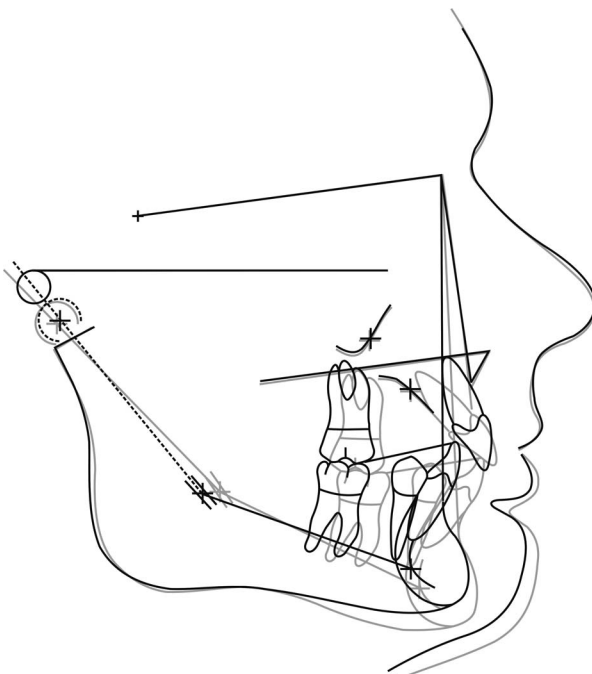


Figure 6. Superpositioning of the pre- and postoperative tracing of the lateral cephalogram. Black line, preoperative; red line, 12 months postoperative. Class I occlusion is achieved by advancing the mandible. Vertical face height is lengthened by clockwise rotation of the mandible with a slight decrease in depth of the mental fold. Note the increased proclination of the upper incisor due to correction by orthodontic treatment.

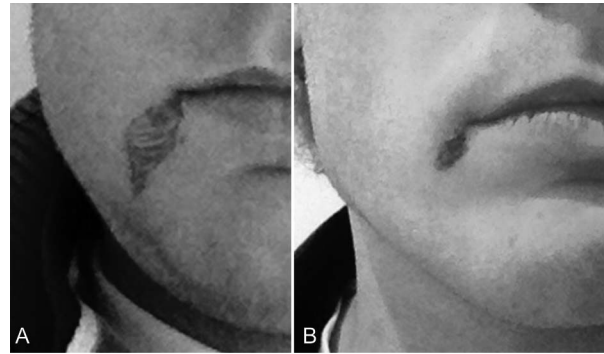


Figure 7. Area of numbness at the right corner of the mouth (marked in blue). (A) Six days after surgery, swelling and yellow bruising can be seen. (B) Eight months after surgery, minor numbness persists.

longer. I also found loud noises particularly bothersome. After 4 days, my face started to turn yellow. I was able to perform limited dental hygiene procedures as the facial swelling decreased slowly. The inside of the cheek was numb. Occlusion was not possible despite contact with the front teeth. Normal occlusion was not possible throughout the first week, likely because of mild edema in the temporomandibular joint (TMJ).

After 9 days, analgesic medication was no longer necessary. After 12 days, I experienced pain at my left TMJ that prevented me from having an uninterrupted sleep. Oral fluid intake was adequate; after 1 week, I started on a soft diet. I resumed work, treating my own patients 20 days after surgery.

One month after surgery, I still experienced some numbness at the right corner of the mouth (Figure 7). The insides of my cheeks felt different, as if they had been touched by cotton wool. The buccal gingiva at the level of the first and second molars felt numb as well. The chin projection (in horizontal and vertical height) had resulted as planned. The lower lip was “unfolding,” resulting in reduced depth of the mental fold (Figure 8).

I continued to awake with TMJ sensitivity while sleeping. After 2 months, the numbness of the gingiva had resolved completely, but numbness persisted at




Figure 8. Photos taken (A) preoperatively, (B) 4 days postoperatively, and (C) 12 months postoperatively.

the buccal mucosa. The occlusion still felt awkward. After 3 months, more balanced occlusion evolved. As a result, there was less pain at the left TMJ, despite some clicking. During the last 3 months of the orthodontic phase, a solid Class I occlusion was achieved. The partial paresthesia of the corner of the mouth persisted up to this point (Figure 7). This sensitivity disturbance is occasional and noted only when I touch the corner of my mouth. However, when drinking cold beverages, I sometimes experience a sensation like fluid running along the right corner of my mouth.

The duration of the postoperative orthodontic treatment was 6 months. Debonding of the orthodontic appliance and insertion of the frontal retainers were performed during a single session. Directly after debonding and removal of the appliance, the settling was felt as a change in occlusion due to minimal tooth movement. Although the tongue was initially injured on the dental lingual and palatal retainers, it had adapted to the new hardware after 7 days. Clicking of the left joint persisted.

Six weeks after removal of the brackets, further settling resulted in successful interdigitation of the left molars and frontal region, with the premolars erupting reaching an improved occlusion. There was moderate settling on the right side, although this had not yet resulted in occlusion. Eight weeks after debonding (8 months postsurgery), the clicking at the left joint had nearly resolved. Nine months after surgery, clicking at the left joint had ceased. One year after surgery, I achieved full occlusion and normal function.

DISCUSSION

My greatest concerns prior to the operation were anesthesia or hypoesthesia of the lower lip as well as the postoperative position of the chin. I consider the surgery to have been successful, despite some minor numbness at the right corner of my mouth. Previous studies have shown that about half of patients experience side effects (such as numbness, painful teeth, or pain in the TMJ), but nearly all patients felt that they have benefited from their treatment.⁵ This finding also supports reports that subjective symptoms are less than objective measurements of hypoesthesia, most likely due to patient habituation.⁴

Patients find it very helpful to receive information on their treatment and outcomes. This helps to reduce concerns as mentioned above. Information leaflets, pictures of treated patients, or meeting other patients are mentioned in questionnaires as being helpful for almost all patients.⁶

In my case, treatment was delayed because of my lack of concern for the esthetic impact of my malocclusion/hypoplasia and only minor complaints. I

noticed a functional impairment with continuous attrition of the lower frontal teeth. I was mildly concerned about the unfavorable palatal bite and the progressive crowding of my upper front teeth. This is in line with a previous report in which patients who underwent orthognathic surgical evaluation for treatment of a skeletal deformity experienced a primary complaint that was more functional than esthetic in nature.⁷ However, other reports describe straight teeth/dentofacial attractiveness as the most common reason for seeking treatment, followed by prevention of future dental problems (as seen from continuous attrition of my lower teeth).^{6,8} However, patients treated in these studies had a mean age of 22–24 years, which could explain this esthetic difference with my case, as younger patients are more insecure about the appearance of their teeth. While my treatment started when I was 34 years old, the malocclusion was present long before. The results of the surgery highlight the importance of early diagnosis; delaying treatment increases the risk of complications such as neurosensory disturbances.⁴

My primary complaints during the orthodontics phase were minor damage to the buccal mucosa of the cheek, lips, and tongue caused by the brackets. However, hyperplasia of the mucosa allowed the tissue to adapt to the brackets and wires after 2–3 weeks. This adaptation process occurred after every orthodontic visit and took 2–3 days. During this period, I routinely switched to a soft diet due to increased sensitivity of the teeth during loading. Notably, published reports identify certain side effects associated with fixed orthodontic treatment: toothache, ulceration, and soreness. Similar to my experience, patients reported difficulty with eating and/or chewing during the early postoperative period.^{9,9}

My experience with the self-ligating brackets was good. Without the banding elastics, one does not encounter elastic discoloration. Changing the wires proceeded more easily as well. The self-ligating system also involves reduced chair time.¹⁰

The main complaints reported during orthognathic surgery are postsurgery sequelae such as nausea or swelling, discomfort/pain, delayed recovery of oral function, and a slow return to presurgical lifestyle and activity levels. The reported findings are in line with the observations about my own postoperative discomfort, except for breathing difficulties.^{5,11} Swelling and bruising resolved in about 1–2 weeks. Proper pain management with naproxen (for 1 week) and paracetamol (not as needed, but rather on a regular schedule according to the postoperative pain protocol) protected me from pain during the daytime. Problems associated with eating, chewing, and opening of the mouth took the longest to resolve—approximately 6–8 weeks. It is

Table 2. Post- and Preoperative Advice for Patients and Surgeons/Orthodontists

Preoperative advice for surgeons/orthodontists

Explain why it is sometimes difficult to predict the exact duration of orthodontic treatment (ie, small movement of teeth takes another one to two sessions and could mean elongation up to 1–3 months), especially after the healing period of the surgical correction.

Address the concerns of the patients.

Match your expectations with those of the patients'.

Postoperative explanations for patients

Occlusion will not be directly perfect after surgery; therefore, orthodontic treatment is still necessary.

After debonding, the occlusion might cause some feeling of discomfort because of the discrepancy between the moment of debonding and the settling phase.

Numbness resolves very slowly and is accompanied by a tingling sensation. Moreover, the numbness in all parts will not resolve at the same time.

Have a regular schedule of taking pain medications for at least 1 week; do not wait until you feel the pain.

At the beginning of the treatment, one will experience some pain/sensitive feeling/clicking of the joints/muscles.

General anesthesia can cause some physical/cognitive discomfort.

About 2–3 weeks' leave from work is sufficient after undergoing a bilateral sagittal split osteotomy.

Postoperative visits to the orthodontists/surgeons are important in case elastic traction is necessary.

Postoperative advice for surgeons/orthodontists

A patient might not be able to fully comprehend postoperative instructions in the recovery room.

Listen to complaints from the patients, however trivial or small they may sound to you.

Review the concerns of a patient during postoperative discussion.

interesting that many patients, despite being informed about these postoperative sequelae, are surprised by the severity and duration of their postoperative symptoms. This could also be biased since patients having sequelae often avoid criticizing their doctors.⁸ I returned to work 2–3 weeks after the surgical procedure; this time period for resuming work was similar to that reported previously.^{5,11} However, patients generally need to take more time off than advised before.⁵

I experienced moderate pain of the left TMJ, most likely due to clenching at night. The clicking of my left joint did not resolve until 7 months after the surgery, most likely due to a lack of proper stabilized occlusion on the left side during the first 6 weeks after surgery. During this healing period, my left TMJ was probably overloaded because of my clenching habit. After establishing stable occlusion on the left side after starting the orthodontic phase again, both TMJs were loaded in a stable functional way, which finally resulted in complete resolution of the crano-mandibular dysfunction at my left TMJ.

Condylar bone changes and disk displacements after orthognathic surgery are related to parafunctional habits such as bruxism and clenching.¹² Frey et al.¹³ showed that long advancements (>7 mm) and clockwise rotation were associated with increased joint sounds, but no independent association was found. Furthermore, when joint sounds occurred, these declined over the 2-year follow-up period. Thus, increased joint symptoms after surgery might be clinically significant only in the short term.¹³

The General Medical Council guidelines recommend avoiding wherever possible the provision of medical

care to anyone with whom the doctor/surgeon has a close personal relationship.¹⁴ However, this is quite difficult if you participate in a small group of specialists such as the community of maxillofacial surgeons in the Netherlands. Having many recall appointments during the orthodontic treatment period makes it difficult to be treated by someone with whom you are not familiar. However, I believe it could have been more difficult for the surgeon and orthodontist treating me than for me as the patient. As requested, I was treated like other patients but with some extra privileges.

This experience as a patient was illuminating to me as a specialist. Klitzman,¹⁵ in his study on health care among doctors, observed that as a patient, the doctors learned much more than they knew before (Table 2). Several doctor-patient participants in Klitzman's study suggest that doctors must remain familiar with "helplessness, loss of power over one's very body and life, confusion and confrontation with the unknown."¹⁵ In addition to achieving a normal Class I occlusion without further damage to my teeth, this experience taught me a great lesson with regard to understanding and empathizing with patients. As surgeons, we should keep in mind that orthognathic surgery should never be "business as usual" and in this regard treat every patient not only as being a different individual with a unique harmonization of dental, bony, and soft tissue but also especially as someone with doubts, fears, and uncertainty. We should supply these patients with the proper information so they are able to understand the underlying dental/skeletal abnormality and the treatment necessary to correct these deviations.

The final question I have received over and over again, "Would you do it again?" is peculiar in my

opinion. If you treat your orthognathic cases with the knowledge we have, I believe it would be worthy each time you operate a patient.

ACKNOWLEDGMENTS

I would like to thank my colleagues who helped during my treatment, the nursing staff during my hospitalization, my colleagues at the operating room, and the staff at the orthodontic practice. Furthermore, I would like to thank L. Fabels, MSc, for his work in superimpositioning the radiographic examinations.

REFERENCES

1. Mensink G, Verweij JP, Frank MD, Eelco BJ, Richard van Merkesteyn JP. Bad split during bilateral sagittal split osteotomy of the mandible with separators: a retrospective study of 427 patients. *Br J Oral Maxillofac Surg.* 2013;51:525–529.
2. Murphy TC. The diary of an orthognathic patient aged 30 3/4. *J Orthod.* 2005;32:169–174.
3. Brook I. A physician's experience as a cancer of the neck patient. *Surg Oncol.* 2010;19:188–192.
4. Mensink G, Zweers A, Wolterbeek R, Dicker GG, Groot RH, van Merkesteyn RJ. Neurosensory disturbances one year after bilateral sagittal split osteotomy of the mandibula performed with separators: a multi-center prospective study. *J Craniomaxillofac Surg.* 2012;40:763–767.
5. Williams RW, Travess HC, Williams AC. Patients' experiences after undergoing orthognathic surgery at NHS hospitals in the south west of England. *Br J Oral Maxillofac Surg.* 2004;42:419–431.
6. Williams AC, Shah H, Sandy JR, Travess HC. Patients' motivations for treatment and their experiences of orthodontic preparation for orthognathic surgery. *J Orthod.* 2005;32:191–202.
7. Proothi M, Drew SJ, Sachs SA. Motivating factors for patients undergoing orthognathic surgery evaluation. *J Oral Maxillofac Surg.* 2010;68:1555–1559.
8. Johnston C, Hunt O, Burden D, Stevenson M, Hepper P. Self-perception of dentofacial attractiveness among patients requiring orthognathic surgery. *Angle Orthod.* 2010;80:361–366.
9. Johal A, Abed Al JF, Marcenes W, Croft N. Does orthodontic treatment harm children's diets? *J Dent.* 2013;41:949–954.
10. Chen SS, Greenlee GM, Kim JE, Smith CL, Huang GJ. Systematic review of self-ligating brackets. *Am J Orthod Dentofacial Orthop.* 2010;137:726.e1–726.e18.
11. Phillips C, Blakey G III, Jaskolka M. Recovery after orthognathic surgery: short-term health-related quality of life outcomes. *J Oral Maxillofac Surg.* 2008;66:2110–2115.
12. Yamada K, Hanada K, Fukui T, et al. Condylar bony change and self-reported parafunctional habits in prospective orthognathic surgery patients with temporomandibular disorders. *Oral Surg Oral Med Oral Pathol Oral Radiol Endod.* 2001;92:265–271.
13. Frey DR, Hatch JP, Van Sickels JE, Dolce C, Rugh JD. Effects of surgical mandibular advancement and rotation on signs and symptoms of temporomandibular disorder: a 2-year follow-up study. *Am J Orthod Dentofacial Orthop.* 2008;133:490–498.
14. General Medical Council, Good Medical Practice, Treating Family Members, Available at: <http://www.gmc-uk.org/guidance/10247.asp>. Published March 25, 2013. Accessed April 25, 2013.
15. Klitzman R. Improving education on doctor-patient relationships and communication: lessons from doctors who become patients. *Acad Med.* 2006;81:447–453.