

# IMMEDIATE OCCLUSAL LOADING THE SAME DAY OR THE DAY AFTER IMPLANT PLACEMENT: COMPARISON OF 2 DIFFERENT TIME FRAMES IN TOTALLY EDENTULOUS LOWER JAWS

*Tiziano Testori, MD, DDS*  
*Massimo Del Fabbro, PhD*  
*Fabio Galli, MD, DDS*  
*Luca Francetti, MD, DDS*  
*Silvio Taschieri, MD, DDS*  
*Roberto Weinstein, MD, DDS*

## KEY WORDS

**Endosseous implants**  
**Dental implants**  
**Rough surfaces**  
**Immediate loading**  
**Edentulous mandible**

*Tiziano Testori, MD, DDS, is head of the Section of Implant Dentistry and Oral Rehabilitation; Massimo Del Fabbro, PhD, is a researcher and head of the Section of Oral Physiology; Fabio Galli, MD, DDS, is with the Section of Oral Implant Dentistry and Oral Rehabilitation; Silvio Taschieri, MD, DDS, is head of the Section of Endodontics; Luca Francetti, MD, DDS, is a researcher and head of the Section of Periodontology; and Roberto Weinstein, MD, DDS, is a full professor and chairman of the Department of Odontology, Galeazzi Institute, University of Milan, Milan, Italy.*

*Address correspondence to Dr Testori at the Department of Odontology, Galeazzi Institute, University of Milan, Via R. Galeazzi 4, 20161 Milan, Italy (e-mail: tiziano.testori@tin.it).*

Immediate loading of endosseous implants is becoming a widespread therapeutic procedure for the rehabilitation of patients with edentulous jaws. The purpose of this prospective clinical trial was to evaluate the long-term success rate of endosseous implants placed in the edentulous lower jaw and loaded on either the same day of surgery or the next day. Nineteen patients were enrolled in the study. Eleven patients, accounting for 64 implants, received their provisional prosthesis the same day of implant placement, and 8 patients, accounting for 52 implants, were rehabilitated the day after surgery. All patients were rehabilitated by a hybrid prosthesis supported by 5 to 6 Osseotite implants. Two implants failed in the group of patients who had their implants loaded the same day (96.9% success rate), whereas 1 implant failed in the other group (98.1% success rate). The overall implant success rate was 97.4%. All failures occurred within 2 months of function. No other complication was reported. The mean follow-up for this interim report was  $37.8 \pm 16.5$  months (range 8–65 months). Crestal bone loss was similar to that reported for standard delayed loading protocols. The results of this study suggest that the rehabilitation of the edentulous lower jaw by an immediate occlusally loaded implant-supported hybrid prosthesis is equally successful when loading is applied the same day or the day after implant placement. Immediate loading with 5 to 6 implant-supported prostheses represents a viable alternative treatment to classic delayed loading protocols.

## INTRODUCTION

**A**n adequate non-functional healing period has long been considered one of the basic prerequisites to achieve osseointegration of dental implants; such period was equal to 3 months for the mandible and 6 months for the upper jaw because of a different osseous structure.<sup>1,2</sup> The actual need for healing periods of such duration has been greatly questioned because they were determined on an empirical basis. Hence, one of the aims of clinical research in modern implant dentistry has been the validation of early and immediate loading protocols as viable therapeutic alternatives, under certain circumstances. Numerous studies have been carried out regarding the physiologic principles that govern on aspects of implant healing and long-term function.<sup>3-8</sup> Experimental studies in animal models have also been performed<sup>9-11</sup> to assess osseointegration around implants loaded earlier with respect to the standard protocol. However, in experimental animal models (such as dogs and monkeys) bone biology is similar to that of humans as long as the sequence of events is concerned, but time lapses can be significantly different, so not all the data regarding healing times could be transposed to clinical practice. Yet the encouraging results obtained with animals led to a growing number of clinical studies on immediate loading of dental implants in humans.<sup>12-24</sup>

Immediate loading procedures have been applied to rehabilitate the edentulous mandible with high predictability. In the totally edentulous jaws, cross-arch stabilization has been proven to be efficient in maintaining the

amount of micromotion below a certain threshold, namely, 150  $\mu\text{m}$ , which was considered critical to osseointegration.<sup>25</sup>

The ultimate goal of an immediate loading protocol is to reduce the number of surgical interventions and shorten the time frame between surgery and prosthesis delivery, all without compromising the success rate of the procedure. These new protocols will ultimately lessen patients' reservations, resulting in increased acceptance of implant therapy. Before accepting the procedure as a routine treatment, the immediate loading technique needs to be validated by a significant number of clinical cases, extended follow-ups, and a clear definition of limitations.

This article presents an interim analysis of a prospective clinical study on the rehabilitation of the edentulous mandible by an immediate occlusally loaded (IL) full-arch screw-retained prosthesis with distal extensions (a hybrid prosthesis) delivered on either the same day or the day after implant placement.

## MATERIALS AND METHODS

The study followed a clinical protocol for immediate occlusal loading of implants placed in the edentulous mandible. The same surgeon performed all the surgeries, and all the clinical and surgical parameters were kept the same except for the time frame of the prosthesis delivering. In fact, one group of patients received the provisional prosthesis the same day of surgery, whereas a second group of patients received the prosthesis the day after surgery.

*Inclusion and exclusion criteria*

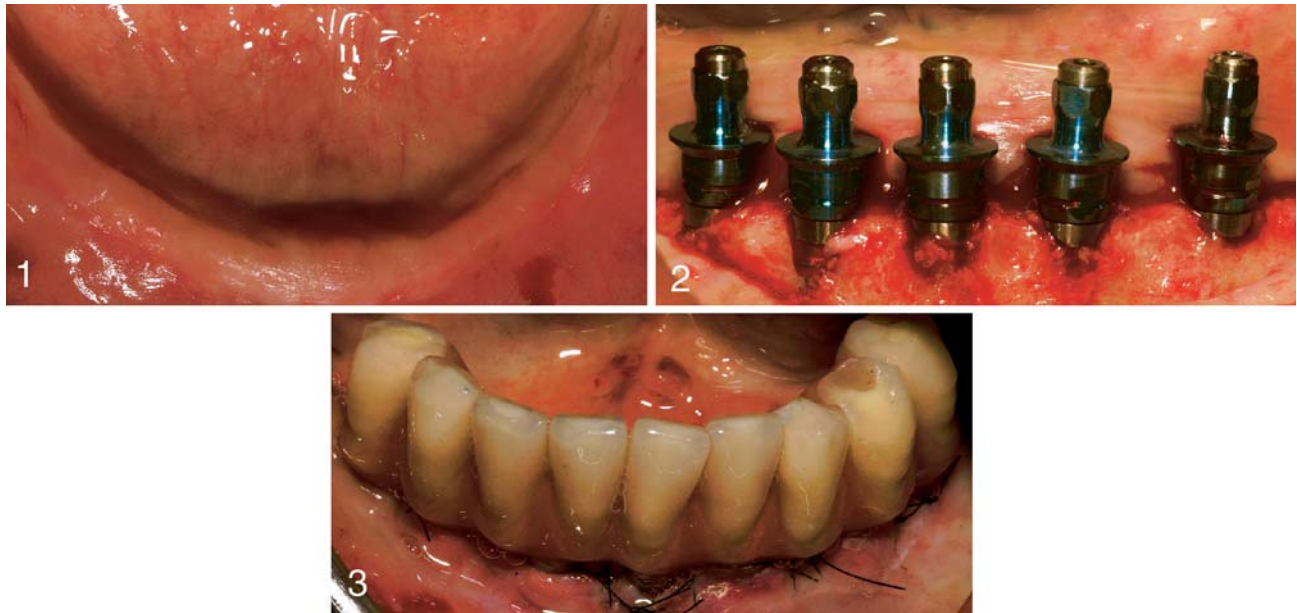
Patients were included in the study according to the following criteria: (1) patients were com-

pletely edentulous in the lower jaw, (2) rehabilitation by endosseous oral implants was considered the treatment of choice, (3) patients were physically able to tolerate conventional surgical and restorative procedures, (4) patients signed an informed consent before enrolling in the study, (5) implants were seated with a torque  $\geq 32$  Ncm showing good primary stability, and (6) the interforaminal area had dense and normal bone quality. Bone quality was scored according to the classification proposed by Trisi et al<sup>26</sup> as dense (equivalent to bone type I according to the classification proposed by Lekholm and Zarb<sup>27</sup>), normal (type II-III), and soft (type IV) bone.

Exclusion criteria were (1) the presence of active infection in the sites intended for implant placement, (2) the presence of systemic diseases such as diabetes (all types, regardless of control), (3) treatment with therapeutic X rays to the head during the past 12 months, (4) the need for bone augmentation at the intended implant site, (5) radiographic evidence of unresorbed allograft at implant site, (6) patients smoking more than 10 cigarettes a day, (7) severe bruxism or clenching, and (8) pregnancy.

*Success criteria*

The following criteria were applied to evaluate implant success: (1) absence of clinically detectable mobility when tested with opposing instrument pressure, (2) no evidence of peri-implant radiolucency on periapical radiographs, (3) absence of recurrent or persistent peri-implant infection, (4) no complaint of pain at the site of treatment, (5) no complaint of neuropathies or paraesthesia, and (6) crestal bone loss not exceeding 1.5 mm by the end of



FIGURES 1–3. FIGURE 1. Peroperative clinical picture of fully edentulous mandible. FIGURE 2. Five implants were inserted according to the so-called crestal positioning surgical protocol, with the hex above the bony ridge. FIGURE 3. The provisional prosthesis, relined in the oral cavity and finished in the lab, is then delivered; in this case, on the same day as surgery (frontal view).

first year of functional loading and less than 0.2 mm/y in the ensuing years (according to the criteria proposed by Albrektsson et al<sup>28</sup>) up to 5 years of follow-up.

#### *Surgical procedures*

All patients received dual acid-etched cylindrical screw-shaped Osseotite implants (3i, West Palm Beach, Fla). The surgeon followed the implant manufacturer's instructions for implant-site preparation and implant-insertion procedure (Figures 1 and 2). Implants were inserted according to the so-called crestal positioning surgical protocol (ie, with the hex above the bony ridge, as recently suggested in the literature<sup>29,30</sup>). Initial-implant primary stability was assessed by setting the insertion torque of the surgical unit and recorded as "tight" (torque  $\geq 32$  Ncm), "firm" (torque between 25 and 32 Ncm), or "loose" (torque  $< 25$  Ncm)<sup>31</sup> by using a drilling unit that allows the clinician to precisely determine

the insertion torque (ElcoMed WH SA200C, Burmoos, Austria). The length and diameter of the individual implants could vary from patient to patient according to bone quality and quantity at each surgical site.

#### *Prosthetic procedures*

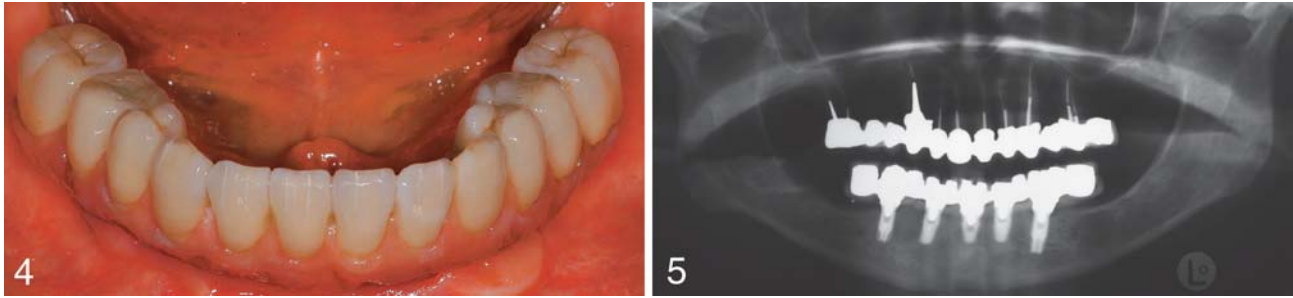
The treatment objective involved delivery of the provisional prosthesis on either the same day or the day after implant placement by using the prosthetic procedure that best suited the clinical case. The patients were randomly allocated to 1 of the 2 protocol groups by means of a coin toss. The design of the prosthesis was determined by a collaborative effort between the surgeon, the restorative doctor, and the patient, as long as the outcome was consistent with the study's objectives. A metal-reinforced acrylic provisional bridge was relined over provisional cylinders and finalized either on the same day or within the next day (Figure 3).

The definitive prosthesis was then fabricated 3 months later (Figures 4 and 5). In either case, the occlusion was evaluated to provide balanced occlusal loading.

#### *Follow-up procedures*

No specific diet was recommended to the patients. The patients were on a strict recall program during the first 6 months: every week during the first month and every month between the second and sixth month. Patients were followed thereafter at 12, 18, and 24 months postloading and then on a yearly basis up to 5 years, according to the prospective protocol.

Orthopantograms and periapical radiographs were obtained at implant insertion. Periapical radiographs were also performed subsequently; after 2, 6, and 12 months of occlusal loading; and yearly thereafter up to 5 years to evaluate crestal bone loss. The latter was measured from



FIGURES 4–5. FIGURE 4. Hybrid definitive prosthesis delivered 3 months after implant placement. FIGURE 5. Orthopantomogram of the final prosthesis.

periapical radiographs by means of a computerized technique as previously described.<sup>23,24,29</sup>

**RESULTS**

*Enrollment and demographics*

Between November 1997 and September 2002, 19 patients (10 men and 9 women) were enrolled in the study. Eleven patients received the provisional prosthesis the same day of surgery, and 8 patients received the provisional the day after surgery. The main characteristics of patients in the 2 groups are resumed in Table 1. This table also reports the implant distribution between the 2 groups. Four patients were smokers and reported smoking up to 10 cigarettes per day.

All patients were rehabilitated with a hybrid prosthesis supported by 5 to 6 immediately loaded Osseotite implants. A

total of 116 implants were inserted. The length and diameter of all the IL implants are summarized in Table 2. Ninety-eight implants (84.5%) were placed in the interforaminal area that scored dense or normal bone quality, and the remaining 18 implants (15.5%) were inserted into areas distal to the foramen that scored soft bone quality.

*Success rate*

Table 3 is a life-table analysis based on the overall data of the present study. A total of 3 implants failed because of mobility, all within 2 months from placement. The overall implant success rate was 97.4%. Two failures were recorded in the same-day loaded group, and 1 failure occurred in the other group. All failed implants were 13 mm long and were positioned in the intraforaminal area. Implants with

a length of 13 mm were the most frequently used (64.7% of the total, as shown in Table 2). Patients with implants loaded on the same day of surgery had a 96.9% implant success rate, whereas patients who received the provisional prosthesis the day after surgery had a 98.1% implant success rate, as reported in Table 1. Because of the small number of failed implants, no statistically significant difference in the implant success rate could be detected between the 2 groups. The failed implants were removed without compromising prosthesis function. None of the other implants showed complications to date.

Eleven patients, accounting for 58 implants (50% of total), had their prosthesis successfully loaded for more than 3 years. The overall mean follow-up duration was 37.8 ± 16.5 months.

No deviations from the protocol were reported. Patients'

TABLE 1  
Comparison between the 2 groups\*

	Same-Day Loading	Next-Day Loading
No. of patients	11	8
Mean age, y	60.4 ± 10.0	55.8 ± 6.2
Men/women	5/6	5/3
No. of smokers	2	2
No. of IL implants placed	64	52
Intraforaminal implants	51	47
Postforaminal implants	13	5
No. of failures	2	1
Implant success rate	96.9	98.1
Mean follow-up, mo	42.9	30.6
Follow-up range, mo	8–65	16–54

\*IL indicates immediate occlusally loaded.

TABLE 2  
Characteristics of the immediately loaded implants

Length, mm	Diameter, mm			Total
	3.75	4	5	
8.5	...	4	...	4
10	8	...	...	8
11.5	5	4	3	12
13	72	...	3	75
15	15	...	...	15
18	2	...	...	2
Total	102	8	6	116

subjective assessment in relation to the type of treatment received was overall favorable. No subjective complaints were reported throughout the follow-up period.

## DISCUSSION

The reduction of the treatment time, the introduction of minimally invasive surgical procedures, and the simplification of the prosthetic phase to provide better service to the patient is a modern trend in implant dentistry. However, this goal should be achieved without giving up to the same success rate as the delayed protocol.

The analysis of the data reported in the literature concerning the success rate of immediately loaded implants in the lower jaw, however, shows that it is difficult

TABLE 3  
Life-table analysis of the 116 immediately loaded implants

Interval time, mo	No. of Patients	No. of Implants	Implant Duration	Failed Implants	Interval Success Rate, %	Cumulative Success Rate, %
0-12	19	116	6	3	97.4	97.4
12-24	18	107	23	0	100	97.4
24-36	14	84	26	0	100	97.4
36-48	11	58	24	0	100	97.4
48-60	7	34	34	0	100	97.4

to compare different studies, mainly because of the different time frames reported. Table 4 summarizes the results of review articles reporting on immediately loaded implant-supported fixed prosthesis in the edentulous mandible. All retrieved articles published in English with a mean follow-up of at least 6 months were considered, regardless of the number of patients treated. The resulting overall implant

survival rate (97.57% on a total of 1689 IL implants) is well comparable with the outcome of the present study. No single study, however, addressed the issue of 2 different loading time frames (the same day of surgery or the next day) in the same protocol.<sup>32-48</sup>

It has been suggested that immediate occlusal loading procedures can be successful only when the amount of micromotion

TABLE 4  
Comparison of articles reporting on immediately loaded full-arch and bilateral bridges supported by implants placed in the lower jaw\*

Reference	Loading Time	Implant Type	No. of Patients	No. of IL Implants/Patient	Total No. of IL Implants	Total No. of Implants	No. of IL Failures	Implant Survival rate, %	Follow-up Duration
Salama et al <sup>35</sup>	Same day	Branemark	1	2	2	6	0	100.0	2 y
Schnitman et al <sup>14</sup>	Same day	Branemark	10	1-6	28	63	4	85.7	up to 10 y
Tarnow et al <sup>15</sup>	Same day	various	6	4-10	36	64	2	94.4	2-5 y
Balshi and Wolfinger <sup>13</sup>	Same day	Branemark	10	4	40	130	8	80.0	1-1.5 y
Levine et al <sup>36</sup>	1 wk	ITI-HS	1	4	4	4	0	100.0	4 y
Branemark et al <sup>17</sup>	Same day	Branemark	50	3	150	150	3	98.0	6 mo-3 y
del Pilar Rios Calvo et al <sup>37</sup>	1 wk	Lifecore	1	4	4	10	0	100.0	1 y
Kinsel and Lamb 2000 <sup>38</sup>	1 d	ITI	8	4-8	47	47	1	97.9	<1-5 y
Horiuchi et al <sup>39</sup>	1 d	Branemark	12	5-10	96	105	2	97.9	up to 2 y
Jaffin et al <sup>19</sup>	< 3 d	various	23	4-8	122	122	8	93.4	6 mo-5 y
Malo et al <sup>40</sup>	Same day	Branemark	9	2-4	28	28	1	96.4	6 mo-4 y
Ganeles et al <sup>42</sup>	<2 d (1 × 7 d)	ITI	27	4-8	161	186	1	99.4	13-41 mo
Chow et al <sup>41</sup>	Same day	Branemark	27	4-8	123	123	2	98.3	3-30 mo
Hatano <sup>44</sup>	Same day	Branemark	35	3	105	105	3	97.1	2-36 mo
Grunder <sup>43</sup>	<24 h	3i Osseotite	5	8-10	43	43	1	97.7	24 mo
Ibanez and Jalbout <sup>45</sup>	<2 d	3i Osseotite	5	6	30	30	0	100.0	24-30 mo
Cooper et al <sup>46</sup>	Same day	Astra Tech	10	5-6	48	54	0	100.0	6-18 mo
Degidi and Piattelli 2003 <sup>47</sup>	Same day	various	28	NR	199	199	2	99.0	2-60 mo
Romanos <sup>48</sup>	Same day	Ankylos	1	6	6	6	0	100.0	18 mo
Testori et al <sup>23</sup>	4-36 h	3i Osseotite	15	5-10	92	103	1	98.9	6-48 mo
Testori et al <sup>24</sup>	Same day	3i Osseotite	62	5-10	325	337	2	99.4	6-60 mo
Total			346		1689	1915	41	97.57	

\*IL indicates immediate occlusally loaded; NR, not reported.

at the bone-implant interface is kept beneath a certain threshold during the healing phase.<sup>25,33</sup> Several studies have reported higher failure rates for immediately loaded implants when compared with delayed-loaded Implants.<sup>14,18,19,34</sup> This shows that this procedure, although predictable, is technique-sensitive and should be applied cautiously.

A gradual and progressive approach to immediate loading is therefore recommended. Our original immediate loading procedure in the edentulous mandible began by adding submerged implants as a reserve, as first proposed by Schnitman et al.<sup>12</sup> In our case, this approach was abandoned after 2 preliminary patients because the histological analysis demonstrated that all 3 IL implants surgically retrieved from patients by trephine were osseointegrated after 2 months<sup>22</sup> and 4 months<sup>21</sup> of function. Because only 3 implants failed in the present, with an overall success rate of 97.4%, the preliminary data suggest that (1) 5 to 6 IL implants can maintain a level of micromotion beneath the critical threshold for implant survival, and (2) 5 to 6 IL implants can provide patients with the same level of success as standard delayed protocol.

On the basis of the results provided by this study, the delivery of provisional hybrid prostheses the same day or the next day does not significantly affect the overall success rate.

#### CONCLUSION

Within the limits of the present study, rehabilitation of the edentulous mandible by an IL provisional hybrid prosthesis supported by 5 to 6 Osseotite implants can be a viable alterna-

tive treatment to the classic delayed protocol. The loading time frame could be chosen upon both the clinical needs of each individual patient and the logistic of the dental practice that may prevent or allow the delivery of the provisional prosthesis the same day.

#### REFERENCES

1. Brånemark P-I, Hansson BO, Adell R, et al. Osseointegrated implants in the treatment of the edentulous jaw. Experience from a 10-year period. *Scand J Plast Reconstr Surg.* 1977;16:1-132.
2. Brånemark P-I, Zarb GA, Albrektsson T. *Tissue Integrated Prostheses: Osseointegration in Clinical Dentistry.* Chicago, Ill: Quintessence Publishing Co; 1985.
3. Roberts WE, Smith RK, Zilberman Y, et al. Osseous adaption to continuous loading of rigid endosseous implants. *Am J Orthod.* 1984;86:95-111.
4. Roberts WE, Helm FR, Marshall KJ, et al. Rigid endosseous implants for orthodontic and orthopedic anchorage. *Angle Orthod.* 1989;59:247-256.
5. Roberts WE, Turley PK, Brezniak N, et al. Bone physiology and metabolism. *Calif Dent Assoc J.* 1987;15:54-61.
6. Roberts WE, Simmons KE, Garetto LP, et al. Bone physiology and metabolism in dental implantology: risk factors for osteoporosis and other metabolic bone diseases. *Implant Dent.* 1992; 1:11-21.
7. Roberts WE. Bone tissue interface. *J Dent Educ.* 1988;52:804-809.
8. Garetto LP, Chen J, Parr JA, et al. Remodeling dynamics of bone supporting rigidly fixed titanium implants: a histomorphometric comparison in four species including humans. *Implant Dent.* 1995;4:235-243.
9. Akagawa Y, Ichikawa Y, Nikai H, Tsuru H. Interface histology of early loaded partially stabilized zirconia endosseous implant in initial bone healing. *J Prosthet Dent.* 1993;69:599-604.
10. Sagara M, Akagawa Y, Nikai H, Tsuru H. The effects of early occlusal loading on one-stage titanium implants in beagle dogs: a pilot study. *J Prosthet Dent.* 1993;69:281-288.
11. Piattelli A, Corigliano M, Scarano A, Quaranta M. Immediate loading of titanium plasma-sprayed implants: an histologic analysis in monkeys. *J Periodontol.* 1998;69:321-327.
12. Schnitman P, Wöhrle PS, Rubenstein JE. Immediate fixed interim prostheses supported by two-stage threaded implants: methodology and results. *J Oral Implantol.* 1990;2:96-105.
13. Balshi TJ, Wolfinger GJ. Immediate loading of Branemark implants in edentulous mandibles: a preliminary report. *Implant Dent.* 1997;6:83-88.
14. Schnitman P, Wöhrle PS, Rubenstein JE, DaSilva JD, Wang NH. Ten years results for Brånemark implants immediately loaded with fixed prostheses at implant placement. *Int J Oral Maxillofac Implants.* 1997;12:495-503.
15. Tarnow DP, Emtiaz S, Classi A. Immediate loading of threaded implants at stage 1 surgery in edentulous arches: ten consecutive case reports with 1- to 5-year data. *Int J Oral Maxillofac Implants.* 1997;12:319-324.
16. Wöhrle PS. Single-tooth replacement in the aesthetic zone with immediate provisionalization: fourteen consecutive cases reports. *Practical Periodont Aesthetic Dent.* 1998;10:1107-1114.
17. Brånemark P-I, Engstrand P, Ohnell L-O, et al. Brånemark Novum: a new treatment concept for rehabilitation of the edentulous mandible. Preliminary results from a prospective clinical follow-up study. *Clin Implant Dent Related Res.* 1999;1:2-16.
18. Ericsson I, Nilson H, Lindhe J, Nilner K, Randow K. Immediate functional loading of Brånemark single tooth implants. An 18 months' follow-up study. *Clin Oral Implants Res.* 2000;11: 26-33.
19. Jaffin RA, Kumar A, Berman CL. Immediate loading of implants in partially and fully edentulous jaws: a series of 27 case reports. *J Periodontol.* 2000; 71:833-838.
20. Lozada JL, Tsukamoto N, Farnos A, Kan J, Rungcharassaeng K. Scientific rationale for the surgical and prosthodontic protocol for immediately loaded root form implants in the completely edentulous patient. *J Oral Implantol.* 2000;26:51-58.
21. Testori T, Szmukler-Moncler S, Francetti L, et al. Immediate loading of Osseotite implants. A case report and histologic analysis after 4 months of occlusal loading. *Int J Periodont Restor Dent.* 2001;21:451-459.
22. Testori T, Szmukler-Moncler S, Francetti L, Del Fabbro M, Trisi P, Weinstein RL. Healing of Osseotite implants under submerged and immediate loading conditions in a patient: a case report and interface analysis after 2



months. *Int J Periodont Restor Dent*. 2002;22:345–353.

23. Testori T, Del Fabbro M, Szmukler-Moncler S, Francetti L, Weinstein RL. Immediate occlusal loading of Osseotite implants in the completely lower edentulous mandible. *Int J Oral Maxillofac Implants*. 2003;18:544–551.

24. Testori T, Meltzer A, Del Fabbro M, et al. Immediate occlusal loading of Osseotite implants in the lower edentulous jaw. A multicenter prospective study. *Clin Oral Implants Res*. 2004;15:278–284.

25. Szmukler-Moncler S, Salama H, Reingewirtz Y, Dubruille JH. Timing of loading and effect of micro-motion on bone-implant interface: a review of experimental literature. *J Biomed Mater Res*. 1998;43:192–203.

26. Trisi P, Rao W, Rebaudi A. A histometric comparison of smooth and rough titanium implants in human low-density jawbone. *Int J Oral Maxillofac Implants*. 1999;14:698.

27. Lekholm U, Zarb GA. Patient selection and preparation. In: Branemark P-I, Zarb GA, Albrektsson T, eds. *Tissue-Integrated Prosthesis: Osseointegration in Clinical Dentistry*, Chicago, Ill: Quintessence Publishing Co; 1985:199–209.

28. Albrektsson T, Zarb G, Worthington P, Eriksson AR. The long-term efficacy of currently used dental implants: a review and proposed criteria for success. *Int J Oral Maxillofac Implants*. 1986;1:11–25.

29. Testori T, Francetti L, Del Fabbro M, Zuffetti C, Weinstein RL. A radiographic evaluation of crestal bone changes in submerged implants supra and sub-crestally positioned. A pilot study in humans [abstract]. *Clin Oral Implants Res*. 1999;10:178.

30. Darvanapah M, Martinez H, Tecucianu J-F. Apical-coronal position: recent surgical proposals. Technical note. *Int J Oral Maxillofac Implants*. 2000;15:865–872.

31. Testori T, Del Fabbro M, Feldman S, et al. A multicenter prospective evaluation of 2-months Osseotite implants placed in the posterior jaws: 3-year follow-up results. *Clin Oral Implants Res*. 2002;13:154–161.

32. Del Fabbro M, Testori T, Francetti L, Bianchi F, Weinstein R. A meta-analysis on survival rate of immediately loaded implants [abstract]. *Clin Oral Implants Res*. 2002;13:xxiv.

33. Szmukler-Moncler S, Piattelli A, Favero GA, Dubruille JH. Considerations preliminary to the application of early and immediate loading protocols in dental implantology. *Clin Oral Implants Res*. 2000;11:12–25.

34. Chaushu G, Chaushu S, Tzohar A, Dayan D. Immediate loading of single-tooth implants: immediate versus non-immediate implantation. A clinical report. *Int J Oral Maxillofac Implants*. 2001;16:267–272.

35. Salama H, Rose LF, Salama M, Betts NJ. Immediate loading of bilaterally splinted titanium root form implants in fixed prosthodontics: a technique re-examined. Two case reports. *Int J Periodont Restor Dent*. 1995;15:345–361.

36. Levine RA, Rose L, Salama H. Immediate loading of root-form implants: two case reports 3 years after loading. *Int J Periodont Restor Dent*. 1998;18:333–343.

37. del Pilar Rios Calvo M, Muller E, Garg AK. Immediate loading of titanium hexed screw-type implants in the edentulous patient: case report. *Implant Dent*. 2000;9:351–357.

38. Kinsel RP, Lamb RE. Development of gingival esthetics in the edentulous patient with immediately loaded, single-stage, implant-supported fixed prostheses: a clinical report. *Int J Oral Maxillofac Implants*. 2000;15:711–721.

39. Horiuchi K, Uchida H, Yamamoto K, Sugimura M. Immediate loading of Branemark system implants following placement in edentulous patients: a clinical report. *Int J Oral Maxillofac Implants*. 2000;15:824–830.

40. Malo P, Rangert B, Dvarsater L. Immediate function of Branemark implants in the esthetic zone: a retrospective clinical study with 6 months to 4 years of follow-up. *Clin Implant Dent Related Res*. 2000;2:138–146.

41. Chow J, Hui E, Liu J, et al. The Hong Kong bridge protocol. Immediate loading of mandibular Brånemark fixtures using a fixed provisional prosthesis: preliminary results. *Clin Implant Dent Related Res*. 2001;3:166–174.

42. Ganeles J, Rosenberg MM, Holt R, Reichman LH. Immediate loading of implants with fixed restorations in the completely edentulous mandible: report of 27 patients from a private practice. *Int J Oral Maxillofac Implants*. 2001;16:418–426.

43. Grunder U. Immediate functional loading of immediate implants in edentulous arches: two-year results. *Int J Periodont Restor Dent*. 2001;21:545–551.

44. Hatano N. The Maxis New. A novel one-day technique for fixed individualised implant-supported prosthesis in the edentulous mandible using Branemark System implants. *Appl Osseointegration Res*. 2001;2:40–43.

45. Ibanez JC, Jalbout ZN. Immediate loading of Osseotite implants: two-year results. *Implant Dent*. 2002;11:128–136.

46. Cooper LF, Rahman A, Moriarty J, Chaffee N, Sacco D. Immediate mandibular rehabilitation with endosseous implants: simultaneous extraction, implant placement, and loading. *Int J Oral Maxillofac Implants*. 2002;17:517–525.

47. Degidi M, Piattelli A. Immediate functional and non-functional loading of dental implants: a 2- to 60-month follow-up study of 646 titanium implants. *J Periodontol*. 2003;74:225–241.

48. Romanos GE. Treatment of advanced periodontal destruction with immediately loaded implants and simultaneous bone augmentation: a case report. *J Periodontol*. 2003;74:255–261.