

AN ESTHETIC TECHNIQUE TO FILL SCREW-RETAINED FIXED PROSTHESES

Ryan C. Taylor, DDS
Ashraf S. Ghoneim, BDS
Edwin A. McGlumphy, DDS, MS

KEY WORDS

Screw access openings
Dental implants
Esthetics

Ryan C. Taylor, DDS, is a resident in the Department of Periodontics, Ashraf S. Ghoneim, BDS, is an implant fellow in the Ohio State Implant Clinic, and Edwin A. McGlumphy, DDS, MS, is an associate professor in Restorative and Prosthetic Dentistry in the College of Dentistry, The Ohio State University, Columbus, Ohio. Correspondence should be addressed to Dr McGlumphy at Restorative and Prosthetic Dentistry, College of Dentistry, The Ohio State University, 305 West 12th Avenue, Columbus, OH 43210 (e-mail: mcGlumphy.1@osu.com).

Currently, many composite materials have been used in the filling of access openings for screw-retained implant prosthesis. The main disadvantage of these materials is the compromise in esthetics that they place on the implant crown. An additional disadvantage is leakage of bacterial contaminants around traditional light-cured composites placed in the screw access hole. This article introduces a technique that uses opaqueing composites and the expansion properties of panacea (Zeza Inc, Chester, NY) resin to help remedy these problems. The fabrication of the silicone obturator is explained in previous literature. By following this technique, the dentist can use resin to decrease microleakage and opaqueing composite to improve esthetics.

TECHNIQUE

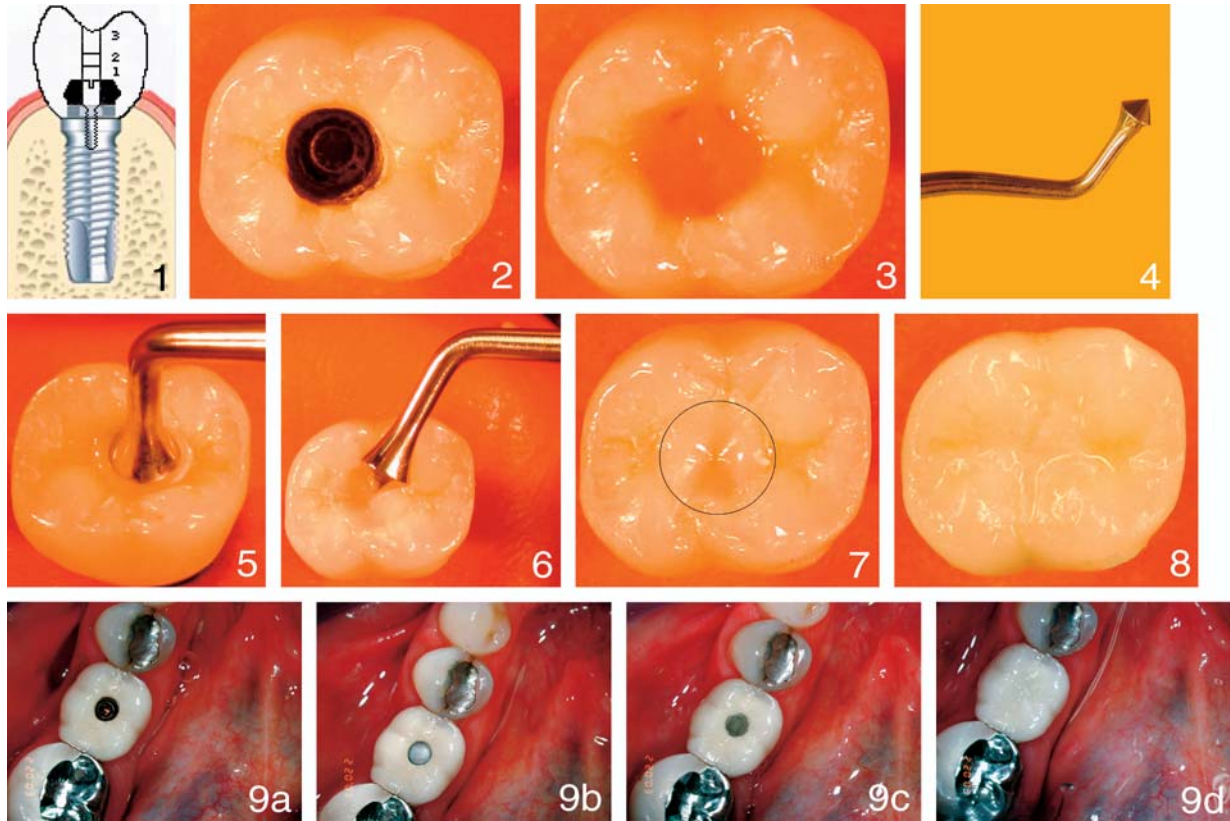
After the prosthesis is screwed onto the abutment, the access canals are filled with light-bodied polyvinylsiloxane impression material (or a cotton pellet).

After the polyvinylsiloxane has completely polymerized, it can be easily removed with an explorer. This polyvinylsiloxane will aid in the protection of the screw during removal with a rotary instrument. In addition, Adrian¹ recommends that during

the interim period, full-length silicone plugs can be used before final sealing of the canal with the resin. The silicone obturator is cut to allow for space for the resin. The technique itself is demonstrated in Figures 1 through 8, and clinical results are shown in Figure 9.

REFERENCE

1. Adrian ED, Krantz WA, Ivanhoe JR, Turner KA. A silicone obturator for the access canal in an implant-retained fixed prosthesis. *J Prosthet Dent.* 1991;65:597.



FIGURES 1–9. FIGURE 1. Cross section of access canal showing the (a) silicone plug (or cotton pellet), (b) panacea, and (c) the composite/resin. FIGURE 2. Screw access opening. FIGURE 3. Place a layer of panacea resin over the silicone obturator or cotton pellet. One of panacea's properties is setting expansion. This helps reduce microleakage, which may cause odor release during future screw removal. FIGURE 4. The nonesthetic darkness comes from the area of the screw and lateral walls of the screw access opening. Use the large amalgam burnisher to provide optimal results when using the opaque (dentin) composites. FIGURE 5. Take opaque (dentin) composite and fill the remaining area of the access opening. Compress the burnisher into the access opening. FIGURE 6. The burnisher will create a cone-shaped impression on top of the resin, masking both the screw area and the lateral walls. FIGURE 7. This technique allows the dentin composite to be thick on the walls of the screw access opening. The resin is then light cured, and the cone-shaped impression will conveniently mark the entrance of the access opening. FIGURE 8. Enamel composite can be used to fill the coned area for optimal esthetics. FIGURE 9. Clinical photos showing the screw access opening (a), cotton pellet (b), placement of panacea (c), and placement of resin (d).