

IMMEDIATE LOADING OF ENDOSSEOUS IMPLANTS IS NOT NEW

Leonard I. Linkow, DDS, DMSc
Robert J. Miller, DDS

KEY WORDS

Immediate load
Histology of immediate load
Endosseus implants

Leonard I. Linkow, DDS, DMSc, is a clinical professor in the Department of Implant Dentistry, NYU College of Dentistry, New York, NY, and an associate clinical professor in the Department of Implantology, Lille University, Lille, France.

Robert J. Miller, DDS, is chairman of the Department of Oral Implantology, Atlantic Coast Dental Research Clinic, Palm Beach, Fla, and is in private practice in Delray Beach, Fla.

Address correspondence to Dr Miller at 16244 South Military Trail, Suite 260, Delray Beach, FL 33484 (e-mail: millerbeardog1@aol.com).

For practitioners trained within the past 20 years in oral implantology, the accepted protocol for implant placement required a significant and trauma-free healing period before prosthetic loading. The majority of implant procedures performed today use this 2-stage protocol. With the evolution of new implant designs, immediate loading of implants has been used with success. Many practitioners, however, are unaware that the concept of immediately loading implants actually began 40 years ago with the contributions of Dr Leonard I. Linkow.

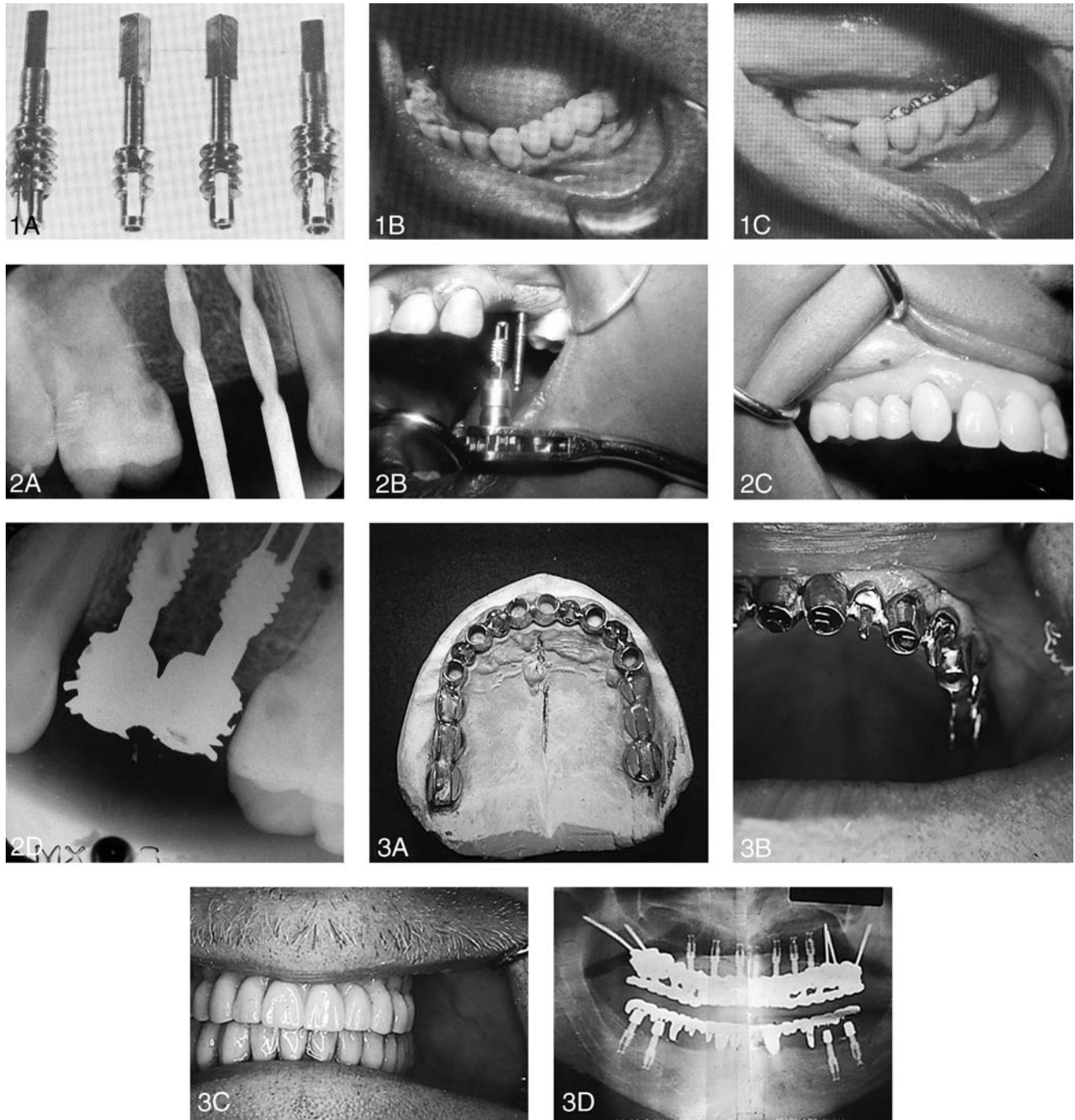
As early as 1963, Dr Linkow had developed the first self-tapping endosseous root-form implant, known as the Ventplant.^{1,2} The protocol that was ultimately adopted was to immediately load these implants with overdentures or acrylic, provisional fixed bridges. In that year the *implant aiguilles* (needle implants)^{3,4} mandated immediate loading, and immediate loaded subperiosteal implants followed in 1964. In 1967, the endosseous blade implant, which also called for immediate loading (for splinting purposes), was introduced.⁵⁻⁹ Before 1967, Dr Linkow carefully established a protocol for immediate loading in root-form procedures. From 1967 to the latter part

of 1999, myriad blade and plate-form implants were also placed into immediate function.¹⁰

In a technique described over 3 decades ago, cut bone shavings were transported to areas within implant fenestrations rather than forced into peri-implant spaces, as most surgeons were doing. These attempts at offering support to newly placed root forms were sometimes responsible for local and occult osteolysis. One of the benefits accruing to those who followed the simple rules espoused and practiced by Dr Linkow was that their implants were capable of supporting immediate loading.

In many unilateral situations where the molar abutments consisted of 1 or 2 implants and the anterior teeth were healthy, the cuspid and first bicuspid (when present) were used as the anterior abutments. A 4- or 5-unit prefabricated or chair-side, acrylic, interim prosthesis was inserted, thereby placing the reconstructed quadrant into immediate function (Figures 1A-C and 2A-D).^{11,12}

The design of such a bridge should include a cuspid rise to ensure accompanying disclusion of the posterior implant-borne prosthesis during lateral movements. The buccal inclined planes and cusps should be flattened, and a hard cement is used if the patient is to wear the provisional



FIGURES 1–3. FIGURE 1. (A) Ventplants of various sizes. (B) The temporary acrylic splint is affixed with a temporary cement. (C) The acrylic and gold-fixed partial denture is cemented with hard cement. FIGURE 2. (A) Pilot drills used as radiographic markers. (B) Placement of ventplant with a drill as parallel marker. (C) Acrylic provisional. (D) Radiograph of acrylic over gold definitive fixed prosthesis. FIGURE 3. (A) A prefabricated cast gold tube guiding template with posterior bilateral horizontal rails to guide the 1-piece ventplants anteriorly, and the needle implants posteriorly. (B) The ventplants screw directly inside the gold template and through the mucoperiosteal tissues and into the bone. The template is locked to the ventplates using a tuberculin syringe filled with methyl methacrylate material. (C) Both the prefabricated and prearticulated maxillary and mandibular full arch definitive prostheses are cemented over the locked prefabricated guiding maxillary template, and over the mandibular ventplant root form implants with their specially designed gold copings. (D) The postoperative panorex.

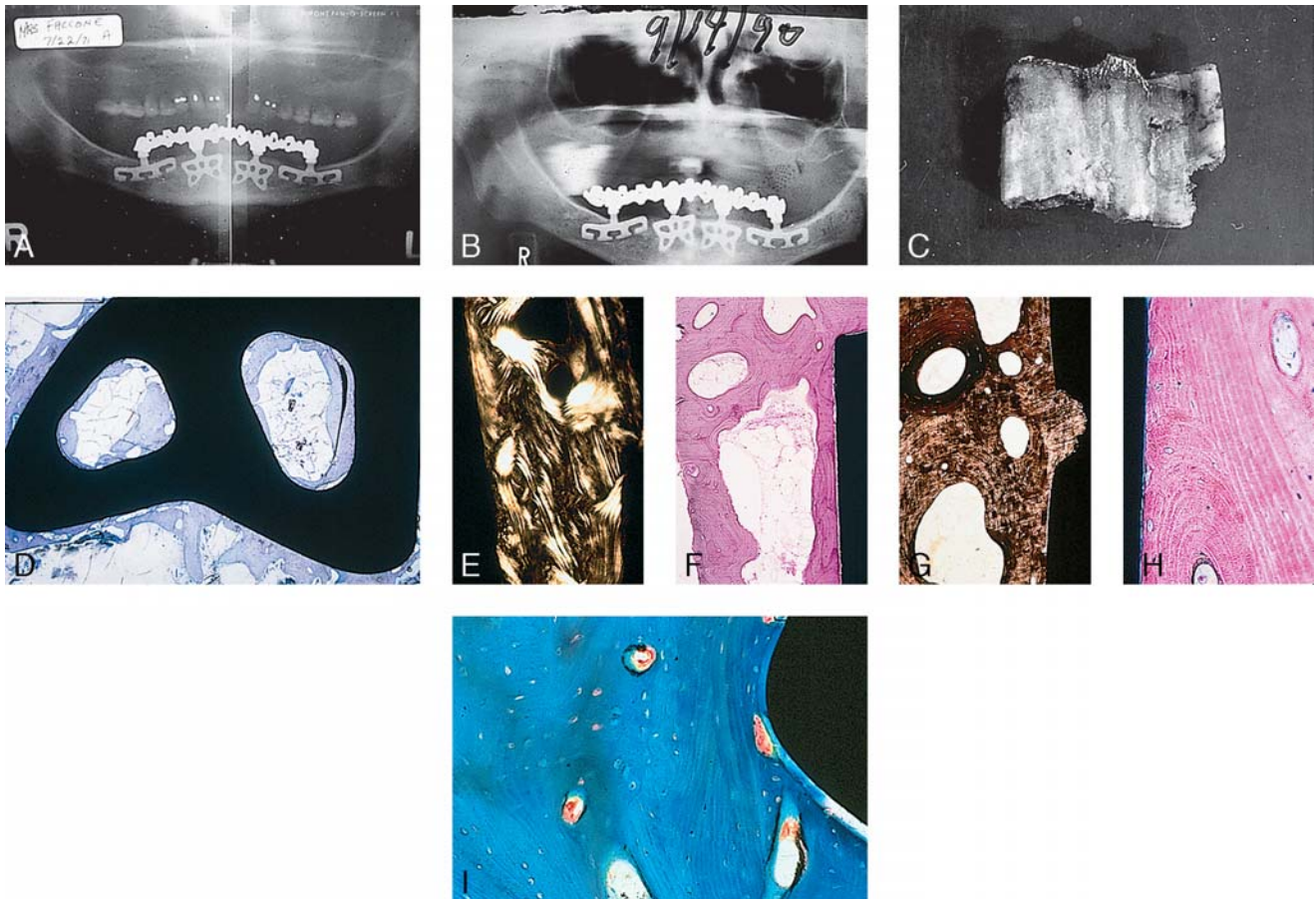


FIGURE 4. (A) Panorex of final prosthesis cemented in place 4 weeks after implant placement. (B) Panorex of case at 19 years, 3 months in function. (C) Block section of fractured implant. (D-I) Photomicrographs with varying stains indicate the remarkable levels of osseointegration.

prosthesis for several months. As a result, the bridge will require sectioning when it must be removed.

The final fixed prosthesis should have a narrower occlusal table, and the cuspal inclines should be no greater than 15 degrees. It is advisable to stabilize these cases with a denture adhesive or a similar very soft cement for several weeks before permanent cementation.

In totally edentulous cases, 4 endosseous root-form or blade implants were inserted, 2 on each side of the arch distal to the canines. Their abutments required parallelism, which could have been achieved by the use of diamonds or by supplying them

with telescopic copings. Angle abutments may be used with 2-piece root-form systems.¹³ A prefabricated acrylic full-arch splint or chair-side cold-cured splint was fitted, trimmed, articulated, and cemented passively over the abutments with temporary cement.¹⁴

The prosthesis should follow a very strict occlusal pattern, such as narrow occlusal tables, with planes inclined to no more than 15 degrees and with group function posteriorly in lateral excursions, as developed by Dr Charles English.¹³ The same post-cementation rules apply for the full-arch interim prostheses as they do for the quadrant designs.^{15,16}

The final porcelain fused to the metal prosthesis must follow the same prosthetic and occlusal guidelines. Often, an acrylic-processed-to-metal bridge may be the prosthesis of choice (Figure 3A-D).

The result of a biopsy study of a case in a totally edentulous mandible of 1 of 4 blade implants that were placed in immediate function verifies integration even after 19 years and 3 months of function. This is the longest state of function ever reported for endosseous implants.¹⁴

Professor Carl Donath of the University of Munich performed the histopathology on this blade implant, which showed an average of 72% bone-to-metal contact

(Figure 4).¹⁸ Most current journal articles on immediate load involve a single implant modality: the endosseous root-form implant. Few practitioners realize that over 40 years ago the practice of placing implant systems into immediate functional activity was a vital, comprehensive, and successful technique.

REFERENCES

1. Linkow LI. Intraosseous implants utilized as fixed bridge abutments. *J Oral Implant Transplant Surg.* 1964;10:17–23.
2. Linkow LI. The radiographic role in endosseous implant interventions. *Chron Omaha District Dent Soc.* 1966; 29:304–311.
3. Linkow LI. The era of endosseous implants. *J DC Dent Soc.* 1967;42:2.
4. Linkow LI. Prefabricated mandibular prosthesis for intraosseous implants. *J Prosthet Dent.* 1968;20:4.
5. Linkow LI. Prefabricated endosseous implant prostheses. *Dent Concepts.* 1967;10:3–11.
6. Linkow LI. Maxillary endosseous implants. *Dent Concepts.* 1966;10:14–24.
7. Linkow LI. The bladevent—a new dimension in endosseous implantology. *Dent Concepts.* 1968;11:3–18.
8. Linkow LI. The endosseous blade implant and its use in orthodontics. *Int J Orthod.* 1969;8:148–154.
9. Linkow LI. Endosseous oral implantology: a two year report. *J Prosthet Dent.* 1970;23:441–448.
10. Linkow LI. Endosseous oral implantology: a seven year progress report. *Dent Clin North Am.* 1970;14:185–200.
11. Linkow LI. A surgical perspective: immediate placement of blade/plate form and self tapping ventplant screw implants into fresh extraction sites. *J Implant Dent.* 1995;21:131–137.
12. Linkow LI. *Theories and Techniques of Oral Implantology.* St Louis, Mo: CV Mosby Co; 1970:335–336.
13. English CE. Biomechanical concerns with fixed partial dentures involving implants. *J Implant Dent.* 1993;2:221–242.
14. Linkow LI, Donath C, Lemons JE. Retrieval analysis of a blade implant after 231 months of clinical function. *J Implant Dent.* 1992;1:37–43.
15. Linkow LI, Kohen A. Statistical analysis of 173 implant patients. *Int J Oral Implantol.* 1974;4:540–562.
16. Linkow LI, Kohen A. Evaluation of 564 implant patients (1540 implants). “Implantologist.” *Int J Oral Implantol.* 1979–1980;1:35–37.
17. Linkow LI. Benefits and risks of endosteal blade implants (Harvard conference, June 1978). *Int J Oral Implantol.* 1980;9:9–44.
18. Linkow LI. *Implant Dentistry Today—A Multidisciplinary Approach.* Padua, Italy: Piccin Nuova Libreria; 1990:606–610.