

IMMEDIATE FUNCTIONAL LOAD OF MANDIBULAR IMPLANT OVERDENTURES: A SURGICAL AND PROSTHODONTIC RATIONALE OF 2 IMPLANT MODALITIES

Jaime L. Lozada, DDS
Aladdin J. Al-Ardah, DDS
Kitichai Rungcharassaeng, DDS, MS
Joseph Y. K. Kan, DDS, MS
Alejandro Kleinman, DDS

KEY WORDS

Endosseous implants
Osseointegration
Overdentures
Immediate functional loading
Subperiosteal implant

Jaime L. Lozada, DDS, is a professor and director, Aladdin J. Al-Ardah, DDS, is an assistant professor, Joseph Y. K. Kan, DDS, MS, and Alejandro Kleinman DDS, are associate professors, and Kitichai Rungcharassaeng, DDS, MS, is an assistant professor of the Graduate Program in Implant Dentistry, Loma Linda University, School of Dentistry Center for Implant Dentistry, Loma Linda, Calif.

Address correspondence to Dr Lozada at 11092 Anderson St, Suite 4411, Loma Linda, CA. 92350 (e-mail: jlozada@sd.llu.edu).

Classic guidelines in osseointegration for root-form dental implants include a long healing period, during which functional load should be avoided. However, the long healing period might impose an intolerable situation on some patients, especially in the completely edentulous situation. Subperiosteal dental implant guidelines demonstrate that the implant upon insertion can be put into immediate function and be restored with the final prosthesis soon after surgery. Studies on immediately functional loaded implant-supported prostheses in patients who are completely edentulous have been reported, exhibiting high success rates comparable with conventionally loaded implants. This article describes the surgical and prosthodontic procedure for the immediately functional loaded mandibular implant overdentures in 2 different dental implant modalities, as well as its clinical rationale.

INTRODUCTION

The viability and predictability of osseointegrated endosseous implants in treating patients who are completely and partially edentulous have been supported with the high success rates reported in numerous studies.¹⁻⁴ Classic guidelines for osseointegration include a long healing period, during which functional load should be avoided. Periods of 3 to 4 months and 4 to 6 months have been

recommended as healing times for osseointegrated implants placed in the mandible and maxilla, respectively.^{5,6} The long healing periods might impose an intolerable situation esthetically, functionally, psychologically, and socially on some patients, especially in a completely edentulous situation.

In 1986, Babbush et al⁷ described a technique of immediately loading 4 titanium plasma-sprayed implants placed in the mandibular symphysis with an overdenture. The implants were

rigidly splinted with a metal bar, and the denture was relined with soft liner within 2 to 3 days after the surgery. The final prosthesis with the clips was placed 2 weeks later. The authors reported a cumulative failure rate of 12% after 8 years of follow-up. Since then, several studies have focused on both fixed and removable immediately loaded implant-supported prostheses in patients who are completely edentulous, and high success rates comparable with conventionally loaded implants have been reported.

The success rates of subperiosteal dental implants have been disputed.^{8,9} Minimal documented evidence of the predictability of these devices has lessened the benefits that the implant offers for patients with severely atrophic mandibles.^{10,11} One of the guidelines of these particular implant modality dictates that the implant upon insertion be loaded with a provisional overdenture. In most cases, the patient's existing denture is modified so it can be used as a provisional denture for 3 months before the final prosthesis is inserted.

The purpose of this article is to describe the surgical and prosthodontic procedure for the immediately loaded mandibular implant overdenture of 2 different implant modalities: root-form implant overdenture and subperiosteal implant overdenture. The clinical rationale and outcomes of each modality are also discussed.

MATERIALS AND METHODS

Patient selection for the root-form implant modality

The patients selected for immediately loaded mandibular implant bar overdentures fulfilled the following criteria: (1) had com-

pletely edentulous maxilla and mandible (Figure 1), (2) had enough bone between the mental foramina to allow for placement of 4 endosseous root-form implants with a minimum length of 12 mm, (3) had bone quality better than type IV according to Lekholm and Zarb,¹² and (4) had a medical history that did not contraindicate implant treatment.

Patient selection for the subperiosteal implant modality

The patients selected for immediately loaded mandibular subperiosteal implant bar overdentures fulfilled the following criteria: (1) had completely edentulous maxilla and mandible (Figure 1), (2) had enough bone to allow for placement of a subperiosteal implant framework without having to augment the mandible with simultaneous bone graft (division C according to Misch¹³), and (3) had a medical history that did not contraindicate implant treatment.

Presurgical prosthodontic procedures

After the patient had been selected as a candidate for immediately loaded mandibular implant overdenture, new maxillary and mandibular complete dentures with proper extensions as well as proper occlusal schemes were fabricated. Adjustments were made so that the patient was as comfortable as possible with the new dentures. A radiographic template was then fabricated with clear acrylic resin (Splint Resin Polymer, Great Lakes Orthodontics, Towanda, NY) by duplicating the mandibular complete denture. Radiopaque markers, such as gutta percha (Dental stopping, Coltene-Whaledent, Cuyahoga Falls, OH) or barium sulfate (E-Z-HD, E-Z-EM), were used during computerized tomography (CT) scan-

ning to determine the implant position and data to produce for the subperiosteal implant protocol a 3-dimensional life-size cast or model of the mandible by stereolithography methods.¹⁴⁻¹⁶ (Figure 2). The radiographic template was later modified into a surgical template.

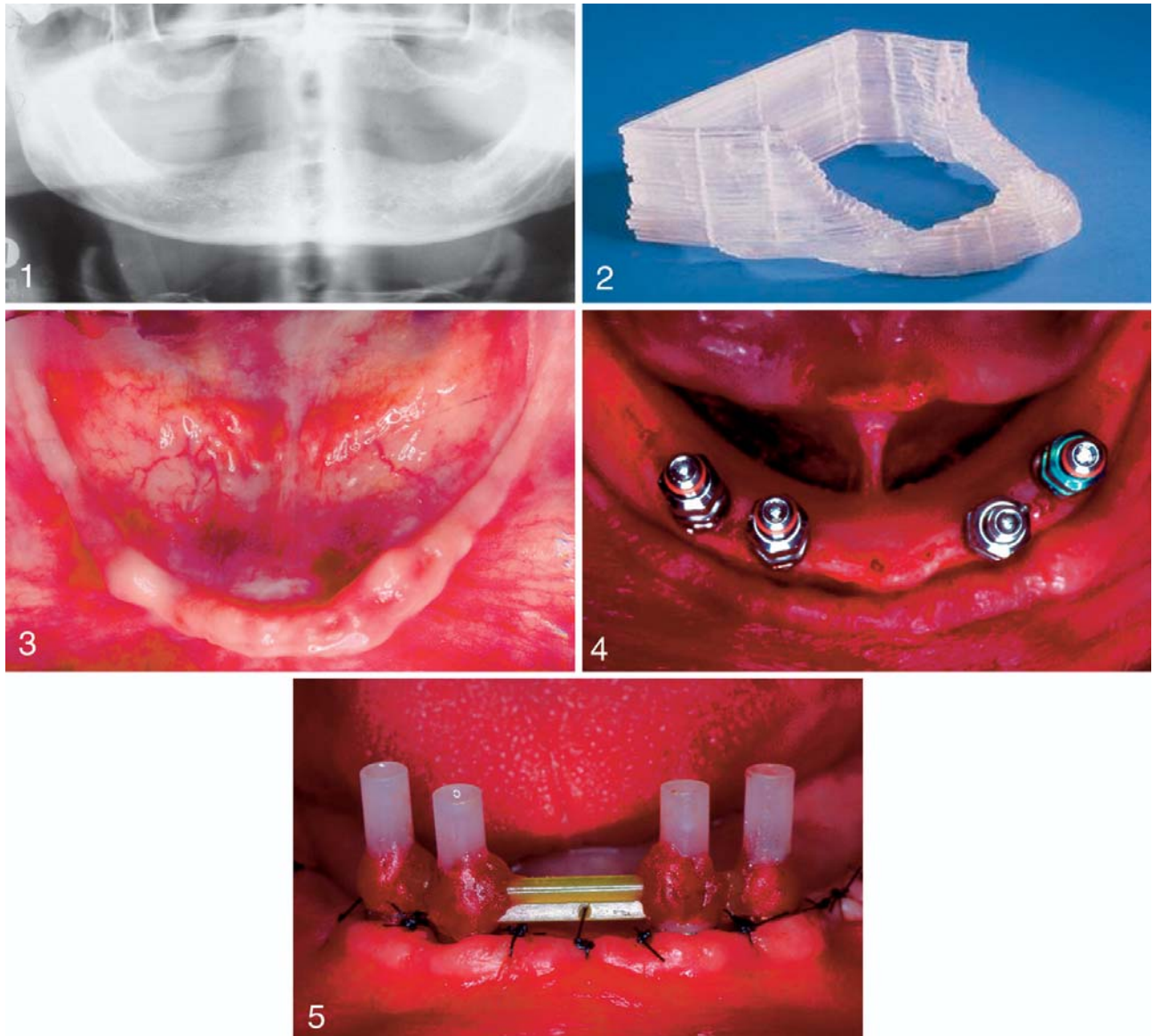
Surgical procedure for the root-form implant modality

Implant placement surgery was performed under local anesthesia by infiltration in the mandible. A midcrestal incision was made, a full-thickness flap was reflected, and the mental foramina were identified bilaterally. The surgical template was then placed in position for evaluation of the clearance for the attachment system. In the patient shown in Figure 3, alveoloplasty was necessary because of the space inadequacy.

The maxillary complete denture was used to locate the midline, and a slight mark was made on the mandible. The 2 posterior implants were located approximately 5 mm anterior to the mental foramina. The 2 anterior implants were about 7 to 10 mm anterior to the posterior implants; the anterior implants should be equidistant from the midline. All implant positions should be within the confines of the surgical template (Figure 4).

A complete series of osteotomies were performed according to the manufacturer's protocol, and the implants were placed into the osteotomy sites. The surgical template and maxillary complete denture were used to verify buccolingual and mesiodistal angulation of the implants, respectively.

Transmucosal abutments of appropriate heights to create a proper plane for the framework fabrication were placed with the appropriate abutment wrench.



FIGURES 1-5. FIGURE 1. Preoperative radiograph of a patient to be treated with root-form implants. FIGURE 2. Three-dimensional model of mandible obtained with computerized tomography scan data. FIGURE 3. Occlusal view of an irregular mandibular edentulous ridge. FIGURE 4. Occlusal view of the properly spaced root-form implants in position. FIGURE 5. Intraoral view of the bar pattern fabrication during surgery.

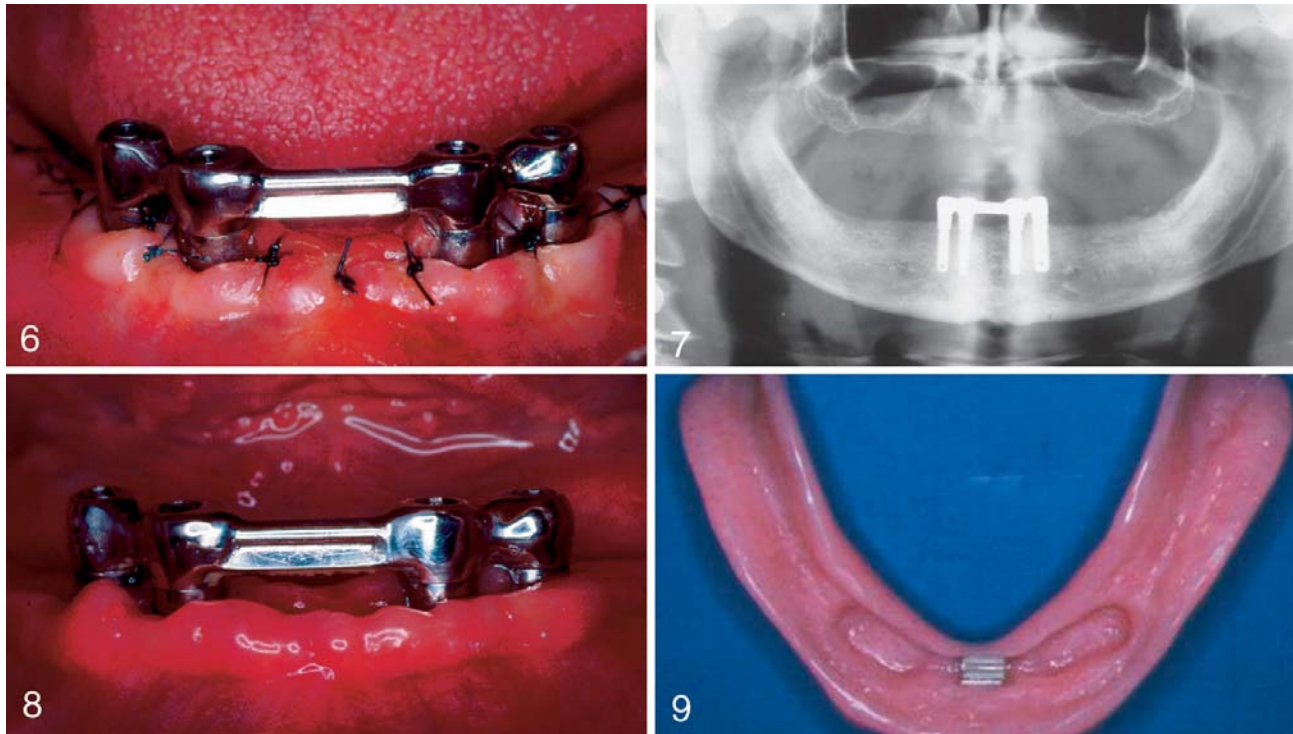
The tops of the transmucosal abutments should follow the anterior occlusal plane of the maxillary complete denture. The recommended torque for the abutments should not be attempted, because this might cause the implant to thread into a deeper level.

Plastic bridge copings were roughened to create a retentive surface and were placed on top of the transmucosal abutments. The

flap was then preliminarily closed with Gore-Tex sutures (3i/WL Gore, Newark, Del). English-Donnelle-Staubi (EDS) plastic bars (Attachments International, San Mateo, Calif) were prepared to the proper lengths and placed between the plastic bridge copings. The bar and the bridge copings were joined with autopolymerizing acrylic resin (GC Pattern Resin, Alsip, Ill). The

anterior bar should be parallel to the occlusal plane of the maxillary complete denture and perpendicular to the line bisecting the mandible (Figure 5).

The resin pattern was left to set intraorally for approximately 20 minutes. It was then removed and transferred to the laboratory, where the metal framework was fabricated in type IV gold alloy (Monogram IV, Leach & Dillon,



FIGURES 6–9. FIGURES 6–7. Intraoral photograph and panoramic radiograph taken immediately after bar insertion 24 hours postsurgery. FIGURE 8. Intraoral photograph taken 2 weeks after surgery. FIGURE 9. Inner overdenture view with the Hader attachment retrofitted to the denture.

Cranston, RI). Meanwhile, the protective titanium healing caps were placed on the transmucosal abutments and the final flap closure was performed, leaving the healing caps exposed.

Amoxicillin 500 mg and ibuprofen (Motrin, Upjohn, Kalamazoo, Mich) 800 mg were prescribed for antibiotic coverage and pain control. The patient was instructed to use 0.12% chlorhexidine gluconate (Peridex, Procter & Gamble, Cincinnati, Ohio) twice a day for 2 weeks and to start brushing the bar regularly with an end-tufted brush (John O. Butler, Chicago, Ill) 1 week after the surgery. The patient was placed on a liquid diet for the next 2 weeks.

Postsurgical prosthodontic procedure for the root-form implant modality

The try-in of the metal framework was completed within 24 hours

after the surgery. After satisfactory fit and stability of the framework were verified both clinically and radiographically, the bar was placed in the patient's mouth (Figures 6 and 7). The patient did not wear the mandibular denture during the soft-tissue healing.

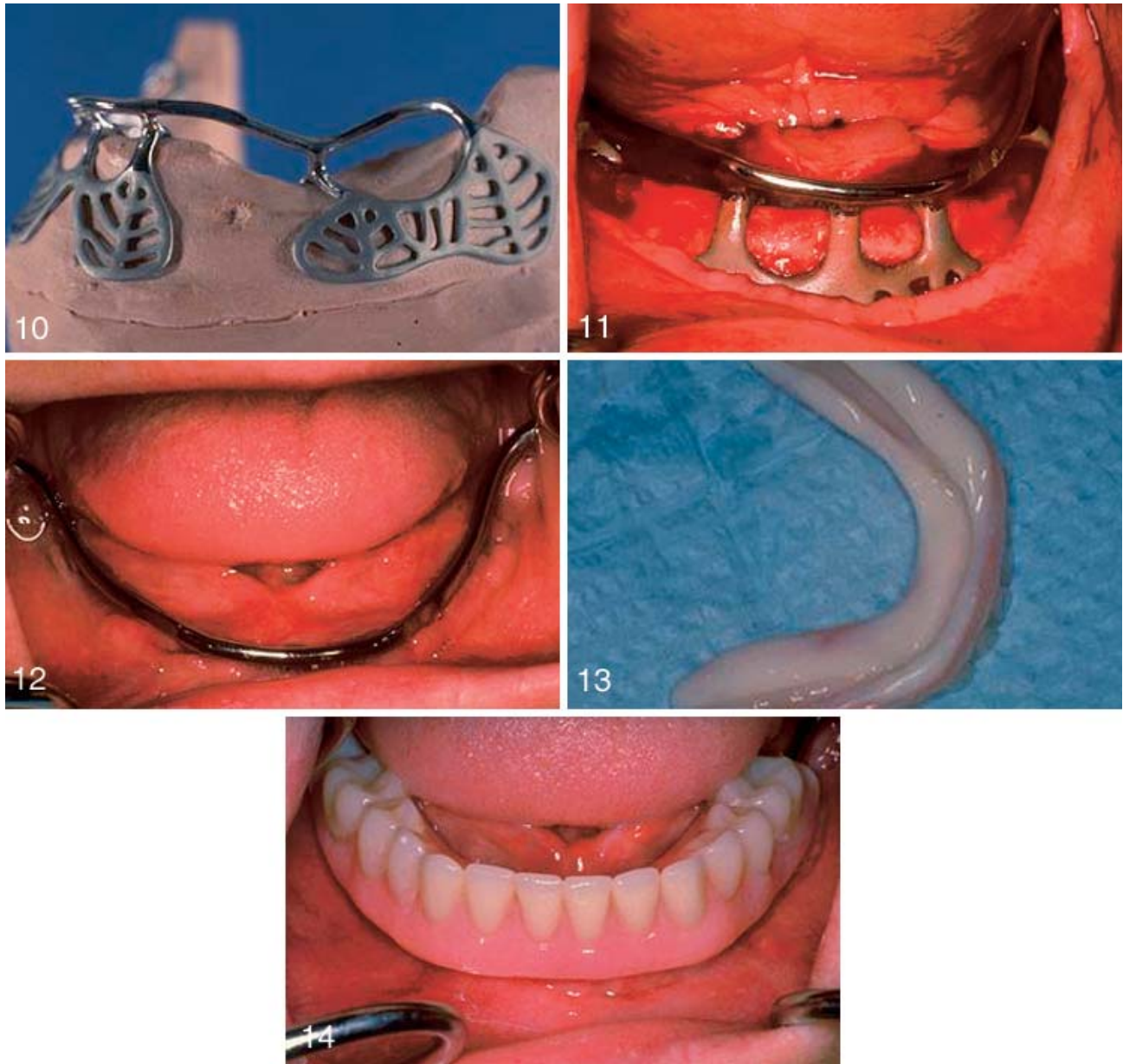
The sutures were removed 2 weeks after the surgery (Figure 8). The mandibular denture was relieved so that it was not touching the bar when placed in position. The pickup impression of the bar was made with the mandibular denture with polyvinyl siloxane impression material (Reprosil, Dentsply, York, Pa). The metal housing for the EDS clip (Attachments International) was incorporated during the relining of the mandibular overdenture. After tissue surface adjustment, the EDS clip was placed in the metal housing. Clinical remount was performed, and occlusion was adjusted for bilaterally balanced

occlusion. Afterward, the final prostheses were placed in the patient's mouth (Figure 9). Oral hygiene instructions were reinforced. Although no food restriction was imposed, the patient was recommended to follow a soft diet for the first 2 to 3 weeks after prosthesis placement.

The patient was asked to return the next day for a post-insertion check and any necessary adjustments. Follow-ups were scheduled at 1, 3, and 6 months after prosthesis placement and every 6 months thereafter.

Surgical procedure for the subperiosteal implant modality

After the protocol outlined by Truitt et al¹⁷ for the morphological replication of mandibles by using 3-dimensional (3-D) modeling and sterelithoradiography, subperiosteal implants were designed and fabricated from surgical-grade Vitallium (How-



FIGURES 10–14. FIGURE 10. Subperiosteal implant seated on 3-dimensional cast. Note design features. FIGURE 11. Intraoperative photograph of implant placement before suturing. FIGURE 12. Postoperative view. Notice satisfactory tissue healing. FIGURE 13. Preexisting denture showing the flanges removed and relined for immediate insertion after surgery. FIGURE 14. Modified immediate completely implant-supported overdenture inserted minutes after surgery.

medica, Kalamazoo, Mich) (27% chrome, 66% cobalt, 7% molybdenum) and coated with hydroxyapatite (HA). They were also fabricated in 1 piece with the continuous intraoral bar in place as part of the implant at the time of insertion (Figure 10). The intraoral incisions were made from the right retromolar pad and

extended along the crest of the ridge to the contralateral retromolar pad. By using periosteal elevators, the mucoperiosteum was reflected from the bone, both buccally and lingually; the mental foramina were identified; and the dissection was completed with minimal trauma to the neurovascular bundles. During implan-

tation, the tissues were carefully retracted with nylon-covered instruments to prevent transfer of metal to the passivated or HA-coated implant. When the implants were fully seated, the approximation of bone to metal was noted and recorded, and any discrepancies were then filled with an appropriate graft

material. The tissues were closed with 4-0 vicryl sutures (Figures 11 and 12).

Postsurgical prosthodontic procedure for the subperiosteal implant modality

Immediately after implant placement and complete closure, the patient's existing denture was modified and adapted for use as a transitional denture. The denture modification consisted of removal of a portion of the buccal and lingual flanges of the denture and the relining of the same denture at the correct vertical dimension of occlusion (Figures 13 and 14).

The modified denture was subsequently adapted and relined, thereby increasing its retention and function for 2 months before the final prosthesis was fabricated.

For the final mandibular overdenture, record bases were made at the time of implant fabrication, which accurately fit on the intraoral bar. These record bases facilitated the intraoral bar and border molding impressions and were also used to obtain the interocclusal records. The record bases had Dolder clips (Attachments International) added to them for retention purposes. Once the interocclusal records were obtained, the subsequent steps involved conventional denture fabrication procedures.

DISCUSSION

Surgical and prosthodontic rationale of the root-form and subperiosteal implant modality

Recently, clinical studies have reported comparably high implant success rates (85%–100%) in immediate loading in patients

who were completely edentulous.^{7,18–24} Peri-implant bone response of the immediately loaded implants is also favorable and comparable with that of conventional delayed-loading implants.²⁴ It is difficult to compare subperiosteal implant overdentures with root-form implant overdentures; however, some elements are common and can be the bases for evaluation of these modalities.

Bone Quality

Root-form implants. Dense trabecular bone provides better intimacy of initial fit and implant-bone contact area, which translates to better primary stability.^{25–27} It has also been documented that implant failure rates in type IV bone are significantly higher than in type I to III bone.^{28–30} In addition, Schnitman et al²¹ reported that 3 of 4 failed immediately loaded implants were placed distal to the mental foramen, where the bone quality is inferior to the symphysis area.

Subperiosteal implants. No comparative studies have reported the success rate of subperiosteal implants among the different bone types; however, some anecdotal reports describe significantly higher failure rates in the maxilla than in the mandible.

Bone Quantity

Root-form implants. Bone quantity dictates the implant diameter and length. Wider-diameter or longer implants provide greater surface area for initial bone-implant contact as well as for osseointegration. Positive correlation has been established between implant diameter or length and the removal torque or push-out force values.^{31–33} Higher implant

failures for short implants (≤ 10 mm) were also reported in both immediate^{21,22} (??) and delayed loadings.^{30,34–36} Although immediate loading of wide-diameter implants has not been reported, it should be considered when available bone permits the placement of such implants.

Subperiosteal implants. The authors of this article have limited the application of the subperiosteal implant to the severely atrophic mandible. Considering the arguments against the use of short endosseous implants, class D according to Misch,¹³ mandibles can successfully be treated with subperiosteal implants without bone grafting. The authors have achieved positive results in the treatment of severely atrophic mandibles.

Implant Geometry

Root-form implants. Threaded implants should be used in immediate loading situations because they provide the strongest immediate mechanical retention after placement.³⁷

Subperiosteal implants. The design according to James has the only documented evidence about the benefits of the lateral support vs the designs with support from only the crest of the ridge. Since 1983, the authors of the current paper have exclusively used the avowed design. The implant, in general, uses maximum support for the body of the mandible and is HA coated.

Implant Surface Characteristics

Root-form implants. Although no significant differences have been in the implant success rates between smooth and rough implant surfaces, recent literature seems to favor a rough surface in achieving a greater magnitude and faster rate of osseointegration.

tion.^{38–41} Therefore, in immediate loading situations where maximum magnitude and rate of osseointegration are desired, implants with surface treatments should be considered.

Subperiosteal implants. Human histology has demonstrated the benefits of HA-coated subperiosteal implants. Positive correlation has been found in the quality of survival between the coated and the noncoated subperiosteal implants.⁴²

Bicortication

Root-form implants. Engaging both the superior and the inferior cortical bone significantly increases the implant stability and the removal torque.⁴³ In addition, Chiapasco et al²³ found no correlation between the implant length and the success rates as long as there was bicortical stabilization. Bicortical initial stabilization could also be enhanced by minimal countersinking.²⁰

It has been frequently stated that implant surgery is prosthetically driven; this is especially true in an immediate loading situation. The final prostheses dictate implant position, angulation, number, and distribution as well as bar length and orientation. The interarch distance and the attachment systems dictate the depth at which the implants are placed. Therefore, fabrication of the final prostheses before implant surgery is very important. The use of the maxillary complete denture and surgical template is very essential during implant surgery. The maxillary complete denture is used to locate the midline, as a guide for mesiodistal implant angulation and implant level, and as a guide for horizontal bar orientation. The surgical template is used to evaluate the clearance for the attachment system, confine the implant

positions, guide buccolingual implant orientation, and guide sagittal bar orientation.

Attachment Systems

The attachment system used in immediate loading situations should involve prompt, rigid splinting of the implants. Lum et al⁴² showed that direct bone-implant interface was achieved when immediately loading HA-coated blade-form implants with rigid fixation to a firm natural tooth. Babbush et al⁷ also showed, in the immediate loading study, that apart from infection, failure was related to delayed application of a rigid splinting bar. The authors of the current paper have also previously reported on the recommended guidelines for immediate functional load, which include the immediate rigid splinting bar placed in the patient's mouth within 24 hours after surgery.⁴⁴ In this report, and in the case of the root-form implant modality, the EDS bar-and-clip system was used and the rigid splinting bar was placed in the patient's mouth within the same period after the implant surgery. The Dolder bar-and-clip system has been used since 1984 for the subperiosteal implant modality. During the fabrication of the subperiosteal implant, the intraoral bar is incorporated to the wax pattern and corresponds to the same bar dimensions of the Dolder system.

Bar Length and Orientation

Root-form implants. The bar orientation should be parallel to the arbitrary transverse horizontal axis horizontally and sagittally.^{45,46} Because the plastic bar pattern is fabricated at the time of surgery, the bar cannot be aligned parallel to the condylar components in the articulator. However,

the anterior occlusal plane of the maxillary complete denture and the surgical template can be used as the guides for horizontal and sagittal bar orientations, respectively. The bar should be parallel to the anterior occlusal plane of the maxillary complete denture and perpendicular to the line connecting the lingual frenum and the midline of the surgical template.

Improper bar length can cause unfavorable force distribution, which may lead to peri-implant bone resorption.⁴⁷ The optimal bar length has been postulated as 18 to 23 mm, which corresponds to a distance of 22 to 27 mm between the centers of the implants.⁴⁷ Nevertheless, this bar length may not be routinely achieved because of anatomic limitations such as the arch form and the location of the mental foramen.

Subperiosteal implants. The location of the intraoral bar for subperiosteal implants is based on the evaluation of the CT scan data in relation to the radiographic templates. The intraoral bar is traced on the 3-D generated model of the mandible following specific guidelines. The radiopaque material present in the radiographic template aids in the location of the transmucosal posts that interconnect the intraoral bar. The main advantage of this modality is that the bar is an integral part of the implant; it is attached to it from the time of insertion and, in essence, is ready to receive a transitional overdenture immediately after surgery.

Implant Number and Distribution

Root-form implants. Although the implant success rates of mandibular overdentures supported by 2 and 4 conventionally loaded implants were not different,^{4,48–50}

Rangert et al⁵¹ suggested that load transferred to individual implants could vary because of the number of the implants and their positions. They have shown that when implants are in line (usually in situations with 2 implants), the bending moment encountered is higher than when the implants are in configurations (eg, tripod or quadrilateral) that create offsets. In immediate loading situations, excessive load in any direction can be detrimental. To provide the offset configuration as well as to allow anterior bar orientation to be parallel to the transverse horizontal axis, 4 implants may be the ideal minimum number.

Implant Position and Angulation

Root-form implants. The implants should be placed within the confines of the surgical template. To avoid any neurovascular injury, the posterior implants are placed approximately 5 mm anterior to the mental foramina. The anterior implants are positioned so that the optimal bar length is achieved without encroaching into the tongue space, and the distance between the centers of the anterior and posterior implants is at least 7 mm for hygiene purposes. During implant placement, the implant angulation should be perpendicular to the occlusal plane to avoid any undue overloading.⁵² The maxillary complete denture and surgical template can be used as guides for mesodistal and buccolingual implant angulation, respectively.

Subperiosteal implants. The location of the implant posts as well as the height of the bar in relation of to the crest of the ridge is "prosthetically driven," and, specifically, the implant designs used in this report were done according to the concepts outlined by James et al.¹⁰

Clinical Outcomes

Root-form implants. Following the described protocol, which was approved by the Institutional Review Board of Loma Linda University, a prospective study was conducted on 5 patients.²⁴ Twenty implants were placed, and all remained successfully osseointegrated after 1 year of loading. The mean marginal bone loss was 1.16 mm at 12 months.²⁴

Although no major complications or loss of osseointegration were encountered, a precautionary measure should be taken. In the case of early failures (less than 3 months after the implant placement surgery) of 1 or more implants, it is recommended that the unaffected implants be left unloaded until they are fully integrated for subsequent restoration in the conventional manner. If the remaining implants are not adequate for supporting a mandibular overdenture, more implants should be implemented accordingly. The patient must be informed of such a possibility before the treatment.

The advantages of immediately functional loaded implant prostheses include the shorter treatment time and the elimination of the provisional stage as well as the second-stage surgery. This article describes the surgical and prosthodontic procedure of the immediately loaded mandibular implant bar overdenture along with its clinical rationale. Although the high implant success rates reported with this treatment modality might suggest that it is a viable and predictable treatment option, careful patient selection and treatment planning are still as important as or even more important than the treatment itself.

Achieving primary stability and maximizing the magnitude

and the rate of osseointegration seem to be the key elements in achieving and maintaining osseointegration in such situations.

Subperiosteal implants. Following the described protocol, which was approved by the Institutional Review Board of Loma Linda University, a retrospective study (unpublished thesis) was conducted on the last 5 patients treated with superosteal implants from June 1995 to June 2000 who had immediate overdentures in function for at least 3 years. After 1 year of loading, all 5 implants that were placed have successfully provided immediate functional load since the day of the surgery. Bone loss around subperiosteal dental implants is often difficult to measure because of the metal superimposition from the implant struts. Radiographs were taken of each implant post at implant placement and at 3-, 6-, 9-, and 12-month intervals. The detectable mean marginal bone loss was 1.2 mm at 1 year.

No major complications or loss of implants occurred; however, some observations are in order. It must be emphasized as reported previously that many of these implants required "minor corrective" soft-tissue surgery. In this particular report, 3 of the 5 implants placed required corrective surgery.

CONCLUSIONS

The surgical and prosthodontic procedures for the immediately functional loaded mandibular implant overdentures described in this article demonstrate the differences between the 2 modalities. The subperiosteal implant modality provides an overdenture that is supported by the implant in its entirety. The technique appears to be highly sensitive and, apart

from the information presented here, lacks documented reproducible data. The root-form implant overdenture modality uses the retention given by the implant bar-and-clip system and partial support given by the edentulous ridge. The technique is simpler and has been reproduced and reported by other clinicians. Within the limitations of this article, both techniques achieve the goal of providing predictable immediate function after surgery.

REFERENCES

1. Adell R, Eriksson B, Lekholm U, Brånemark P-I, Jemt T. A long-term follow-up study of osseointegrated implants in the treatment of totally edentulous jaws. *Int J Oral Maxillofac Implants.* 1990;5:347-359.
2. Naert I, Quirynen M, van Steenberghe D. A six-year prosthodontic study of 509 consecutively inserted implants for the treatment of partial edentulism. *J Prosthet Dent.* 1992;67:236-245.
3. Andersson B, Ödman P, Lindvall AM. Single tooth restorations supported by osseointegrated implants: results and experiences from a prospective study after 2 to 3 years. *Int J Oral Maxillofac Implants.* 1995;10:702-711.
4. Jemt T, Chai J, Harnett J, et al. A 5-year prospective multicenter follow-up report on overdentures supported by osseointegrated implants. *Int J Oral Maxillofac Implants.* 1996;11:291-298.
5. Albrektsson T, Brånemark P-I, Hansson HA, Lindstrom J. Osseointegrated titanium implants. Requirements for ensuring a long-lasting, direct bone-to-implant anchorage in man. *Acta Orthop Scand.* 1982;52:155-170.
6. Brånemark P-I. Osseointegration and its experimental background. *J Prosthet Dent.* 1983;50:399-410.
7. Babbush CA, Kent JN, Misiek DJ. Titanium plasma sprayed (TPS) screw implants for the reconstruction of the edentulous mandible. *J Oral Maxillofac Surg.* 1986;44:274-282.
8. Schnitman PA, Shulman LB. *Dental Implants: Benefit and Risk.* NIH Harvard Consensus Development Conference, US Dept of Health and Human Sciences; 1980. Publication 81:1531.
9. James RA. Subperiosteal implant design based on peri-implant tissue behavior. *NYJD.* 1983;53:407-413.
10. James RA, Lozada JL, Truit PH, Foust BE, Jovanovic SA. Subperiosteal implants. *J Calif Dent Assoc.* January 1988;10-14.
11. Minichetti JC. Analysis of HA-coated subperiosteal implants. *J Oral Implantol.* 2003;3:111-116.
12. Lekholm U, Zarb GA. Patient selection and preparation. In: Brånemark P-I, Zarb GA, Albrektsson T, eds. *Tissue-Integrated Prostheses. Osseointegration in Clinical Dentistry.* Chicago, Ill: Quintessence; 1985:199-210.
13. Misch CE. *Contemporary Implant Dentistry.* 2nd ed. St Louis, Mo: Mosby; 1999:94-106.
14. James RA, Lozada JL, Truitt HP. Computer tomography (CT) applications in implant dentistry. *J Oral Implantol.* 1991;17:10-15.
15. Tardieu PB, Vrielinck L, Escolano E. Computer-assisted implant placement. A case report: treatment of the mandible. *J Oral Maxillofac Implants.* 2003;18:599-604.
16. Sarment DP, Al-Shammari K, Kazor CE. Stereolithographic surgical templates for placement of dental implants in complex cases. *Int J Periodont Restor Dent.* 2003;23:287-295.
17. Truit HP, James RA, Altman A, Boyne P. Use of computer tomography in subperiosteal implant therapy. *J Prosthet Dent.* 1988;59:474-477.
18. Buser DA, Shroeder A, Sutter F, Lang NP. The new concept of ITI hollow-cylinder and hollow-screw implants. Part 2. Clinical aspects, indications, and early clinical results. *Int J Oral Maxillofac Implants.* 1988;3:173-181.
19. Schnitman PA, Wohrle PS, Rubenstein JE. Immediate fixed interim prostheses supported by two-stage threaded implants. Methodology and results. *J Oral Implantol.* 1990;16:96-105.
20. Salama H, Rose LF, Salama M, Betts NJ. Immediate loading of bilaterally splinted titanium root-form implants in fixed prosthodontics—a technique reexamined: two case reports. *Int J Periodont Restor Dent.* 1995;15:345-361.
21. Schnitman PA, Wohrle PS, Rubenstein JE, DaSilva JD, Wang NH. Ten-year results for Brånemark implants immediately loaded with fixed prostheses at implant placement. *Int J Oral Maxillofac Implants.* 1997;12:495-503.
22. Tarnow DP, Emtiaz S, Classi A. Immediate loading of threaded implants at stage 1 surgery in surgery in edentulous arches: ten consecutive case reports with 1- to 5-year data. *Int J Oral Maxillofac Implants.* 1997;12:319-324.
23. Chiapasco M, Gatti C, Rossi E, Haefliger W, Markwalder TH. MImplant retained mandibular overdentures with immediate loading. *Clin Oral Implants Res.* 1997;8:48-57.
24. Rungcharassaeng K, Lozada JL, Kan JYK, Campagni WV, Munoz CA. Marginal bone change around immediately loaded threaded HA-coated implants: one-year results. Paper presented at: 14th Annual Meeting of the Academy of Osseointegration; March 4-6, 1999; Palm Springs, Calif.
25. Truhlar RS, Lauciello F, Morris HF, Ochi S. The influence of bone quality on periosteal values of endosseous dental implants at stage II surgery. *J Oral Maxillofac Surg.* 1997;55:55-61.
26. Tricio J, van Steenberghe D, Rosenberg D, Duchateau L. Implant stability related to insertion torque force and bone density; an in vitro study. *J Prosthet Dent.* 1995;74:608-612.
27. Misch CE. Density of bone: effect on treatment plans, surgical approach, healing, and progressive bone loading. *Int J Oral Implantol.* 1990;6:23-31.
28. Jaffin RA, Berman CL. The excessive loss of Branemark fixtures in type IV bone: a five year analysis. *J Periodontol.* 1991;62:2-4.
29. Engquist B, Bergendal T, Kallus T, Linden U. A retrospective multicenter evaluation of osseointegrated implants supporting overdentures. *Int J Oral Maxillofac Implants.* 1988;3:129-134.
30. Goodacre CJ, Kan JYK, Rungcharassaeng K. Clinical complications of osseointegrated implants. *J Prosthet Dent.* 1999;81:537-552.
31. Ivanoff CJ, Sennerby L, Johanson C, Rangert B, Lekholm U. Influence of implant diameters on the integration of screw implants. An experimental study in rabbits. *Int J Oral Maxillofac Surg.* 1997;26:141-148.
32. Ochi S, Morris HF, Winkler S. The influence of implant type, material, coating, diameter, and length on periosteal values at second-stage surgery: DICRG interim report no. 4. Dental Implant Clinical Research Group. *Implant Dent.* 1994;3:159-162.
33. Block MS, Delgado A, Fontenot MG. The effect of diameter and length of hydroxylapatite-coated dental implants on ultimate pullout force in dog alveolar bone. *J Oral Maxillofac Surg.* 1990;48:174-178.
34. Gunne J, Jemt T, Linden B. Implant treatment in partially edentulous patients: a report on prostheses after 3 years. *Int J Prosthodont.* 1994;7:143-148.
35. Friberg B, Jemt T, Lekholm U. Early failures in 4,641 consecutively placed Branemark dental implants:

a study from stage 1 surgery to the connection of completed prostheses. *Int J Oral Maxillofac Implants*. 1991;6:142-146.

36. Jemt T, Lekholm U. Implant treatment in edentulous maxillae: a 5-year follow-up report on patients with different degrees of jaw resorption. *Int J Oral Maxillofac Implants*. 1995;10:303-310.

37. Brunski JB. Biomechanical factors affecting the bone-dental implant interface [review paper]. *Clin Mater*. 1992;10:153-201.

38. Buser D, Nydegger T, Hirt HP, Cochran DL, Nolte LP. Removal torque value of titanium implants in the maxilla of miniature pigs. *Int J Oral Maxillofac Implants*. 1998;13:611-619.

39. Klokkevold PR, Nishimura RD, Adachi M, Caputo A. Osseointegration enhanced by chemical etching of the titanium surface. A torque removal study in the rabbit. *Clin Oral Implants Res*. 1997;8:442-447.

40. Wennerberg A, Ektessabi A, Alkerktson T, Johansson C, Andersson B. A 1-year follow-up of implants of differing surface roughness placed in rabbit bone. *Int J Oral Maxillofac Implants*. 1997;12:486-494.

41. Wong M, Eulenberger J, Schenk R, Hunziker E. Effect of surface topology on the osseointegration of implant materials in trabecular bone. *J Biomed Mater Res*. 1995;29:1567-1575.

42. Lum LB, Beirne OR, Curtis DA. Histologic evaluation of hydroxyapatite-coated versus uncoated titanium blade implants in delayed and immediately loaded applications. *Int J Oral Maxillofac Implants*. 1991;6:456-462.

43. Ivanoff CJ, Sennerby L, Lekholm U. Influence of mono-and bicortical anchorage on the integration of titanium implants. A study in the rabbit tibia. *Int J Oral Maxillofac Surg*. 1996;2:229-235.

44. Babbush CA. Titanium plasma spray screw implant system for reconstruction of the edentulous mandible. *Dent Clin North Am*. 1986;30:117-131.

45. Zarb GA, Bolender CL, Carlsson GE. *Boucher's Prosthodontic Treatment for Edentulous Patients*. 11th ed. St Louis, Mo: Mosby; 1997:522-523.

46. Spiekermann H, Donath K, Hasel T, Jovanovic S, Richter J. *Implantology*. New York, NY: Thieme Medical; 1995:152-159.

47. Hertel RC, Kalk W. Influence of the dimensions of implant superstructure

on peri-implant bone loss. *Int J Prosthodont*. 1993;6:18-24.

48. Cune MS, de Putter C, Hoogstraten J. Treatment outcome with implant-retained overdenture: part I—clinical findings and predictability of clinical treatment outcome. *J Prosthet Dent*. 1994;72:144-151.

49. Leimola-Virtanen R, Peltola J, Oksana E, Helenius H, Happonen RP. ITI titanium plasma-sprayed screw implants in the treatment of edentulous mandibles: a follow-up study of 39 patients. *Int J Oral Maxillofac Implants*. 1995;10:595-603.

50. Wismeyer D, van Waas MAJ, Vermeeren JJJF. Overdentures supported by ITI implants: a 6.5-year evaluation of patient satisfaction and prosthetic aftercare. *Int J Oral Maxillofac Implants*. 1995;10:744-749.

51. Rangert BR, Sullivan RM, Jemt TM. Load factor control for implants in the posterior partially edentulous segment. *Int J Oral Maxillofac Implants*. 1997;12:360-370.

52. Weinberg LA, Kruger B. A comparison of implant/prosthesis loading with four clinical variables. *Int J Prosthodont*. 1995;8:421-433.