

# Long-term stability of maxillary protraction therapy in Class III patients with complete unilateral cleft lip and palate

Yixin Zhang<sup>a</sup>; Zhen Fu<sup>b</sup>; Haichao Jia<sup>c</sup>; Yiping Huang<sup>d</sup>; Xiaobei Li<sup>e</sup>; Hao Liu<sup>e</sup>; Weiran Li<sup>f</sup>

## ABSTRACT

**Objectives:** This study evaluated the long-term stability of maxillary protraction (MP) in patients with complete unilateral cleft lip and palate (UCLP) and identified factors influencing relapse and long-term outcomes.

**Materials and Methods:** Twenty-three adolescents with UCLP who underwent MP therapy were recalled when craniofacial growth was close to completion. Subjects exhibiting reverse/positive overjets were assigned to unstable/stable groups. Lateral cephalometric measurements were made before treatment (T0), after active treatment (T1), and at the end of the growth spurt (T2).

**Results:** About 63% of the subjects exhibited positive overjets during follow-up. The unstable group demonstrated higher B-x and Co-Gn distances than the stable group (both  $P < .05$ ) at T0. More short-term (T0-T1) sagittal advancement of point A (A-y) was evident in the unstable group than in the stable group ( $P < .05$ ), but no long-term difference was apparent between the two groups ( $P = .481$ ). During the posttreatment period (T1-T2), the SNA angle and maxillary incisor protrusion (U1-SN angle) were considerably lower in the unstable group than in the stable group (both  $P < .05$ ). Overall, the unstable group exhibited a lower increase in the vertical extent of point A (A-x) than the stable group from T0 to T2 ( $P < .05$ ).

**Conclusions:** In the long term, MP affords favorable maxillary advancement in patients with UCLP. A mandibular excess at T0 and vertical maxillary hypoplasia may contribute to the long-term relapse of a reverse overjet. (*Angle Orthod.* 2019;89:214-220.)

**KEY WORDS:** Maxillary protraction; Unilateral complete cleft lip and palate; Skeletal Class III malocclusion; Long-term stability

<sup>a</sup> PhD candidate, Department of Orthodontics, Peking University School and Hospital of Stomatology, Beijing, P.R. China.

<sup>b</sup> Attending Doctor, Department of Orthodontics, Affiliated Hospital of Stomatology, School of Medicine, Zhejiang University, Hangzhou, P.R. China.

<sup>c</sup> Clinical Professor, Department of Orthodontics, School of Stomatology, Capital Medical University, Beijing, P.R. China.

<sup>d</sup> Resident, Department of Orthodontics, Peking University School and Hospital of Stomatology, Beijing, P.R. China.

<sup>e</sup> Graduate student, Department of Orthodontics, Peking University School and Hospital of Stomatology, Beijing, P.R. China.

<sup>f</sup> Professor and Department Chair, Department of Orthodontics, Peking University School and Hospital of Stomatology, Beijing, P.R. China.

Corresponding author: Dr Weiran Li, Department of Orthodontics, Peking University School and Hospital of Stomatology, 22 Zhongguancun South Avenue, Haidian District, Beijing 100081, P.R. China (e-mail: weiranli2003@163.com)

Accepted: October 2018. Submitted: July 2018.

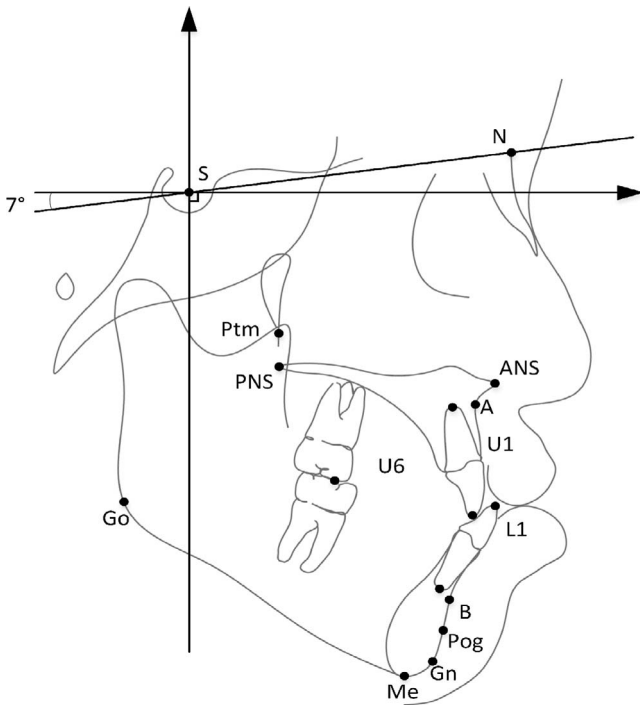
Published Online: November 28, 2018

© 2019 by The EH Angle Education and Research Foundation, Inc.

## INTRODUCTION

Almost 70% of adolescents with unilateral complete cleft lip and palate (UCLP) exhibit skeletal Class III malocclusion caused by maxillary retrusion,<sup>1,2</sup> triggering functional, esthetic, and psychological problems. Many studies have shown that favorable skeletal relationships are evident immediately after active maxillary protraction (MP) in growing patients with UCLP.<sup>3,4</sup> However, such adolescents remain in active growth, and reversion to the Class III relationship may occur after growth is complete.<sup>5</sup> Thus, the long-term stability of MP in patients with UCLP warrants attention.

Previous studies found that relapse to a reverse overjet occurred in 24% to 33% of MP-treated patients without cleft.<sup>6-9</sup> A large gonial angle, a steep mandibular plane, a large mandibular body and/or ramus, an increased posterior facial height, and an acute cranial base angle were predictors of unfavorable prognoses.<sup>8,10-12</sup> Compared with a successful group before MP, Choi et al.<sup>8</sup> found that an unsuccessfully treated group exhibited more horizontal displacement of points A and



**Figure 1.** Landmarks.

B and pogonion, lower Wits appraisal values, greater anterior facial heights, and smaller articular angles.

The outcomes of MP for patients with UCLP may differ from those for patients without cleft because patients with UCLP exhibit cleft-related maxillary deformities and palatal scar tissues.<sup>5,13</sup> To date, only a single study has explored the long-term effects of MP in patients with UCLP.<sup>5</sup> Such patients exhibited considerable variations in facial growth to the time of growth completion. However, only 11 subjects were enrolled and some had extremely severe skeletal problems. No study has yet compared the stable and unstable subjects after follow-up or identified factors affecting relapse and long-term MP outcomes. Thus, predictive factors for long-term stability of MP therapy in patients with UCLP after their adolescent growth spurt were identified in this study.

## MATERIALS AND METHODS

### Study Design and Participants

This retrospective cohort study complied with all relevant tenets of the Declaration of Helsinki and was approved by the Institutional Review Board of Peking University Hospital of Stomatology. All participants gave written informed consent. The records of 23 patients (16 boys and 7 girls) with UCLP who underwent MP therapy between 2009 and 2013 at the Cleft Lip and Palate Centre of Peking University Hospital of Stomatology were collected. Patients were

asked to record their height every 3 months and were followed up annually. When the annual increase in height fell to  $<2$  mm, dental models and lateral cephalography were performed. Patients who retained positive overjet were assigned to the stable group, and those exhibiting relapse to a negative overjet were assigned to the unstable group.<sup>6</sup> Primary cheiloplasty had been performed using the modified Millard technique at 3–6 months of age. The modified von Langenbeck method was applied at 8–10 months of age. Alveolar bone grafting was performed at the age of 9–11 years, before MP therapy. The inclusion criteria were an operated nonsyndromic UCLP, an anterior crossbite with an ANB angle between  $-4^\circ$  and  $0^\circ$  before MP (T0),<sup>13,14</sup> cervical vertebral maturation stage (CVMS) I–II at T0 ( $10.7 \pm 1.1$  years), bone grafting of Bergland scale type I or II,<sup>15</sup> consecutive and successful active MP treatment (creating a positive overjet at T1), and a CVMS of stage IV–V after recall (T2:  $16.1 \pm 1.6$  years).<sup>16</sup> Subjects with additional congenital anomalies or temporomandibular disorders were excluded. Four boys were excluded because of a loss of contact ( $n = 1$ ), failure to achieve a clinically normal overjet after MP therapy ( $n = 1$ ), and continuation of the growth spurt ( $n = 2$ ). Thus, 19 patients (12 boys and 7 girls) were enrolled. The durations of protraction and follow-up were  $1.8 \pm 0.8$  and  $3.5 \pm 1.4$  years, respectively.

### MP Treatment Protocol

All patients were treated by a single orthodontist (W.L.) using a standard protocol. A Hyrax appliance was attached to the upper first molars and premolars/deciduous molars. A bite block was placed in the lower arch to eliminate incisor interference. Patients were instructed to wear the facemask for at least 12 h/d. The elastic force (450–500 g per side) from the canine region was oriented downward and forward to the occlusal plane. Facemask therapy was discontinued after a positive anterior overjet was obtained and posterior occlusal stability achieved.

### Cephalometric Analysis

Lateral cephalograms were taken before MP treatment (T0), after active treatment (T1), and at the time of recall (T2) using the same cephalostat (in centric occlusion) for all patients. Cephalometric analyses were performed with the aid of Dolphin software (version 11.7; Dolphin Imaging & Management Solutions, Chatsworth, Calif). A horizontal reference plane drawn at  $7^\circ$  clockwise from the sella–nasion line (at sella) served as the x-axis, and a vertical line drawn perpendicular to the x-axis through point S as the y-axis (Figure 1). Sixteen dentoskeletal variables were

**Table 1.** Definitions of Cephalometric Variables

Variables	Definitions
<b>Maxillary</b>	
SNA (°)	Angle between A point and sella at nasion
A-y (mm)	Horizontal distance from point A to a plane drawn perpendicularly to SN-7° plane (a horizontal plane angulated 7° clockwise to the SN plane) at S point
A-x (mm)	Vertical distance from point A to SN-7° plane (a horizontal plane angulated 7° clockwise to the SN plane)
Ptm-A/PP (mm)	Distance between A point and Ptm projected on the PP plane (palatal plane), respectively
SN/PP (°)	Angle between the SN plane and PP plane (palatal plane)
<b>Mandibular</b>	
SNB (°)	Angle between B point and sella at nasion
B-y (mm)	Horizontal distance from point B to a plane drawn perpendicularly to SN-7° plane (a horizontal plane angulated 7° clockwise to the SN plane) at S point
B-x (mm)	Vertical distance from point B to SN-7° plane (a horizontal plane angulated 7° clockwise to the SN plane)
Co-Gn (mm)	Total mandibular length
MP-SN (°)	Angle between the mandibular plane and SN plane, representing the mandibular inclination
<b>Maxillomandibular</b>	
ANB (°)	Angle between A point and B point at nasion
Wits (mm)	Distance between the points of perpendiculars tracing from points A and B contact on the occlusal plane, indicating the relative position of maxilla and mandible anteroposteriorly
<b>Dental</b>	
U1-SN (°)	Angle between the long axis of the upper central incisor and the SN plane, determining the inclination of the central incisor relative to the anterior cranial base
IMPA (°)	Angle between the long axis of the lower central incisor and the mandibular plane, determining the axial inclination between the mandibular incisor and the inferior border of the mandible
Overjet (mm)	Distance between the maxillary anterior teeth ridges and the mandibular anterior teeth ridges in the anterior-posterior axis
Overbite (mm)	Distance between the maxillary anterior teeth ridges and the mandibular anterior teeth ridges in the vertical axis

selected for analysis (Table 1). All landmarks were traced by one investigator (Y.Z.) and confirmed by another investigator (X.L.). To assess intra-examiner reliability, the same investigator (Y.Z.) retraced and measured five randomly selected pairs of variables from each time point after a 2-week interval.

### Statistical Analysis

The one-sample Kolmogorov-Smirnov test was used to confirm the normality of all cephalometric measurements. Intragroup cephalometric values were compared between pairs of time points using the paired *t*-test. After implementing Levene's test of equality of variance, two-sample *t*-tests were used to compare age characteristics and cephalometric changes between the stable and unstable groups. Fisher's exact test was used to detect intergroup, sex distribution differences. SPSS software version 20.0 (IBM Corp, Armonk, NY) was used for all statistical analyses. A *P* value < .05 was considered to reflect statistical significance.

### RESULTS

The intraclass correlation coefficients ranged from 0.86 to 0.99, evidencing a high degree of reliability. After follow-up, 7 patients (5 boys, 2 girls) exhibiting relapse to an anterior crossbite were allocated to the unstable group, and 12 patients (7 boys, 5 girls) to the stable group. Thus, the stability rate was 63.2% (12 of

19 patients). The mean ages at all stages and the sex distributions were similar between the stable and unstable groups (all *P* > .05; Table 2).

### Cephalometric Values at T0, T1, and T2

The short-term, follow-up, and long-term results after MP therapy for all 19 patients are summarized in Table 3. The SNA angle increased significantly (2.8°) from T0 to T1, and then decreased by about 50% from T1 to T2. The sagittal advancement of point A (A-y) was 3.4 mm in the short-term and remained stable during follow-up. The maxillary length (Ptm-A/PP) increased by 1.6 mm after therapy and remained almost unchanged from T1 to T2. The vertical movement of point A (A-x) increased significantly to T1 and also during follow-up. The palatal plane angle decreased by 1.7° from T0 to T1 but relapsed at T2. The MP-SN angle increased significantly after MP therapy but relapsed to the initial value during follow-up. The overjet and the Wits value increased significantly with time. The extent of overbite decreased from T0 to T1 and then did not change from T1 to T2. Overall, both the upper and lower incisors showed proclination.

### Pretreatment Differences Between the Stable and Unstable Groups

Table 4 shows that the maxillary position (A-y, A-x) and length (Ptm-A/PP) were similar in both groups at

**Table 2.** Characteristics of Participants

	Total (n = 19)	Stable (n = 12)	Unstable (n = 7)	P
Sex (n, %)				
Male	12 (63.2%)	7 (58.3%)	5 (71.4%)	.656 <sup>c</sup>
Female	7 (36.8%)	5 (41.7%)	2 (28.6%)	
Age at T0 (y) <sup>a</sup>	10.7 ± 1.1	10.5 ± 1.3	11.1 ± 0.6	.214 <sup>b</sup>
Age at T1 (y) <sup>a</sup>	12.5 ± 1.4	12.4 ± 1.7	12.8 ± 0.7	.477 <sup>b</sup>
Age at T2 (y) <sup>a</sup>	16.1 ± 1.6	16.1 ± 1.7	16.0 ± 1.4	.846 <sup>b</sup>
Treatment duration from T0 to T1 (y)	1.8 ± 0.8	1.8 ± 1.0	1.7 ± 0.3	.640 <sup>b</sup>
Follow-up period from T1 to T2 (y)	3.5 ± 1.4	3.8 ± 1.5	3.2 ± 1.2	.416 <sup>b</sup>
Overall period from T0 to T2 (y)	5.3 ± 1.3	5.6 ± 1.3	4.9 ± 1.2	.254 <sup>b</sup>

<sup>a</sup> T0 indicates before treatment; T1, after the active treatment; T2, at the end of long-term follow-up.

<sup>b</sup> The age difference between the stable and unstable groups with two-sample *t*-test.

<sup>c</sup> Sex distribution difference between the stable and unstable group with Fisher exact test.

\* *P* < .05.

T0. However, the vertical distance of B point from the x-axis was significantly longer in the unstable than in the stable group (B–x, 83.54 ± 5.65 mm vs 79.15 ± 3.12 mm; *P* < .05). Also, mandibular length was greater in the unstable group (Co–Gn, 108.16 ± 5.29 mm vs 102.22 ± 5.27 mm; *P* < .05). Although statistical significance was not attained, the unstable group had a greater mandibular plane angle (MP–SN, 38.49 ± 6.26° vs 36.29 ± 6.37°; *P* = .476) and a lower ANB angle (ANB, –2.63 ± 0.69° vs –1.74 ± 1.26°; *P* = .064) at T0 than the stable group.

**Short-Term Differences Between the Stable and Unstable Groups**

Short-term (T0–T1) changes in the stable and unstable groups after MP therapy are shown in Table

5. Compared with the stable group, the unstable group exhibited more sagittal advancement of point A (A–y, 5.19 ± 2.86 mm vs 2.29 ± 2.72 mm; *P* < .05). No other difference was evident.

**Changes During Follow-Up Between the Stable and Unstable Groups**

As shown in Table 5, the unstable group exhibited about 0.67 mm backward movement from point A, whereas the stable group exhibited 1.18 mm of further advancement from T1 to T2. Moreover, the SNA angle decreased more in the unstable than in the stable group after treatment (–3.24 ± 1.49° vs –0.46 ± 2.33°; *P* < .05). During this period, remarkable decreases in the ANB angle, maxillary incisor protrusion (U1–SN),

**Table 3.** Cephalometric Analyses of All 19 Participants at T0, T1, and T2<sup>a</sup>

Variable	T0,	T1,	T2,	T1-T0		T2-T1		T2-T0		
	Mean (SD)	Mean (SD)	Mean (SD)	Mean (SD)	<i>P</i>	Mean (SD)	<i>P</i>	Mean (SD)	<i>P</i>	
<b>Maxillary</b>										
SNA (°)	74.56 (3.07)	77.34 (3.95)	75.86 (3.84)	2.78 (2.63)	<.001***	–1.48 (2.44)	.016*	1.30 (2.64)	.046*	
A-y (mm)	53.46 (4.58)	56.82 (4.98)	57.31 (5.64)	3.36 (3.05)	<.001***	0.49 (2.72)	.438	3.85 (3.01)	<.001***	
A-x (mm)	45.62 (2.31)	47.66 (3.27)	51.25 (2.59)	2.04 (2.11)	.001**	3.59 (3.12)	<.001***	5.63 (1.89)	<.001***	
Ptm-A/PP (mm)	38.34 (3.36)	39.95 (3.37)	40.23 (3.83)	1.62 (1.97)	.002**	0.27 (2.02)	.563	1.89 (2.40)	.003**	
SN/PP (°)	10.58 (2.32)	8.91 (3.31)	9.36 (2.97)	–1.68 (2.92)	.022*	0.46 (2.62)	.457	–1.22 (3.11)	.104	
<b>Mandibular</b>										
SNB (°)	76.85 (3.40)	75.84 (4.15)	77.20 (4.77)	–1.01 (2.14)	.054	1.36 (2.34)	.021*	0.35 (2.47)	.548	
B-y (mm)	51.63 (6.45)	50.49 (8.10)	55.00 (10.06)	–1.14 (4.08)	.238	4.51 (4.87)	.001**	3.37 (5.14)	.010*	
B-x (mm)	80.77 (4.61)	85.92 (5.27)	89.77 (4.81)	5.15 (3.52)	<.001***	3.85 (3.28)	<.001***	9.00 (3.83)	<.001***	
Co-Gn (mm)	104.41 (5.91)	108.76 (7.42)	116.44 (8.52)	4.36 (3.52)	<.001***	7.67 (4.70)	<.001***	12.03 (4.96)	<.001***	
MP-SN (°)	37.10 (6.25)	38.51 (6.96)	37.05 (7.28)	1.41 (2.42)	.021*	–1.46 (3.00)	.047*	–0.05 (2.58)	.930	
<b>Maxillomandibular</b>										
ANB (°)	–2.29 (1.15)	1.50 (1.82)	–1.34 (3.13)	3.79 (1.75)	<.001***	–2.84 (2.64)	<.001***	0.95 (2.74)	.247	
Wits (mm)	–4.29 (2.96)	0.41 (3.32)	–2.83 (3.82)	4.71 (2.88)	<.001***	–3.24 (2.99)	<.001***	1.47 (2.95)	.044*	
<b>Dental</b>										
U1-SN (°)	95.09 (4.92)	103.95 (6.72)	105.53 (5.79)	8.86 (5.85)	<.001***	1.58 (6.77)	.267	10.44 (5.77)	<.001***	
IMPA (°)	83.83 (6.98)	83.96 (6.97)	85.99 (5.63)	0.13 (3.89)	.327	2.03 (4.03)	.237	2.17 (3.78)	.038*	
Overjet (mm)	–3.52 (0.99)	2.13 (1.09)	–0.11 (2.67)	5.65 (1.43)	<.001***	–2.24 (2.64)	.003**	3.41 (2.40)	<.001***	
Overbite (mm)	3.18 (1.26)	0.88 (1.12)	0.71 (0.84)	–2.31 (1.77)	<.001***	–0.17 (1.22)	.717	–2.48 (1.69)	<.001***	

<sup>a</sup> T0 indicates before treatment; T1, after the active treatment; T2, at the end of long-term follow-up.

\* *P* < .05; \*\* *P* < .01; \*\*\* *P* < .001 according to paired Student *t* test.



**Table 4.** Cephalometric Differences Between the Stable and Unstable Groups at T0 (Before Treatment)

Variable	Stable, Mean (SD)	Unstable, Mean (SD)	Unstable-Stable, Mean (SD)	P
<b>Maxillary</b>				
SNA (°)	74.41 (2.23)	75.43 (4.23)	1.02 (1.47)	.377
A-y (mm)	53.61 (4.54)	53.20 (4.99)	-0.41 (2.24)	.857
A-x (mm)	45.13 (1.92)	46.47 (2.80)	1.34 (1.08)	.229
Ptm-A/PP (mm)	38.38 (3.44)	38.26 (3.48)	-0.12 (1.64)	.940
SN/PP (°)	10.92 (2.55)	10.01 (1.89)	-0.91 (1.11)	.429
<b>Mandibular</b>				
SNB (°)	76.15 (2.69)	78.06 (4.32)	1.91 (1.60)	.249
B-y (mm)	51.08 (5.95)	52.57 (7.64)	1.49 (3.14)	.641
B-x (mm)	79.15 (3.12)	83.54 (5.65)	4.39 (1.99)	.041*
Co-Gn (mm)	102.22 (5.27)	108.16 (5.29)	5.94 (2.51)	.030*
MP-SN (°)	36.29 (6.37)	38.49 (6.26)	2.20 (3.01)	.476
<b>Maxillomandibular</b>				
ANB (°)	-1.74 (1.26)	-2.63 (0.69)	-0.89 (0.45)	.064
Wits (mm)	-3.82 (3.03)	-5.11 (2.88)	-1.29 (1.42)	.372
<b>Dental</b>				
U1-SN (°)	93.87 (5.41)	97.19 (3.27)	3.32 (2.27)	.161
IMPA (°)	84.63 (7.87)	82.46 (5.40)	-2.17 (3.05)	.488
Overjet (mm)	-3.26 (0.82)	-3.96 (1.16)	-0.70 (0.45)	.142
Overbite (mm)	3.48 (1.32)	2.69 (1.06)	-0.79 (0.59)	.196

\*  $P < .05$ ; \*\*  $P < .01$ ; \*\*\*  $P < .001$  according to two-sample  $t$  test.

and overjet were evident in the unstable compared with the stable group (all  $P < .05$ ).

### Long-Term Differences Between the Stable and Unstable Groups

Long-term (T0-T1) changes in the stable and unstable groups are shown in Table 5. From T0 to

T2, the changes in the A-y distance and SNA angle did not differ between the groups (both  $P > .05$ ). However, the unstable group exhibited a lower increase in the vertical distance of point A than the stable group from T0 to T2 (A-x,  $4.43 \pm 1.64$  mm vs  $6.33 \pm 1.71$  mm;  $P < .05$ ). Also, the overall maxillary incisor protrusion (U1-SN) and overjet of the unstable group fell to greater extents than in the stable group (both  $P < .05$ ).

**Table 5.** Comparison of Cephalometric Changes Between the Stable and Unstable Groups<sup>a,b</sup>

Variable	Stable vs Unstable (T0-T1)			Stable vs Unstable (T1-T2)			Stable vs Unstable (T0-T2)		
	Stable	Unstable	P	Stable	Unstable	P	Stable	Unstable	P
<b>Maxillary</b>									
SNA (°)	2.08 (2.33)	3.99 (2.86)	.132	-0.46 (2.33)	-3.24 (1.49)	.012*	1.62 (2.74)	0.75 (2.57)	.498
A-y (mm)	2.29 (2.72)	5.19 (2.86)	.042*	1.18 (2.96)	-0.67 (1.89)	.159	3.47 (3.24)	4.52 (2.69)	.481
A-x (mm)	2.12 (2.27)	1.91 (1.98)	.847	4.22 (3.28)	2.51 (2.69)	.262	6.34 (1.71)	4.42 (1.64)	.029*
Ptm-A/PP (mm)	1.31 (2.31)	2.14 (1.14)	.388	0.53 (2.16)	-0.16 (1.84)	.494	1.84 (2.65)	1.98 (2.10)	.898
SN/PP (°)	-1.04 (3.21)	-2.77 (2.13)	.223	0.06 (2.81)	1.14 (2.29)	.400	-0.98 (2.94)	-1.63 (3.58)	.675
<b>Mandibular</b>									
SNB (°)	-1.63 (1.81)	0.04 (2.38)	.102	1.42 (2.63)	1.26 (1.93)	.891	-0.21 (2.28)	1.30 (2.67)	.208
B-y (mm)	-2.42 (3.37)	1.04 (4.51)	.073	4.32 (5.14)	4.84 (4.75)	.828	1.90 (4.50)	5.88 (5.52)	.104
B-x (mm)	5.81 (3.89)	4.03 (2.68)	.301	3.80 (2.88)	3.93 (4.12)	.937	9.61 (3.66)	7.96 (4.18)	.380
Co-Gn (mm)	4.19 (4.00)	4.64 (2.78)	.796	7.19 (4.93)	8.50 (4.54)	.574	11.38 (4.56)	13.14 (5.77)	.472
MP-SN (°)	1.81 (2.26)	0.73 (2.72)	.364	-1.36 (3.48)	-1.64 (2.17)	.848	0.45 (2.66)	-0.91 (2.40)	.279
<b>Maxillomandibular</b>									
ANB (°)	3.71 (2.03)	3.95 (1.14)	.411	-1.88 (2.14)	-4.50 (2.59)	.021*	1.83 (2.30)	-0.55 (3.10)	.109
Wits (mm)	4.55 (3.09)	4.97 (2.70)	.768	-2.40 (2.41)	-4.67 (3.52)	.112	2.15 (2.29)	0.30 (3.74)	.195
<b>Dental</b>									
U1-SN (°)	7.88 (6.52)	10.20 (4.73)	.429	4.91 (5.59)	-2.32 (6.39)	.037*	12.79 (4.44)	7.88 (5.55)	.025*
IMPA (°)	0.08 (3.54)	2.20 (4.30)	.282	1.54 (4.37)	0.90 (3.83)	.774	1.62 (3.29)	3.10 (4.72)	.741
Overjet (mm)	5.70 (1.31)	5.73 (1.72)	.969	-0.61 (1.05)	-5.12 (1.94)	<.001***	5.09 (1.30)	0.61 (0.85)	<.001***
Overbite (mm)	-2.41 (2.13)	-2.21 (1.16)	.828	-0.44 (1.39)	0.43 (0.62)	.109	-2.85 (1.74)	-1.78 (1.13)	.068

<sup>a</sup> T0 indicates before treatment; T1, after the active treatment; T2, at the end of long-term follow-up.

<sup>b</sup> Stable vs unstable (T0-T1), comparison of short-term (T0-T1) cephalometric changes between the stable and unstable groups. Stable vs unstable (T1-T2), comparison of changes during follow-up (T1-T2) between the stable and unstable groups. Stable vs unstable (T0-T2), comparison of long-term (T0-T1) cephalometric changes between the stable and unstable groups.

\*  $P < .05$ ; \*\*  $P < .01$ ; \*\*\*  $P < .001$  according to two-sample  $t$  test.

## DISCUSSION

The long-term stability of MP in patients with UCLP remain unclear.<sup>5,17</sup> The MP-treated subjects with UCLP were examined when craniofacial growth was close to completion. After follow-up, 36.8% of subjects (7 of 19) relapsed to a reverse overjet and were assigned to the unstable group. In the long term, MP therapy induced favorable maxillary advancement and an increase in maxillary length. The mandible rotated clockwise after active therapy but relapsed to the initial position during follow-up. Also, the upper and lower incisors were proclined at T2. The MP treatment primarily moved a recessive maxilla forward.<sup>12,18</sup> In this study, the long-term maxillary advancement was comparable between the stable and unstable groups.

In the short term, the unstable group exhibited more sagittal advancement of point A (2.89 mm) than the stable group. Nevertheless, gains in the overjet, ANB angle, and Wits value were similar from T0 to T1 in both groups, perhaps reflecting the inherently unfavorable skeletal (Class III) pattern of the unstable group. Before MP, both groups exhibited similar SNA and SNB angles. However, the ANB angle then decreased to a greater extent in the unstable group. Given the hyperdivergent mandibular plane angle, it was observed that the mandibles of the unstable patients were positioned significantly more inferiorly before treatment. Also, previous studies reported that an increased vertical mandibular dimension, a prognathic mandible, and a steep mandibular plane angle compromised the long-term stability usually afforded by MP.<sup>11,19</sup> Therefore, adolescents with Class III UCLP and excess mandible require special attention.

During the follow-up period (T1–T2), the maxillary, sagittal dentoskeletal effects differed in the stable and unstable groups. In terms of the sagittal skeletal component, the stable group evidenced a further 1.18-mm advancement of point A; the unstable group exhibited about 12.9% of sagittal relapse. Also, the unstable group exhibited a significantly greater decrease in the SNA angle. Thus, the stable group developed a favorable growth pattern after protraction with reverse headgear. Similarly, Hägg et al.<sup>12</sup> and Wells et al.<sup>6</sup> found that the maxilla grew to a greater forward extent in a stable group than a relapsing group during the posttreatment period. Semb<sup>20</sup> reported that the maxillary prominence of patients with UCLP decreased remarkably from 11 to 16 years of age. Thus, MP-induced maxillary advancement when young may allow future maxillary growth in stable patients. Significant lingual inclination of the upper incisors was observed after treatment in the unstable group, contributing to reverse overjet relapse.

Maxillary vertical deficiencies pose challenges to orthodontists.<sup>21,22</sup> Here, downward and forward protraction forces were applied, and the unstable group exhibited less vertical movement at point A than the stable group from T0 to T2, indicating that hypoplasia in the maxillary vertical dimension contributed to relapse after MP therapy. Yepes et al.<sup>23</sup> suggested that facemasks should deliver a vertical force. Given the observed maxillary vertical growth and reversal of the maxillary counterclockwise rotation, it may be speculated that a downward force vector (relative to the occlusal plane) might be beneficial for MP-treated patients with UCLP.

The study had certain limitations. Although all patients were recalled at a CVMS stage  $\geq$  IV, some residual craniofacial growth was evident. Therefore, patients in the stable group should be monitored until growth completion. Second, the sample size was small; thus, further research is required. Different force vectors were not applied in this study, which might have improved the clinical effects.

## CONCLUSIONS

- In the long term, MP therapy afforded favorable maxillary sagittal advancement in patients with UCLP.
- An excess mandible before treatment and long-term hypoplasia in the maxillary vertical dimension may predict poor MP prognoses.

## ACKNOWLEDGMENTS

A special thanks to the Cleft Lip and Palate Treatment Centre of Peking University Hospital of Stomatology for providing the cooperation work in this study. The authors declare no potential conflicts of interest with respect to the authorship and/or publication of this article.

## REFERENCES

1. Williams AC, Beam D, Mildinhal S, et al. Cleft lip and palate care in the United Kingdom - The Clinical Standards Advisory Group (CSAG) study. Part 2: Dentofacial outcomes and patient satisfaction. *Cleft Palate Craniofac J.* 2001;38:24–29.
2. Chen KF, So LL. Soft tissue profile changes of reverse headgear treatment in Chinese boys with complete unilateral cleft lip and palate. *Angle Orthod.* 1997;67:31–38.
3. Ahn HW, Kim KW, Yang IH, Choi JY, Baek SH. Comparison of the effects of maxillary protraction using facemask and miniplate anchorage between unilateral and bilateral cleft lip and palate patients. *Angle Orthod.* 2012;82:935–941.
4. Singla S, Utreja A, Singh SP, Lou W, Suri S. Increase in sagittal depth of the bony nasopharynx following maxillary protraction in patients with unilateral cleft lip and palate. *Cleft Palate Craniofac J.* 2014;51:585–592.
5. Susami T, Okayasu M, Inokuchi T, et al. Maxillary protraction in patients with cleft lip and palate in mixed dentition:

- cephalometric evaluation after completion of growth. *Cleft Palate Craniofac J.* 2014;51:514–524.
6. Wells AP, Sarver DM, Proffit WR. Long-term efficacy of reverse pull headgear therapy. *Angle Orthod.* 2006;76:915–922.
  7. Kwak HJ, Park HJ, Kim YJ, Lee DY. Factors associated with long-term vertical skeletal changes induced by facemask therapy in patients with Class III malocclusion. *Angle Orthod.* 2017;88:157–162.
  8. Choi YJ, Chang JE, Chung CJ, Tahk JH, Kim KH. Prediction of long-term success of orthopedic treatment in skeletal Class III malocclusions. *Am J Orthod Dentofacial Orthop.* 2017;152:193–203.
  9. Wendl B, Stampfl M, Muchitsch AP, et al. Long-term skeletal and dental effects of facemask versus chin cup treatment in Class III patients: a retrospective study. *J Orofac Orthop.* 2017;78:293–299.
  10. Moon YM, Ahn SJ, Chang YI. Cephalometric predictors of long-term stability in the early treatment of Class III malocclusion. *Angle Orthod.* 2005;75:747–753.
  11. Baccetti T, Franchi L, McNamara JA Jr. Cephalometric variables predicting the long-term success or failure of combined rapid maxillary expansion and facial mask therapy. *Am J Orthod Dentofacial Orthop.* 2004;126:16–22.
  12. Hagg U, Tse A, Bendeus M, Rabie AB. Long-term follow-up of early treatment with reverse headgear. *Eur J Orthod.* 2003;25:95–102.
  13. Jia H, Li W, Lin J. Maxillary protraction effects on anterior crossbites. Repaired unilateral cleft versus noncleft prepubertal boys. *Angle Orthod.* 2008;78:617–624.
  14. Fu Z, Lin Y, Ma L, Li W. Effects of maxillary protraction therapy on the pharyngeal airway in patients with repaired unilateral cleft lip and palate: a 3-dimensional computed tomographic study. *Am J Orthod Dentofacial Orthop.* 2016;149:673–682.
  15. Bergland O, Semb G, Abyholm FE. Elimination of the residual alveolar cleft by secondary bone-grafting and subsequent orthodontic treatment. *Cleft Palate J.* 1986;23:175–205.
  16. Baccetti T, Franchi L, McNamara JA. An improved version of the cervical vertebral maturation (CVM) method for the assessment of mandibular growth. *Angle Orthod.* 2002;72:316–323.
  17. Zhang Y, Jia H, Fu Z, et al. Dentoskeletal effects of facemask therapy in skeletal Class III cleft patients with or without bone graft. *Am J Orthod Dentofacial Orthop.* 2018;153:542–549.
  18. Shanker S, Ngan P, Wade D, et al. Cephalometric A point changes during and after maxillary protraction and expansion. *Am J Orthod Dentofacial Orthop.* 1996;110:423–430.
  19. Gu Y. Factors contributing to stability of protraction facemask treatment of Class III malocclusion. *Aust Orthod J.* 2010;26:171–177.
  20. Semb G. A study of facial growth in patients with unilateral cleft lip and palate treated by the Oslo CLP team. *Cleft Palate Craniofac J.* 1991;28:1–21; discussion 46–48.
  21. Meazzini MC, Basile V, Mazzoleni F, Bozzetti A, Brusati R. Long-term follow-up of large maxillary advancements with distraction osteogenesis in growing and non-growing cleft lip and palate patients. *J Plast Reconstr Aesthet Surg.* 2015;68:79–86.
  22. Oberoi S, Chigurupati R, Vargervik K. Morphologic and management characteristics of individuals with unilateral cleft lip and palate who required maxillary advancement. *Cleft Palate Craniofac J.* 2008;45:42–49.
  23. Yepes E, Quintero P, Rueda ZV, Pedroza A. Optimal force for maxillary protraction facemask therapy in the early treatment of Class III malocclusion. *Eur J Orthod.* 2014;36:586–594.