

# SINGLE-TOOTH REPLACEMENTS IN THE ESTHETIC ZONE WITH AN IMMEDIATE FUNCTION IMPLANT: A PRELIMINARY REPORT

William M. Locante, DDS

## KEY WORDS

Immediate function  
Deep- and wide-spaced spiral  
Load-bearing area  
Trabecular bone density  
Immediate provisionalization

Patients demand an economic, esthetic, and expedient fashion to replace teeth that are missing in the esthetic zone. The clinical response of a 1-piece spiral immediate-function implant was evaluated for this purpose. The implants were placed into immediate extraction sites as well as healed sites and were provisionalized, and patients were put into immediate function the same day as surgery. Sites that qualified for this technique were based on bone density. Bone density in combination with its aggressive thread design and conservative surgical osteotomy preparation produced a 98.8% success rate over a 3-year period for 86 patients.

## INTRODUCTION


**T**he purpose of this study was to report the clinical responses of a dental implant system named Stabledent (Crystal Medical Corporation, Pelham, Ala). In this study, the implant was used for the replacement of single teeth in the esthetic zone, after which they were placed into immediate function.

The Stabledent is a 1-piece, aluminum oxide, grit-blasted, self-tapping, tapered spiral implant with deep, widely spaced threads. The manufacturer suggests that the thread design coupled with a unique surgical approach encourages maximum bone adaptation at the time of placement.<sup>1-3</sup> The abutment portion of the implant is defined by

a margin or platform at its base (Figure 1). This implant is available in widths of 3.25, 4.0, and 5.0 mm and in lengths of 9, 12, and 15 mm, with abutment dimensions of a 3-mm base tapering 6 degrees to the driving square. The surgical kit consists of a 2-mm pilot drill and countersinks that correspond to the greater diameter of the implant, paralleling pins, driving tool, and ratchet. The countersinks are used to open the crestal portion of the osteotomy to allow the greater diameter of the implant to pass unimpeded as well as to seat the platform portion of the implant.

The research plan, which was devised by the author and approved by the research and development committee of the supplier, enlisted the enrollment of up to 100 patients over a time period of 3 years. Eighty-six

*William M. Locante, DDS, is in private practice. Address correspondence to Dr Locante at 850 Willow Tree Circle, Cordova, TN 38018 (e-mail: DocOsteo@aol.com).*



FIGURES 1-2. FIGURE 1. The Stabledent crown and bridge implant. FIGURE 2. Surgical kit.

patients were treated in this study during that time. Patients who qualified included those whose health histories did not contraindicate the use of dental implants; smokers were not excluded. The Stabledent implant was the only device used in the study. It was to be placed into immediate extraction sites as well as those that were healed.<sup>4,6</sup> Bone quality, however, was restricted to D-2 and D-3 classifications.<sup>7</sup> Implant lengths were selected based on total available bone.<sup>8</sup> In all immediate extraction sites, the implant bodies were made to extend into at least 35% new bone. Implant widths were selected based on maximum thread engagement, seeking to avoid overcompression of the buccal plates. All implants were put into immediate provisionalization postsurgically and allowed to function fully in light centric contact. Final restorations were inserted 8 to 12 weeks after surgery.

#### MATERIALS AND METHODS

A total of 86 patients in good general health were screened and required single-tooth replacement in the esthetic zone. All required immediate extraction, had previous extraction, or had

congenitally missing teeth. The decision to place into immediate function was made at the time of surgery when bone density could be evaluated by surgical manipulation; D-2 and D-3 densities were accepted. All patients had provisionals made and placed at the time of surgical placement of the implant. Of the 86 patients, 35 were males, 51 were females, all were between 12 and 81 years of age, 9 were smokers, 46 had fresh extraction sites, 28 had healed extraction sites, and 12 had congenitally missing teeth. Any site with acute infection or severe buccal or lingual bone loss was not included because of anticipated additional bone resorption and an inability to achieve complete thread submersion. Bone grafting was not to be included in this study except to fill the minor circumferential voids around the implant base at the crest in immediate extraction sites. All cases were to have immediate provisionals placed, and all were to be put into balanced immediate occlusion. This was checked clinically by adjustment and articulation paper markings, ensuring that all contacts were even and light on the provisional in centric occlusion. Heavy excursive contacts were

eliminated. Once the soft tissue had healed and adapted to the provisionals (approximately 6-8 weeks for tissue punch and 8-12 weeks for flapped cases), the provisionals were removed and the newly formed sulcus was probed from the base of the implant platform. Radiographs using the paralleling technique were done to evaluate bone approximation to the implant body at this appointment as well, in order to evaluate the hard- and soft-tissue adaptation to the implant and the platform. All cases were restored with porcelain fused to metal crowns or full porcelain jackets.

#### *Surgical procedure*

For sites requiring immediate extraction, full mucoperiosteal flaps were elevated to check for buccal-plate defects, such as fracture or fenestration. Teeth were extracted with great care either by elevation or forceps, thereby minimizing buccal-plate injuries.

The healed sites encompassed the congenitally missing teeth as well. If adequate bone width, height, and zone of attached gingiva were present, and for which an acceptable trajectory was anticipated, a tissue-punch technique was used for implant insertion. This technique contributes in the preservation and development of the papilla.<sup>9</sup> Otherwise, a soft-tissue flap was raised to expose the site.

In all cases, implant lengths were selected based on available bone height, using the longest implant that would not impinge on adjacent vital structures. The widths of the implants that were chosen for the immediate extraction sites were those that best filled the site without overcompressing their buccal plate but that were clearly capable of engaging the mesial and distal

walls.<sup>10</sup> At the healed sites, the diameters that would permit 1 to 1.5 mm of bone margin to cover the abutment platforms both facially and lingually were selected.

All patients were given preoperative antibiotics consisting of amoxicillin 2 g or cleocin 600 mg 1 hour before the procedure. This ensured a high blood level of antibiotic at the time of surgical insult, followed by the usual dosage postsurgically for 3 days.<sup>11</sup> Naproxen sodium 550 mg was given postsurgically to help reduce inflammation and discomfort. All patients rinsed for 1 minute with chlorohexadine solution 0.12% before the anesthetic was given.

In healed sites, including congenitally missing teeth, the soft-tissue punch technique was used if the parameters as discussed above were adequate; if not, these sites were flapped. A circular biopsy punch was centered in the zone of attached gingiva. With an apically directed force, a twisting motion was used to remove a circular piece of attached gingiva the same size as the diameter of the implant. In each case, the site was scored with a surgical #557 bur at the crest for the healed or congenitally missing site or at the base of the socket for immediate extraction sites. This formed a purchase point that the pilot drill could engage, and it eliminated "walking" of the bur. The pilot drill then reached the anticipated final depth. The drill itself is 2 mm in diameter and most frequently becomes the final sizing bur as well. The pilot drill, which is used to initiate the procedure, is clearly marked so that it can serve for the placement of any of the 3 lengths of implant (9, 12, and 15 mm). To accommodate this system's requirements for cervical countersinking, it provides a set of burs that perform

this function. Their diameters (3.25, 4, and 5 mm) correspond to the widths of their matching implants (Figure 2). These countersink burs serve dual functions: (1) to open the crestal portion of the osteotomy for unimpeded passage of the greater diameter of the implant threads to pass and (2) to create the appropriate receptor site for the seating of the implant platform. In less dense bone, such as in the maxilla, osteotomes can be used to accomplish the countersinking procedure. In more dense bone, the 2-mm pilot drill is to be followed by the 2.5-mm drill.

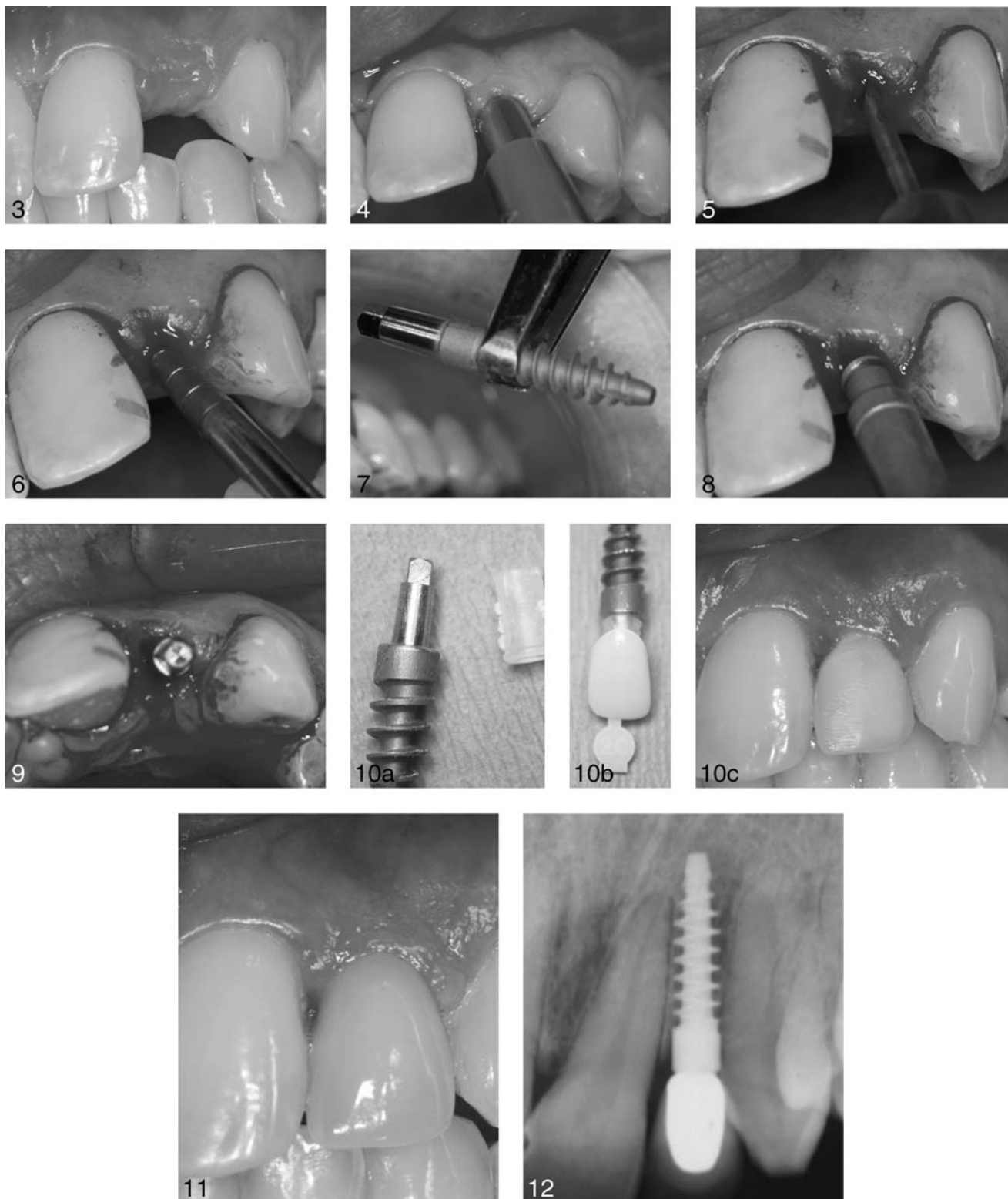The implants in this system respond most satisfactorily to the use of the hand ratchet for final placement. In instances when pericervical osseous defects were noted, they were filled with a composite particulate graft mixture of a cortical freeze-dried bone and calcium phosphate matrix (Osteogen, Impladent, Holliswood, NY). Provisional crowns were fabricated and adjusted chairside and were seated with temporary cement. Soft tissues were then adapted to the provisional and sutured with 4.0 silk-interrupted sutures to reestablish soft-tissue architecture in the given site.<sup>10</sup> All patients were instructed on postoperative care, which included diet modifications (soft diet), proper hygiene, and continuation of the antibiotic and the antinflammatory medication for the following 3 days, postoperatively. All patients were instructed to apply gauze dampened in the chlorohexadine solution to the surgical site for 20 minutes 3 times daily. In this author's opinion and observation, this technique has eliminated any potential wicking of silk suture and reduces the discoloration of teeth and acrylic that is typically seen with its

use. This technique is performed until the sutures are removed. Patients returned in 7 to 10 days for suture removal in cases that were flapped; in cases that were not flapped, patients returned in 7 days simply to observe the health and adaptation of the tissue architecture. After suture removal, the soft tissues were allowed to heal for 6 to 8 weeks, then the stability of the implants in all cases was evaluated clinically by removing the provisionals and physically tapping the abutment to postcheck for any signs of mobility. The newly formed sulcus attachment was gently probed with a periodontal probe to check for tissue adaptation on the platform and for any pocket formation beyond the platform. All cases were checked radiographically by the paralleling technique to observe bone levels and compare them with the bone levels radiographically at the time of placement. This radiographic information coupled with the clinical observations of no mobility, absence of pain, and tight tissue attachment at the base of the implant platform was sufficient evidence of implant-bone interface health to release the patient to have final restoration procedures.

The final restorations were completed about 3 months after the implants had been inserted. The following 2 case reports illuminate the details of several clinical situations.

#### CASE 1: SINGLE-TOOTH TISSUE PUNCH

A 26-year-old woman required evaluation of tooth #10. She had a Maryland bridge that failed and was seeking alternative treatment options. The replacement plan included the use of the Stabledent implant (Figure 3).



FIGURES 3–12. FIGURE 3. The operative site of tooth #10 indicates a good zone of fixed, keratinized gingiva and adequate dimensions to permit the placement of an implant. FIGURE 4. A 4-mm, disposable, soft-tissue biopsy punch is used in the center of the healed operative site. Turning and pressing its handle will incise a circular piece of tissue, permitting its simple removal. Of note is the well-preserved papilla. FIGURE 5. The 2-mm diameter pilot drill is used after a cortical entry made by a high-speed #557 bur. It is directed to depth 1 mm beyond the full depth of the planned implant and in a direction that will permit a proper angle of

A 4-mm biopsy punch was centered in the zone of attached gingiva (Figure 4). After completing the classical insertion procedure, as described earlier (Figures 5 through 8), papillary integrity had been retained (Figure 9). Fabrication and cementation of an Ion crown completed the procedure (Figure 10A, B, and C). The soft tissues were allowed to heal for 4 weeks before final restoration impressions were taken. The final restoration was seated 8 weeks postsurgery (Figures 11 and 12).

#### CASE 2: FLAP ELEVATION

A 48-year-old woman presented with an unrestorable, fractured right maxillary incisor. She was entered into the research project (Figure 13).

The patient was prepared in the usual fashion. Once she was anesthetized, an intrasulcular incision was made with relieving incisions added to the mesial and distal of tooth #7, including the full papillae and extending past the mucogingival junction. A full mucoperiosteal flap was elevated, exposing the entire buccal plate. The palatal tissue was minimally reflected to expose the crestal margin of the palatal bone, which allowed for better access and visualization to fill any voids on this aspect of the extraction site. The tooth was gently elevated and the socket was debrided. Even though the tooth released very easily, the buccal plate had developed a mi-

nor fracture. The site was prepared with the 2-mm pilot drill to depth of 15 mm, extending beyond the apex approximately 6 mm. A 4- by 15-mm implant was selected. The implant was ratcheted into place, engaging the apical bone and the socket walls (Figure 14). The site was prepared so that the central post would emerge within the incisal edge position of the adjacent clinical crowns (Figure 15). Voids around the implant were filled with a composite graft of cortical freeze-dried bone and calcium phosphate salt (Figure 16). The provisional restoration was fabricated with an acrylic sleeve that provided excellent adaptation to the central post (Figure 17) and was then picked up with cold cure acrylic in the prefabricated provisional crown (Figure 18). The provisional was contoured, the occlusion was relieved, and then it was seated. The tissues were readapted to the provisional and were sutured with 4.0 silk (Figure 19). The sutures were removed 10 days later (Figure 20). The tissue was allowed to heal for 8 weeks postoperatively, and the final restoration was placed 11 weeks postoperatively (Figures 21 and 22).

The patient returned for follow-up at 2.5 years (Figures 23 and 24). The soft tissue and papilla had been maintained and were healthy in appearance, with a pocket depth less than 2 mm. X ray revealed minimal bony changes.

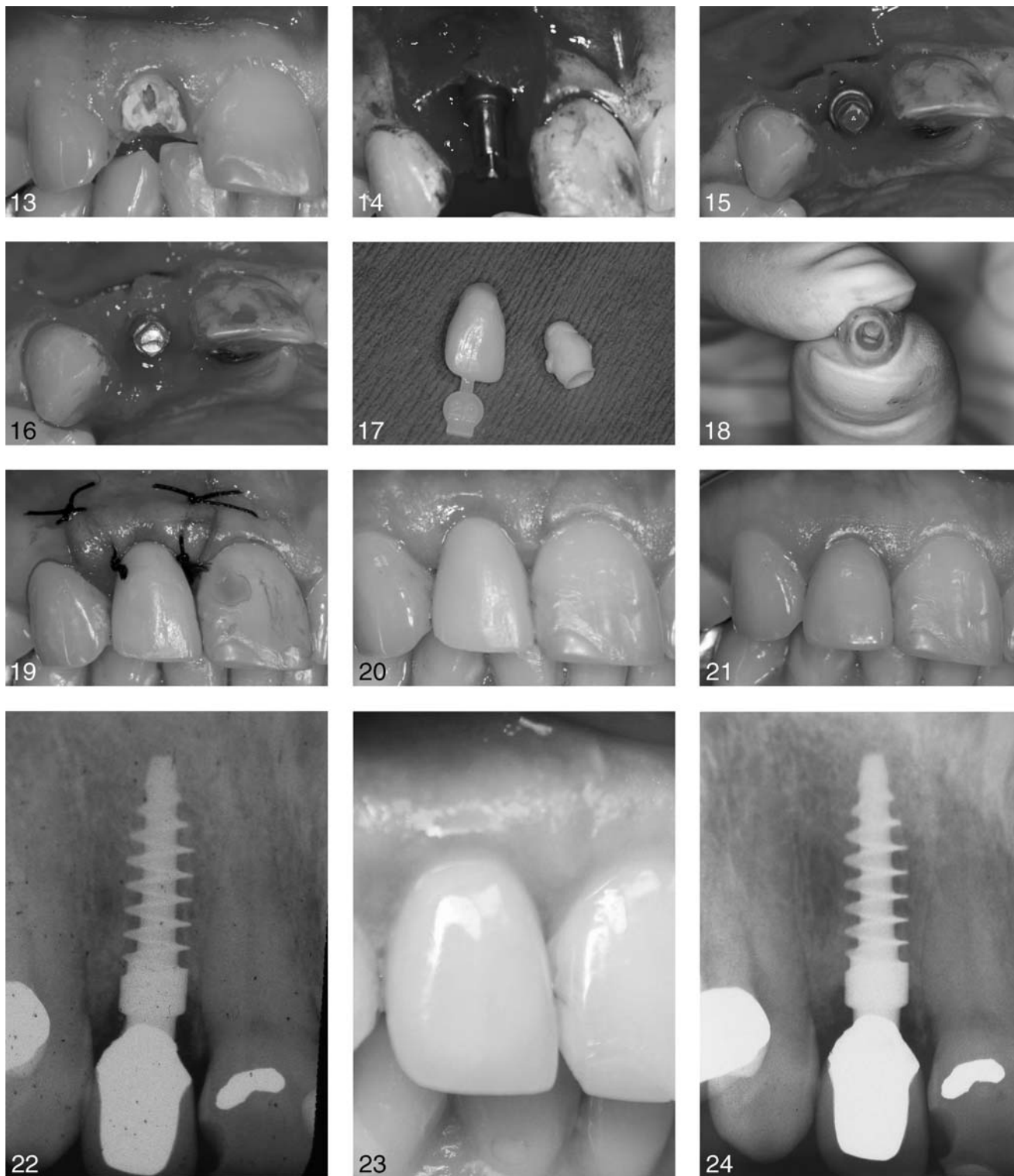
#### RESULTS

A total of 86 patients (35 males, 51 females) in good health qualified for this study on the basis of bone density. Ages ranged from 12 to 81 years. Forty-six implants were placed into fresh extraction sites, 28 were placed into healed sites, and 12 were placed into congenitally missing-tooth sites. Total time in function at preparation of this study was 12 to 42 months. Tooth locations for implant placement were as follows: maxillary central incisors (21), maxillary lateral incisors (39), maxillary canines (16), maxillary premolars (8), and mandibular canines (2). Nine patients were smokers who smoked no more than 2 packs per day. No implant losses were in the smoker group. Of the 86 total implants, only 1 implant was lost, and that was within the first 4 weeks after surgery. The lost implant was of the immediate variety in the maxillary first premolar alveolus of a 40-year-old non-smoking man. The implant was replaced by a classical 2-stage implant. The overall success rate achieved was 98.8 % (Table).

#### DISCUSSION

The use of a new, 1-piece, immediate-function, tapered, spiral implant for immediate restoration and function in the esthetic zone has been described. In selected cases with single-tooth operative sites of D-2 and D-3 bone where maximum thread engagement and bone adaptation can be

←  
emergence. FIGURE 6. Utilization of an osteotome to expand the crestal portion of the site instead of countersink. FIGURE 7. The Stabdent implant. Note the aggressive wide-spaced and deep thread design. FIGURE 8. The implant is hand ratcheted to place. FIGURE 9. The implant abutment in optimal position within the neutral zone of the site. FIGURE 10. (A, B) The machined acrylic sleeve used to fabricate a well-adapted provisional and the preformed ion crown that is filled with fast-set acrylic to pickup sleeve. (C) The provisional is shaped, polished, and seated to place the same day as surgery. The placement of a well-contoured provisional aids in the redevelopment of papilla. FIGURE 11. Final restoration in place 8 weeks postoperatively. Note the exceptional soft tissue and esthetic result. FIGURE 12. Final X ray shows the seating of the final restoration and the excellent osseous adaptation to the aggressive implant thread design.



FIGURES 13-24. FIGURE 13. Fractured tooth #7. FIGURE 14. Implant in place. Note the buccal-plate fracture. FIGURE 15. Abutment in position. FIGURE 16. Voids filled with composite graft. FIGURE 17. Acrylic sleeve and provisional. FIGURE 18. Sleeve picked up in provisional. FIGURE 19. Tissue readapted to provisional and sutured. FIGURE 20. Suture removal, 10 days postoperative. FIGURE 21. Final restoration 11 weeks postoperative. FIGURE 22. Final X ray. FIGURE 23. Clinical 2.5 years postoperative. FIGURE 24. X ray at 2.5 years postoperative. Note the excellent osseous response.

Location	No. Implants	Removal	% Survival
Maxillary central	21		100
Maxillary lateral	39		100
Maxillary canine	16		100
Maxillary premolar	8	1	87.5
Mandibular canine	2		100
Total	86	1	98.8

achieved, this implant has been shown to have a very high degree of predictability.

The advantages of a 1-piece immediate-function implant are many. First, patients are able to leave the dental office with a fixed provisional restoration that can be put into function the same day of surgery. Second, esthetic requirements are acquired readily because soft-tissue architecture can be maintained and even developed. This benefit may be noted based on the observations made about the osseous structures; they were successfully maintained because of the presence of the implants and provisional crowns, which contributed to the support and architecture of the gingival soft tissues. Total treatment time from insertion to final restoration has been greatly reduced. Final restorations were usually placed 8 to 12 weeks postimplant insertion. Finally, because it is a 1-piece implant, 2-stage surgery is eliminated, as is the potential microgap that can exist between component parts, thus eliminating the concern of a bacterial

reservoir that can potentially create hard- and soft-tissue problems.<sup>11-13</sup>

#### SUMMARY AND CONCLUSIONS

Immediate function and restoration is not a new concept; this is simply revisiting a technique that was once widely used in implantology.<sup>14</sup> Better understanding of design, biomaterials, surgical technique, and bone physiology and the interrelationships of these factors allow us to shorten treatment time, ease discomfort, and offer predictable esthetic and functional results for patients who are able to satisfy some stringent requirements.

#### REFERENCES

1. Valen M, Locante W. Introducing osteocompression in dentistry. *Int J Oral Implantol.* 2000;3:177-184.
2. Locante W, Valen M. Clinical consideration of osteocompression. *Int J Oral Implantol.* 2000;3:185-192.
3. Brunski JB. Biomechanical factors affecting the bone-dental implant interface. *Clin Mater.* 1992;10:153-201.

4. Lazzara RJ. Immediate implant placement into extraction sockets. Surgical and restorative advantages. *Int J Periodont Restor Dent.* 1989;9:333-343.

5. Rosenquist B, Grenthe B. Immediate placement of implants into extraction sockets. Implant survival. *Int J Oral Maxillofac Implants.* 1996;11:205-209.

6. Gelb DA. Immediate implant surgery: three-year retrospective evaluation of 50 consecutive cases. *Int J Oral Maxillofac Implants.* 1993;8:388-399.

7. Misch CE. Density of bone: effect on treatment plans, surgical approach, healing, and progressive bone loading. *Int J Oral Implantol.* 1990;6:23-31.

8. Misch CE. Density of bone: A key determinant for clinical success. In: Misch CE, ed. *Contemporary Implant Dentistry.* 2nd ed. St Louis, Mo: Mosby Inc; 1999:109-118.

9. Auty C, Siddiqui A. Punch technique for preservation of interdental papillae at nonsubmerged implant placement. *Implant Dent.* 1999;8:160-166.

10. Locante W. The nonfunctional immediate provisional in immediate extraction sites: a technique to maximize esthetics. *Implant Dent.* 2001;4:1-5.

11. Quirynen M, van Steenberghe D. Bacterial colonization of the internal part of two stage implants: an in vivo study. *Clin Oral Implants Res.* 1993;4:158-161.

12. Becker W, Becker BE, Newman MG, et al. Clinical and microbiologic findings that may contribute to dental implant failure. *Int J Oral Maxillofac Implants.* 1990;5:31-38

13. Laskin DM, Dent CD, Morris HF, Ochi S, Olson JW. The influence of preoperative antibiotics on the success of endosseous implants at 36 months. *Ann Periodontol.* 2000;5:166-174.

14. Linkow LI, Chercheve R. *Theories and Techniques of Oral Implantology.* St Louis, Mo: CV Mosby; 1970.