

# A NEWLY DESIGNED TEMPLATE DEVICE FOR USE WITH THE INSERTION OF IMMEDIATELY LOADED IMPLANTS

Marco A. B. Pontual, DDS, MScD  
José N. O. Freire, DDS, MScD  
Dircilene C. Souza, DDS, MScD  
Cimara F. Ferreira, DDS, MScD  
Marco A. Bianchini, DDS, MScD  
Ricardo S. Magini, DDS, MScD,  
PhD

## KEY WORDS

Immediately loaded implants  
New surgical template device  
Immediately placed fixed  
prosthesis

Marco A. B. Pontual, DDS, José N. O. Freire, DDS, MScD, Dircilene C. Souza, DDS, MScD, Cimara F. Ferreira, DDS, MScD, and Marco A. Bianchini, DDS, MScD are students of oral implantology in the doctoral degree program, and Ricardo S. Magini, DDS, MScD, PhD, is a graduate advisor in dental implantology at Federal University of Santa Catarina, Florianópolis, Santa Catarina, Brazil.

Address correspondence to Dr Pontual at Rua Eurico de Aguiar 130/410, Vitória, ES, Brazil 29055-280 (e-mail: mpontual@terra.com.br).

This article describes a newly designed surgical template that was used to facilitate dental implant placement. The implants were planned to function by loading them immediately. A case report describing the device and the benefits of its use for a patient with an edentulous mandible is presented. Four implants were placed in the anterior region of the mandible to support an immediately fixed prosthesis. Clinical and radiographic analyses were conducted postoperatively to evaluate bone loss and peri-implant soft-tissue healing. The salutary results demonstrated the positive value of this therapeutic approach and presented the advantages of shorter treatment times, fewer patient visits, lower costs, and elimination of secondary surgical procedures.

## INTRODUCTION

The experiences of this article's authors and of other authors within the scientific community have demonstrated the myriad benefits of using osseointegrated implants as a modality for improving the effectiveness of oral rehabilitation. The traditional 2-stage protocol, as suggested originally by Branemark et al,<sup>1</sup> was designed to protect the implants from bacterial contamination and to avoid the stigmata that were predicted if preintegration loading was permitted. Thus, keeping the implants submerged for 3 to 6 months was considered a basic requirement for osseointegration.<sup>1,2</sup> This pro-

cedure often required patients to wear removable prostheses, or none at all, for protracted periods of time. These events served poorly to enlighten or build the confidence of the public about the values of dental implants.

From the outset, manufacturers such as ITI (Dental Implant System—Institute Straumann, Waldenburg, Switzerland) considered it unnecessary to submerge implants to achieve osseointegration. ITI introduced a single-stage surgical protocol for placement of their implants, and successful results have been reported for over 15 years, which have been comparable with the devices marketed by the more traditional manufacturers.<sup>3,4</sup> A large number of studies have reported good

clinical results with the use of single-stage implants.<sup>5-11</sup>

On the basis of the 1-stage philosophy, many clinicians recently have begun to contradict traditional precepts by inserting implants, placing their abutments, and subjecting them to loading all at the same visit. Although the classic manner of supplying immediate prostheses was with removable appliances, Schnitman et al<sup>12</sup> described a technique that supplied their patients with fixed prostheses from the outset. Their results were very encouraging.

Subsequently, the outcomes of a 10-year follow-up of the original study demonstrated the long-term success of an expanded and more carefully designed protocol.<sup>13</sup> Although this method has been used and developed, some criteria for its use had to be settled<sup>14</sup> to ensure an acceptable success rate for this therapy. Presently, with the information obtained during this period, it is possible to place definite prosthesis on the same day as the implant placement surgery.<sup>15</sup>

As practitioners became more interested and the obvious benefits of immediate loading created high levels of participation, more articles and lectures were devoted to immediate loading and its benefits, risks, complications, and myriad approaches to the surgery and prosthetic construction. Certainly, the introduction of the *Branemark Novum* implant has engendered the interest of a growing number of clinicians who are following the paths of instant functions and immediate loading.<sup>15</sup> The enthusiasm for pursuing these techniques was responsible for the presentation of this case report. It describes a novel template device used to assist in the placement of implants that were loaded immedi-

ately when used for a patient with an edentulous mandible.

#### CLINICAL CASE REPORT

The patient, a 46-year-old woman in good health, was referred for implant placement in the anterior mandible (Figure 1). Tomographic studies (Figures 2 and 3) were used for simulation of the planned surgery as described in the literature.<sup>16</sup> The plan encompassed the use of immediate loading with the application of a newly designed surgical drill guide that had been developed by the authors. This device is composed of a biarticulated surgical template and a prefabricated titanium bar that functions as a mesostructure for a soon-to-be-placed implant-supported prosthesis. This surgical guide had been developed in an articulation modality to permit its adjustment to different mandibular anatomies. The template was placed over the patient's mandibular tomogram, and the planned implant sites were transferred to it in the form of titanium cylinders by the use of marks transferred to it. The cylinders would serve as guides directing the location, angulation, and depth of the osteotomies. The implant placement that followed was virtually automatic. To ensure a flawless procedure, firm stabilization of the template was accomplished before surgical intervention with bilateral fixation screws.

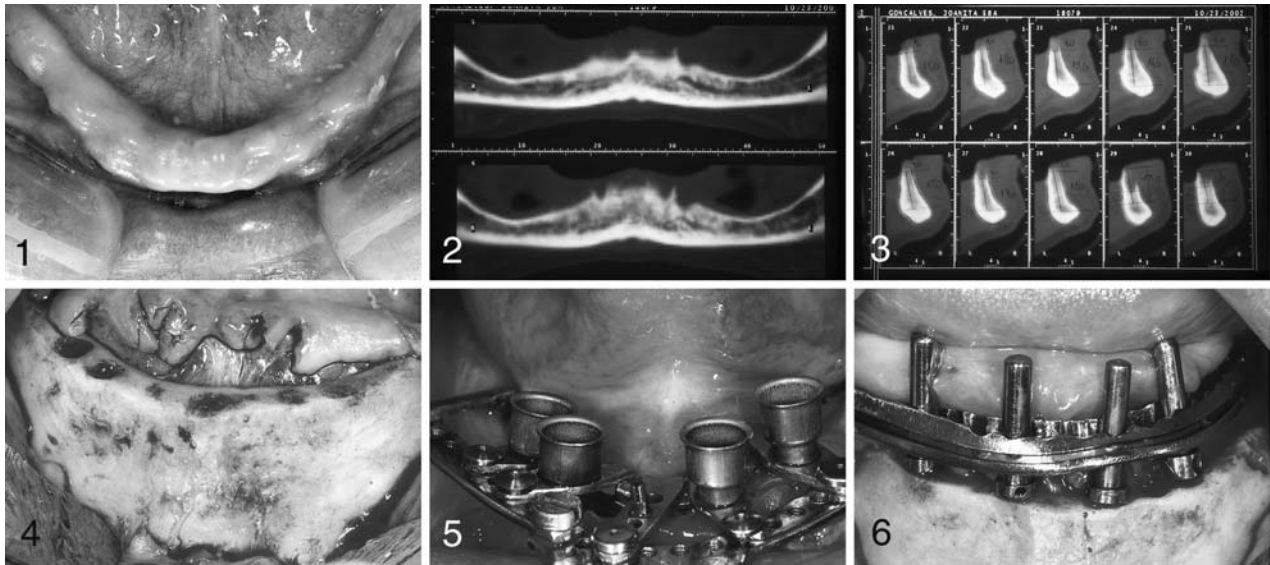
The surgery began with the administration of infiltration anesthesia, mucogingival incision and reflection, and an alveoloplasty. The resulting crestal host site demonstrated uniform height and a width of 6 mm (Figure 4). The implant widths of 4 mm mandated an additional 2 mm of

ridge expanse. The surgical guide then was placed over the exposed bone and stabilized with the 2 distal screws (Figure 5). The implant osteotomies were completed, the orienting guides for the prosthesis were placed, and, over these, the first titanium bar try-in was affected, which confirmed accurate implant positioning (Figure 6). After the implants had been inserted, titanium UCLA abutments (Implant and Prostheses Conexao Master System, Sao Paulo, Brazil) were attached to them (Figures 7 and 8). The bar was placed into its proper position, thereby permitting the UCLA abutments to protrude into the preexisting space, and autopolymerizing resin was used to attach them to the bar (Figures 9 and 10).

After acrylic polymerization, the occlusion was recorded with the addition of silicone impression material. The bar-UCLA assembly was removed from the silicone material, which permitted the placement of the analogs and the fabrication of the master cast. After mounting the master cast on the articulator (Figure 11), the titanium bar and UCLA abutments were spot welded as guided by the acrylic luting (Figure 12).

The prosthesis was waxed up, and openings were created on the cingula for the placement of the abutment-retaining screws. Then the prosthesis was flaked, and the resultant device was polished and inserted 36 hours after surgery (Figures 13 through 15).

During the healing phase, the patient was periodically evaluated regarding the condition of the periimplant tissues, the fixed prosthesis, and all other related structures and conditions. Twenty-one additional immediately loaded implants have been placed since this first patient's procedure



FIGURES 1–6. FIGURE 1. The initial occlusal aspect of the mandible is shown. FIGURES 2–3. These tomographic studies, were used for implant planning and placement and proved to be a beneficial aid. FIGURE 4. An alveoplasty was performed, which resulted in a 6-mm width and a uniform height of the planned operative site. FIGURE 5. The surgical template is affixed firmly over the exposed ridge. Its guide tubes will direct the osteotomies in location, angulation, and depth. FIGURE 6. Upon completion of the osteotomies, the first try-in of the titanium bar is completed, which confirms implant positioning.

was completed. All have achieved osseointegration and have demonstrated virtually no clinical or radiographic stigmata.

#### DISCUSSION

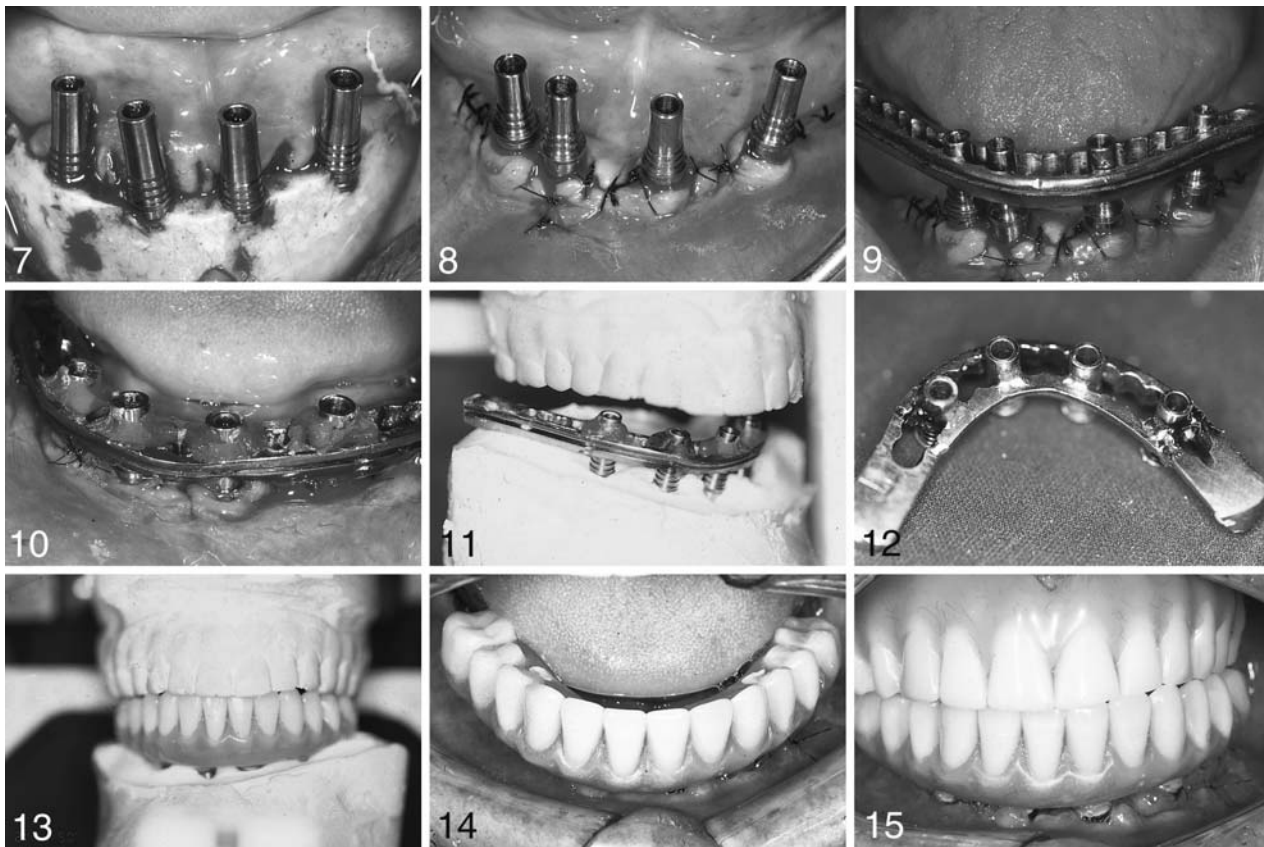
The rigid guidelines that were imposed to ensure osseointegration have been followed for many years; however, recent thinking, experimentation, and clinical practice have encouraged a flexible approach. More recently, ever-growing converts to immediate use of implants have enjoyed high levels of success. Although some practitioners consider the concepts of immediate loading to be innovative, students of history are aware of the use of these techniques by those who practiced placement of subperiosteal implants; Chercheve and many other spirals; virtually all blade and anchor implants; and, more recently, mini-interim (Dentatus-type) implants. Nonetheless, the

prospects for continuing current success of this beneficial technique (or the renewal of what was a necessary stabilizing factor in earlier times) are positive, particularly if specific guidelines are followed.<sup>14</sup> The benefits accruing to patients, staff, and doctors alike are lower costs, fewer office visits, less surgery, saved time, and near-instant delivery of fixed prostheses. The elimination of the wearing of clumsy, unwieldy, and uncomfortable removable interim appliances has also made the practice of immediate loading an attractive one. Schnitman et al<sup>12</sup> were pioneers in developing a protocol with fixed prostheses for the application of immediate loading over osseointegrated implants in the rehabilitation of patients with total edentulous mandibles.

Recent studies analyzing different modalities of implant distribution concluded that the success of this form of therapy depends basically on the location

of implants (they should be in the anterior region of the mandible) and on their number and location, which should be strategically located so that the immediate load will be properly distributed.<sup>13</sup> Thus, the placement of 5 to 6 implants in the region between the mental foramina was suggested, 3 of which could be submitted to immediate load. It was concluded that the 2 most distal implants and the most central implant would be the most appropriate to receive the immediate use because they satisfy the geometric precepts of triangularization, thereby optimizing the distribution of occlusal forces. Initial stability, which can be achieved by bicortical osseous support and immediate rigid splinting of the implants with a provisional fixed prosthesis, are fundamental requirements for the achievement of success.

Clearly, the forces that threaten osseointegration must be man-



FIGURES 7–15. FIGURE 7. Before closure, titanium UCLA abutments are placed into each implant. FIGURE 8. The wound is sutured around each abutment. FIGURE 9. The titanium bar is positioned for a second time, on this occasion over the abutments. FIGURE 10. The openings and fenestrations on the bar and between the bar and the abutments are filled with autopolymerizing resin. FIGURE 11. A silicone impression is used to transfer the assembly to an articulator. FIGURE 12. Spot welding is performed at each resin site, which attaches the abutments to the bar. FIGURE 13. Teeth and gingivae are waxed to the bar, and the occlusion is adjusted on the articulator. Lingual holes are placed at the requisite cingular sites to permit access to the fixation screws. FIGURE 14. The fixed prosthesis is delivered and affixed to the implants with screws. The screw holes are covered. FIGURE 15. The completed case (with the sutures in evidence) shows the occlusal relationships, the fixed mandibular superstructure, and the superstructure's opposing complete maxillary denture.

aged. This may be accomplished with implants in sufficient quantity and appropriate and diverse locations to form a stabilized polygon, known as Roy's polygon.<sup>17</sup> The longer the segments are, the better the stabilization becomes. One of the advantages of the template described in this article is that it offers the opportunity of properly distributing 4 implants to achieve the highest levels of rigidity.

Criteria for the application of immediate loading over implants would depend on (1) bone quality at the receptor site (mandible), (2) acceptable mac-

ro- and microscopic features of the implants (titanium, plasma sprayed, threaded), (3) initial stability achieved with bicortical engagement, (4) strategic distribution of the implants, and (5) avoidance or minimal use of cantilevers.<sup>14</sup> The initial stability of implants immediately after their placement as well as during the bone-healing period has been widely considered in the literature as a basic requirement for therapeutic success when using the immediate-load concepts.<sup>18–24</sup>

The novel surgical guide described in this article not only has

been used to locate the position of implants but also has the capability to ensure its own stability. It also ensures that a fixed prosthesis will fit over the implants passively and without static tension, which is one of the most important requisites for a positive biological response and the maintenance of the structural integrity of the overlying prosthesis. In addition, another advantage of this template is its simplicity of surgical application because of its few components.

Immediate loading procedures are a reality, and significant benefits are now accruing to

the professionals and patients who use them. The scientific community will anticipate the establishment of protocols that encompass care of the partially edentulous patient as well. The progress made within the discipline of immediate loading represents but a small step in the scientific cascade to further improve the welfare of patients.

### CONCLUSION

Immediate loading is a modality of oral rehabilitation available to patients with edentulous mandibles. The use of a novel surgical template has been described. It offers several advantages over alternative techniques, among which are simplicity of placement, diminution of surgical time, a faster delivery of the prosthesis, and an enhanced passive adaptation of the prostheses-implant system.

### ACKNOWLEDGMENTS

Appreciation is extended to the Implant and Prosthesis Conexao Master System, Sao Paulo, Brazil, for providing the material for this research and to the Vaiazi Prosthodontic Laboratory, Sao Paulo, Brazil, for its support.

### REFERENCES

1. Branemark P-I, Breine U, Adell R, Hansson BO, Lindstrom J, Ohlsson A. Intra-osseous anchorage of dental prostheses. *Scand J Plast Reconstr Surg.* 1969; 3:81-100.
2. Adell R, Lekholm U, Rockler B, Branemark P-I. A 15-year study of osseointegrated implants in the treatment of the edentulous jaw. *Int J Oral Surg.* 1981;10:387-416.
3. Buser DA, Schroeder A, Sutter F, Lang NP. The new concept of ITI hollow-

4. Schroeder A, Sutter F, Krekeler G. *Oral Implantology.* Stuttgart, Germany: Georg Thieme Verlag; 1990.
5. Bernard JP, Belser UC, Martinet JP, Borgis SA. Osseointegration of Branemark fixtures using a single-step operating technique. A preliminary prospective one-year study in the edentulous mandible. *Clin Oral Implant Res.* 1995;6:122-129.
6. Buser D, Weber HP, Lang NP. Tissue integration of non-submerged implants. 1-year results of a prospective study with 100 ITI hollow-cylinder and hollow-screw implants. *Clin Oral Implant Res.* 1990;1:33-40.
7. Ericsson I, Randow K, Glantz P-O. Clinical and radiographical features of submerged and non-submerged titanium implants. *Clin Oral Implant Res.* 1994; 5:185-189.
8. Ruggieri A, Franchi M, Marini N, Trial P, Piattelli A. Supracrestal circular collagen fiber network around osseointegrated non-submerged titanium implants. *Clin Oral Implant Res.* 1992;3:169-175.
9. Schroeder A, Van der Zypen E, Stich H, Sutter F. The reactions of bone, connective tissue and epithelium to endosteal implants with sprayed titanium surfaces. *J Maxillofac Surg.* 1981;9:15-25.
10. Ten Bruggenkate CM, Mutter K, Oosterbeek HS. Clinical evaluation of the ITI (F-type) hollow-cylinder implants. *Oral Surg Oral Med Oral Pathol Oral Radiol Endod.* 1990;70:693-697.
11. Weber HP, Buser D, Donath K. Comparison of healed tissues adjacent to submerged and non-submerged unloaded titanium dental implants. A histometric study in beagle dogs. *Clin Oral Implant Res.* 1996;7:11-19.
12. Schnitman PA, Wohrle PS, Rubenstein JE. Immediate fixed interim prostheses supported by two-stage threaded implants: methodology and results. *J Oral Implantol.* 1990;16:96-105.
13. Schnitman PA, Wohrle PS, Rubenstein JE. Ten-year results of Branemark implants immediately loaded with fixed prostheses at implant placement. *Int J Oral Maxillofac Implants.* 1997;12: 495-503.
14. Salama H, Rose LF, Salama M, Betts NJ. Immediate loading of bilaterally splinted titanium root-form implants in fixed prosthodontics. A technique reexamined: two case reports. *Int J Periodont Restor Dent.* 1995;15:345-361.
15. Branemark P-I. The Branemark Novum Protocol for Same-Day Teeth: A Global Perspective. Chicago, Ill: Quintessence; 1999.
16. Passoni OM. Protocolo de Diagnóstico por Imagem em Implantodontia. Dissertação de Mestrado em Implantodontia. Santa Catarina, Brazil: Federal University of Santa Catarina; 2001.
17. Pontual MAB, Siqueira MP. Prótese microparafusada, a evolução da prótese fixa implanto-suportada. *Innovations J.* 2000;2:48-51.
18. Bijlani M, Lozada J. Immediately loaded dental implants—influence of early functional contacts on implant stability, bone level, integrity, and soft tissue quality: a retrospective 3- and 6-year clinical analysis. *Int J Oral Maxillofac Implants.* 1996;11:126.
19. Chiapasco M, Gatti C, Rossi E, Haefliger W, Markwalder TH. Implant-retained mandibular overdentures with immediate loading. *Clin Oral Implant Res.* 1997;8:48-57.
20. Leimola-Virtanen R, Peltola J, Ok-sala E, Helenius H, Happonen R-P. ITI titanium plasma-sprayed screw implants in the treatment of edentulous mandibles: a follow-up study of 39 patients. *Int J Oral Maxillofac Implants.* 1995;10:373-378.
21. Piattelli A, Trisi P, Romasco N, Emanuelli M. Histologic analysis of a screw implant retrieved from man: influence of early loading and primary stability. *J Oral Implantol.* 1993;19:303-306.
22. Sirota CA, Fiorellini J, Corso M, Weber HP. Immediate loading of implants with various coating in beagle dogs [abstract]. *J Dent Res.* 1996;76 (special issue):400.
23. Salama H, Rose LF, Minsk L, Klinger E. Immediate loading of TPS root-form implants in the human mandible. *Int J Oral Maxillofac Implants.* 1995; 11:125.
24. Tarnow DP, Emtiaz S, Classi A. Immediate loading of threaded implants at stage 1 surgery in edentulous arches: ten consecutive case reports with 1 to 5 year data. *Int J Oral Maxillofac Implants.* 1997;12:319-324.