

MAXILLARY SINUS AUGMENTATION WITH A SYNTHETIC CELL-BINDING PEPTIDE: HISTOLOGICAL AND HISTOMORPHOMETRICAL RESULTS IN HUMANS

Marco Degidi, MD, DDS
 Maurizio Piattelli, MD, DDS
 Antonio Scarano, DDS
 Giovanna Iezzi, DDS
 Adriano Piattelli, MD, DDS

KEY WORDS

Anorganic bovine bone
 Autologous bone
 Sinus augmentation procedures
 Synthetic cell-binding peptide

Marco Degidi, MD, DDS, is in private practice in Bologna, Italy, and is a visiting professor, Maurizio Piattelli, MD, DDS, is an associate professor, Antonio Scarano, DDS, is a researcher, Giovanna Iezzi, DDS, is a research fellow, and Adriano Piattelli, MD, DDS, is a professor at the Dental School, University of Chieti, Chieti, Italy.

Bone substitutes should be used when sufficient amounts of autologous bone cannot be harvested from intraoral donor sites. P-15 is a highly conserved linear peptide with a 15 amino acid sequence identical to the sequence contained in the residues 766 to 780 of the alpha-chain of type I collagen. PepGen P-15 (Dentsply Friadent, Mannheim, Germany) is a combination of the mineral component of bovine bone (Osteograf/N 300) with P-15. Bio-Oss (Geistlich, Mannheim, Germany) is a deproteinized sterilized bovine bone with 75% to 80% porosity and a crystal size of approximately 10 μm in the form of cortical granules. The purpose of the present histological and histomorphometrical study was to compare maxillary sinus augmentation procedures in humans performed with PepGen P-15 with procedures associated with Bio-Oss and autologous bone. Seven patients participated in this study (3 men and 4 women; ages between 48 and 69 years, mean of 58 years) and were categorized into 3 groups. In group 1, a mixture of 50% autologous bone from an intraoral source and 50% Bio-Oss was used. In group 2, the graft materials used were 50% Bio-Oss and 50% PepGen P-15. In group 3, 50% autologous bone and 50% PepGen P-15 were used. Group 1 histomorphometry showed that the percentage of newly formed bone was $38.7\% \pm 3.2\%$, marrow spaces represented $45.6\% \pm 5\%$, and residual graft particles constituted the remaining $14.4\% \pm 2.1\%$. Group 2 histomorphometry showed that newly formed bone represented $36.7\% \pm 3.3\%$, marrow spaces represented $39.7\% \pm 3.4\%$, and residual graft particles represented $19.6\% \pm 2.1\%$. In group 3, newly formed bone represented $32.2\% \pm 3.2\%$, marrow spaces represented $38\% \pm 2.5\%$, and residual graft particles represented $28.8\% \pm 1.1\%$. Non-statistically significant differences were found in the percentage of newly formed bone in the different groups ($P = .360$). Statistically

significant differences were found in the percentage of residual graft materials among the different groups (group 1 vs groups 2 and 3) ($P = .0001$). These data demonstrate that the use of bone-replacement materials, without the addition of autologous bone, could be an alternative in sinus augmentation procedures. Such treatment would increase patient satisfaction, decrease surgical complications, and save the clinician substantial operating time.

INTRODUCTION

Insufficient bone volume in the posterior portions of the maxilla can create problems for dental implant installation, and the reduced bone quantity and quality may affect the outcome of implant treatment in this area.¹ The purpose of the augmentation procedures is to provide a sufficient volume of bone for mechanical support and integration of implants.² The maxillary sinus augmentation was first presented by Tatum in 1976.^{3,4} Several different materials have been used for sinus grafting, but it is still not clear which graft materials are clinically most suitable for bone regeneration.⁵ Autologous grafts are considered the golden standard in terms of osteogenic potential, but they present some disadvantages, such as a limited availability of material from the intraoral donor site, a tendency to be partially resorbed, and that the extraoral site requires general anesthesia with an additional surgery at the donor site and is often associated with morbidity (limping, anesthesia, paresthesia, residual defects) at the donor site.^{1,6-15} There is a prolonged operation time, which, in turn, leads to higher expenses for the surgery.¹ These facts have led to a quest for a bone substitute that could be used in bone-regeneration techniques. These bone substitutes should be used when sufficient amounts of autologous bone cannot be harvested from intraoral donor sites.⁷ Moreover, because autologous

bone grafts often undergo a significant resorption (up to 50%),^{7,16} the addition of a material that does not resorb or resorbs very slowly could help stabilize the graft. A further obvious advantage would be to use the bone substitutes alone because no donor site for harvesting of autologous bone is needed.^{2,5} Several types of mixture of graft materials have been proposed and reported in the literature; however, the ideal ratio of these mixtures is still unknown.¹

P-15 is a highly conserved linear peptide with a 15 amino acid sequence identical to the sequence contained in the residues 766 to 780 of the alpha-1 chain of type I collagen. PepGen P-15 is a combination of the mineral component of bovine bone (Osteograf/N 300) with P-15. The anorganic bovine-derived bone-mineral component provides the necessary calcium phosphate and the natural anatomical matrix needed for osteoconduction.¹⁷⁻²⁹ P-15 competes for cell-surface sites for attachment of collagen and, when immobilized on surfaces, promotes adhesion of cells. P-15 has been shown to facilitate physiological processes in a way similar to collagen, that is, exchanging mechanical signals and promoting cell differentiation.¹⁷⁻²⁹ Like other bone augmentation materials, P-15 associated with anorganic-derived bone matrix has been shown to aid in the treatment of periodontal defects, alveolar ridge defects, or sinus lifting procedures.¹⁷⁻²⁹

Bio-Oss is a deproteinized sterilized bovine bone with 75% to 80% porosity and a crystal size of approximately 10 μm in the form of cortical granules. It has a natural, nonantigenic porous matrix with 0.25- to 1.00-mm particles.³⁰⁻⁴⁸ This material is chemically and physically identical to human bone and is reported to be highly osteoconductive. The large-mesh interconnecting pore system facilitates angiogenesis and migration of osteoblasts.⁴⁴ Bone formation has been reported with the use of Bio-Oss in sinus elevation procedures, critical-size bone defects, guided bone-regeneration procedures, dehiscence defects, and regenerative periodontal treatment.³⁰⁻⁴⁸

The purpose of the present histological and histomorphometrical study was to compare maxillary sinus augmentation procedures in humans performed with PepGen P-15 with procedures associated with Bio-Oss and autologous bone.

MATERIALS AND METHODS

Seven patients participated in this study (3 men and 4 women; ages between 48 and 69 years, mean of 58 years). The Ethics Committee approved the protocol, and all patients signed a written informed consent. Inclusion criteria were presence of a maxillary partial (unilateral or bilateral) edentulism involving the premolar or molar areas and presence of a residual alveolar ridge height between 1 and 4 mm. Exclusion criteria were patients who were

smokers, had systemic diseases or maxillary sinus pathology, or had recent extractions in the involved area. At the initial visit, all patients received a clinical and occlusal examination, and periapical and panoramic radiographs and computerized tomography (CT) scans were performed to evaluate any possible intrasinus pathology as well as bony-walls morphology.

SURGICAL PROTOCOL

The patients were categorized into 3 groups. In group 1, a mixture of 50% autologous bone from an intraoral source and 50% Bio-Oss was used. In group 2, the graft materials used were 50% Bio-Oss and 50% PepGen P-15. In group 3, 50% autologous bone and 50% PepGen P-15 were used. Patients were then covered to guarantee maximum asepsis. Skin was disinfected with Betadine, and the patients were asked to rinse with clorexidine mouthwash 0.2%. Under local anesthesia, a crestal incision, slightly toward the palatal aspect throughout the entire length of the edentulous segment, was performed supplemented by buccal releasing incisions mesially and distally. Full-thickness flaps were elevated to expose the alveolar crest and the lateral wall of the maxillary sinus. By using a round bur under cold (4°C–5°C) sterile saline irrigation, a trap door was made in the lateral sinus wall. The door was rotated inward and upward with a top hinge to a horizontal position. The sinus membrane was elevated with curettes of different shapes until it became completely detached from the lateral and inferior walls of the sinus.

Whenever a small tear was noted in the membrane, it was repaired with a collagen membrane (Biogide, Geistlich, Wolhu-

sen, Switzerland). The graft material was mixed with sterile saline solution and carefully packed in the sinus cavity. Another membrane (Biogide) was positioned against the packed sinus window. The mucoperiosteal flap was then replaced and sutured with multiple horizontal mattress sutures. Amoxicillin (1 g twice daily) was prescribed for 1 week, and analgesics were prescribed as required. Sutures were removed 2 weeks after surgery. Postsurgical visits were scheduled at monthly intervals to check the course of healing.

Six months later, a second CT scan was performed in the sinuses augmented with biomaterial without autogenous bone. The dimension of the graft was evaluated and, by means of a surgical template, the implants were placed. The sinus augmentation procedure was bilateral in 4 edentulous patients and unilateral in 3 partially edentulous patients. Twelve Frialit2 and 21 XiVE implants (Dentsply, Frialit, Mannheim, Germany) were inserted (16 implants were 3.8 × 13 mm, 5 implants were 5.5 × 13 mm, and 12 implants were 4.5 × 13 mm). At the time of implant surgery, bone cores were harvested from the lateral wall with a 3.5- × 10-mm diameter trephine under a cold (4°C–5°C) sterile saline solution irrigation. Implants were then buried, and the second-stage surgery was carried out after a healing period of an additional 6 months.

Specimen processing

The specimens were immediately fixed in 10% buffered formalin and processed to obtain thin ground sections with the Precise 1 Automated System (Assing, Rome, Italy).⁴⁹ The specimens were dehydrated in an ascending

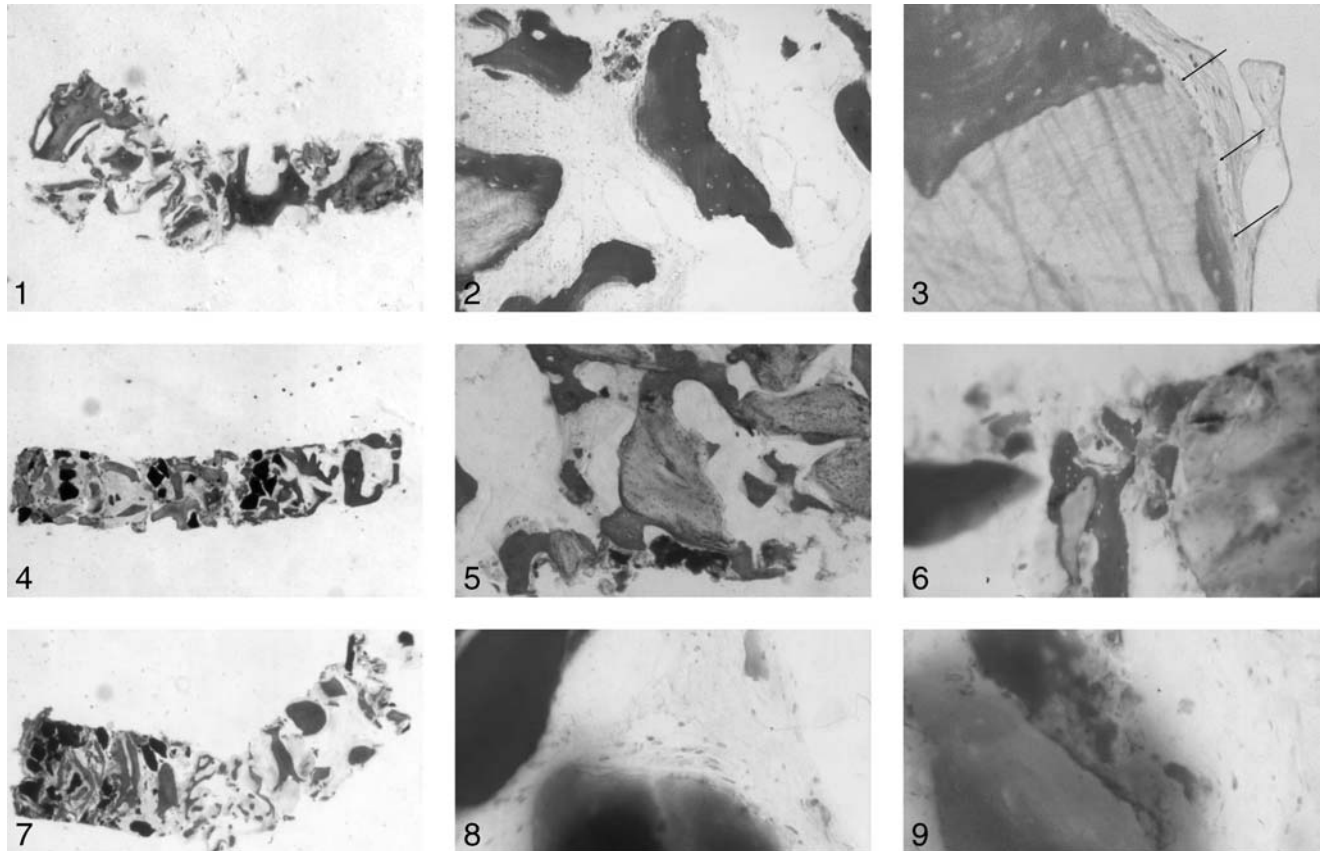
series of alcohol rinses and embedded in a glycolmethacrylate resin (Technovit 7200 VLC, Kulzer, Wehrheim, Germany). After polymerization, the specimens were sectioned along their longitudinal axis with a high-precision diamond disc at about 150 µm and ground down to about 30 µm with a specially designed grinding machine. The slides were stained with acid fuchsin and toluidine blue. The slides were observed in normal transmitted light under a Leitz Laborlux microscope (Laborlux S, Leitz, Wetzlar, Germany). The histomorphometry was carried out with a light microscope connected to a high-resolution video camera (3CCD, JVC KY-F55B, JVC Professional Products, Milan, Italy) and interfaced to a monitor and personal computer (Intel Pentium III 1200 MMX, Intel Ireland Ltd, Kildare, Ireland). This optical system was associated with a digitizing pad (Matrix Vision GmbH, Oppenweiler, Germany) and a histometry software package with image-capturing capabilities (Image-Pro Plus 4.5, Media Cybernetics Inc, Immagini & Computer Snc, Milano, Italy).

Statistical evaluation

The differences in the percentage of newly formed bone and residual graft particles in the different groups were evaluated with the analysis of variance. The significance of the differences observed was evaluated with the Bonferroni test for multiple comparisons. The percentages were expressed as a mean ± SD and SE. Statistically significant differences were set at $P < .05$.

RESULTS

None of the 7 patients had major complications. Only a moderate



FIGURES 1–9. FIGURE 1. Newly formed bone with wide osteocytic lacunae, and Bio-Oss (arrow) particles are lined by newly formed bone (toluidine blue and acid fuchsin, original magnification $\times 12$). FIGURE 2. Autologous bone presents similar features to those of host bone (toluidine blue and acid fuchsin, original magnification $\times 100$). FIGURE 3. The Bio-Oss particles are surrounded by newly formed bone and osteoblasts (arrows) (toluidine blue and acid fuchsin, original magnification $\times 200$). FIGURE 4. Newly formed bone is present around Bio-Oss and PepGen P-15 particles (toluidine blue and acid fuchsin, original magnification $\times 100$). FIGURE 5. The Bio-Oss (B) and PepGen P-15 particles (P) are surrounded by newly formed bone (toluidine blue and acid fuchsin, original magnification $\times 100$). FIGURE 6. In this area, newly formed bone with large osteocytic lacunae is present around Bio-Oss and PepGen P-15 particles (toluidine blue and acid fuchsin, original magnification $\times 200$). FIGURE 7. PepGen P-15 and newly formed bone are present (toluidine blue and acid fuchsin, original magnification $\times 12$). FIGURE 8. PepGen P-15 particles are surrounded by osteoblasts (toluidine blue and acid fuchsin, original magnification $\times 200$). FIGURE 9. The new bone inside of P-15 particle (toluidine blue and acid fuchsin, original magnification $\times 200$).

swelling was sometimes present. All implants were clinically osseointegrated and stable and, after the abutment connection, received provisional fixed acrylic-resin prostheses. Radiographic examinations showed the presence of dense bone around the implants. After a mean of 7 months (range 6–7.5 months), all patients underwent definitive prosthetic rehabilitation with ceramometal fixed prostheses. All patients were followed for a minimum of 2 years after the prosthesis placement.

Group 1: autologous bone and Bio-Oss

A total of 12 biopsies were evaluated. At low magnification, it was possible to see that most of the Bio-Oss particles were lined by newly formed bone (Figure 1). Some of the particles appeared to be united by this newly formed bone. The material appeared to be highly osteoconductive. The newly formed bone was easily distinguished because of its higher staining affinity for dyes (Figures 2 and 3). In some specimens,

a rim of osteoblasts lined the newly formed bone. Basic-fuchsin-positive, highly stained lines, similar to the cementing lines, divided the grafted bone from the newly formed bone. These lines had a higher staining than the cementing lines observed in normal bone. Autologous bone showed a pattern similar to that of host bone. Grafted particles seemed to undergo a very slow resorption process. At higher magnification, the newly formed bone presented wide osteocytic lacunae. In almost all particles, the

Haversian canals appeared to be colonized by capillaries and cells. In some of the Haversian canals, it was possible to observe the presence of acid-fuchsin-positive, not-yet-mineralized material lining their inner surface. Histomorphometry showed that the percentage of newly formed bone was $38.7\% \pm 3.2\%$, marrow spaces represented $45.6\% \pm 5\%$, and residual graft particles constituted the remaining $14.4\% \pm 2.1\%$.

Group 2: *Pep-Gen P-15* and *Bio-Oss*

A total of 12 biopsies were evaluated. In most of the *PepGen P-15* particles, newly formed tissue with the staining characteristics of bone was present in the internal portion of the graft material. Around most of the particles was a 100- to 200- μm gap between newly formed bone and graft material; in this interposed tissue it was possible to find fibroblasts and cells with phagocytic activity (Figures 4 and 5). Scattered multinucleated giant cells were present in resorption lacunae in the outer portion of the graft particles. No inflammatory cell infiltrate was present. Most of the *Bio-Oss* particles appeared to be surrounded by newly formed mature and compact bone, with well-organized osteons (Figure 6). Some osteoblasts apposed bone directly on the particle surface. No gaps were observed at the bone-particles interface, and the bone was always in close contact with the particles. Osteocyte lacunae of the graft particles were filled by osteocytes. The *Bio-Oss* particles presented marked staining differences from the host bone and had a lower affinity for the stains. No inflammatory infiltrate was present around the particles or at the interface with bone. Multinucleated giant cells

	% Newly Formed Bone	% Marrow Spaces	% Residual Graft Materials
Autologous bone + <i>Bio-Oss</i>	38.8 ± 3.2	45.7 ± 5.0	14.4 ± 2.1
<i>Bio-Oss</i> + <i>PepGen P-15</i>	36.7 ± 3.3	39.7 ± 3.4	19.6 ± 2.1
Autologous bone + <i>PepGen P-15</i>	32.2 ± 2.5	38 ± 3.2	28.8 ± 1.1

were apparent in only in a few areas. Histomorphometry showed that newly formed bone represented $36.7\% \pm 3.3\%$, marrow spaces represented $39.7\% \pm 3.4\%$, and residual graft particles represented $19.6\% \pm 2.1\%$.

Group 3: *autologous bone* and *PepGen P-15*

A total of 9 biopsies were evaluated. The histological data for the different graft materials have already been described. Newly formed bone represented $32.2\% \pm 3.2\%$, marrow spaces represented $38\% \pm 2.5\%$, and residual graft particles represented $28.8\% \pm 1.1\%$ (Figures 7 through 9).

STATISTICAL EVALUATION

Nonstatistically significant differences were found in the percentage of newly formed bone in the different groups ($P = .360$). Statistically significant differences were found in the percentage of residual grafted materials among the different groups (group 1 vs groups 2 and 3, Table 1) ($P = .0001$).

DISCUSSION

Autologous bone is the most predictable and successful graft material available. Because the main problem concerning the use of autologous bone is its availability, many other types of materials have been proposed and used as a substitute. It has been reported

that the addition of osteoconductive materials can expand the volume, induce dense new bone formation, and prevent premature resorption of the augmented site.¹ *Bio-Oss* is obtained from cortical and cancellous bone and has 2 particle sizes (0.25–1 mm and 1–2 mm). It is constituted by a calcium-deficient carbonate apatite with a crystal size of about 10 nm; the material is identical to human bone from a chemical and physical point of view.⁵ *Bio-Oss* has a compressive strength of 35 Mpa, and its porous nature (75% of the total volume) serves to greatly increase the surface area of the material.⁴¹ This increased surface area provides a substratum for an increased angiogenesis and represents a scaffold for bone formation.⁴¹ It appears that 2 different mechanisms contribute to the bone regeneration by *Bio-Oss*.⁵ Bone formation begins anywhere inside the graft if autogenous bone is added to the *Bio-Oss* particles, whereas the bone grows upward from the pre-existing bone at the sinus floor into the grafted area when *Bio-Oss* is used alone.⁵ The advantage of using autogenous bone is the fast ingrowth of vessels from the surrounding bone, whereas the use of *Bio-Oss* can help prevent the unwanted early resorption that is present when using autologous bone.^{2,14} In fact, Hallmann et al⁷ reported a less than 10% resorption with the use of *Bio-Oss* and

intramembranous bone from the chin. Tadjodin et al⁵ reported data that showed a decreasing value of bone volume and bone metabolism (osteoid surface, resorption surface, and mineral apposition rate) with decreasing proportions of autologous bone in the graft: the bone value was 37.3% with 20% Bio-Oss but 22.9% with 100% Bio-Oss. A higher proportion of Bio-Oss produced less bone volume. It has also been suggested that with an increasing ratio of anorganic bone mineral to autologous bone, resorption of the bone additive decreases because of the lesser quantity of osteoclasts recruited from the autologous bone.¹ Tadjodin et al.⁵ showed that a mixture of 50% Bio-Oss and 50% autologous bone was adequate to obtain a primary stability of dental implants after a 6-month healing period. Also, Mayfield et al⁵⁰ reported that deproteinized bovine bone in combination with autogenous bone grafts enabled implants to osseointegrate and remain stable in a 4- to 6.5-year period.

In our study, we found that newly formed bone started to form within the PepGen P-15 graft particles. Currently, we cannot assess the importance of this finding in the bone-regeneration processes; it could certainly be important in the future to have specimens with longer follow-ups to see what happens to the graft particles. Multinucleated cells were in close contact with the material surface of Bio-Oss and PepGen P-15 and were involved in the resorption of some particles. This process seems to be slow. No inflammatory cell infiltrate was present. This study has shown a good clinical outcome and no adverse effects during the healing process with all tested materials. We can con-

clude in this limited case series that all tested grafted materials can be successfully used in maxillary sinus augmentation procedures. Our histologic data show that, although the addition of PepGen P-15 to autologous bone seems to produce a lesser quantity of newly formed bone compared with Bio-Oss (32.2% vs 38.8%), the difference is not statistically significant; therefore, additional patients are required to determine significance. Furthermore, the clinical study design did not test whether the P-15 peptide, which is believed to stimulate cell attachment and speed the process of bone formation, promoted greater bone formation before 6 months. By the 6-month time point reported in this study, bone formation may have stabilized, and the benefit of earlier bone formation would not be observed by this protocol. Additional studies are required that take bone cores at earlier time points.

Although vital bone quantity was measured, no known correlation exists between vital bone formed and implant success. Furthermore, bone quality and bone volume were not measured in this study, both of which may affect clinical outcome and implant success. Although evidence demonstrates that autologous bone can lose up to 50% of the volume occupied in the sinus (because of its rapid resorption), it is believed that bovine-derived bone-replacement materials do not lose such substantial volumes because of their slower resorptive properties. Additional studies are required to measure bone volume at the time of graft-material placement and after implant placement.

We wish to stress that a substantial amount of bone (36.7%) is present in the specimens obtained

with PepGen P-15 and Bio-Oss without the use of autologous bone and that no significant differences were in vital bone formed compared with treatments containing autologous bone. The combination of PepGen P-15 with Bio-Oss improved the amount of vital bone formed (36.7%) compared with that previously reported with 100% Bio-Oss (22.9%) at a later time period (8 months).⁵ These data demonstrate that the use of bone-replacement materials, without the addition of autologous bone, could be an alternative in sinus augmentation procedures. Such treatment would increase patient satisfaction, decrease surgical complications, and save the clinician substantial operating time.

ACKNOWLEDGMENTS

This work was partially supported by the National Research Council, Rome, Italy; by the Ministry of Education, University and Research, Rome, Italy; and by Research Association for Dentistry and Dermatology, Chieti, Italy.

REFERENCES

1. Merckx MAW, Maltha JC, Stoelinga PJW. Assessment of the value of anorganic bone additives in sinus floor augmentation: a review of clinical reports. *Int J Oral Maxillofac Surg.* 2003;32:1-6.
2. Hallman M, Sennerby L, Lundgren S. A clinical and histologic evaluation of implant integration in the posterior maxilla after sinus floor augmentation with autogenous bone, bovine hydroxyapatite, or a 20:80 mixture. *Int J Oral Maxillofac Implants.* 2002;17:635-643.
3. Tatum OH. Maxillary and sinus implant reconstruction. *Dent Clin North Am.* 1986;30:207-229.
4. Tatum OH, Liebowitz MS, Tatum CA, Borgner RA. Sinus augmentation: rationale, development, long-term results. *NY State Dent J.* 1993:43-48.

5. Tadjoein ES, de Lange GL, Bronckers ALJJ, Lyaruu DM, Burger EH. Deproteinized cancellous bovine bone (Bio-Oss[®]) as bone substitute for sinus floor elevation. A retrospective, histomorphometrical study of five cases. *J Clin Periodontol.* 2003;30:261–270.
6. Sartori S, Silvestri M, Forni F, Icaro Cornaglia A, Tepei P, Cattaneo V. Ten-year follow-up in a maxillary sinus augmentation using anorganic bovine bone (Bio-Oss). A case report with histomorphometric evaluation. *Clin Oral Implants Res.* 2003;14:369–372.
7. Hallman M, Lederlund A, Linsskog S, Lundgren S, Sennerby L. A clinical histologic study of bovine hydroxyapatite in combination with autogenous bone and fibrin glue for maxillary sinus floor augmentation. Results after 8 months of healing. *Clin Oral Implants Res.* 2001;12:135–143.
8. Triplett RG, Schow SR. Autologous bone grafts and endosseous implants: complementary techniques. *J Oral Maxillofac Surg.* 1996;54:486–494.
9. Becker W, Becker BE, Polizzi G, Bergstrom C. Autogenous bone grafting of bone defects adjacent to implants placed into immediate extraction sockets in patients: a prospective study. *Int J Oral Maxillofac Implants.* 1994;9:389–396.
10. Lauer G, Schilli W. Collected implant cavity borings used as peri-implant osseous augmentation material. *Int J Oral Maxillofac Implants.* 1994;9:437–443.
11. Piattelli A, Degidi M, Di Stefano D, Rubini C, Fioroni M, Strocchi R. Microvessel density in alveolar ridge regeneration with autologous and alloplastic bone. *Implant Dent.* 2002;11:370–375.
12. Orsini G, Vinci R, Bianchi AE, Piattelli A. Histologic evaluation in man of the use of autogenous calvarial bone in maxillary onlay bone grafts: a report of two cases. *Int J Oral Maxillofac Implants.* 2003;18:594–598.
13. Striker A, Voss PJ, Gutwald R, Schramm A, Schmelzesein R. Maxillary sinus floor augmentation with autogenous bone grafts to enable placement of SLA-surfaced implants: preliminary results after 15–40 months. *Clin Oral Implants Res.* 2003;14:207–212.
14. Schlegel KA, Fichtner G, Schultemogau S, Wiltfang J. Histologic findings in sinus augmentation with autogenous bone chips versus a bovine bone substitute. *Int J Oral Maxillofac Implants.* 2003;18:53–58.
15. Proussaefs P, Lozada J, Kleinman A, Rohrer MD, McMillan PJ. The use of titanium mesh in conjunction with autogenous bone graft and inorganic bovine bone mineral (Bio-Oss) for localized alveolar ridge augmentation: a human study. *Int J Periodont Restor Dent.* 2003;23:185–195.
16. Haas R, Donath K, Fodiger M, Watzek G. Bovine hydroxyapatite for maxillary sinus grafting: comparative histomorphometric findings in sheep. *Clin Oral Implants Res.* 1998;9:107–116.
17. Yukna RA, Callan DP, Krauser JT, et al. Multi-center clinical evaluation of combination anorganic bovine-derived hydroxyapatite matrix (ABM)/cell binding peptide (P-15) as a bone replacement graft material in human periodontal osseous defects. 6-month results. *J Periodontol.* 1998;69:655–663.
18. Bhatnagar RS, Qian JJ, Gough CA. The role in cell binding of a beta-bend within the triple helical region in collagen alpha1 (I) chain: structural and biological evidence for conformational tautomerism on fiber surface. *J Biomol Struct Dyn.* 1997;14:547–560.
19. Qian JJ, Bhatnagar RS. Enhanced cell attachment to anorganic bone mineral in the presence of a synthetic peptide related to collagen. *J Biomed Mater Res.* 1996;31:545–554.
20. Bhatnagar RS, Qian JJ, Wedrychowska A, Sadeghi M, Wu YM, Smith N. Design of biomimetic habitat for tissue engineering with P-15, a synthetic peptide analogue of collagen. *Tissue Eng.* 1999;5:53–65.
21. Bhatnagar RS, Qian JJ, Wedrychowska A, Dixon E, Smith N. Biomimetic habitat for cells: ordered matrix deposition and differentiation in gingival fibroblasts cultured on hydroxyapatite coated with a collagen analogue. *Cell Mater.* 1999;9:93–104.
22. Lallier TE, Yukna R, St Marie S, Moses R. The putative collagen binding peptide hastens periodontal ligament cell attachment to bone replacement graft materials. *J Periodontol.* 2001;72:990–997.
23. Krauser JT, Rohrer MD, Wallace SS. Human histologic and histomorphometric analysis comparing Osteograf/N with PepGen P-15 in the maxillary sinus elevation procedure: a case report. *Implant Dent.* 2000;9:298–302.
24. Yukna RA, Salinas TJ, Carr RF. Periodontal regeneration following use of ABM/p-15: a case report. *Int J Periodont Restor Dent.* 2002;22:146–155.
25. Yukna RA, Krauser JT, Callan DP, Evans GH, Cruz R, Martin M. Thirty-six follow-ups of 25 patients treated with combination anorganic bovine-derived hydroxyapatite matrix (ABM) cell-binding peptide (P-15) bone replacement grafts in human infrabony defects. I. Clinical findings. *J Periodontol.* 2002;73:123–128.
26. Yukna RA, Krauser JT, Callan DP, Evans GH, Cruz R, Martin M. Multi-center clinical comparison of combination anorganic bovine-derived hydroxyapatite matrix (ABM)/cell binding peptide (P-15) and ABM in human periodontal osseous defects. 6-month results. *J Periodontol.* 2000;71:1671–1679.
27. Carinci F, Pezzetti F, Volinia S, et al. P15 cell binding domain derived from collagen: analysis of MG63 osteoblastic-cell response by means of a microarray technology. *J Periodontol.* 2004;75:60–77.
28. Hahn J, Rohrer MD, Tofe AJ. Clinical, radiographic, histologic and histomorphometric comparison of PepGen P-15 particulate and PepGen P-15 Flow in extraction sockets. A same-mouth case study. *Implant Dent.* 2003;12:170–174.
29. Scarano A, Iezzi G, Petrone G, et al. Cortical bone regeneration with PepGen P-15: a histological and histomorphometric pilot study in rabbits. *Implant Dent.* 2003;12:318–324.
30. Valentini P, Abensur D, Densari D, Graziani JN, Hämmerle CHF. Histological evaluation of Bio-Oss[®] in a 2-stage sinus floor elevation and implantation procedure. A human case report. *Clin Oral Implants Res.* 1998;9:59–64.
31. Valentini P, Abensur D. Maxillary sinus floor elevation for implant placement with demineralized freeze-dried bone and bovine bone (Bio-Oss[®]): a clinical study of 20 patients. *Int J Periodont Restor Dent.* 1997;17:233–241.
32. Artzi Z, Nencovsky CE, Dayan D. Bovine-HA spongiosa blocks and immediate implant placement in sinus augmentation procedures. Histopathological and histomorphometric observations on different histological stainings in 10 consecutive patients. *Clin Oral Implants Res.* 2002;13:420–427.

33. Scarano A, Pecora G, Piattelli M, et al. Osseointegration in a sinus augmented with bovine porous bone mineral: histological results in an implant retrieved 4 years after insertion. A case report. *J Periodontol*. 2004;75:1161–1166.
34. Berglundh T, Lindhe J. Healing around implants placed in bone defects treated with Bio-Oss. *Clin Oral Implants Res*. 1997;8:117–124.
35. Maiorana C, Sommariva L, Brivio P, Sigurtà D, Santoro F. Maxillary sinus augmentation with anorganic bovine bone (Bio-Oss) and autologous platelet-rich plasma: preliminary clinical and histologic evaluations. *Int J Periodont Restor Dent*. 2003;23:227–235.
36. Haas R, Mailath G, Dortbudack O, Watzek G. Bovine hydroxyapatite for maxillary sinus augmentation: analysis of interfacial bond strength of dental implants using pull-out tests. *Clin Oral Implants Res*. 1998;9:117–122.
37. McAllister BS, Margolin MD, Cogan AG, Taylor M, Wollins J. Residual lateral wall defects following sinus grafting with recombinant human Osteogenic Protein-1 or Bio-Oss on the chimpanzee. *Int J Periodont Restor Dent*. 1998;18:227–239.
38. Hallman M, Nordin T. Sinus floor augmentation with bovine hydroxyapatite mixed with fibrin glue and later placement of nonsubmerged implants: a retrospective study in 50 patients. *Int J Oral Maxillofac Implants*. 2004;19:222–227.
39. Piattelli M, Favero GF, Scarano A, Orsini G, Piattelli A. Bone reactions to anorganic bovine bone (Bio-Oss) used in sinus lifting procedure: a histologic long-term report of 20 cases in man. *Int J Oral Maxillofac Implants*. 1999;14:835–840.
40. Tawil J, Mawla M. Sinus floor elevation using a bovine bone mineral (Bio-Oss) with or without the concomitant use of a bilayered collagen barrier (bio-gide): a clinical report of immediate and delayed implant placement. *Int J Oral Maxillofac Implants*. 2001;16:713–721.
41. Rodriguez A, Anastasou GE, Lee H, Buchbinder D, Wettan H. Maxillary sinus augmentation with deproteinized bovine bone and platelet rich plasma with simultaneous insertion of endosseous implants. *J Oral Maxillofac Implants*. 2003;61:157–163.
42. Furst G, Gruber R, Tangl S, et al. Sinus grafting with autogenous platelet-rich plasma and bovine hydroxyapatite. A histomorphometric study in minipigs. *Clin Oral Implants Res*. 2003;14:500–508.
43. Haas R, Baron M, Donath K, Zechner W, Watzek G. Porous hydroxyapatite for grafting the maxillary sinus: a comparative histomorphometric study in sheep. *Int J Oral Maxillofac Implants*. 2002;17:337–346.
44. Yildirim M, Spiekermann H, Biesterfeld, Edelhoff D. Maxillary sinus augmentation using xenogenic bone substitute material Bio-Oss^R in combination with venous blood. A histologic and histomorphometric study in humans. *Clin Oral Implants Res*. 2000;11:217–229.
45. Hurzeler MB, Quinones CR, Kirsch A, et al. Maxillary sinus augmentation using different grafting materials and dental implants in monkeys. Part I. Evaluation of anorganic bovine-derived bone matrix. *Clin Oral Implants Res*. 1997;8:476–486.
46. Margolin MD, Cogan AG, Taylor M, et al. Maxillary sinus augmentation in the non-human primate: a comparative radiographic and histologic study between recombinant human Osteogenic Protein-1 and natural bone mineral. *J Periodontol*. 1998;69:911–919.
47. Artzi Z, Tal H, Dayan D. Porous bovine bone mineral in healing of human extraction sockets. Part 1: histomorphometric evaluations at 9 months. *J Periodontol*. 2000;71:1015–1023.
48. Landi L, Pretel RW, Hakimi NM, Setayesh R. Maxillary sinus floor elevation using a combination of DFDBA and bovine-derived porous hydroxyapatite: a preliminary histologic and histomorphometric report. *Int J Periodont Restor Dent*. 2000;20:575–583.
49. Piattelli A, Scarano A, Quaranta M. High precision, cost-effective system for producing thin sections of oral tissues containing dental implants. *Biomaterials*. 1997;18:577–579.
50. Mayfield LJA, Skoglund A, Hising P, Lang NP, Attstrom R. Evaluation following functional loading of titanium fixtures placed in ridges augmented by deproteinized bone mineral. A human case study. *Clin Oral Implants Res*. 2001;12:508–514.