

## Case Report

# Orthodontic Treatment of a Patient with Stickler Syndrome

Naoto Suda<sup>a</sup>; Sachiko Handa<sup>b</sup>; Norihisa Higashihori<sup>c</sup>; Takuya Ogawa<sup>c</sup>; Michiko Tsuji<sup>d</sup>; Kimie Ohyama<sup>e</sup>

### ABSTRACT

Stickler syndrome (MIM 108300, 604841, 184840) is an autosomal dominant disease characterized by midfacial flattening and variable disorders of vision, hearing and articulation. There are three types of the syndrome caused by mutations in different genes (type 1, *COL2A1*; type 2, *COL11A1*; and type 3, *COL11A2*). About 20% of type 1 patients have cleft palate or bifid uvula, but there have been no case reports of orthodontic treatment of this syndrome so far. The Japanese female patient presented here with Stickler syndrome was characterized by a flat midface and had high myopia, sensorineural hearing loss, enlarged joints, and cleft of the soft palate. She had fairly small SNA and SNB angles and a steep mandibular plane with an enlarged gonial angle. The incisors of both arches were retroclined, and a large overjet and overbite were noted. Orthodontic treatment was initiated at 11 years of age using a lingual arch appliance followed by an edgewise multibracket appliance. Stable functional occlusion was obtained after the treatment. Most of the other seven Stickler syndrome patients exhibited pretreatment characteristics of small SNA and SNB angles, steep mandibular planes, enlarged gonial angles, and retroclined incisors of both arches, demonstrating the characteristic skeletal and occlusal features of this syndrome.

**KEY WORDS:** Stickler syndrome; Orthodontic treatment

### INTRODUCTION

Stickler and Pugh<sup>1</sup> first reported the classic form of Stickler syndrome, now referred to as Stickler syndrome type 1 (MIM 108300) in 1967. It is characterized by flat

midface, high myopia, retinal detachment, cataracts, hearing loss, arthropathy, and cleft palate (or bifid uvula) and constitutes about 70% of all Stickler syndrome cases.

Type 2 (MIM 604841), representing 25% of all Stickler syndrome cases, is also characterized by midface

<sup>a</sup> Lecturer, Maxillofacial Orthognathics, Department of Maxillofacial Reconstruction and Function, Division of Maxillofacial/Neck Reconstruction, Graduate School, Tokyo Medical and Dental University, Tokyo, Japan.

<sup>b</sup> Clinical Fellow, Maxillofacial Orthognathics, Department of Maxillofacial Reconstruction and Function, Division of Maxillofacial/Neck Reconstruction, Graduate School, Tokyo Medical and Dental University, Tokyo, Japan.

<sup>c</sup> Dental Resident, Maxillofacial Orthognathics, Department of Maxillofacial Reconstruction and Function, Division of Maxillofacial/Neck Reconstruction, Graduate School, Tokyo Medical and Dental University, Tokyo, Japan.

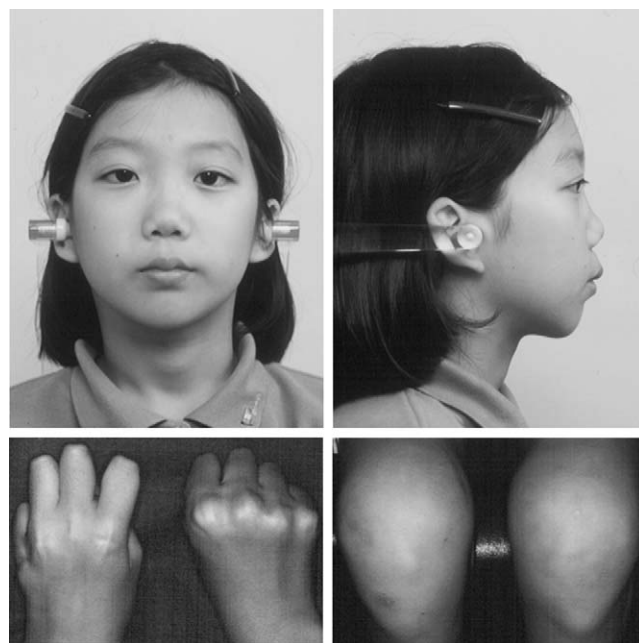<sup>d</sup> Assistant Professor, Maxillofacial Orthognathics, Department of Maxillofacial Reconstruction and Function, Division of Maxillofacial/Neck Reconstruction, Graduate School, Tokyo Medical and Dental University, Tokyo, Japan.

<sup>e</sup> Ex-Professor, Maxillofacial Orthognathics, Department of Maxillofacial Reconstruction and Function, Division of Maxillofacial/Neck Reconstruction, Graduate School, Tokyo Medical and Dental University, Tokyo, Japan.

Corresponding author: Dr Naoto Suda, Maxillofacial Orthognathics, Department of Maxillofacial Reconstruction and Function, Division of Maxillofacial/Neck Reconstruction, Graduate School, Tokyo Medical and Dental University, 1-5-45 Yushima, Bunkyo-ku, Tokyo, 113-8549, Japan (e-mail: n-suda.mort@tmd.ac.jp)

Accepted: October 2006. Submitted: August 2006.

© 2007 by The EH Angle Education and Research Foundation, Inc.



**Figure 1.** Pretreatment frontal and lateral facial photographs and joints at 11 years 4 months of age.

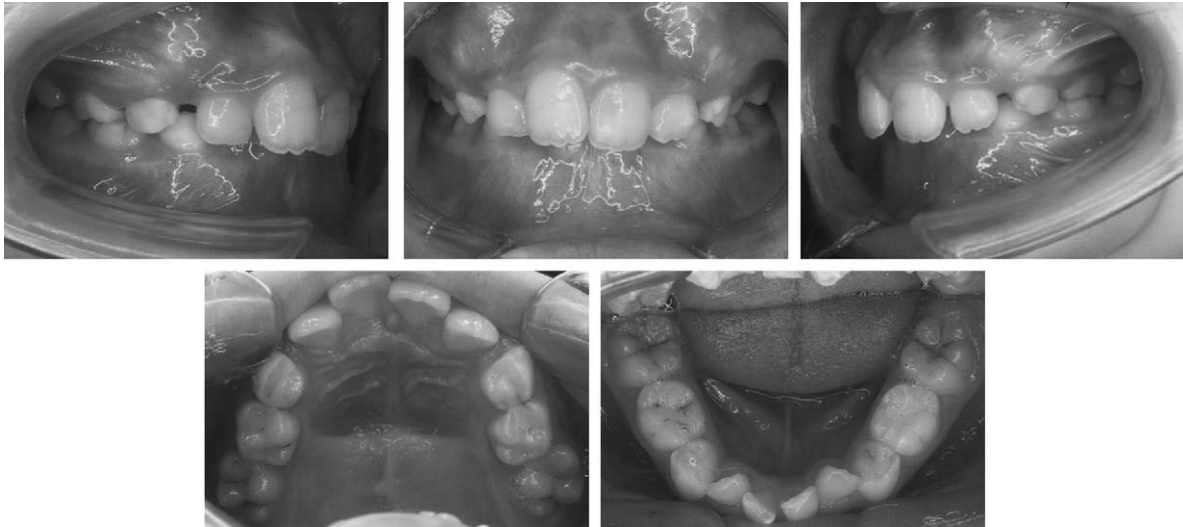

Figure 2. Pretreatment intraoral photographs.

hypoplasia, myopia, anteverted nares, and hearing loss.<sup>2</sup> Arthropathy is not necessarily present in type 2. Both types are inherited in an autosomal dominant manner, and a differential diagnosis distinguishing between these types from the symptoms is not easy.<sup>3</sup>

Recently, responsible genes for types 1 and 2 are identified as *COL2A1*<sup>4</sup> and *COL11A1*,<sup>5</sup> respectively.

The final type (type 3) of the syndrome is referred as nonocular type (oto-spondylo-megepiphyseal dysplasia, MIM 184840), lacking eye involvement but

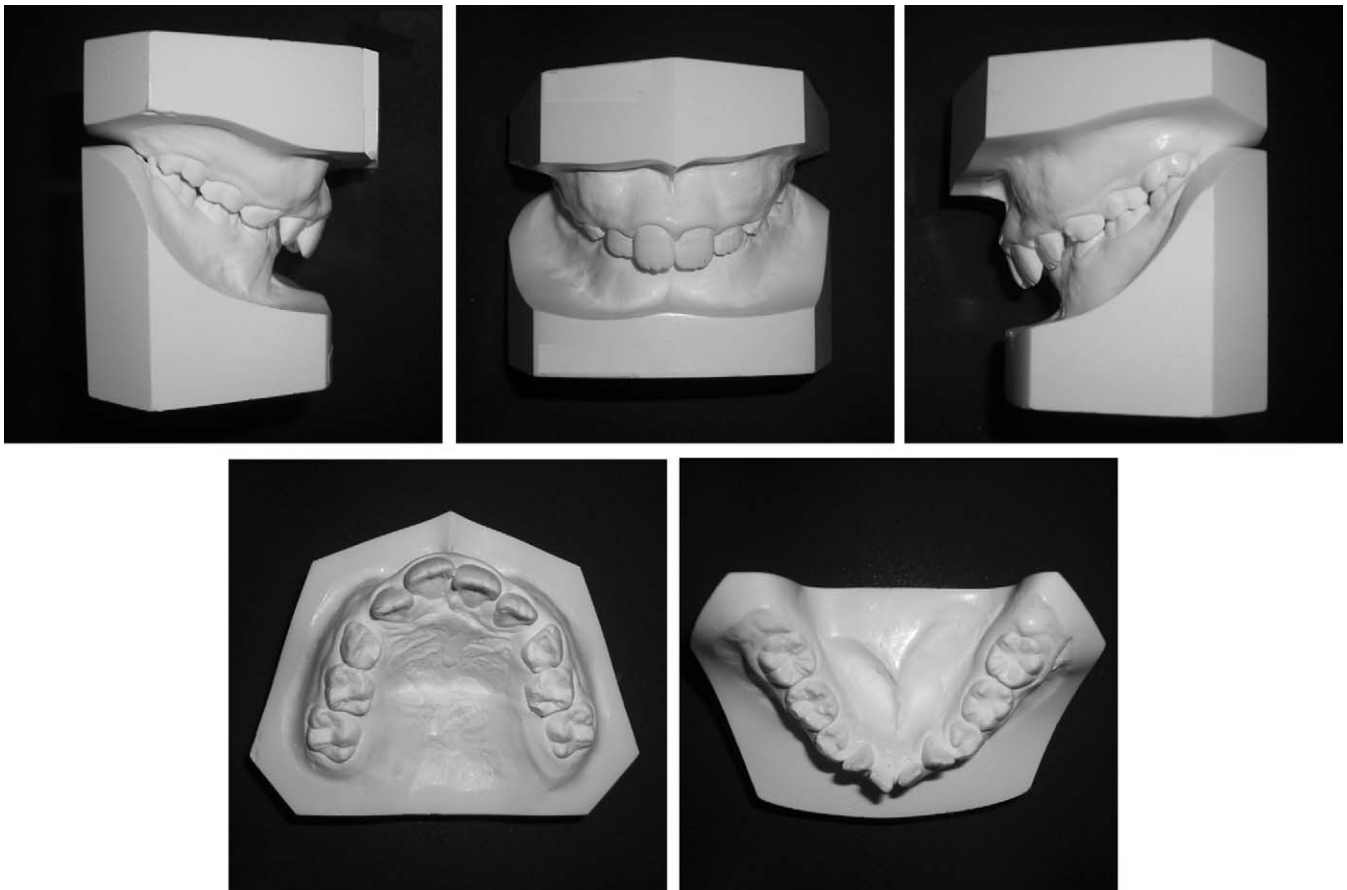
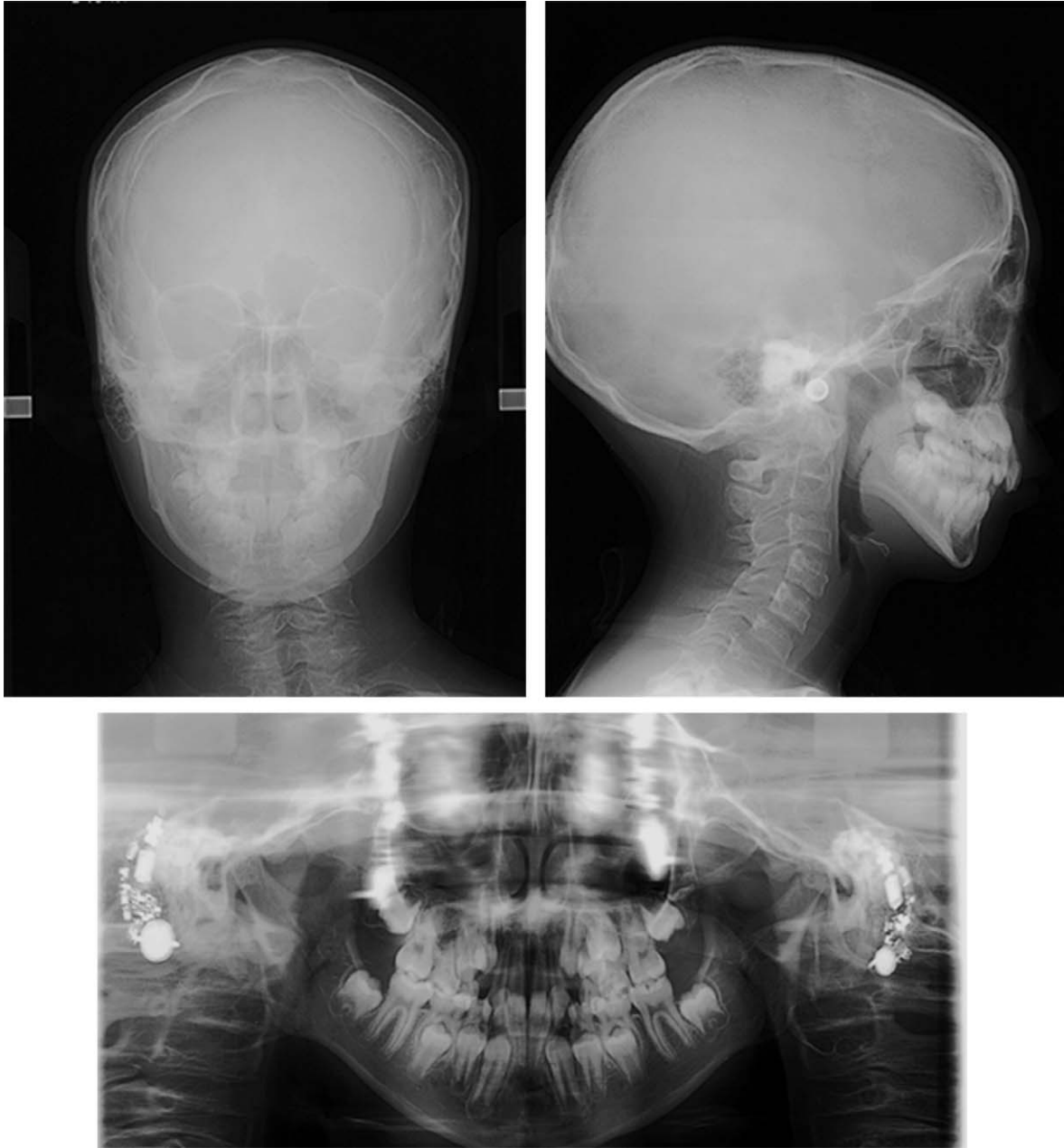

Figure 3. Pretreatment dental cast.



**Figure 4.** Pretreatment radiographs.

sharing the other symptoms in types 1 and 2.<sup>6</sup> Type 3 is inherited in an autosomal dominant or recessive manner, and the responsible gene has been identified as *COL11A2*.

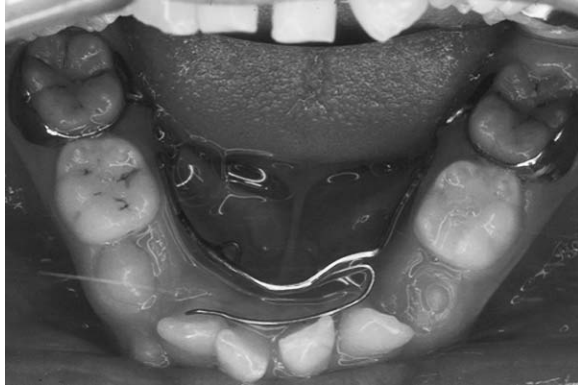
There have been no case reports of orthodontic treatment of Stickler syndrome so far. The present report describes the orthodontic treatment of a Japanese female patient with the syndrome who was characterized by a flat midface and showed high myopia, sensorineural hearing loss, enlarged joints, and cleft of the soft palate. The pretreatment characteristics of other seven cases of Stickler syndrome are also discussed in this report.

## CASE REPORTS

### Diagnosis and Etiology

The present Japanese female patient was born to healthy parents. She has an older brother without any congenital anomalies, and no other family members are affected with this syndrome. She was born in a normal gestational period. At birth, the patient was 49.0 cm in length and weighed 3,580 g. She had a cleft of the soft palate, which was surgically closed at 1 year 11 months of age. She had high myopia, internal strabismus, and enlargement of the knee joints. Surgical procedures for these features were undertaken





**Figure 5.** Intraoral photograph during the first phase of treatment with a lingual arch at 11 years 7 months of age.

en at 6 and 7 years of age, respectively. She also had sensorineural hearing loss, and a hearing aid was used from 2 years of age.

She presented to our orthodontic clinic at 11 years 4 months with a chief complaint of maxillary protrusion. She showed midfacial flattening with a retarded chin point, protrusive lips, depressed nasal bridge, anteverted nares, long philtrum, and low-set ears (Figure 1). Even though she had surgery for internal strabismus and joints, right strabismus and enlargement of joints in finger, knee, elbow, wrist, and ankle were noted at this stage. Considering disorders in the eyes, hearing, joints, and cleft palate, she was diagnosed with Stickler syndrome. A large overjet (+11.5 mm) and deep overbite (+10.0 mm) were noted in the mixed dentition (Figures 2 and 3). Crowding of the anterior teeth was seen in both arches, and it was projected that this would become serious in the future permanent dentition.

A panoramic radiograph showed a congenitally

**Table 1.** Analytical Measurements (Degrees) Before and After Treatment of the Present Case

	Before Treatment (11 yr 2 mo)	After Treatment (20 yr 9 mo)
SNA	73.9 (80.5 ± 3.5)	73.6 (82.3 ± 3.5)
SNB	70.2 (76.2 ± 1.7)	69.9 (78.9 ± 3.5)
ANB	3.7 (4.3)	3.7 (3.4)
U-1 to FH plane	92.6 (110.6 ± 1.6)	100.6 (111.1 ± 5.5)
L-1 to mandibular plane	79.7 (94.1 ± 6.2)	94.3 (96.3 ± 5.8)
Mandibular plane angle	44.2 (32.4 ± 4.5)	44.9 (28.8 ± 5.2)
Gonial angle	138.58 (128.3 ± 3.7)	139.1 (122.2 ± 4.6)

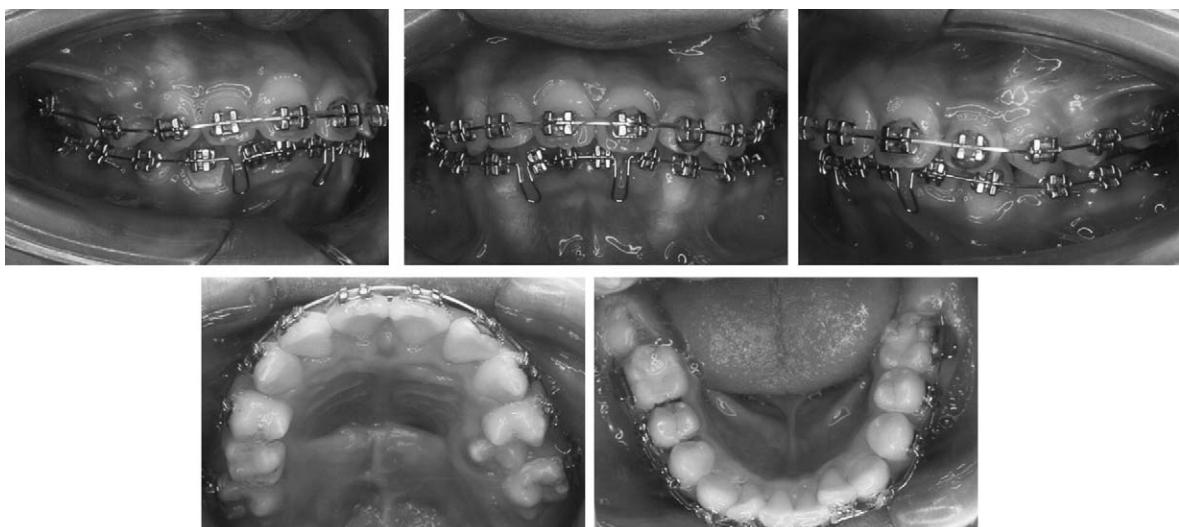
S indicates sella turcica; N, nasion; A, point A; SNA, angle between SN and NA; B, point B; SNB, angle between SN and NB; U-1, long axis of maxillary central incisor; U-1 to FH plane, angle between U-1 and FH (Frankfort horizontal) plane; L-1, long axis of mandibular central incisor; L-1 to mandibular plane, angle between L-1 and mandibular plane; mandibular plane angle, angle between mandibular plane and FH plane; and gonial angle, angle between mandibular plane and ramus plane. Numbers in parentheses denote the means ± standard deviation of the Japanese norms at various dental development stages.

missing maxillary right second premolar (Figure 4). The lateral cephalogram showed retroclined incisors in both arches and fusion of the cervical bones (C2 and C3). The cephalometric analysis showed that SNA and SNB were smaller than the Japanese norm<sup>7</sup> (Table 1). The incisors were significantly retroclined in both arches, and the mandibular plane angle was steep with an enlarged gonial angle.

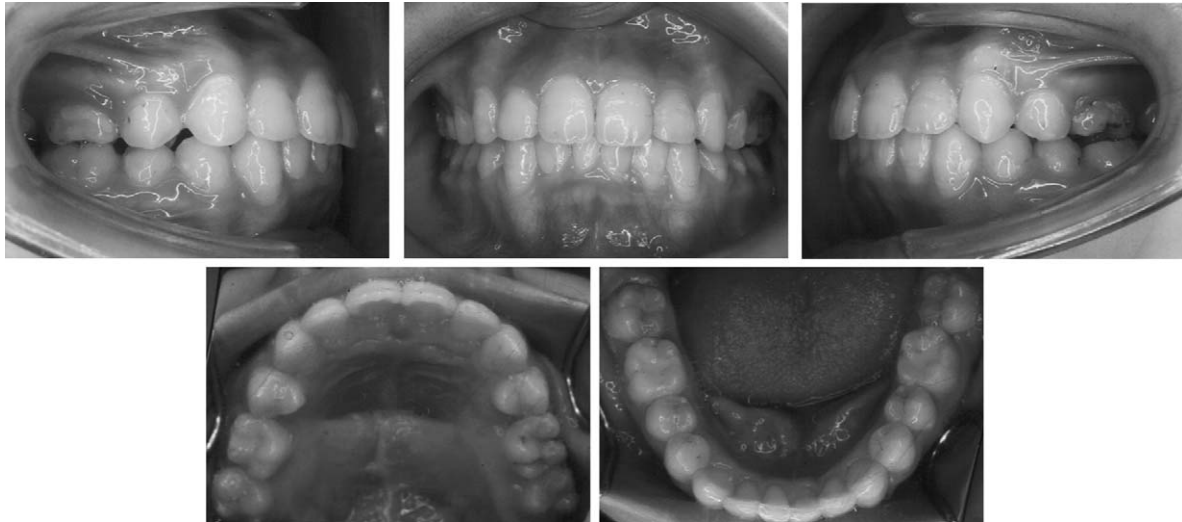### Treatment Objectives and Alternatives

The treatment objectives were (1) to eliminate the arch length discrepancies in the maxillary arch by extraction and (2) to correct the large overjet and deep bite and align both arches.

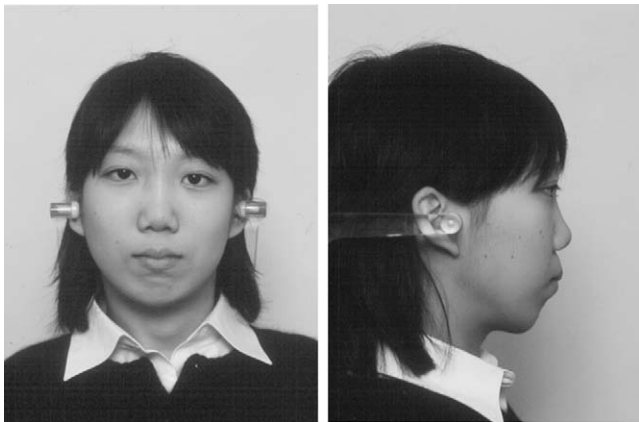
To accomplish these objectives, labial tipping of the



**Figure 6.** Intraoral photographs during the second phase of treatment at 14 years 3 months of age.



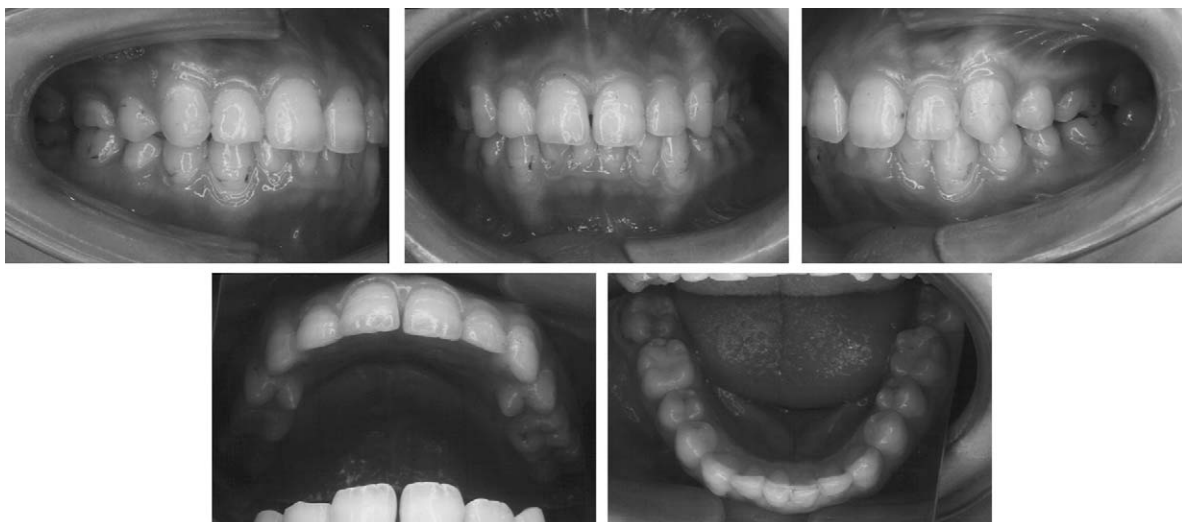**Figure 7.** Intraoral photographs after the active treatment at 16 years 4 months of age.



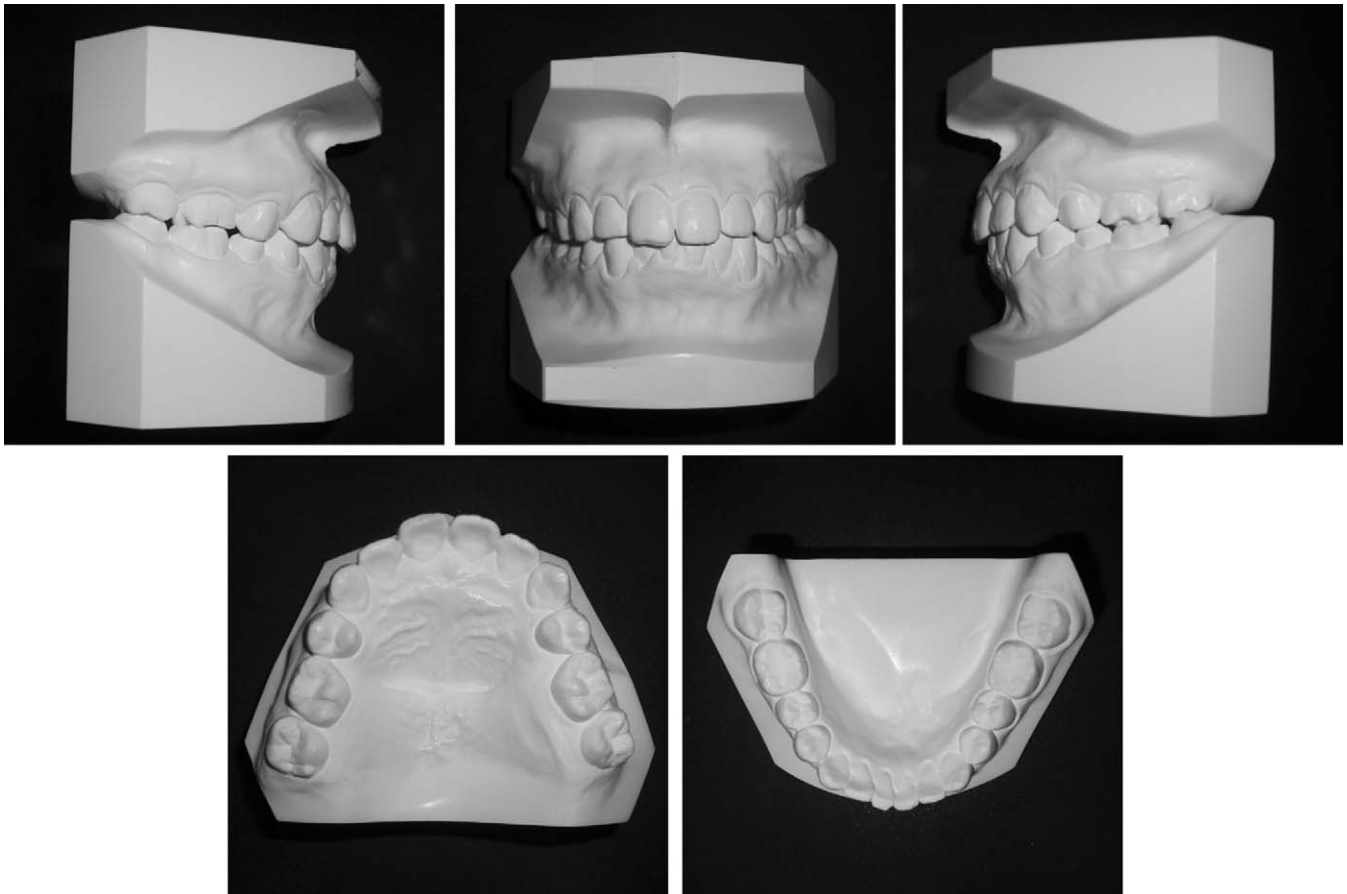**Figure 8.** Posttreatment frontal and lateral facial photographs at 20 years of age.

retroclined mandibular incisors was planned in the first phase of treatment. After the eruption of the permanent lateral dentition, alignment of the maxillary arch was planned with the extraction of the maxillary right deciduous second molar and left second premolar. Labial and lateral expansion of the mandibular arch was planned without any extraction of the lower teeth. Since the patient had undergone surgical palatal closure, careful observation of the maxillary growth was required.

As treatment alternatives, extraction of mandibular teeth was considered to eliminate the arch length discrepancy and obtain a class I molar relationship. However, in this case, a large amount of horizontal mandibular growth was not expected. Thus, it was planned to tip the mandibular incisors without the mandibular



**Figure 9.** Posttreatment intraoral photographs.



**Figure 10.** Posttreatment dental cast.

premolar extraction. As the alternative to extraction, the maxillary left first premolar instead of the second premolar was considered. However, since the second premolar had erupted in a lingual position and the opposite-side tooth was missing, this tooth was chosen for the extraction in the maxillary arch.

### Treatment Progress

For the first phase of treatment, at 11 years 7 months of age, the lingual arch was placed in the mandibular arch to tip the incisors labially (Figure 5). After the teeth in the lateral dentition had erupted, at 13 years 9 months of age, an edgewise multibracket appliance was placed to align both arches and to correct the large overjet and deep bite. Oral photos during the second phase of treatment are shown in Figure 6. The maxillary right deciduous second molar and left second premolars were extracted at 14 years 5 months of age. At 16 years 4 months of age, a stable and functional occlusion was obtained with a favorable amount of overjet and overbite (Figure 7). Retention was initiated using removable retainers in both arches up to 20 years of age. The facial photos at this stage showed a slight long face with midfacial flattening and

retarded chin point (Figure 8). The protrusive lips in her profile were improved after the treatment. Oral photos and a model showed a small space between the maxillary central incisors, minor crowding in the mandibular anterior teeth, and a slightly increased overbite, but the functional occlusion was maintained during the retention period (Figures 9 and 10). A panoramic radiograph showed that the teeth were aligned in a parallel manner without significant root resorption. Cephalograms showed enlarged cervical bones and a protruded chin point in the mandible (Figure 11).

### Treatment Results

The values of SNA and SNB did not change during treatment and remained significantly smaller than the Japanese norm<sup>7</sup> (Table 1). The gonial and mandibular plane angles also did not change during the treatment and remained extremely higher than the Japanese norm.<sup>7</sup> Significant and moderate labial tipping of the mandibular and maxillary incisors were noted, respectively. The growth directions of the maxilla and mandible were mainly downward (Figure 12), which would help toward obtaining a favorable overbite in this case.

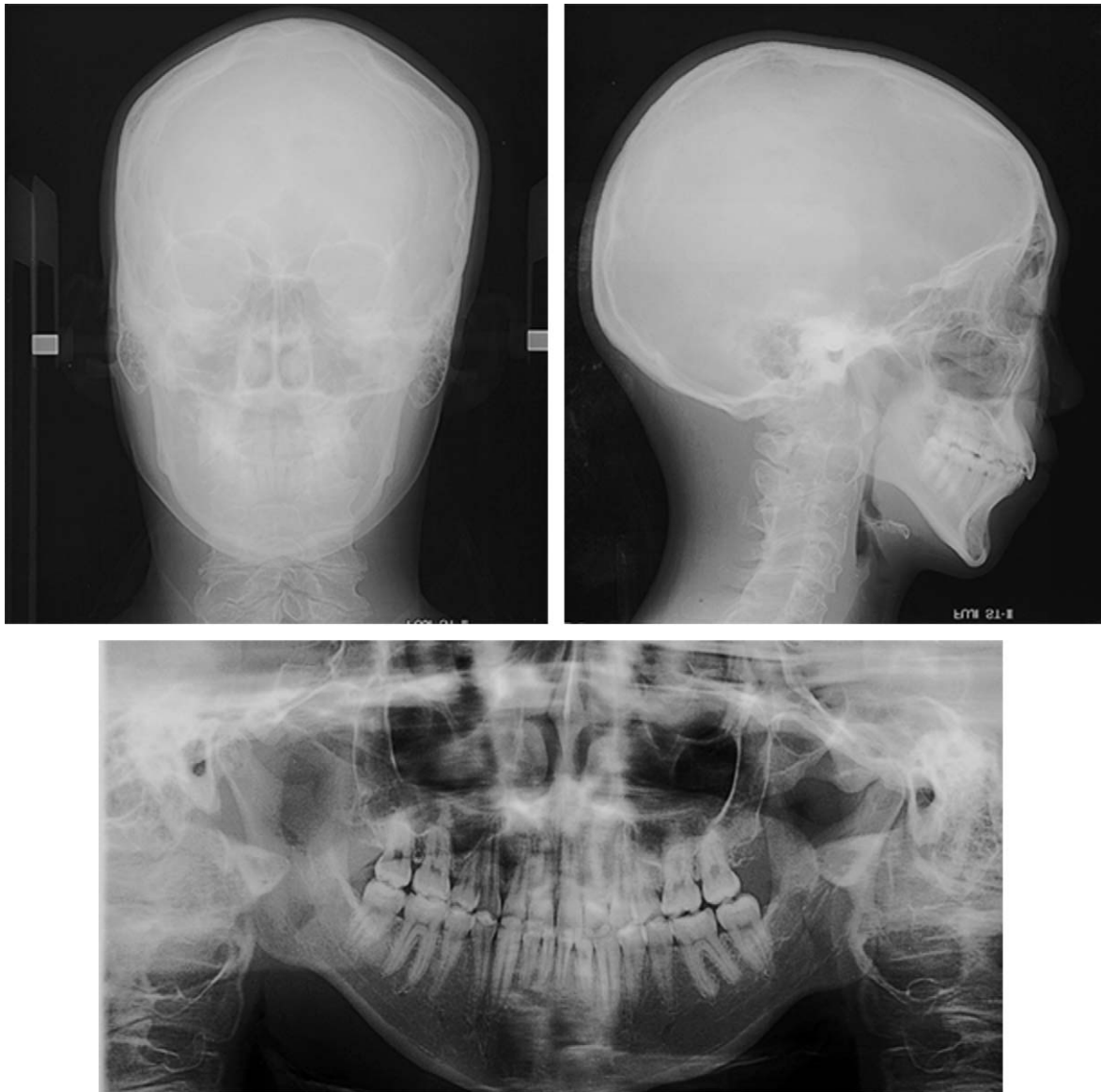

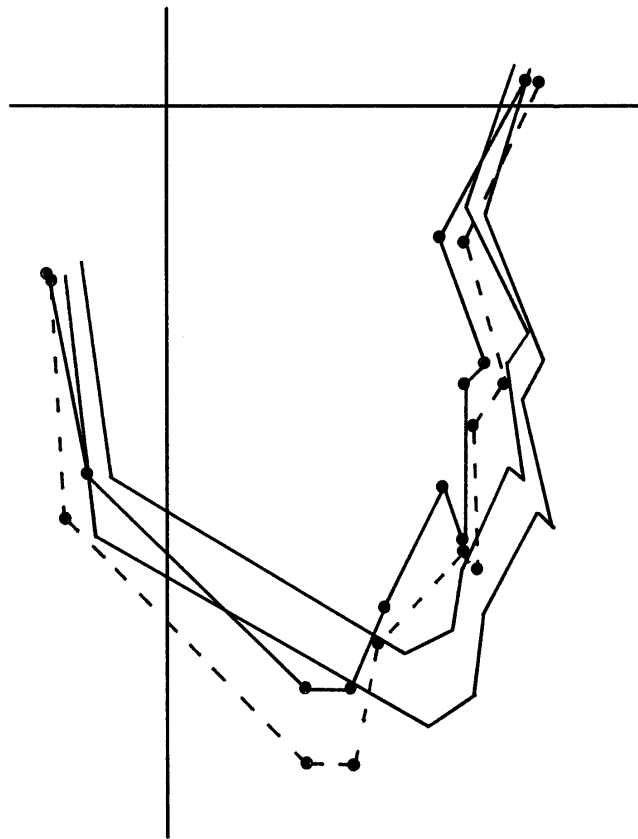
Figure 11. Posttreatment radiographs.

Table 2. Clinical Features of Eight Stickler Syndrome Cases

Feature	Present Case, Female (11 yr 2 mo)	Cases 2 and 3, Male (7 yr 5 mo)	Case 4, Male (9 yr 11 mo)	Case 5, Female (10 yr 3 mo)	Case 6, Female (9 yr 10 mo)	Case 7, Female (10 yr 4 mo)	Case 8, Female (13 yr 2 mo)
Eye	IS, high myopia	RD, myopia	Myopia	RD	—	Myopia	RD, myopia
Ear	Hearing loss, low-set ear	—	Hearing loss	—	—	—	—
Articulation	Enlargement (finger, knee, elbow, wrist, and ankle)	—	Arthropathy	Enlargement	Enlargement	Enlargement	Enlargement
Cleft	Soft palate	Palate	Palate	Palate	Palate	Palate	Palate

IS indicates internal strabismus; RD, retinal detachment.





**Figure 12.** Superimposed profilograms of the present case. Pretreatment at 11 years 4 months of age (—●—) and posttreatment at 20 years of age (---●---). The Japanese female norms<sup>9</sup> at 10 years 3 months of age and 17 years 7 months of age are denoted by solid lines without symbols.

**Pretreatment Characteristics of Seven Other Stickler Syndrome Patients**

To investigate the pretreatment characteristics in Stickler syndrome patients, clinical features and ceph-

alometric measures of the present case and seven other cases are shown in Tables 2 and 3, respectively. Case 2 (male, 7 years 5 months of age) and Case 3 (male) were twins and had retinal detachment, myopia, and cleft palate. Their father and grandfather also had severe myopia, and six siblings of their father died before 3 years of age. Case 4 (male, 9 years 11 months of age) had myopia, hearing loss, arthropathy, and cleft palate. Case 5 (female, 10 years 3 months of age) had retinal detachment, joint enlargement, and cleft palate. Her brother and mother also demonstrated retinal detachment. Case 6 (female, 9 years 10 months of age) had joint enlargement and cleft palate. Her mother also had severe myopia, and her grandmother was blind in his mid 30s. Case 7 (female, 10 years 4 months of age) had myopia, joint enlargement, and cleft palate. Her mother and maternal uncle also had severe myopia. Case 8 (female, 13 years 2 months of age) had retinal detachment, myopia, joint enlargement, and cleft palate. Her father and two sisters also showed retinal detachment.

All cases showed smaller SNA angles, and seven cases showed smaller SNB angles than the Japanese norm.<sup>7</sup> Retroclined maxillary incisors were noted in all cases except case 8. Retroclined mandibular incisors were seen in all cases. The mandibular plane angle was larger in seven cases, and the gonial angle was larger in all cases than the Japanese norm.<sup>7</sup>

**DISCUSSION**

It is known that patients with Stickler syndrome show midface flattening.<sup>3</sup> Some variations are seen among cases with this syndrome.<sup>9</sup> However, most of the eight Stickler syndrome patients exhibited the pretreatment characteristics of small SNA and SNB angles, steep mandibular planes, enlarged gonial angles,

**Table 3.** Analytical Measurement (Degrees) of Eight Stickler Syndrome Cases Before Treatment

Value	Present Case, Female (11 yr 2 mo)	Case 2, Male (7 yr 5 mo)	Case 3, Male (7 yr 5 mo)	Case 4, Male (9 yr 11 mo)	Case 5, Female (10 yr 3 mo)	Case 6, Female (9 yr 10 mo)	Case 7, Female (10 yr 4 mo)	Case 8, Female (13 yr 2 mo)
SNA	73.9 (80.5)	80.8 (81.4)	80.0 (81.4)	71.1 (80.9)	74.5 (80.5)	75.7 (80.5)	74.9 (80.5)	74.3 (80.5)
SNB	70.2 (76.2)	76.1 (76.2)	76.8 (76.2)	67.7 (76.2)	72.5 (76.2)	73.9 (76.2)	71.2 (76.2)	70.2 (76.2)
ANB	3.7 (4.3)	4.4 (5.2)	3.2 (5.2)	3.4 (4.7)	2.0 (4.3)	1.8 (4.3)	3.7 (4.3)	4.1 (4.3)
U-1 to FH plane	92.6 (110.6)	103.8 (104.8)	88.2 (104.8)	107.9 (109.8)	104.3 (110.6)	103.6 (110.6)	107.2 (110.6)	111.7 (110.6)
L-1 to mandibular plane	79.7 (94.1)	82.0 (89.5)	79.5 (89.5)	73.5 (93.8)	83.9 (94.1)	90.5 (94.1)	82.9 (94.1)	87.9 (94.1)
Mandibular plane angle	44.2 (32.4)	36.3 (31.5)	40.5 (31.5)	40.8 (32.0)	31.7 (32.4)	36.3 (32.4)	33.5 (32.4)	40.3 (32.4)
Gonial angle	138.5 (128.3)	140.5 (130.1)	143.2 (130.1)	139.3 (129.2)	132.4 (128.3)	133.7 (128.3)	129.5 (128.3)	134.9 (128.3)

S indicates sella turcica; N, nasion; A, point A; SNA, angle between SN and NA; B, point B; SNB, angle between SN and NB; U-1, long axis of maxillary central incisor; U-1 to FH plane, angle between U-1 and FH (Frankfort horizontal) plane; L-1, long axis of mandibular central incisor; L-1 to mandibular plane, angle between L-1 and mandibular plane; mandibular plane angle, angle between mandibular plane and FH plane; and gonial angle, angle between mandibular plane and ramus plane. Numbers in parentheses denote the Japanese norms at various dental development stages.



and retroclined incisors in both arches, suggesting the skeletal and occlusal characteristics frequently seen in this syndrome (Table 3). In our previous study, we examined cephalometric measures in Robin sequence patients.<sup>10</sup> Robin sequence patients, like the present Stickler syndrome patients, have a steep mandibular plane and smaller SNA and SNB angles. However, overall, the ANB angle was larger in the Robin sequence patients than in the present cases because of the severity of the size of the mandible.

The growth direction of maxilla and mandible was mainly downward in the present case (Figure 12). This was also the case in the Robin sequence patients.<sup>10</sup> The present eight cases all had cleft palate and palatal closure performed at young ages, which should affect the maxillary growth. It would be valuable to clarify whether the mutations in the collagen genes cause the characteristic growth pattern seen in Stickler syndrome.

In the present Stickler syndrome case, right strabismus and enlargement of joints in the fingers, knees, elbows, wrists, and ankles were noted at 11 years of age. The patient had been using a hearing aid and had begun using a walking stick from the retention period. She came to have pain in her waist after standing for a while. She had pain in the temporomandibular joint at the wide open position. Considering these progressive symptoms, it is essential to follow up the systemic condition carefully as well as the occlusion. Furthermore, when treating patients with midface flattening with disorders in the eye and/or ear and/or joints, special care is required for the differential diagnosis of Stickler syndrome.

## CONCLUSIONS

- Most of the eight Stickler syndrome patients exhibited smaller SNA and SNB angles, retroclined incisors of both arches, and a steep mandibular plane with an enlarged gonial angle.

- The growth direction of the maxilla and mandible was mainly downward in the present treated case.
- It is necessary to pay special attention to the systemic condition when treating patients with midface flattening and disorders in eye and/or ear and/or joints.

## REFERENCES

1. Stickler GB, Pugh DG. Hereditary progressive arthroophthalmopathy. II. Additional observation on vertebral anomalies, a hearing defect and a report of a similar case. *Mayo Clin Proc.* 1967;42:495–500.
2. Snead MP, Yates JR, Williams R, Payne SJ, Pope FM, Scott JD. Stickler syndrome type 2 and linkage to the *COL11A1* gene. *Ann N Y Acad Sci.* 1996;785:331–332.
3. Gorlin RJ, Cohen MM Jr, Hennekam RCM. Syndromes affecting bone; other skeletal dysplasia. In: Gorlin RJ, Cohen MM Jr, Hennekam RCM, eds. *Syndromes of the Head and Neck.* 4th ed. New York, NY: Oxford University Press; 2001: 305–365.
4. Ahmad NN, Ala-Kokko L, Knowlton RG, Jimenez SA, Weaver EJ, Maguire JL, Tasman W, Prockop DJ. Related. Stop codon in the procollagen II gene (*COL2A1*) in a family with the Stickler syndrome (arthro-ophthalmopathy). *Proc Natl Acad Sci U S A.* 1991;88:6624–6627.
5. Martin S, Richards AJ, Yates JR, Scott JD, Pope M, Snead MP. Stickler syndrome: further mutations in *COL11A1* and evidence for additional locus heterogeneity. *Eur J Hum Genet.* 1999;7:807–814.
6. Sirko-Osadsa DA, Murray MA, Scott JA, Lavery MA, Warman ML, Robin NH. Stickler syndrome without eye involvement is caused by mutations in *COL11A2*, the gene encoding the alpha2 (XI) chain of type XI collagen. *J Pediatr.* 1998;132:368–371.
7. Iizuka T. Roentgencephalometric analysis of craniofacial growth in Japanese children. *J Stomatol Soc Jpn.* 1958;25: 18–30.
8. Sakamoto T. A study on the developmental changes of dentofacial complex of the Japanese with special reference to sella turcica. *J Jpn Orthod Soc.* 1959;18:1–17.
9. Ohyama K, Iwata K, Kitsugi A, Uji M, Yamamoto M, Kuroda T. Stickler syndrome and Marshall syndrome among the cleft palate patients. *J Jpn Cleft Palate Assoc.* 1993;18: 373–380.
10. Matsuda A, Suda N, Motohashi N, Tsuji M, Ohyama K. Skeletal characteristics and treatment outcome of five cases with Robin sequence. *Angle Orthod.* 2006;76:896–906.