

## Root Shortening in Patients Treated with Two-step and En Masse Space Closure Procedures with Sliding Mechanics

Yan Huang<sup>a</sup>; Xu-Xia Wang<sup>b</sup>; Jun Zhang<sup>c</sup>; Chao Liu<sup>d</sup>

### ABSTRACT

**Objective:** To investigate the comparative amount of root shortening between two-step and en masse space closure procedures.

**Materials and Methods:** Fifty-two patients were selected from a pool of patients satisfying the following inclusion criteria: no evidence of resorption on the pretreatment panoramic radiographs; no dental trauma; no dilacerations of incisor roots, anodontia, or impacted canines; complete root formation at the start of treatment; intact and caries-free incisors; no endodontically treated incisors; Angle Class I or II malocclusion; extraction of four first premolars; and space closure with moderate anchorage. Patients received treatment with either a two-step or an en masse procedure to close the extraction spaces after alignment and leveling with the same preadjusted appliances. Root shortening of the maxillary and mandibular incisors was evaluated on panoramic radiographs, taken before and after space closure, and measured in millimeters. Distortion of measurements caused by panoramic radiographs was corrected by using special metal rods ligated to brackets. Statistical comparisons of root shortening between space closure procedures were investigated with the two-sample *t* test.

**Results:** No difference was found in the amount of root shortening between space closure procedures. The average root shortening of maxillary central and lateral incisors was  $0.43 \pm 0.12$  mm and  $0.58 \pm 0.10$  mm, respectively, and that of mandibular central and lateral incisors was  $0.23 \pm 0.07$  mm and  $0.22 \pm 0.06$  mm, respectively.

**Conclusion:** No difference should be expected in root resorption between two-step and en masse space closure procedure. (*Angle Orthod.* 2010;80:492–497.)

**KEY WORDS:** Root shortening; Space closure; Sliding mechanics; Special rod

<sup>a</sup> PhD student, Department of Orthodontics, School of Stomatology, Tongji University, Shanghai, China; Graduate MS student, Department of Orthodontics, School of Stomatology, Shandong University, Jinan, Shandong, China.

<sup>b</sup> Professor, Department of Oral and Maxillofacial Surgery, School of Stomatology, Shandong University, Jinan, Shandong, China.

<sup>c</sup> Professor, Department of Orthodontics, School of Stomatology, Shandong University, Jinan, Shandong, China.

<sup>d</sup> Resident, Department of Stomatology, Affiliated Shandong Provincial Hospital, Shandong University, Jinan, Shandong, China.

Corresponding author: Dr Jun Zhang, Department of Orthodontics, School of Stomatology, Shandong University, Wenhua West Road 44-1, Jinan, Shandong, 250012 China (e-mail: zhangj@sdu.edu.cn)

Accepted: October 2009. Submitted: March 2009.  
© 2010 by The EH Angle Education and Research Foundation, Inc.

### INTRODUCTION

External apical root resorption (EARR) is a frequent iatrogenic outcome of orthodontic treatment, which can be seen on standard radiographs,<sup>1</sup> and root shortening is usually the most evident manifestation of EARR on routine panoramic radiographs. Maxillary and mandibular incisors, especially the maxillary incisors, are most susceptible to EARR.<sup>2–4</sup>

The identification of factors implicated in the initiation and progression of EARR during orthodontic treatment has been the focus of numerous studies. These factors can be categorized as follows: (1) biological factors, (2) mechanical factors, (3) combined biological and mechanical factors, and (4) other factors.<sup>5</sup> Although no conclusive results can be drawn, the evidence in the relevant literature suggests no

**Table 1.** Clinical Patient Data

Characteristics	Total (n = 52)	Two-Step (n = 26)	En Masse (n = 26)	P
Mean ( $\pm$ SD) age (y)	15.6 $\pm$ 1.9	15.8 $\pm$ 1.8	15.4 $\pm$ 1.9	NS*
Gender				
Female	36	18	18	NS**
Male	16	8	8	
Mean ( $\pm$ SD) duration of space closure (mo)	6.9 $\pm$ 1.6	7.9 $\pm$ 1.8	5.8 $\pm$ 1.4	< .001***
Angle Class				
I	35	16	19	NS**
II	17	10	7	

\* Two-sample *t* test (NS indicates not significant); \*\* chi-square test; \*\*\* significant (two-sample *t* test).

significant relationship between EARR and gender<sup>2,6,7</sup> or between EARR and chronological age.<sup>6–10</sup> In contrast, it appears that there might be a positive correlation between EARR and dental agenesis,<sup>7,11,12</sup> trauma,<sup>13,14</sup> extraction,<sup>10,15–17</sup> treatment duration,<sup>4,15,16</sup> and amount and type of tooth movement.<sup>9,10,18</sup> Opinions differ as to the relationship of apical root resorption and malocclusion,<sup>2,6,9,17,19</sup> endodontic treatment,<sup>20–22</sup> and appliance type.<sup>10,23–25</sup>

Few studies have dealt with the prevalence and severity of EARR during different stages of orthodontic treatment. Root resorption can be detected in the early leveling stages of orthodontic treatment, and patients with EARR during the early stages of treatment are more likely to experience resorption during the following treatment period.<sup>3,26</sup> A recent study investigated the root resorption of maxillary incisors during the torquing (third stage) and nontorquing phases (first two stages) of orthodontic treatment with a tip-edge appliance and indicated that comparable amounts of EARR were shown in the first and final stages of treatment.<sup>27</sup> However, in the orthodontic literature, no studies have explored EARR during the stage of space closure.

During premolar extraction treatment, the orthodontist has several options for space closure. Two-step and en masse space closure with sliding mechanics are popular methods in the straight-wire edgewise technique to close extraction spaces. Although the two-step procedure is predictable and has excellent fail-safe characteristics, it takes longer to close space in two steps than in one step.<sup>28</sup> Because the risk of resorption increases with the duration of fixed appliance treatment,<sup>4,15,16</sup> it has been postulated that EARR would be more frequent and serious in two-step space closure than following an en masse procedure.

The present study tested the hypothesis that differences in the method of space closure would affect the root resorption of maxillary and mandibular incisors. Our purpose was to comparatively assess the severity of root shortening in patients treated with two-step and en masse procedures with sliding mechanics to close extraction spaces.

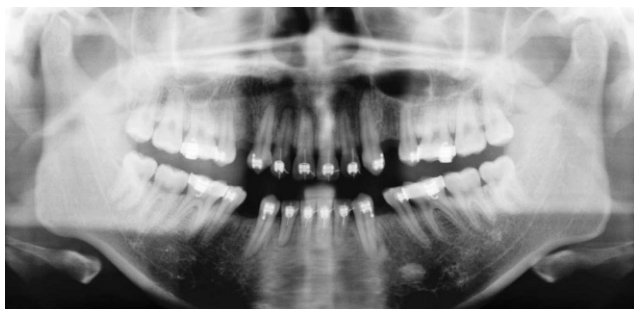
## MATERIALS AND METHODS

### Inclusion Criteria

Fifty-two patients (16 boys and 36 girls; average age, 15.6 years) who met the selection criteria were selected. Their selection was based on the following inclusion criteria: no evidence of resorption on the pretreatment panoramic radiographs; no contributing history of trauma; no severely dilacerated incisor roots, anodontia, or impacted canines; complete root formation of incisors at the start of treatment; intact and caries-free incisors; no endodontically treated incisors; Angle Class I or II malocclusion; extraction of all four first premolars; and space closure with moderate anchorage. Informed written consent was obtained from the patients and, where appropriate, the parents. The demographic data of these subjects, including gender and age at the start of space closure, are listed in Table 1.

### Method

All patients were treated with 0.022-inch bracket slot multibonded preadjusted appliances (OPA-K; Tomy, Ohkuma-machi, Japan). After alignment and leveling, extraction space closure was achieved by using 0.018- $\times$  0.025-inch steel wires. The patients were divided into two equal groups, which were treated, respectively, with either a two-step or a one-step (en masse) procedure to close the extraction spaces. In the two-step procedure group, space closure was done in two steps: first, the canines were retracted by sliding them along the archwire, and second, the four incisors were retracted with sliding mechanics. Canine and incisor retraction was carried out with 0.012-inch nickel-titanium (Ni-Ti) coil springs (Grikin, Beijing, China), which was activated to 150 g and ligated with a wire to the canine bracket hook or archwire hook, soldered mesial to the canine. In the en masse procedure group, Ni-Ti coil springs were placed across the extraction sites from the buccal tube hook on the first molar to the archwire hook, soldered mesially to the canine, and the spring was also activated to 150 g.



**Figure 1.** The metal rods were ligated to the incisors' brackets with ligature wires.

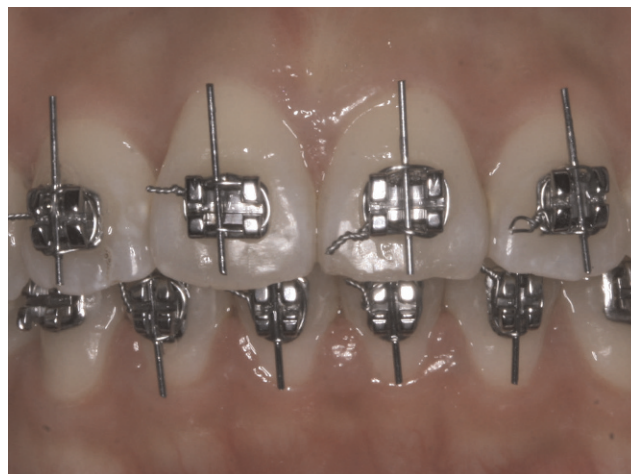The patients were recalled every 4 weeks, excess wire was clipped distal to the molar buccal tubes, and the springs were checked to confirm 150-g activation. Occlusal interferences were avoided during space closure.

The digital panoramic radiographs were obtained before and after space closure (before finishing procedure). All panoramic radiographs were taken with the same radiographic machine (Orthophos; Sirona, Bensheim, Germany) and a standardized technique. Before panoramic radiographs were obtained, eight metal rods were ligated to the incisors' brackets with ligature wires (Figure 1). The metal rods, which were made of 0.018-inch stainless steel wires, were 8.0 mm or 6.0 mm in length, as measured with venire caliper, and were ligated to maxillary and mandibular incisor brackets, respectively. The rods were parallel with the longitudinal axis of the clinical crown of each tooth.

On digital panoramic radiographs, tooth length was measured from the apex to the incisal edge along the longitudinal axis of each tooth as accurately as possible. All measurements were performed by the same clinician with the software (Sidexis; Sirona, Bensheim, Germany) with an accuracy of 0.01 mm. The length of each metal rod was also recorded, and was used as a coefficient to account for different angulation and magnification between radiographs (Figure 2). The real tooth length (T) in millimeters was calculated using the following formula:  $T = 8 \times T'/R$  or  $6 \times T'/R$ , where T' is the tooth length on the radiograph and R is the rod length on the radiograph. Root shortening per tooth was calculated using the following formula:  $T_1 - T_2$ , where T1 is the tooth length before space closure and T2 is the tooth length after space closure.

### Method Error

Method error for root resorption was determined by randomly selecting 10 radiographs and measuring them again 1 month after the original measurements



**Figure 2.** Panoramic radiograph on which the length of teeth and rods was measured.

were taken. Paired *t* tests of the replicate measurements showed no significant differences between measurements.

### Statistical Analysis

To determine whether the demographic characteristics and space closure duration differed significantly between the two treatment groups, a two-sample *t* test was carried out for the quantitative variables and a chi-square test was performed for the qualitative variables.

A two-sample *t* test was also used to test for any difference in the root length reduction in millimeters between the two groups for each examined tooth (maxillary central and lateral incisors, mandibular central and lateral incisors) separately. To test for differences in root resorption between the central and lateral incisors of both arches, a paired-samples *t* test was performed. All statistical analyses were performed with the SPSS statistical package (version 14.0; SPSS Inc, Chicago, Ill).

### RESULTS

Table 1 shows the distribution of demographic characteristics and duration of space closure in the two procedure groups. The two patient groups were well matched for sex and age. However, the space closure duration was longer ( $P < .001$ ) in the two-step procedure group than in the en masse procedure group.

In Table 2, the amount of root shortening on the maxillary and mandibular incisors is shown. Overall, the maxillary lateral incisors showed the greatest amount of root shortening, followed by the maxillary central incisors. The mandibular incisors showed the least resorption; the mandibular central and lateral incisors showed similar root shortening ( $P = .488$ ).

**Table 2.** Root Shortening (mm, Mean  $\pm$  SD) in the Treatment Groups

Incisor	Total (n = 72)	Two-Step (n = 36)	En Masse (n = 36)	P*
Maxillary				
Central	0.43 $\pm$ 0.12	0.45 $\pm$ 0.13	0.42 $\pm$ 0.12	.24, NS
Lateral	0.58 $\pm$ 0.10	0.60 $\pm$ 0.11	0.56 $\pm$ 0.08	.14, NS
P**	< .001, S	< .001, S	< .001, S	
Mandibular				
Central	0.23 $\pm$ 0.07	0.23 $\pm$ 0.06	0.23 $\pm$ 0.07	.88, NS
Lateral	0.22 $\pm$ 0.06	0.22 $\pm$ 0.07	0.23 $\pm$ 0.06	.86, NS
P**	.49, NS	.33, NS	.96, NS	

\* Two-sample *t* test for intergroup comparisons (NS indicates not significant); \*\* Paired-samples *t* test for intragroup comparisons (S indicates significant).

Negative values, indicating root elongation, were noticed for all groups of teeth. The analysis of the difference in the root resorption between the two treatment groups, in millimeters, revealed no significant difference at the 5% level for all tooth types, although the average root shortening in the en masse group was slightly less than that in the two-step group for maxillary incisors.

## DISCUSSION

We attempted to comparatively investigate the degree of root shortening at maxillary and mandibular incisors of patients treated with either two-step or en masse space closure procedures. The present results support previous findings reporting more EARR of maxillary incisors than mandibular incisors,<sup>2-4</sup> and EARR on the maxillary lateral incisors was more severe. Compared with other studies, the amount of root shortening in our study represents about one-third to one-fourth of the EARR<sup>9,15,16,29</sup> experienced during the entire orthodontic treatment period and two-thirds of the EARR<sup>3</sup> during the first 12 months of orthodontic treatment. This implies that the EARR during the stage of space closure may be the same as that which occurs during other stages of orthodontic treatment. The hypothesis is supported by the research of van Loenen et al,<sup>27</sup> which indicated that a comparable amount of EARR was shown in the first and final stages of treatment. However, further investigations are necessary to elucidate the differences in EARR during different stages of orthodontic treatment.

Many studies have shown that treatment duration had a positive association with the extent of EARR.<sup>4,15,16,25</sup> However, no statistically significant difference in root shortening was found between two-step and en masse space closure procedures, although the duration of space closure was significantly different between the two procedures. It is the canine retraction that prolongs the duration of space closure for the two-step procedure, and the roots of the incisors undergo less stress during canine retraction than during incisor retraction. This may be the reason

that the root shortening was not dependent on the duration of space closure in the present study. Although it did not reach significance, a trend was evident that indicated more EARR of the maxillary incisors for the two-step procedure, and no such trend was seen for the mandibular incisors. The susceptibility to EARR of maxillary incisors may have caused this trend. More research is needed before a definitive conclusion can be drawn on this subject.

In addition, the present study demonstrated again that it takes longer to close space in two steps than in one step. However, the two procedures do not seem to have significantly different effects on EARR. More investigation is required to analyze which procedure is superior and help clinicians to choose the optimal method.

It is difficult to compare the amount of EARR between studies because of the various methods used in the literature. Different radiographic views, including periapical,<sup>15,17</sup> panoramic,<sup>4,25</sup> and cephalometric,<sup>16,30</sup> have been used along with various measuring methods to determine the extent of EARR. Therefore, direct measurements of pretreatment and posttreatment radiographs with or without magnification correction,<sup>2,9,25</sup> expression of EARR as a percentage of loss of total tooth length,<sup>15,24</sup> and subjective ordinal scales<sup>4,17,30</sup> have been reported in the literature.

In general, panoramic radiographs are considered less accurate than periapical radiographs in studying the extent of EARR. However, Katona<sup>31</sup> claimed that the compensatory algorithms on periapical films were incapable of reliably identifying constant length roots. Sameshima and Asgarifar<sup>29</sup> found in their research that the amount of root loss was overestimated by 20% or more when panoramic films were used. Root resorption of mandibular incisors measured on panoramic films was significantly higher than when measured on periapical radiographs (panoramic 1.14 mm vs periapical 0.55 mm). At maxillary incisors, where EARR is more prevalent, the difference between the two radiographic methods was 0.13 mm (panoramic 1.34 vs periapical 1.21 mm).



Most earlier studies reported that the average root resorption of maxillary incisors was less than 2 mm after fixed orthodontic treatment.<sup>9,15,16,29</sup> The amount of root resorption in the study of Årtun et al,<sup>3</sup> in which the resorption of maxillary incisor roots was recorded 12 months after bracket placement, was much less than other studies (average 0.76 mm for all four maxillary incisors). Because the present authors investigated root shortening during one stage of orthodontic treatment (about 4 to 10 months), the amount of EARR was even lower (average 0.42 mm and 0.58 mm for maxillary central and lateral incisors, respectively). Thus, the error of 0.13 mm introduced by Sameshima and Asgarifar<sup>29</sup> could not be tolerated in our study. We used a method with a special metal rod to measure root shortening, which corrected the inaccuracy of the panoramic radiograph. This permitted us to calculate the absolute values of root lost and made the results more accurate. However, the study of Brezniak et al<sup>32</sup> indicates that even the use of a special jig cannot solve the problem of accurate measurement of tooth length changes in consecutive radiographs. So, the results of our research reveal the EARR in different space closure procedures only to a degree and may not be accurate enough. A more accurate method is required for further study.

## CONCLUSIONS

- During space closure, root shortening is greater in the maxillary incisors than in the mandibular incisors, and the maxillary lateral incisors are more susceptible to EARR than the maxillary central incisors.
- No significant difference in root resorption was seen between the two-step and en masse space closure procedures. However, the en masse procedure showed a trend of less root resorption. Validation of this finding requires further long-term investigation.
- Root shortening using both treatment modalities demonstrated was minute (about 0.5 mm) and was within the limits of error for radiographic interpretation.

## REFERENCES

1. Hartsfield JK Jr, Everett ET, Al-Qawasmi RA. Genetic factors in external apical root resorption and orthodontic treatment. *Crit Rev Oral Biol Med*. 2004;15:115–122.
2. Sameshima GT, Sinclair PM. Predicting and preventing root resorption: part I. Diagnostic factors. *Am J Orthod Dentofacial Orthop*. 2001;119:505–510.
3. Årtun J, Smale I, Behbehani F, Doppel D, Van't Hof M, Kuijpers-Jagtman AM. Apical root resorption six and 12 months after initiation of fixed orthodontic appliance therapy. *Angle Orthod*. 2005;75:919–926.
4. Apajalahti S, Peltola JS. Apical root resorption after orthodontic treatment—a retrospective study. *Eur J Orthod*. 2007;29:408–412.
5. Brezniak N, Wasserstein A. Root resorption after orthodontic treatment. Part 2. Literature review. *Am J Orthod Dentofacial Orthop*. 1993;103:138–146.
6. Harris EF, Kineret SE, Tolley EA. A heritable component for external apical root resorption in patients treated orthodontically. *Am J Orthod Dentofacial Orthop*. 1997;111:301–309.
7. Levander E, Malmgren O, Stenback K. Apical root resorption during orthodontic treatment of patients with multiple aplasia: a study of maxillary incisors. *Eur J Orthod*. 1998;20:427–434.
8. Levander E, Malmgren O. Evaluation of the risk of root resorption during orthodontic treatment: a study of upper incisors. *Eur J Orthod*. 1988;10:30–38.
9. Baumrind S, Korn EL, Boyd RL. Apical root resorption in orthodontically treated adults. *Am J Orthod Dentofacial Orthop*. 1996;110:311–320.
10. McNab S, Battistutta D, Taverne A, Symos A. External apical root resorption following orthodontic treatment. *Angle Orthod*. 2000;70:227–232.
11. Kjaer I. Morphological characteristics of dentitions developing excessive root resorption during orthodontic treatment. *Eur J Orthod*. 1995;16:25–34.
12. Thongudomporn U, Freer TJ. Anomalous dental morphology and root resorption during orthodontic treatment: a pilot study. *Aus J Orthod*. 1998;15:162–167.
13. Malmgren O, Goldson L, Hill C, Orwin A, Petrini L, Lundberg M. Root resorption after orthodontic treatment of traumatized teeth. *Am J Orthod*. 1982;82:487–491.
14. Brin I, Ben-Bassat Y, Heling I, Engelberg A. The influence of orthodontic treatment on previously traumatized incisors. *Eur J Orthod*. 1991;13:372–377.
15. Mohandesan H, Ravanmehr H, Valaei N. A radiographic analysis of external apical root resorption of maxillary incisors during active orthodontic treatment. *Eur J Orthod*. 2007;29:134–139.
16. Sameshima GT, Sinclair PM. Predicting and preventing root resorption: part II. Treatment factors. *Am J Orthod Dentofacial Orthop*. 2001;119:511–515.
17. de Freitas MR, Beltrão RT, Janson G, Henriques JF, Chiqueto K. Evaluation of root resorption after open bite treatment with and without extractions. *Am J Orthod Dentofacial Orthop*. 2007;132:143.e15–143.e22.
18. Han G, Huang S, Von den Hoff JW, Zeng X, Kuijpers-Jagtman AM. Root resorption after orthodontic intrusion and extrusion: an intra-individual study. *Angle Orthod*. 2005;75:912–918.
19. Sameshima GT, Sinclair PM. Characteristics of patients with severe root resorption. *Orthod Craniofacial Res*. 2004;7:108–114.
20. Mah R, Holland GR, Pehowich E. Periapical changes after orthodontic movement of root-filled ferret canines. *J Endod*. 1996;22:298–303.
21. Bender IB, Byers MR, Mori K. Periapical replacement resorption of permanent, vital, endodontically treated incisors after orthodontic movement: report of two cases. *J Endod*. 1997;23:768–773.
22. Esteves T, Ramos AL, Pereira CM, Hidalgo MM. Orthodontic root resorption of endodontically treated teeth. *J Endod*. 2007;33:119–122.
23. Janson GR, De Luca Canto G, Martins DR, Henriques JF, De Freitas MR. A radiographic comparison of apical root resorption after orthodontic treatment with 3 different fixed appliance techniques. *Am J Orthod Dentofacial Orthop*. 1999;118:262–273.
24. Mavragani M, Vergari A, Selliseth NJ, Bøe OE, Wisht PL. A radiographic comparison of apical root resorption after

- orthodontic treatment with a standard edgewise and a straight-wire edgewise technique. *Eur J Orthod.* 2000;22:665–674.
25. Pandis N, Nasika M, Polychronopoulou A, Eliades T. External apical root resorption in patients treated with conventional and self-ligating brackets. *Am J Orthod Dentofacial Orthop.* 2008;134:646–651.
  26. Smale I, Årtun J, Behbehani F, Doppel D, Van't Hof M, Kuijpers-Jagtman AM. Apical root resorption 6 months after initiation of fixed orthodontic appliance therapy. *Am J Orthod Dentofacial Orthop.* 2005;128:57–67.
  27. van Loenen M, Dermaut LR, Degrieck J, De Pauw GA. Apical root resorption of upper incisors during the torquing stage of the tip-edge technique. *Eur J Orthod.* 2007;29:583–588.
  28. Proffit WR, Fields HW. *Contemporary Orthodontics.* 3rd ed. St Louis, MO: Mosby; 1999.
  29. Sameshima GT, Asgarifar KO. Assessment of root resorption and root shape: periapical vs panoramic films. *Angle Orthod.* 2001;71:185–189.
  30. Brin I, Tulloch JFC, Koroluk L, Philips C. External apical root resorption in Class II malocclusion: a retrospective review of 1- versus 2-phase treatment. *Am J Orthod Dentofacial Orthop.* 2003;124:151–156.
  31. Katona TR. Flaws in root resorption assessment algorithms: role of tooth shape. *Am J Orthod Dentofacial Orthop.* 2006;130:698.e19–698.e27.
  32. Brezniak N, Goren S, Zoizner R, Dinbar A, Arad A, Wasserstein A, Heller M. The use of an individual jig in measuring tooth length changes. *Angle Orthod.* 2004;74:780–785.