

## Effects of a Mandibular Lateral Shift on the Condyle and Mandibular Bone in Growing Rats

*A Morphological and Histological Study*

Chang Liu<sup>a</sup>; Sawa Kaneko<sup>b</sup>; Kunimichi Soma<sup>c</sup>

### ABSTRACT

**Objective:** To examine the effects of mandibular lateral shift on the growth and morphology of the condyle and mandibular bone in growing rats.

**Materials and Methods:** A maxillary resin plate was designed to displace 4-week-old rat mandibles 2 mm to the left during closure. The plate was cemented, and the rats were killed after 2, 4, 8, or 12 weeks. Gross dimensions of the condylar head were measured. Radiographic films of the mandibles were exposed, and selected measurements were made. The newly formed bone in the condyle was evaluated with periodic acid and Schiff's reagent (PAS) staining.

**Results:** The length of the condylar head was greater on the ipsilateral side compared with the contralateral side. The experimental rats developed an asymmetric mandible, shorter in horizontal dimension but longer in the vertical dimension on the ipsilateral side. The mandibular growth direction was also affected, with the mandible on the ipsilateral side growing in a more anterior and superior direction. The amount of newly formed bone was greater in the superior subchondral region but lower in the posterior subchondral region on the ipsilateral side compared with the contralateral side.

**Conclusions:** Mechanical stimuli delivered by a functional shift produce a series of morphological and histological responses in the condyle and lead to condylar and mandibular asymmetry in rats.

**KEY WORDS:** Condyle; Mandible; Mandibular lateral shift

### INTRODUCTION

Mandibular asymmetry is a common finding in individuals with normal facial appearance.<sup>1</sup> However, se-

vere asymmetry can create esthetic concerns and functional abnormality.<sup>2</sup> Although the nature of the etiologic factors is still not well understood, mandibular asymmetry appears to depend on a fusion of congenital and acquired influences.<sup>3,4</sup> Functional mandibular displacement caused by unilateral posterior crossbite (UPXB) will result in mandibular asymmetry without early interceptive treatment.<sup>5</sup> Although the morphological and positional asymmetries of the mandible in children with functional UPXB are well documented, the causative mechanism has not been clarified.

Numerous studies have shown that mechanical loading plays a key role in maintaining normal morphology and function of the cartilage. As secondary cartilage, condylar cartilages can respond to mechanical factors more sensitively than primary cartilage.

The growth modification of condylar cartilage and mandibular bone has been examined extensively in animal models by positioning the mandible forward,<sup>6</sup> backward,<sup>7</sup> or downward<sup>8</sup> or by changing the food consistency.<sup>9</sup> However, the growth modification under mandibular lateral shift has received less attention. In adult rhesus monkeys with an asymmetric lateral force, a growth

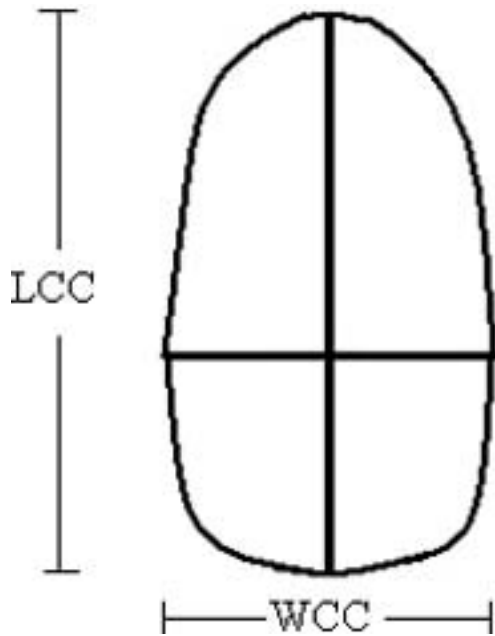
<sup>a</sup> Graduate Student, Orthodontic Science, Department of Orofacial Development and Function, Division of Oral Health Sciences, Graduate School, Tokyo Medical and Dental University, Tokyo, Japan.

<sup>b</sup> Research Assistant, Orthodontic Science, Department of Orofacial Development and Function, Division of Oral Health Sciences, Graduate School, Tokyo Medical and Dental University, Tokyo, Japan.

<sup>c</sup> Professor and Department Chair, Orthodontic Science, Department of Orofacial Development and Function, Division of Oral Health Sciences, Graduate School, Tokyo Medical and Dental University, Tokyo, Japan.

Corresponding author: Dr Chang Liu, Orthodontic Science, Department of Orofacial Development and Function, Division of Oral Health Sciences, Graduate School, Tokyo Medical and Dental University, 1-5-45, Yushima, Bunkyo-Ku, Tokyo, Tokyo 113-8549, Japan  
(e-mail: liuorts@tmd.ac.jp)

Accepted: November 2006. Submitted: September 2006.  
© 2007 by The EH Angle Education and Research Foundation, Inc.



**Figure 1.** Illustration of gross condylar measurements (for definition, see Table 1).

modification occurred on the distal surface of the condyle after 6 months.<sup>10</sup> The lateral forced bite in growing rats influenced the shape and structure of mandibular bone and composition of the masseter, leading to an asymmetric mandible.<sup>11</sup> Moreover, several studies indicated that a functional shift could increase the thickness of condylar cartilage and the proliferation of the prechondroblast on the contralateral side.<sup>12</sup> In addition, accelerated chondrocyte maturation was observed on the side opposite to incisor disocclusion after 7 days of unilateral incisor disocclusion in rats.<sup>13</sup>

Several studies have shown the morphological changes in the temporomandibular joint (TMJ), including smaller condylar head, smaller superior condylar space, and steeper eminence, on the shifted side compared with nonshifted side in asymmetric patients.<sup>14,15</sup> Meanwhile, a higher incidence of internal derangement was also reported.<sup>15</sup> Other studies also suggested that there is a higher incidence of disk displacement and temporomandibular dysfunction symptom on the deviated side than the nondeviated side in mandibular asymmetric patients.<sup>16,17</sup> These findings imply that, to some degree, the asymmetric morphology of TMJ will interact with its dysfunction.

The purpose of this study was to investigate the effect of a lateral functional shift on the morphological changes of condyle and mandibular bone and its underlying mechanism in rats.

## MATERIALS AND METHODS

Forty-eight 4-week-old male Wistar rats were randomly divided into four control and four experimental

**Table 1.** Definitions of Landmarks, Linear and Angular Measurements

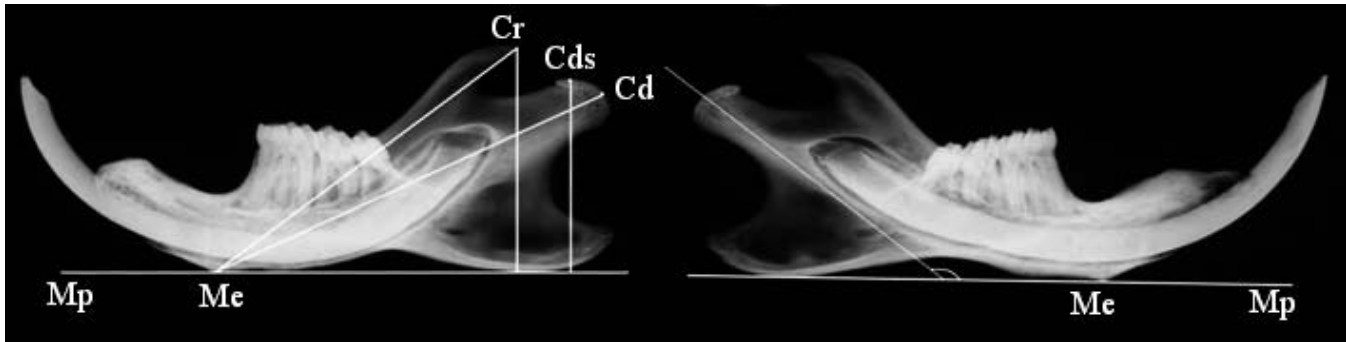
Variable	Definition
<b>Landmarks</b>	
Cd	Most posterior point of condylar head
Cds	Most superior point of condylar head
Cr	Most posterior point of coronoid process
Me	Menton
Mp	Mandibular plane
<b>Linear measurements</b>	
LCC	Maximal anteroposterior length of the condylar cartilage
WCC	Maximal mediolateral width of the condylar cartilage
Cd-Me	Length from condylar head to Me
Cds-Mp	Height from Cds to Mp
Cr-Me	Length from Cr to Me
Cr-Mp	Height from Cr to Mp
<b>Angular measurement</b>	
Stutzmann angle	Angle between the main orientation of the newly formed endochondral bone trabeculae, located in the central area of the condyle immediately under the condylar cartilage and the mandibular plane

groups (n = 6). The methods of inducing and maintaining a mandibular lateral shift 2 mm to left were those used by Liu et al.<sup>18</sup> The left side was designated as the ipsilateral side, while the right side was designated a contralateral side. The rats in the control group received no appliance.

All rats were fed with a soft diet from 3 weeks of age and were allowed free access to drinking water. The rats were weighed periodically. All procedures followed the guideline of the Tokyo Medical and Dental University for Animal Research. The experimental protocols were approved by the local ethics committee.

The rats were killed after 2, 4, 8, or 12 weeks, and the heads were fixed in 4% paraformaldehyde. After fixation, the mandible was dissected out and halved, and as much soft tissue as possible was removed. The length (LCC) and width (WCC) of the condylar cartilage were measured with a caliper accurate to 0.01 mm under stereo microscopy (Nikon SMZ-U, Kanagawa, Japan; Figure 1; Table 1).<sup>19</sup> Then, the lingual sides of the mandibles were placed in contact with FR film (Fujifilm, Tokyo, Japan), and x-ray images were obtained (23 Kvp, 5 mA, 15 seconds) using SOFTEX CMB-3 (Softex Co, Tokyo, Japan). The result was enlarged threefold and printed on photographic paper, on which the morphometric points were traced and measurements carried out (Figure 2; Table 1).<sup>11,20</sup>

The mandibles were stored at  $-80^{\circ}\text{C}$  for repeated condylar measurements 1 month later. Then, the man-



**Figure 2.** Illustration of landmarks and linear and angular measurements on the mandible (for definition, see Table 1). Notice the morphological changes in condyle and mandibular bone between the ipsilateral side (left) and contralateral side (right) in rat in the 12-week group.

dibles were decalcified and embedded in paraffin. Serial sagittal sections at 5  $\mu\text{m}$  were cut through the condylar head. The sections were stained with Periodic Acid and Schiff's reagent (Sigma, St Louis, Mo) to identify newly formed bone. The newly formed bone is in a distinctive magenta color, while the mature bone is in weak pink.

Pictures were obtained with a digital camera (Dxm 1200; Nikon, Kanagawa, Japan) with a magnification of 100 $\times$ . Image Plus-Pro (Media Cybernetics, Silver Spring, Md), which can recognize the difference in the shade of color between new bone and mature bone, was used for quantitative analysis. The areas of newly formed bone in two measurement frames of 400  $\times$  400  $\mu\text{m}$ , set just beneath the erosive front in the superior region and posterior region of the subchondral bone layer, were quantified automatically by the software (Figure 3).<sup>6</sup>

The value for the control group was obtained from the average of two sides in each rat. Analysis of covariance (ANCOVA) with body weight as the covariate was used to control the influence of body weight on linear measurements.<sup>21</sup> A paired *t*-test, as well as ANCOVA, was applied to examine the intragroup and intergroup significant differences in angular and area measurements. All the measurements were repeated for 10 randomly selected animals 1 month later by the

same observer. Hypothesis testing indicated no significant difference between the two registrations. The error of measurement was calculated with the Dahlberg's formula<sup>22</sup>:  $Me = \sqrt{\sum d^2/2n}$ . Table 2 lists the size of the method error.

## RESULTS

### Body Weight

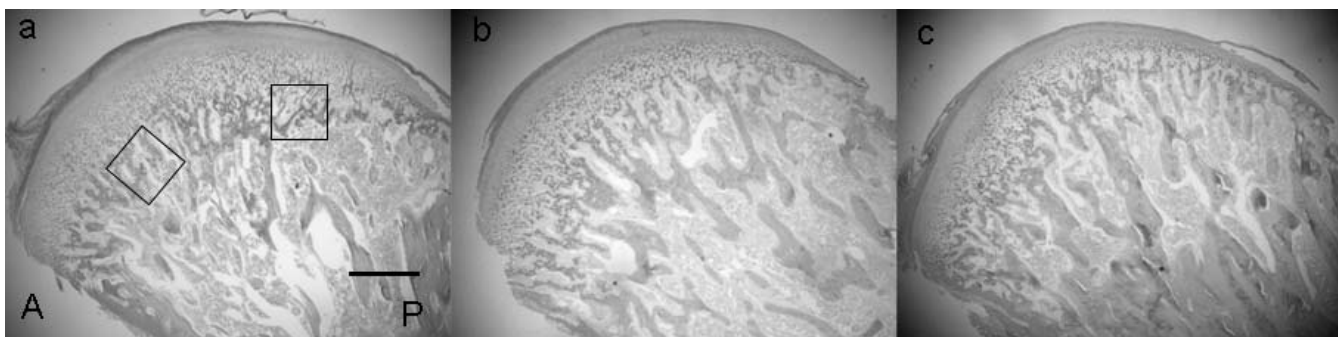
The experimental rats lost about 10% of body weight after the first week and then began to gain weight in the same way as the control group. At the end of the experiment, the average weights of experimental group and control group were  $338.7 \pm 10.2$  g and  $383 \pm 9.3$  g, respectively.

### Statistical Analysis

The correlation coefficients were high in all groups, ranging from .113 to .93. Data from the original measurements are presented in Table 3, and the adjusted data are presented in Table 4.

### Condylar Measurements

The LCC was greater on the ipsilateral side than contralateral side throughout the experiment (Table 3). No significant difference for WCC was found between



**Figure 3.** Overview of the rat's condylar head in the 4-week group with PAS staining. The two areas of interest were also shown here (a, ipsilateral side; b, contralateral side; c, control). A indicates anterior; P, posterior. Scale bar = 500  $\mu\text{m}$ .

**Table 2.** The size of Method Error *Me* in Measurements

Measurement	Method Error
Linear measurements, mm	
LCC	0.048
WCC	0.042
Cd-Me	0.03
Cds-Mp	0.029
Cr-Me	0.033
Cr-Mp	0.036
Angular measurement, (degree)	
Stutzmann angle	1.452
Area measurements, mm <sup>2</sup>	
Area 1	0.000665
Area 2	0.000589

the two sides, although the value on the ipsilateral side was much larger than on the contralateral side at 2 weeks. According to adjusted data, the LCC on the contralateral side was significantly smaller than the control group, whereas there was no significant difference between the ipsilateral side and control group (Table 4). No intergroup significant difference was found for the WCC.

## Mandibular Measurements

The Cd-Me was significantly bigger on the contralateral side than on the ipsilateral side from 4 weeks. On the other hand, the CdS-Mp was significantly smaller on the contralateral side than ipsilateral side at 4 weeks and 8 weeks (Table 3). Based on adjusted data, the Cd-Me on the contralateral side did not significantly differ from that of the control group, while on the ipsilateral side, it was significantly smaller than the control group. CdS-Mp in the experimental group was significantly smaller than the control group (Table 4). Cr-Me and Cr-Mp tended to change in the same pattern as Cd-Me and CdS-Mp.

The contralateral side showed a more opened Stutzmann angle than the ipsilateral side and control group, whereas the ipsilateral side showed a significantly closed angle at the beginning of the experiment (Figure 4).

## New Bone Formation

In the superior region, the amount of new bone formation on the contralateral side was significantly lower than on the ipsilateral side at 4 weeks (Figure 5), whereas it was significantly higher than the opposite

**Table 3.** Original Values of Linear Measurements on Condylar Head and Mandibular Bone in Experimental Groups<sup>a</sup>

	2 Wk		4 Wk		8 Wk		12 Wk	
	I	C	I	C	I	C	I	C
Linear measurements for condylar head								
LCC	3.15 ± 0.23	2.71 ± 0.23**	3.46 ± 0.25	3.1 ± 0.28**	3.5 ± 0.11	3.3 ± 0.08**	3.51 ± 0.36	3.16 ± 0.26**
WCC	1.58 ± 0.07	1.44 ± 0.17	1.49 ± 0.07	1.49 ± 0.011	1.4 ± 0.07	1.38 ± 0.09	1.4 ± 0.07	1.48 ± 0.08
Linear measurements for mandibular bone								
Cr-Me	16.7 ± 0.7	17.2 ± 0.7**	18.1 ± 0.1	18.8 ± 0.1**	19 ± 0.2	19.5 ± 0.4**	20.3 ± 0.4	20.8 ± 0.4**
Cd-Me	18.8 ± 0.7	19.4 ± 0.7**	20.4 ± 0.2	21.3 ± 0.3**	21.6 ± 0.4	22.3 ± 0.3**	22.7 ± 0.5	23.4 ± 0.4**
Cr-Mp	11 ± 0.5	10.7 ± 0.6	11.5 ± 0.3	11.3 ± 0.4*	12.3 ± 0.5	12.1 ± 0.5*	12.8 ± 0.4	12.9 ± 0.4
CdS-Mp	9.3 ± 0.3	9.1 ± 0.3	9.7 ± 0.3	9.5 ± 0.4*	10.6 ± 0.6	10.3 ± 0.5*	11.4 ± 0.6	11.4 ± 0.7

<sup>a</sup> I indicates ipsilateral side; C, contralateral side.

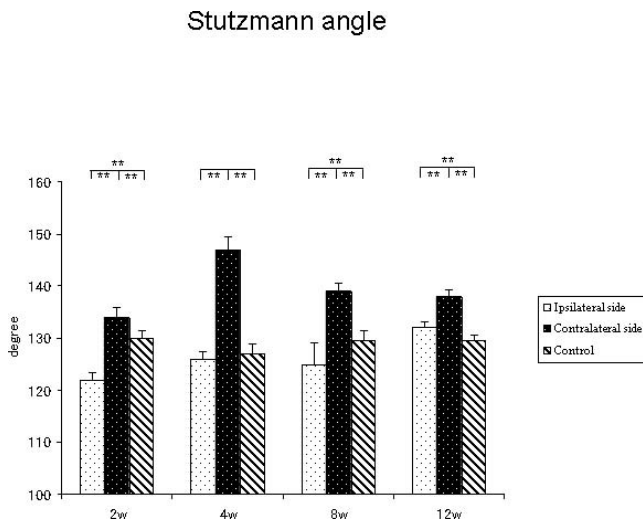
\*  $P < .05$ ; \*\*  $P < .01$  (by paired *t*-test).

**Table 4.** Adjusted Values of Linear Measurements on Condylar Head and Mandibular Bone in Experimental and Control Groups<sup>a</sup>

	2 Wk			4 Wk		
	I	Control	C	I	Control	C
Linear measurements for condylar head						
LCC	3.27 ± 0.07	3.28 ± 0.1	2.84 ± 0.07**	3.65 ± 0.07	3.54 ± 0.09	3.24 ± 0.07*
WCC	1.64 ± 0.05	1.61 ± 0.06	1.5 ± 0.05	1.47 ± 0.04	1.61 ± 0.06	1.45 ± 0.04
Linear measurements for mandibular bone						
Cr-Me	17.15 ± 1.6	17.18 ± 2.2	17.6 ± 1.6	18.01 ± 2.6**	19.6 ± 3.4	18.77 ± 2.6*
Cd-Me	19.29 ± 1.4	19.34 ± 1.9	19.9 ± 1.4	20.45 ± 3.1*	22.01 ± 4.1	21.29 ± 3.1
Cr-Mp	11.21 ± 1.9	10.94 ± 2.6	10.98 ± 1.9	11.5 ± .7**	12.66 ± 2.2	11.27 ± 1.7**
CdS-Mp	9.49 ± 1.5	9.86 ± 2.1	9.12 ± 1.5*	9.62 ± 1.7**	11.15 ± 2.5	9.41 ± 1.9**

<sup>a</sup> I indicates ipsilateral side; Control, indicates control group; and C indicates contralateral side.

\*  $P < .05$ ; \*\*  $P < .01$  (by analysis of covariance).



**Figure 4.** The change of Stutzmann angle in this experiment. \*  $P < .05$ ; \*\*  $P < .01$ .

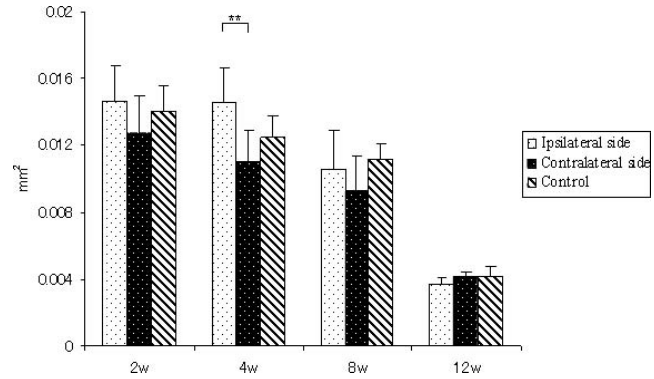
side, except at 12 weeks in the posterior region. The ipsilateral side showed a significantly lower amount of new bone formation in the posterior region than the control group at 2 weeks and 4 weeks (Figure 6).

**DISCUSSION**

The model used here has been verified by several authors to be effective in the rat.<sup>11,12,18</sup> To ensure a mandibular shift of 2 mm during this experiment, the distance was checked periodically and maintained.

The LCC on the ipsilateral side were significantly bigger than the opposite side throughout the experiment. However, previous clinical studies indicated that asymmetric patients had a larger condyle on the shifted side compared with the nonshifted side. This discrepancy can be explained by anatomic and functional difference in TMJ between rats and human beings. The rat does not have a distinct articular eminence and posterior wall in the fossa. Therefore, the change in mechanical circumstances on the condyle due to the dislocation from fossa may be different between rat and human beings.

This finding was supported by another study in rats



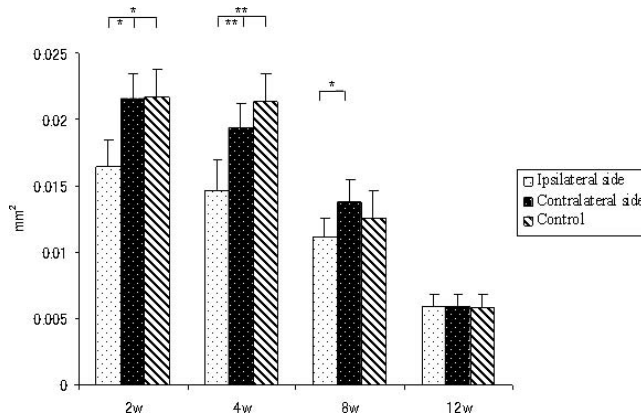
**Figure 5.** The change of the amount of newly formed bone in the superior region of the subchondral bone layer at each time point. \*  $P < .05$ ; \*\*  $P < .01$ .

in which the condylar head on the shifted side was found bigger and thicker than on the opposite side. Moreover, enhanced enzyme activity and bone apposition on the anterior border of the condyle were observed when the rat's mandible was displaced backward.<sup>23</sup> On the other hand, the change in masticatory function during a shift was supposed to contribute to this result. It has been suggested that the masseteric fibers maintained almost normal size on the ipsilateral side, whereas they decreased significantly on the contralateral side.<sup>11</sup> Hence, the condyle on the ipsilateral side can receive near-normal masticatory stimulation to maintain the growth of the cartilage. The decrease in LCC on the contralateral side seemed to parallel reports of decreased condylar dimensions in rats with a soft diet.<sup>9,19</sup> This result implies that the mechanical loading from functional movement was as important as orthopedic force as a determinant of TMJ morphology. No significant difference for WCC can be found. Since only the maximal width was measured, it perhaps could not reflect the contour changes completely because of the shape of the rat's condyle.<sup>24</sup>

Although differences exist in structure and functional movement of the TMJ between rats and humans, the lateral shift did lead to an asymmetric condyle in the rats. A previous study has shown that the mandibular shift led to a bigger size of fossa on the ipsilateral side

**Table 4.** Extended

	8 Wk		12 Wk			
	I	Control	C	I	Control	C
	3.51 ± 0.07	3.62 ± 0.09	3.34 ± 0.07*	3.53 ± 0.14	3.47 ± 0.17	3.19 ± 0.14
	1.40 ± 0.04	1.42 ± 0.06	1.38 ± 0.04	1.4 ± 0.04	1.47 ± 0.05	1.48 ± 0.04
	19.03 ± 1.5**	20.49 ± 2.1	19.49 ± 1.5**	19.14 ± 1.3**	20.28 ± 1.9	19.56 ± 1.3*
	21.71 ± 1.5**	23.08 ± 2.1	22.69 ± 1.5	22.93 ± 1.6	23.42 ± 2	23.62 ± 1.6
	12.17 ± 2.2	13.07 ± 3.1	12.01 ± 2.2*	12.87 ± 1.7**	13.9 ± 2.2	13.05 ± 1.7*
	10.43 ± 2.7*	11.61 ± 3.9	10.21 ± 2.9*	11.2 ± 2.6**	12.64 ± 3.3	11.31 ± 2.6*



**Figure 6.** The change of the amount of newly formed bone in the posterior region of the subchondral bone layer at each time point. \*  $P < .05$ ; \*\*  $P < .01$ .

compared with the opposite side.<sup>18</sup> Taking all these facts into consideration, the discrepancy between the size of the condyle and fossa in the experimental group was assumed to be a causal factor in abnormal TMJ function. This result implies that a lateral shift induced not only the positional change of condyle in the fossa but also a morphological change in TMJ, and both may be correlated to abnormal function in the TMJ.

The experimental rats developed an asymmetric mandible, which was partly in accordance with the previous study.<sup>11</sup> However, the pronounced increment of mandibular height on the ipsilateral side was not found in this experiment. It has been reported that adaptive growth of the condyle during upward displacement of the fossa results in an increase in the length but not the height in the rats since the articulating surface of the fossa is almost parallel to the occlusal plane.<sup>25</sup> Therefore, a lateral shift should have less effect on the mandibular height than on length during condylar displacement.

The smaller size of the mandible in the experimental groups was attributed to the decrease in masticatory function and retardation in growth. The result revealed that Cd-Me on the contralateral side did not differ significantly from control groups. This finding implies that condylar forward positioning could counteract the side effect of decreased function on condylar growth on the contralateral side. On the other hand, the decrease in mandibular horizontal growth was evident on the ipsilateral side since the condylar head on the ipsilateral side was thought to receive a compressive force that restricted the growth of mandibular bone.<sup>7,20</sup>

It has been proposed that mandibular length depends on both the growth rate and the growth direction of condylar cartilage. Therefore, the Stutzmann angle was introduced to estimate mandibular growth direction.<sup>26,27</sup> The angle on the contralateral side reached its highest value at 4 weeks and then decreased grad-

ually. Conversely, the angle on the ipsilateral side decreased dramatically at 2 weeks but increased gradually. These findings are in agreement with previous studies, in which mandible forward deviation resulted in an open angle and the maximal value appeared 4 weeks after the experiment began, while the backward deviation of the mandible led to a closed angle.<sup>26,27</sup> The change in this angle also lent support to the mandibular measurements. Since the opening of the angle corresponds to the increase in mandibular length and decrease in height, the difference in the Stutzmann angle between the two sides can be partly implicated in mandibular asymmetry.

There was less new bone formation in the superior region and more new bone formation in the posterior region on the contralateral side than the ipsilateral side. Because the condyle on the contralateral side was considered to move forward, the increased osteogenesis in the posterior region was in line with other reports in which mandibular forward positioning induced higher new bone formation in the posterior region of condyle.<sup>6,28</sup> The significant differences in the amount of new bone formation in the experimental groups was found at the early stage of the experiment and disappeared gradually. These results are supported by a previous study, in which the maximal levels of condylar adaptation were found after 2 to 4 weeks of soft diet in rats.<sup>19</sup> Thus, the stimulatory growth of cartilage and bone from lateral shift diminished gradually with their functional and morphological adaptation.

The new bone formation could be associated well with mandibular linear and angular measurements. The enhanced osteogenesis in the superior region on the ipsilateral side contributed to a significant increase of Cds-Mp, and similarly, the increased osteogenesis in the posterior region on the contralateral side reflected the increase of Cd-Me. The higher amount of new bone formation in the posterior region but relatively lower amount in the superior region meant that the condylar growth direction was more posterior on the contralateral side. The differential osteogenesis in the two areas in the experimental group was in agreement with a previous study in which the change in mechanical load induced sectional differences in the maturation state of chondrocytes in rats.<sup>29</sup>

The results suggest that a UPXB should be corrected as early as possible to promote morphologic and functional bilateral symmetry of the condyle and mandible by eliminating the etiological factor of skeletal asymmetry.

## CONCLUSIONS

- Lateral mandibular shift can cause morphological asymmetry in the condyle and mandibular bone. The

condylar head is bigger and the mandibular body is shorter on the ipsilateral side. This morphological change could be correlated with the differential new bone apposition and growth direction on the two sides.

- The data presented here provide further evidence that a lateral mandibular shift contributes to the asymmetry of the condyle and mandible by a combined mechanism of changing both new bone formation and growth direction, leading to a real skeletal asymmetry if uncorrected.

## ACKNOWLEDGMENT

This work was partially supported by Grant-in-Aids for Scientific Research (15592158, 16791282) from the Ministry of Education, Culture, Sports, Science, and Technology of Japan.

## REFERENCES

- Ponyi S, Szabo G, Nyilasi J. Asymmetry of mandibular dimensions in European skulls. *Proc Finn Dent Soc.* 1991;87:321–327.
- Athanasiou AE, Melsen B, Mavreas D, Kimmel FP. Stomatognathic function of patients who seek orthognathic surgery to correct dentofacial deformities. *Int J Adult Orthodon Orthognath Surg.* 1989;4:239–254.
- Bishara SE, Burkey PS, Kharouf JG. Dental and facial asymmetries: a review. *Angle Orthod.* 1994;64:89–98.
- Pirttiniemi PM. Associations of mandibular and facial asymmetries—a review. *Am J Orthod Dentofacial Orthop.* 1994;106:191–200.
- Pinto AS, Buschang PH, Throckmorton GS, Chen P. Morphological and positional asymmetries of young children with functional unilateral posterior crossbite. *Am J Orthod Dentofacial Orthop.* 2001;120:513–520.
- Rabie AB, She TT, Hägg U. Functional appliance therapy accelerates and enhances condylar growth. *Am J Orthod Dentofacial Orthop.* 2003;123:40–48.
- Asano T. The effects of mandibular retractive force on the growing rat mandible. *Am J Orthod Dentofacial Orthop.* 1986;90:464–474.
- Mavropoulos A, Bresin A, Kiliaridis S. Morphometric analysis of the mandible in growing rats with different masticatory functional demands: adaptation to an upper posterior bite block. *Eur J Oral Sci.* 2004;112:259–266.
- Kiliaridis S, Thilander B, Kjellberg H, Topouzelis N, Zafiriadis A. Effect of low masticatory function on condylar growth: a morphometric study in the rat. *Am J Orthod Dentofacial Orthop.* 1999;116:121–125.
- Curtis DA, Nielsen I, Kapila S, Miller AJ. Adaptability of the adult primate craniofacial complex to asymmetrical lateral forces. *Am J Orthod Dentofacial Orthop.* 1991;100:266–273.
- Nakano H, Maki K, Shibasaki Y, Miller AJ. Three-dimensional changes in the condyle during development of an asymmetrical mandible in a rat: a microcomputed tomography study. *Am J Orthod Dentofacial Orthop.* 2004;126:410–420.
- Sato C, Muramoto T, Soma K. Functional lateral deviation of the mandible and its positional recovery on the rat condylar cartilage during the growth period. *Angle Orthod.* 2006;76:591–597.
- Ramirez-Yanez GO, Daley TJ, Symons AL, Young WG. Incisor disocclusion in rats affects mandibular condylar cartilage at the cellular level. *Arch Oral Biol.* 2004;49:393–400.
- Akahane Y, Deguchi T, Hunt NP. Morphology of the temporomandibular joint in skeletal class III symmetrical and asymmetrical cases: a study by cephalometric laminography. *J Orthod.* 2001;28:119–128.
- Ueki K, Nakagawa K, Takatsuka S, Shimada M, Marukawa K, Takazakura D, Yamamoto E. Temporomandibular joint morphology and disc position in skeletal class III patients. *J Craniomaxillofac Surg.* 2000;28:362–368.
- Goto TK, Nishida S, Nakayama E, Nakamura Y, Sakai S, Yabuuchi H, Yoshiura K. Correlation of mandibular deviation with temporomandibular joint MR dimensions, MR disk position, and clinical symptoms. *Oral Surg Oral Med Oral Pathol Oral Radiol Endod.* 2005;100:743–749.
- Fushima K, Akimoto S, Takamoto K, Sato S, Suzuki Y. Morphological feature and incidence of TMJ disorders in mandibular lateral displacement cases. *Nippon Kyosei Shika Gakkai Zasshi.* 1989;48:322–328.
- Liu C, Kaneko S, Soma K. Glenoid fossa responses to mandibular lateral shift in growing rats. *Angle Orthod.* In press.
- Bouvier M. Effects of age on the ability of the rat temporomandibular joint to respond to changing functional demands. *J Dent Res.* 1988;67:1206–1212.
- Yamada S, Saeki S, Takahashi I, Igarashi K, Shinoda H, Mitani H. Diurnal variation in the response of the mandible to orthopedic force. *J Dent Res.* 2002;81:711–715.
- Xenakis D, Ronning O, Kantomaa T, Helenius H. Reactions of the mandible to experimentally induced asymmetrical growth of the maxilla in the rat. *Eur J Orthod.* 1995;17:15–24.
- Dahlberg G. *Statistical Methods for Medical and Biological Student.* London, UK: George Allen & Unwin; 1940:122–132.
- Ingervall B, Freden H, Heyden G. Histochemical study of mandibular joint adaptation in experimental posterior mandibular displacement in the rat. *Arch Oral Biol.* 1972;17:661–671.
- Jolly M. Condylectomy in the rat: an investigation of the ensuing repaired processes in the region of the temporomandibular articulation. *Aust Dent J.* 1961;6:243–256.
- Kantomaa T. Growth of the mandible: an experimental study in rat. *Proc Finn Dent Soc.* 1984;80:58–66.
- Stutzmann JJ, Petrovic AG. Role of the lateral pterygoid muscle and meniscotemporomandibular frenum in spontaneous growth of the mandible and in growth stimulated by the postural hyperpropulsor. *Am J Orthod Dentofacial Orthop.* 1990;97:381–392.
- Petrovic A, Stutzmann JJ. Effects on the rat mandible of a chincup-type appliance and of partial or complete immobilization. *Proc Finn Dent Soc.* 1991;87:85–91.
- Rabie AB, Leung FY, Chayanupatkul A, Hägg U. The correlation between neovascularization and bone formation in the condyle during forward mandibular positioning. *Angle Orthod.* 2002;72:431–438.
- Kantomaa T, Tuominen M, Pirttiniemi P. Effect of mechanical forces on chondrocyte maturation and differentiation in the mandibular condyle of the rat. *J Dent Res.* 1994;73:1150–1156.