

THE USE OF BALL-CLIP ATTACHMENTS WITH AN IMPLANT-SUPPORTED PRIMARY-SECONDARY BAR OVERDENTURE

Rodney P. Steffen, DDS
Vincent White
N. Robert Markowitz, DMD

KEY WORDS

Implant
Secondary encapsulator
Secondary bar
Bredent clip
Patrix

Rodney P. Steffen, DDS, is president of Advanced Dental, Oklahoma City, Okla.

Vincent White is laboratory general manager of Advanced Dental, Oklahoma City, Okla.

N. Robert Markowitz, DMD, is staff oral and maxillofacial surgeon of Advanced Dental, Oklahoma City, Okla. Correspondence should be addressed to Dr Markowitz at Advanced Dental, PO Box 21840, Oklahoma City, OK 73156 (e-mail: longmirec@interdent.com).

INTRODUCTION

The goals of overdenture attachment for implant-reconstructed edentulous mandibles are to maximize stability and retention of the overdenture and provide shared support of the implants longitudinally, extending their longevity.

The attachment system should be simple, predictable, cost-effective, and satisfying to the patient. Many types of attachments have been used for implant overdentures. These include magnets, ball-O-rings, and clips and bars.

The most common cause of implant or implant overdenture failure is the higher occurrence of hardware complications, rather than actual direct implant failure.^{1,2} These include the need to repair the retentive clip fractures, acrylic resin fractures, acrylic teeth fractures, and bar fractures, and to replace loose screws. Soft tissue problems include hyperplasia and peri-implant mucositis.

Increased maintenance requirements postdelivery can be oral hygiene-related. In addition, there can be opposing denture problems or a need for relines.^{3,4} The overdenture prosthesis must be carefully designed,⁵ according

to the requirements, to ensure adequate stability and optimum form, contour, esthetics, and patient comfort.

Clinical and technical aspects should be considered at the beginning of treatment to (1) select the optimal implant position, (2) establish an adequate number of functional units, (3) select the appropriate retainers, and (4) apply the best technique for framework processing and veneering.

Ball-O-ring attachments (Bio-horizon O-Rings, Birmingham, Ala) have been widely used because of their low cost, ease of changing attachments, and minimal chair time required.⁶ The use of O-rings alone allows for prosthesis movement in 6 directions, but they may require constant replacement of the O-rings from wear and tear of the environmental elements of stress, friction, heat, and swelling.

In most cases, connecting the implants with a bar, rather than utilizing them individually (free-standing), is preferred. With the addition of a secondary encapsulator, which is a female attachment inserted into the denture, prosthesis movement can be minimized. Using the encapsulator makes O-ring replacement easier, but failure can still occur because of incorrect O-ring size, improper

lab technique, or failure to properly maintain and lubricate the O-rings. These failures lead to decreased stability and retention, and add significantly to postdelivery chair time.⁷ In addition, processing the O-ring assembly into the acrylic is not as accurate as cast metal. Chaffee et al⁸ reported that of 58 patients who had O-ring attachments, only 6 required no adjustments. The remaining 52 patients made 327 return visits (194 nonscheduled) for prosthesis or abutment adjustments. These return visits required 115 practitioner hours to provide prosthetic solutions to patient concerns. The estimated cost for all professional and laboratory services was \$12 624, or \$218 per patient.

Hader clips processed into the denture acrylic with a primary bar have gained wide popularity, but, in our experience, they often must be replaced because of loosening,⁹ warping, or fracturing¹⁰ of the clips. These produce lateral forces on the denture and greatly reduce its stability and retention, as the denture rotates on the primary bar.¹¹⁻¹⁵ Metal Hader clips have also failed from stress fractures of the metal, and they are difficult and time-consuming to replace in the mouth. The intraoral "pickup" procedure for these is extremely technique-sensitive because of the possibility of the cold-curing acrylic's locking the denture onto the bar.

In our experience, Ceka attachments are unforgiving, making the lab procedure difficult and offering little adjustability if the denture is ill-fitting on the primary bar. Our experience with these attachment methods has shown limited success because of the need for long-term maintenance including remakes, relines, and other adjustments, which can

be demanding in continuing care.¹⁶

MATERIALS AND METHODS

For the past 22 months, we have successfully used a combination of a primary and secondary support bar with Bredent (Bredent USA, Miami, Fla) ball attachments to minimize hardware complications, maximize stability and retention, and provide balanced support to the implants. The prognosis of the overdenture is excellent, thanks to the rigid double bar design and the functional flexibility incorporated in the prosthetic design. Use of this system reduced prosthesis movement to almost zero because of the rigidity of the prosthesis. The design placement of the Bredent ball attachments is related to the anatomy of the mandible, the implant angulation, and the number and size of implants placed.

According to our criteria for success, there must not only be excellent retention of the overdenture so that it is not easily dislodged during function, but the patient must also be able to comfortably and easily remove it. The postdelivery maintenance must be minimal, having only occasional need to replace or adjust the Bredent female plastic attachments. For the system to be predictable and cost-effective, there must be minimal postinsertion maintenance and replacement.

The system does require close communication with the lab personnel, however, for correct laboratory fabrication of the prosthesis is critical to the success of treatment.¹⁷ Because of its need for a primary and secondary bar, this system requires more hardware than other systems. The primary metal bar rigidly

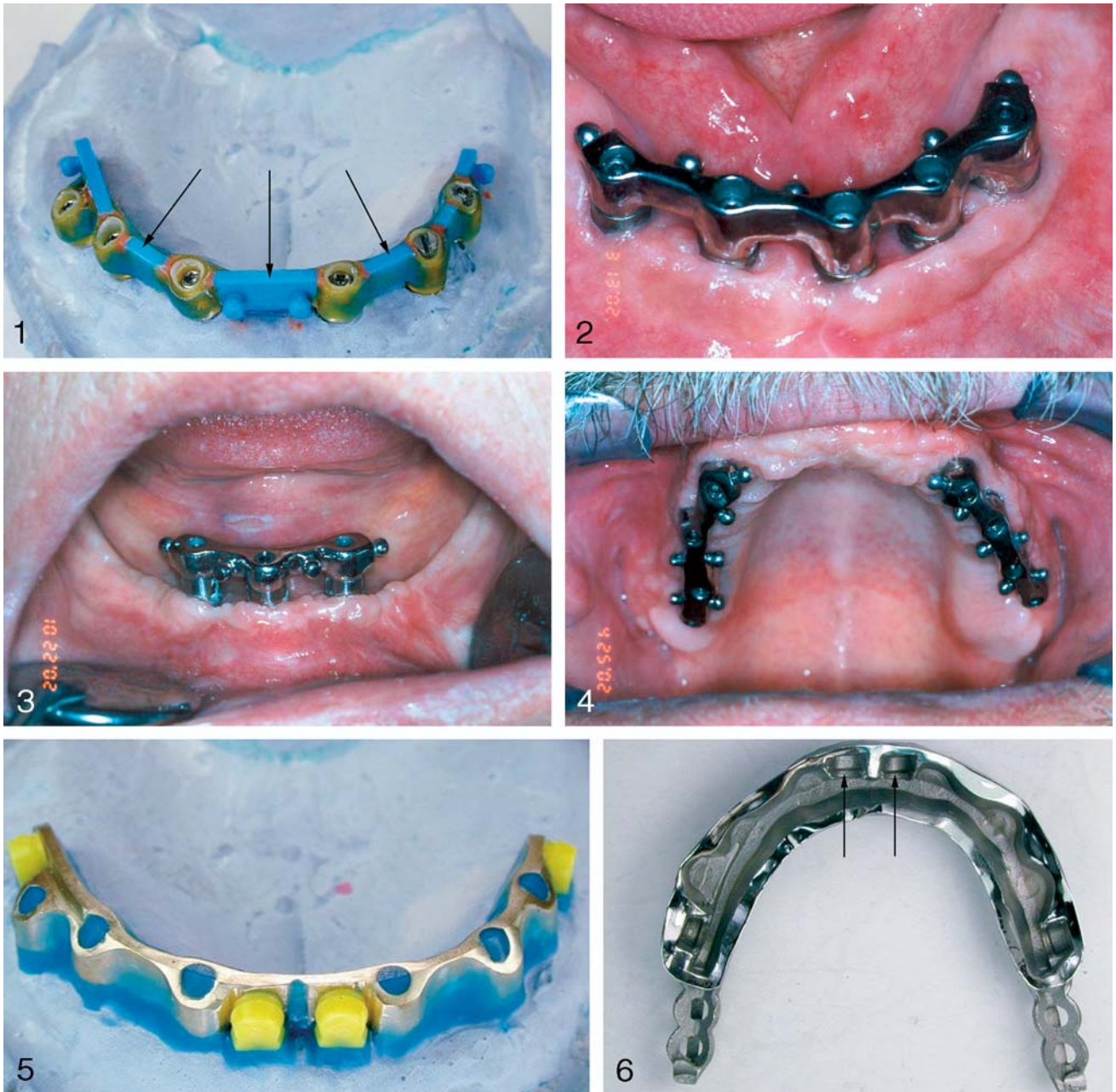
joins the lower implants while the secondary metal bar does the same to the upper implants. It is initially more costly, but the postinsertion advantages provide an overall high success rate and excellent patient satisfaction. Postdelivery chair time is reduced, saving cost to the clinician in the long run.

Clinical and laboratory procedure

A routine polyvinylsiloxane transfer impression is taken of the implant-exposed mandibular ridge with treatment abutments. The lab then fabricates the primary bar.

The laboratory production sequence includes, first, obtaining an impression with the treatment abutments in place. Next, waxing sleeves are customized with resin, and the implant frame (Figure 1) is waxed up using the SG bar patrix, which is a plastic mold that will be burned out to make the Bredent metal primary and secondary bars. Different types of patrices are available, depending on the case. The bar is then cast in a type 4 alloy.

The ball placement is determined by the anatomy of the mandible, the number and size of the implants, the interarch space, and the angulation of the implants to the ridge. There is great flexibility in the system, for the balls can be placed lingually (Figure 2) if there is too much buccal inclination of the implants; and, concurrently, buccally (Figure 3) if there is too much lingual implant inclination. The balls can also be placed both buccally and palatally in the maxilla (Figure 4). Placing the balls on the side of the bar allows for a wider restoration that gives better stability.¹⁸ Because the balls are not on top of the primary bar, the attachments do not compromise the vertical



FIGURES 1–6. FIGURE 1. Implant frame waxed up using the SG matrix. FIGURE 2. Bredent balls lingual and distal on the primary bar. FIGURE 3. Bredent balls buccal and distal on the primary bar. FIGURE 4. Bredent balls buccal and lingual on the primary bar. FIGURE 5. Females are snapped onto the attachments parallel to each other and all other undercuts are blocked out. FIGURE 6. The attachment housings are automatically created as part of the overframe.

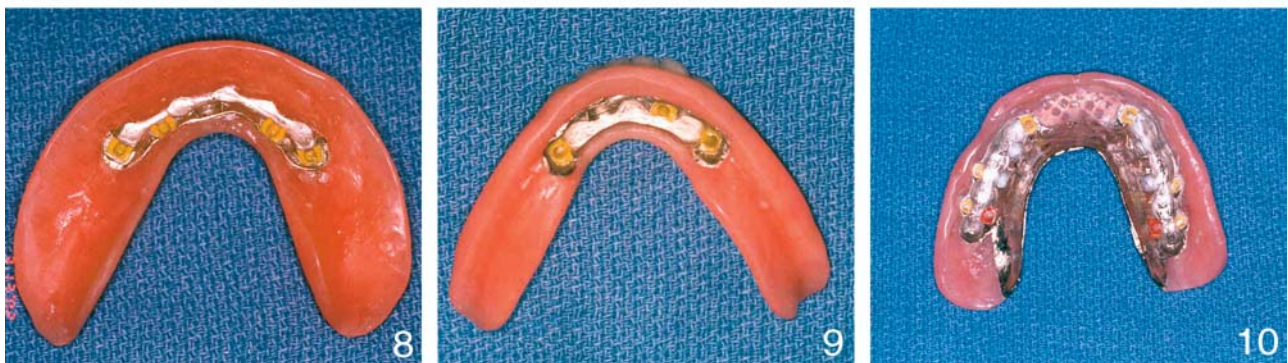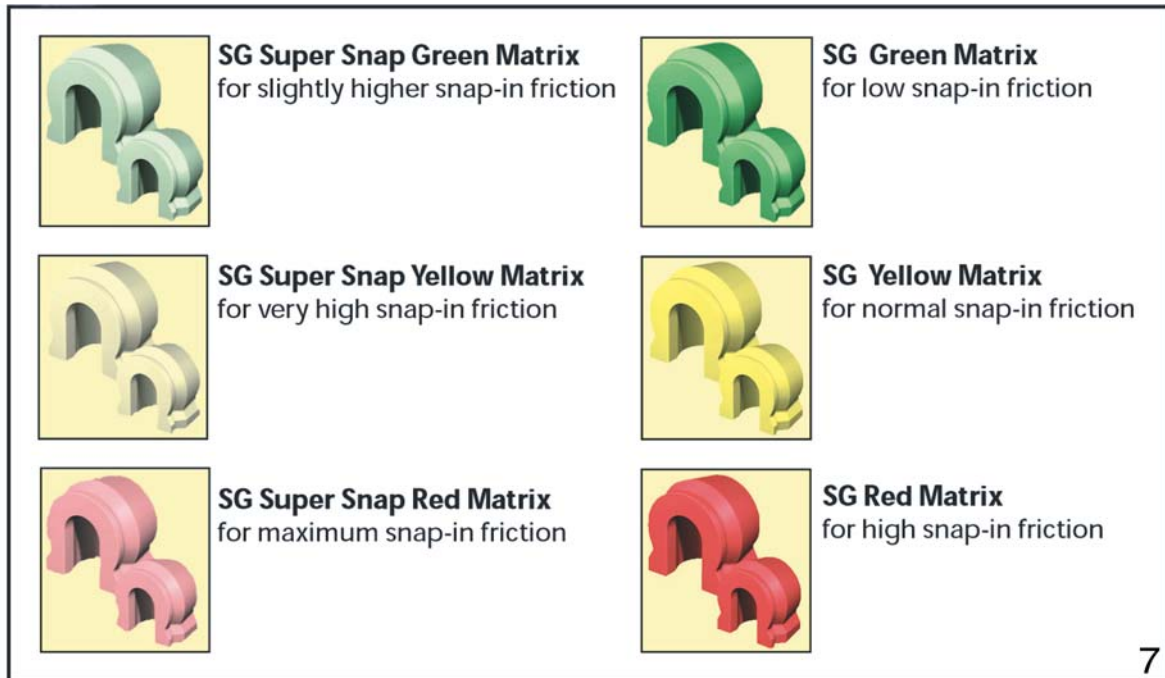
room; they have the added advantage of placing the resistant force of the attachment close to the implant body. The Bredent attachments last longer than attachments on top of a bar, which receive most forces between the bar and the denture. When the ball is on the side of the bar, the

bar itself absorbs most of the forces, leaving the attachments unstressed. Distal balls can also be placed, depending on the desired cantilever effect and the number and size of the implants placed. The balls are available in either 1.7-mm or 2.2-mm sizes. The size of balls used is depen-

dent on the room available and the amount of retention desired.

The primary bar is fitted passively and checked for acceptable height and position before the secondary bar is designed.

To create the secondary bar, the primary bar is placed on the



FIGURES 7–10. FIGURE 7. Bredent color-coded retentive clips. FIGURE 8. Mandibular overdenture with secondary bar and lingual and distal clips. FIGURE 9. Mandibular overdenture with secondary bar and buccal and distal clips. FIGURE 10. Maxillary overdenture with secondary bar and buccal and palatal clips.

model and the females (yellow) are snapped onto the attachments parallel to each other (Figure 5). All undercuts in the case are blocked out, including under the attachments. A silicone mold is formed for duplication and a refractory model is poured in investment material. The over-casting is waxed onto the refractory model and is then cast and depleted. The attachment housings (Figure 6) are automatically created as part of the overframe, which is the metal casting encapsulator.

The custom secondary bar is fitted precisely on top of the primary bar. The secondary bar contains the housing for the retentive element and is fabricated similar to a cast metal framework.^{19–21} The primary and secondary bars are made of semi-precious metal.

The framework secondary bar is waxed over the female plastic clips that come with the Bredent balls. The secondary bar framework thus becomes the housing for the retentive element, and the precise fit of the secondary bar is

determined in the lab before it is sent to the clinician. The denture base is then made over the secondary bar for taking final records during denture fabrication. A full wax try-in of both bars, with the retentive base plate and final tooth arrangement, is necessary to check for acceptable esthetics, vertical dimension, and occlusion before final processing. This assures proper placement and clearance of the retentive balls and the secondary framework, and helps prevent the need for refabrication if the bar does

TABLE 1
Breakdown of 60 cases

Site	Mandible	Mandible	Mandible	Mandible	Maxilla
Number of implants	3	4	5	6	8
Number of cases	8	17	28	4	3

not fit under the denture satisfactorily, thus avoiding extra expense.

The retentive clips (Figure 7) are polymers with different retention qualities, having varying levels of hardness. They are color-coded, enabling an easy adjustment to allow for varying surface resistance to the insertion of the Bredent ball (Figures 8 through 10). In our experience, the clips can be easily interchanged for more or less retention, or adjusted, using the high-speed bur, for less retention. The clips can be easily replaced if they wear out. A groove is made in the female clip with a bur. It is then pried out with an instrument such as an explorer. A new female clip is then pushed into place with the insertion pin.

The Bredent ball attachments help control the rotational function of stress that is transmitted to the cantilever areas distally. This helps maintain the forces vertical to the implants. Extra balls can be placed in cases where there is a shorter primary bar, such as when only 3 implants are used. In patients having 4 or more implants, the connecting bar is longer, so greater variance in placement and numbers of the balls is possible. Extending the primary bar posteriorly past the most distal implant is not necessary, because of the retention of the secondary bar with the Bredent balls. This reduces stress on the most distal implant, distributing forces evenly throughout the primary bar. Den Dunnen et al²² have demonstrated that the

longer the cantilever, the greater the possibility of superstructure fractures. The polymer female attachments allow some resiliency, compared with a fixed detachable prosthesis.

RESULTS

Over the past 22 months, 60 implant cases have been constructed using the Bredent system. All implants were Life Core-Restore, TMS-coded, threaded implants. These include (Table 1): 8 cases with 3 mandibular implants, 17 cases with 4 mandibular implants, 28 cases with 5 mandibular implants, 4 cases with 6 mandibular implants, and 3 cases with 8 maxillary implants. The overall implant failure rate, according to Albrektsson's criteria, was 2%, while the cumulative implant survival rate was 98%. There have been high patient-satisfaction rates and minimal need of postoperative adjustments.

Following delivery of the system, the patients were scheduled for a 3-day, postoperative evaluation to determine their satisfaction. Generally, some adjustments to the acrylic flanges were needed because of tissue impingement. There were no denture fractures and there were seldom any adjustments needed for the retention mechanism. Rather than hearing patient complaints of insufficient retention, we had only to adjust the retentive attachment to make the overdenture easier to remove.

DISCUSSION

The advantages of this system include increased stability and retention, wherein a predictable, constant reproduction of centric occlusion is maintained. Because the system is practically rigid, there is minimal prosthesis movement, which allows for the masticatory forces to be directed vertically. There are fewer soft tissue abrasions and less bone loss. There is improved maximal occlusal force and chewing ability. The tongue and perioral musculature resume more normal positions. There is less need for extension of the prosthesis, hence less soft tissue coverage. In addition, because of improved stability and retention, there is better speech, the patient having more confidence and comfort while eating and speaking. Based on the criteria of Wismeyer et al²³ for patient satisfaction, all the patients reported marked improvement in eating and speaking. They had no problem being understood, and they enjoyed their new appearance. With their new self-confidence, they no longer worried about visiting their families or attending parties. Patient expectations are more predictably met, including improvements in function, comfort, and appearance,²⁴ resulting in increased referrals.

CONCLUSION

Although the system initially requires higher cost and some additional chair time, postdelivery visits, in our experience, involve little need for adjustments and rarely have maintenance problems. This reduces overall chair time, compared with other systems, making the system less costly in the long run. The Bredent primary and secondary bar

system meets our criteria for success wherein there is enough retention so the denture is not easily dislodged, but the patient can easily and comfortably remove the denture. This leads to high satisfaction and better quality of life for the patient and increased referrals for the practitioner.

REFERENCES

1. Cordioli G, Majzoub Z, Castagna S. Mandibular overdentures anchored to single implants: a five-year prospective study. *J Prosthet Dent.* 1997;78:159–165.
2. Muftu A, Karabetou S. Complications in implant supported overdentures. *Compend Contin Educ Dent.* 1997;18:493–504.
3. Freeman C, Brook I, Joshi R. Long term follow-up of implant stabilized overdentures. *Eur J Prosthodont Restor Dent.* 2001;9:147–150.
4. Zitzmann NU, Marinello CP. A review of clinical and technical considerations for fixed and removable implant prosthesis in the edentulous mandible. *Int J Prosthodont.* 2002;15:65–72.
5. Naert I, Gizani S, Vuylsteke M, Van Steenberghe D. A 5-year prospective randomized clinical trial of the influence of splinted and unsplinted oral implants retaining a mandibular overdenture: prosthetic aspects and patient satisfaction. *J Oral Rehabil.* 1999;26:195–202.
6. Misch CE. *Contemporary Implant Dentistry.* 2nd ed. St Louis, Mo: CV Mosby; 1999:175–192.
7. Naert IE, Hooghe M, Quirynen M, Van Steenberghe D. The reliability of implant-retained hinging overdentures for the fully edentulous mandible. *Clin Oral Investig.* 1997;1:119–124.
8. Chaffee NR, Felton DA, Cooper LF, et al. Prosthetic complications in an implant retained mandibular overdenture population: initial analysis of a prospective study. *J Prosthet Dent.* 2002;87:40–44.
9. Payne AG, Solomons YF. Mandibular implant-supported overdentures: a prospective evaluation of the burden of prosthodontic maintenance with three different attachment systems. *Int J Prosthodont.* 2000;13:246–253.
10. Welsh G, Bissell V. Simplified procedure for replacement of retentive clips in a bar-retained implant overdenture. *J Prosthet Dent.* 2000;83:586–588.
11. Gotfredsen K, Holm B. Implant-supported mandibular overdentures retained with ball or bar attachments: a randomized prospective 5-year study. *Int J Prosthodont.* 2000;13:125–130.
12. Wismeyer D, Van Waas MA, Vermeeren J. Overdentures supported by ITI implants: a 6.5-year evaluation of patient satisfaction and prosthetic aftercare. *Int J Oral Maxillofac Implants.* 1995;10:744–749.
13. Payne AG, Solomons YF. Mandibular implant supported overdentures: a prospective evaluation of the burden of prosthodontic maintenance with three different attachment systems. *Int J Prosthodont.* 2000;13:246–253.
14. Gutfredsen K, Holm B. Implant-supported mandibular overdentures retained with ball or bar attachments: a randomized prospective 5-year study. *Int J Prosthodont.* 2000;13:125–130.
15. Kayacan R, Ballarini R, Mullen RL, Wang RR. Effect of attachment clips on an occlusal force transmission in removable implant-supported overdentures and cantilevered superstructures. *Int J Oral Maxillofac Implants.* 1997;12:228–236.
16. Tinsley D, Watson CJ, Russell JL. A comparison of hydroxylapatite coded implant retained fixed and removable prosthesis over 4–6 years. *Clin Oral Implants Res.* 2001;12:159–166.
17. Hooghe M, Naert I. Implant supported overdentures: the Leuven experience. *J Dent.* 1997;25:25–32.
18. *Art and Technology in Dentistry Manual.* Miami, Fla: Bredent USA; 2002.
19. Choy E, Reimer D. Laboratory processing of housing retained attachments for implant supported overdentures. *J Prosthet Dent.* 2001;85:516–518.
20. Rodrigues AH. Metal reinforcement for implant-supported mandibular overdentures. *J Prosthet Dent.* 2000;83:511–513.
21. Cheng AC, Wee AG, Maxymiw W, Morrison D. The management of implant-retained overdenture treatment with custom made metallic attachment housing. *J Prosthodont.* 1998;7:79–83.
22. den Dunnen AC, Slagter AP, de Baat C, Kalk W. Adjustments and complications of mandibular overdentures retained by four implants: a comparison between superstructures with and without cantilever extensions. *Int J Prosthodont.* 1998;11:307–311.
23. Wismeyer D, van Waas MA, Vermeeren JI. Overdentures supported by ITI implants: a 6.5-year evaluation of patient satisfaction and prosthetic aftercare. *Int J Oral Maxillofac Implants.* 1995;10:744–748.
24. Walton JN, MacEntee MI, Glick N. One-year prosthetic outcomes with implant overdentures: a randomized clinical trial. *Int J Oral Maxillofac Implants.* 2002;17:391–398.