

FIVE-YEAR OUTCOME OF 111 IMMEDIATE NONFUNCTIONAL SINGLE RESTORATIONS

Marco Degidi, MD
 Adriano Piattelli, MD, DDS
 Peter Gehrke, DDS
 Pietro Felice, MD
 Francesco Carinci, MD

KEY WORDS

Cox analysis
 Dental implants
 Immediate nonocclusal loading
 Implant success
 Implant survival
 Single implants

Marco Degidi, MD, is a senior lecturer at the Dental School, University of Bologna, Italy.

Adriano Piattelli, MD, DDS, is a professor of Oral Pathology at the Dental School, University of Chieti-Pescara, Italy. Address correspondence to Prof Adriano Piattelli, Via F. Schiucchi 63, 66100 Chieti, Italy (e-mail: apiattelli@unich.it).

Peter Gehrke, DDS, is in private practice in Ludwigshafen, Germany.

Pietro Felice, MD, is a fellow at the Dental School, University of Chieti-Pescara, Italy.

Francesco Carinci, MD, is an associate professor of Maxillofacial Surgery at the University of Ferrara, Italy.

Immediate loading is a surgical-prosthetic procedure extensively used in implant dentistry. Despite its frequent use, minimal data are available on the long-term clinical success rate of immediate functional loading (IFL) and immediate nonfunctional loading (INFL) of implants. The aim of this study was to evaluate the long-term survival and bone loss of immediate nonfunctional single implant restorations in a group of patients that were monitored for 5 years. One hundred and eleven patients (41.4% men) with a median age of 40 years were included in this study. A total of 111 implants were placed. All implants were placed with a minimum insertion torque of 25 Ncm. A temporary restoration was relined with acrylic resin, trimmed, polished, and cemented or screw-retained 1 to 2 hours later. Occlusal contact was avoided in centric and lateral excursions. After provisional crown delivery, a periapical radiograph was performed by means of a customized Rinn holder device. Data were analyzed by means of Kaplan-Meier and life-table algorithms. Stratification of implant survival was performed for the available variables of interest, and comparisons were analyzed using a log-rank test. Investigated parameters were time of implant placement, bone quality, implant site, implant diameter and length, and type of implant surface enhancement. The parameters for overall success rate were defined by bone resorption <1.5 mm after the first year of loading and <0.2 mm thereafter. During the 5-year follow-up period, a survival rate of 95.5% was observed. All failures occurred within 4 months of implant loading. There were statistically significant differences regarding healed vs post-extraction implant sites (100% and 92.5%, respectively, $P = .05$) and type of bone (D1 vs D4 yielded 100% and 95.5%, respectively, $P < .05$). No differences were detected for: (1) site (100% for mandible and 94.6% for maxilla, $P = .319$); (2) implant diameter (survival rates of 97.26% for <4.5-mm diameter and 92.11% for >4.5-mm diameter, $P = .206$); (3) implant lengths (survival rates of 96.97% for implants >13 mm and 94.87% for implants <13 mm, $P = .624$); and (4) type of implant surface enhancement (survival rates of 94.03% for 67 cases of grit-blasted and acid-etched surfaces and a failure rate of 4 out of 5, and 94.12% for 17 cases of hydroxyapatite (HA)-coated surfaces with only 1 failure). The success rate (defined as bone resorption >1.5 mm after the first year of loading and >0.2 mm thereafter) was 97.2%. Immediate nonocclusal loading of single implants is a reliable surgical-prosthetic procedure with a low rate of implant loss and a low quantity of peri-implant bone loss over time.

INTRODUCTION

Traditionally, implant treatment of edentulous patients was based on a 2-stage surgical protocol with a healing period of 3 to 6 months (during which implants were submerged) to achieve osseointegration.¹ This approach was considered to be an essential step for successful implant treatment. Babbush et al² reported a cumulative success rate of 88% in 1739 immediately loaded titanium plasma-sprayed (TPS) implants. In the 1980s, the concept of a 1-stage surgical approach was proposed.³ Subsequently, several clinical and histologic studies focused on possible guidelines that produced for the 1-stage surgical-prosthetic procedure the same results as the traditional submerged technique.^{3,4} In these clinical studies, implants inserted according to a 1-stage surgical procedure showed the same success rate obtained with the original 2-stage protocol. Further studies confirmed that a 1-stage surgical procedure followed by an immediate loading of the implants can achieve high clinical and radiographic success rates.⁵⁻⁷ In addition, immediate loading was successfully used in totally edentulous patients to avoid removable prostheses in the healing phase.⁸⁻¹¹ Excellent results have also been reported for immediate functional loading (IFL) and immediate nonfunctional loading (INFL) of implants in cases of partial edentulism.¹²

These promising results convinced clinicians to use the new technique also in cases of single-implant rehabilitation, and it was a successful procedure in terms of achievement and maintenance of osseointegration.¹³⁻¹⁶ Conse-

quently, immediate implant restoration seems to be a reliable treatment. However, there are still some unresolved questions regarding the outcome of immediately loaded single implants. The purpose of this study was to evaluate survival and bone loss over time (expressed in terms of bone maintenance) of immediate nonfunctional single implant restorations of a group of patients over a 5-year follow-up period. This paper will specifically address questions relative to healed vs postextraction sites, bone quality, bone recipient site (ie, maxilla vs mandible) and implant length, diameter, and surface enhancement.

MATERIALS AND METHODS

One hundred and eleven subjects were consecutively enrolled in this study, 46 (41.4%) men and 65 (58.6%) women. Informed written consent approved by the local ethics committee was obtained from patients so that their data may be used for research purposes. Subjects were screened according to the following inclusion criteria: a recipient bone site that allowed the insertion of an implant with a minimum length of 10 mm and a minimum diameter of 3.5 mm; no need of bone augmentation procedures prior to implant placement; controlled oral hygiene; presence of natural teeth mesially and distally to the missing tooth, no tooth decay, and no active periodontal disease; and the willingness of the patient to give informed consent. Exclusion criteria were: untreated caries; uncontrolled periodontal disease; adjacent teeth that exceeded class I mobility; bruxism or other parafunctional habits; unstable posterior occlusion (missing or early

contacts in maximum intercuspation); smoking more than 20 cigarettes/day; general health or medications that might compromise the osseointegration process, such as the patient's inability to come to follow-up visits; and unrealistic expectations about the procedure.

Before surgery, radiographic examinations were accomplished with periapical radiography, pantomography, and CT scans. In the follow-up periods, periapical standardized radiographs were used. In each patient, peri-implant crestal bone levels were evaluated by a calibrated examination of periapical X rays. Measurements were recorded after surgery and after a 12-month period. A Peak Scale Loupe with a 7-fold magnifying factor and a scale graduated in 0.1 mm was used. The non-blinded evaluations were made by 3 independent examiners. Peri-implant probing was not performed because there is still a controversy regarding the correlation between probing depth and implant success rates.^{17,18} The measurements were made on the mesial/distal surface of each implant, calculating the distance between the edge of the implant shoulder and the most coronal point of contact between the bone and the implant. The bone level recorded just after the surgical insertion of the implant was the reference point for the follow-up measurements. Each measurement was rounded to the nearest 0.5 mm. The implant success rate was evaluated according to the following criteria: (1) absence of persistent pain or dysesthesia; (2) absence of peri-implant infection with suppuration; (3) absence of mobility; and (4) absence of persistent peri-implant bone resorption >1.5 mm during the first year of loading and >0.2 mm/year during the following years.¹⁹

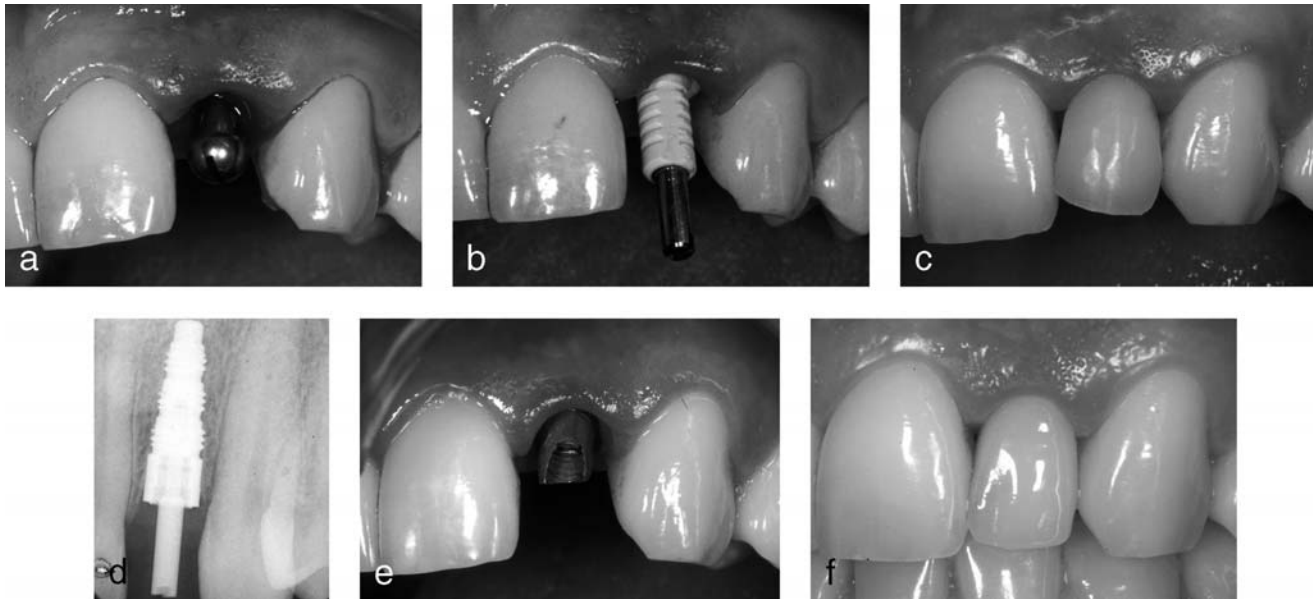


FIGURE 1. (a) The implant is in place. (b) The temporary abutment is placed in site. (c) Immediate provisionalization of the implant. (d) Post surgical X ray. (e) The final abutment is inserted. (f) The final restoration is placed.

The implants placed had the following surfaces: machined ($n = 6$), TPS ($n = 5$), sand-blasted and acid-etched (SAE, $n = 76$), hydroxyapatite-coated (HA, $n = 17$), and sand-blasted with a restorable blast medium (RBM, $n = 7$). The generic implant type, its inherent surface, and its diameter were chosen according to the shape of alveolar defect and the quantity of the bone. Small diameters were used in cases of good bone quality and thin residual alveolar crest. Implant length and diameter ranged from 10 to 18 mm and from 3.5 to 6.5 mm, respectively.

Surgical and prosthetic technique

All patients underwent the same surgical protocol. Antimicrobial prophylaxis was obtained with 500 mg amoxicillin twice daily for 5 days starting 1 hour before surgery. Local anesthesia was induced by infiltration with articaine/epinephrine, and post-surgical analgesic treatment was performed with 100 mg of nimesulid twice daily for 3 days.

Patients had a soft diet for 4 weeks and oral hygiene instructions were provided.

After a crestal incision, or an intrasulcular incision in the cases of immediate post-extraction implants, a mucoperiosteal flap was elevated. Implants were inserted according to the procedures recommended for each system. The smooth (machined) crestal implant collar was positioned 1 mm above the alveolar crest, regardless of the implant system used. A minimum insertion torque of 25 Ncm was used for all implants and all implants were clinically stable. A temporary restoration was relined with acrylic resin, trimmed, polished, and cemented or screw-retained 1 to 2 hours later. Occlusal contact was avoided in centric and lateral excursions.

A total of 111 implants were inserted: 40 FRIALIT (Dentsply Friadent, Mannheim, Germany), 2 IMZ Twin Plus (Dentsply Friadent), 36 XiVE (Dentsply Friadent), 4 Ankylos (Dentsply Friadent), 3 Restore (Lifecore Biomedical, Chaska, Minn), 20

Maestro (Biohorizons, Birmingham, Ala), and 6 Branemark (Nobel Biocare, Gothenburg, Sweden). They were placed in the following sites: 23 central incisors, 40 lateral incisors, 22 cuspids, and 26 premolars. Sixty-seven were immediate post-extraction implants. After provisional crown placement, a periapical radiograph was performed by means of a noncustomized Rinn holder device. This device was necessary to maintain the X-ray cone perpendicular to a film placed parallel to the long axis of the implant. Sutures were removed 14 days after surgery. Twenty-four weeks after implant placement, the provisional crowns were removed and final impressions of the intra-oral implant position were made using a polyvinylsiloxane impression material. The final restorations were cemented and were completed approximately 32 weeks after implant insertion. All patients were part of a strict hygiene recall and were reevaluated after 1, 2, 3, 4, and 5 years (Figures 1 through 4).

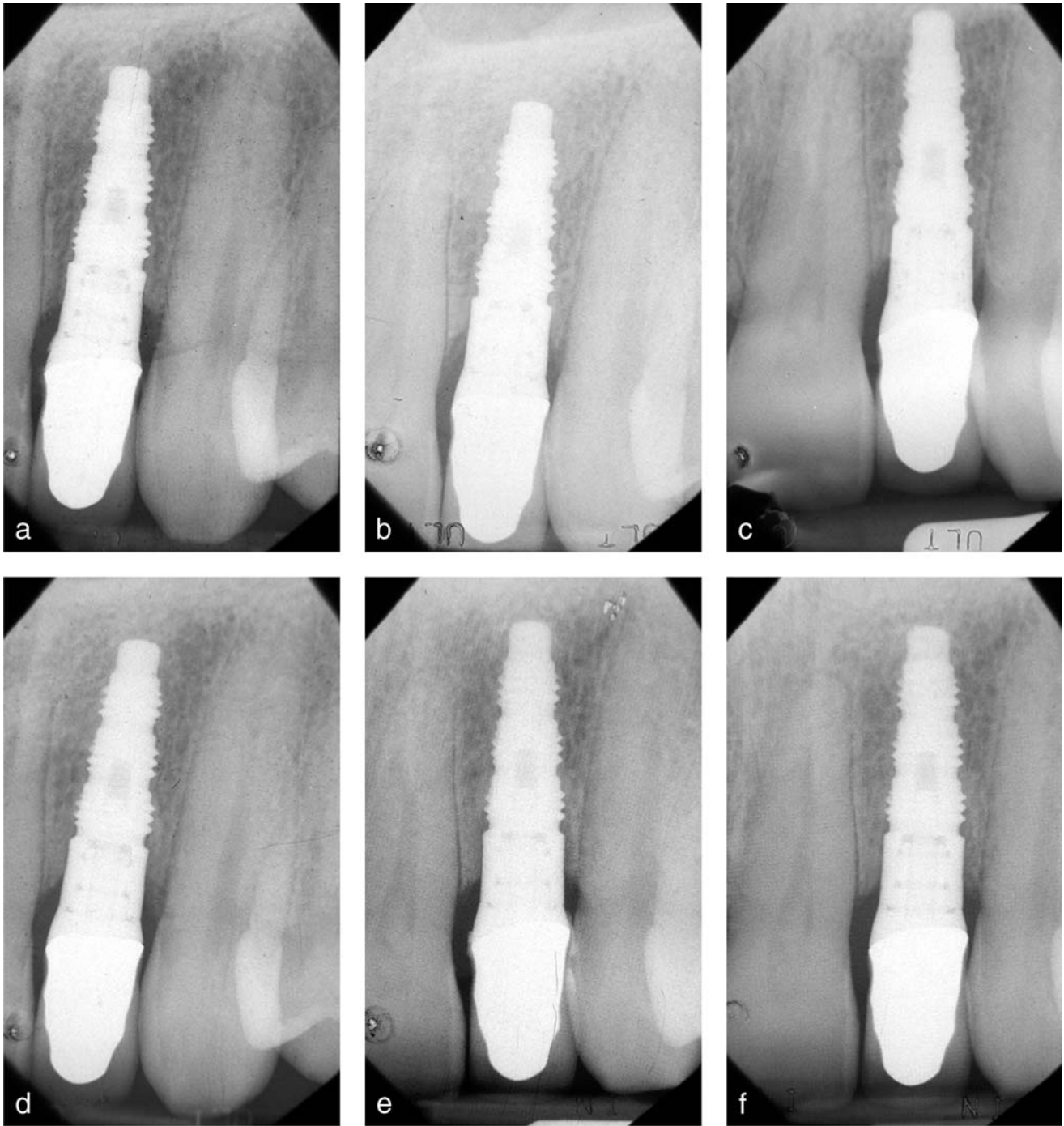

FIGURE 2. (a) Control X ray after 1 year. (b) Control X ray after 2 years. (c) Control X ray after 3 years. (d) Control X ray after 4 years. (e) Control X ray after 5 years. (f) Control X ray after 6 years.

Statistical analysis

Univariate Analysis

Implant survival curves were calculated according to the product-limit method (Kaplan-Meier

algorithm).²⁰ Time zero was defined as the date of initial placement of the implant. Surviving implants were included in the total number with a risk of failure only up to the time of their last

follow-up examination. Therefore, the success rate changed only when a failure occurred. The calculated survival curve was the most likely estimate (maximum likelihood estimate)

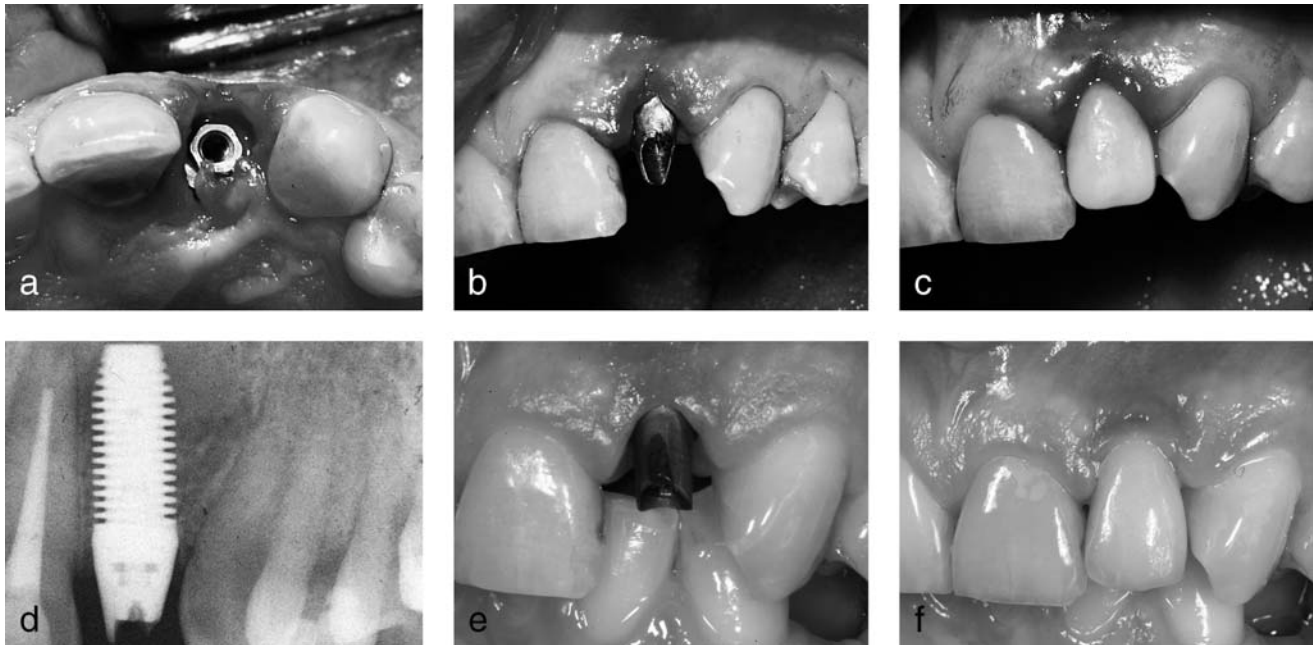


FIGURE 3. (a) Implant in place. (b) Temporary abutment. (c) Immediate provisionalization. (d) Post surgical X ray. (e) Final abutment. (f) Final restoration.

of the true success curve. A log-rank test was used to explore the differences between the survival curves stratified for the variable of interest.

Investigated parameters were: time of implant placement, bone quality, implant site, implant diameter and length, and type of implant surface enhancement. The graduation of bone quality has been carried out according to the classification of Misch²¹ (D1 = dense cortical bone; D2 = thick, dense-to-porous cortical bone on crest and coarse trabecular bone within; D3 = thin, porous cortical bone on crest and fine trabecular bone within; D4 = fine trabecular bone). The parameters for overall success rate were defined by bone resorption >1.5 mm after the first year of loading and >0.2 mm thereafter. The implant success rate was evaluated by life-table analysis by using fixed cut-off points of 1 year, each from 0 to 5 years.

RESULTS

There were 46 (41.4%) men and 65 (58.6%) women with an average age of 40 (15–83) years. Nineteen patients (17.1%) were smokers. Crude survival rate (overall survival not stratified according to any available variable) for the overall series was 95.5% (Figure 5). All failures occurred within 4 months of implant loading (Table 1). The probabilities of implants surviving 5 years after the time of insertion according to healed or post-extraction sites were 100% and 92.5%, respectively ($P < .05$) (Figure 6). The 5-year survival rates of the data set stratified according to bone quality (from D1 to D4) yielded 100% for D1, 94.55% for D2, 97.83% for D3, and 95.5% for D4 ($P < .05$ for the comparison D1 vs D4) (Figure 7). The comparison between the mandible and maxilla produced survival rates of 100% and 94.6%, respectively ($P = .319$) (Figure 8).

The 5-year survival rates of groups divided according to implant length (dichotomized in <13 mm and >13 mm) were 96.97% and 94.87%, respectively ($P = .624$) (Figure 9). The 5-year survival rates of groups stratified according to implant diameter were 97.26% and 92.11% for diameter <4.5 mm and diameter >4.5 mm, respectively ($P = .206$) (Figure 10). By analyzing implant surfaces, there were 76 cases of SAE and 17 cases of HA-coated implants. The survival rate was 94.03% for the SAE implants and 94.12% for the HA-coated implants (Figure 11). Life-table analysis (Table 2) for crestal bone loss yielded a success rate of 97.2% over 5 years. The analysis was performed without the 5 failed implants. Success/failure was defined as bone resorption >1.5 mm after the first year of loading and >0.2 mm in subsequent years.¹⁹ The mean marginal bone loss was 0.6 ± 0.2 and 0.9 ± 0.2 at 1 and 5 years, respectively.

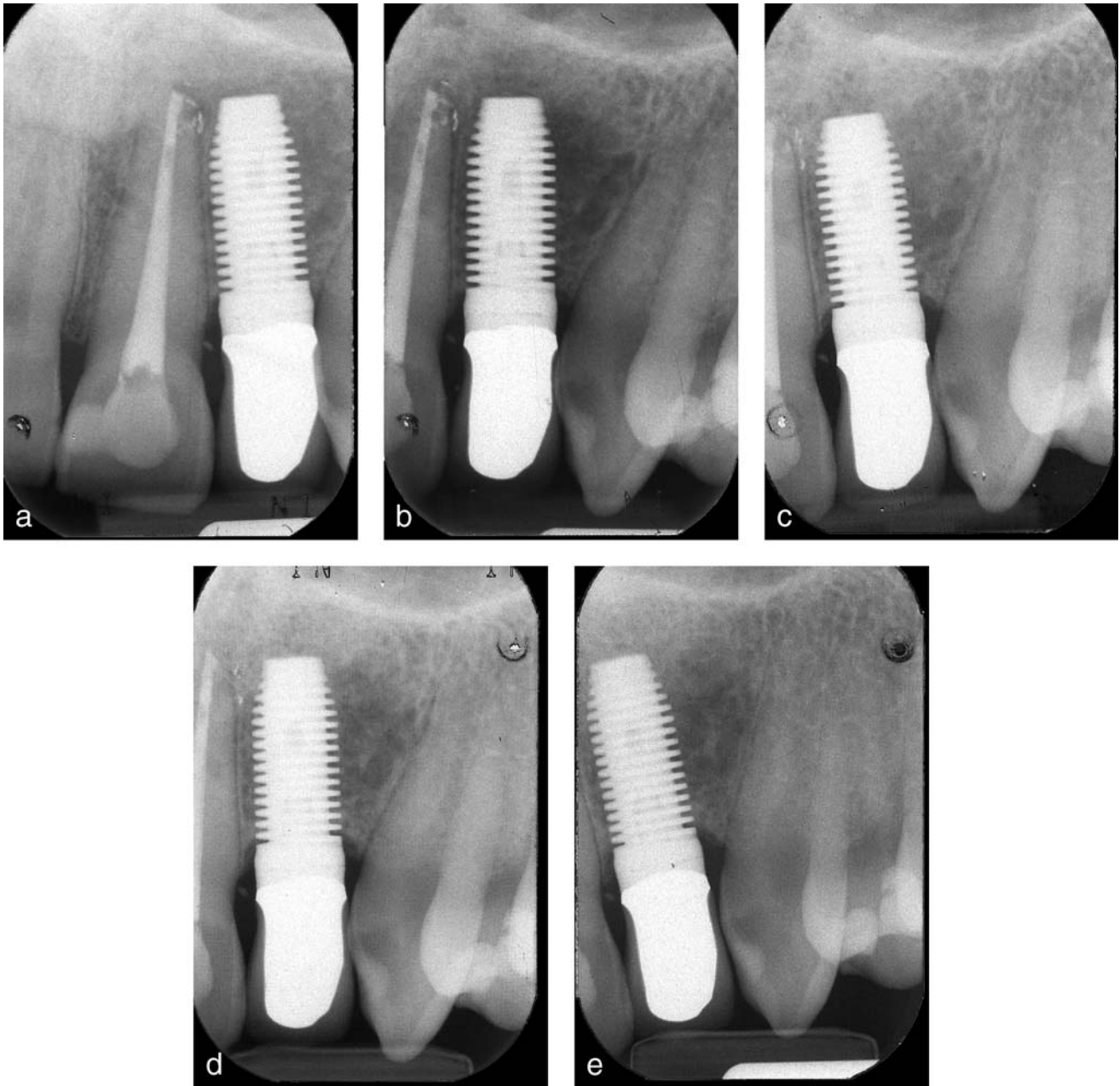


FIGURE 4. (a) Control X ray after 1 year. (b) Control X ray after 2 years. (c) Control X ray after 3 years. (d) Control X ray after 4 years. (e) Control X ray after 5 years.

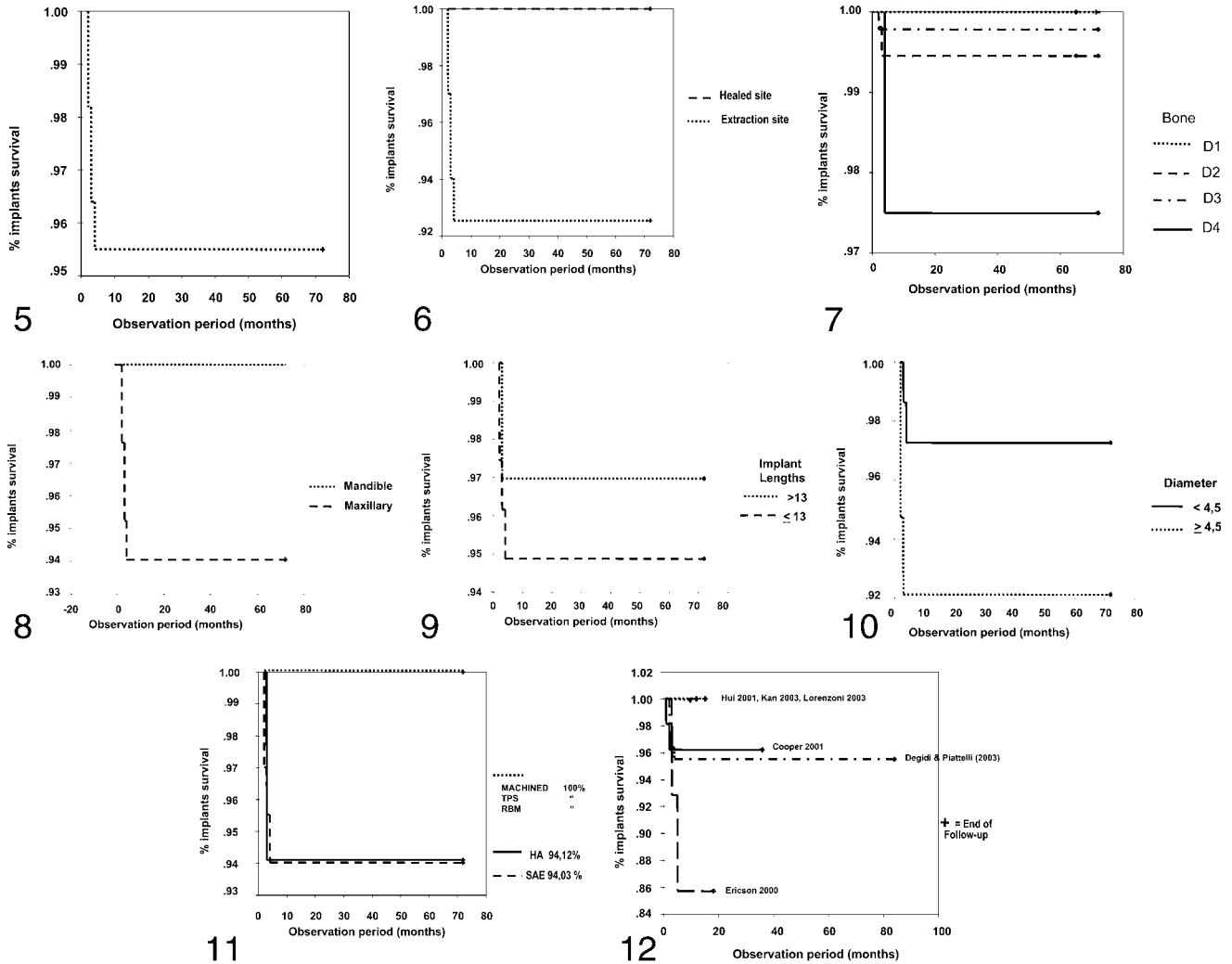
DISCUSSION

To meet patients' increased demands for immediate esthetic implant restorations, it is fundamental to strictly observe the established guidelines. Immediate loading has been successfully used in totally edentulous pa-

tients to avoid removable prostheses in the healing phase.⁸⁻¹¹ Later, excellent results have been reported for IFL and INFL of implants in cases of partial edentulism.¹² Based on such promising results, clinicians started to use IFL and INFL even for single-implant rehabilitations. It was a

successful procedure in terms of achievement and maintenance of osseointegration.¹³⁻¹⁶

The overall survival rate of immediate nonocclusal loading of single implants in the present study was 95.5% (Figure 9). All failures occurred within 4 months of implant loading (Table 1). This



FIGURES 5–12. FIGURE 5. Implant survival curve according to Kaplan-Meier algorithm. No. of implants: 111; survival rate: 95.5%. FIGURE 6. Distribution for extraction site; $P = .0656$, log-rank test. FIGURE 7. Distribution for type of bone; $P = .2$, log-rank test. FIGURE 8. Distribution for arch; $P = .32$, log-rank test. FIGURE 9. Distribution according to length; $P = .6$, log-rank test. FIGURE 10. Distribution for diameter; $P = .2$, log-rank test. FIGURE 11. Distribution for surface; $P =$ not significant, log-rank test. FIGURE 12. Different implant survival curves according to Kaplan-Meier algorithm.

result is comparable to those of other reports^{22–29} (Figure 12). Four of the five failures were protocol deviations: low primary stability (80% or less of the minimum required insertion torque of 25 Ncm), low patient compliance with oral hygiene, heavy smokers, or defects involving more than one third of the buccal plate. No cause was found in only 1 case; if the 4 protocol deviations were eliminated, the overall success rate became 99.1%. To better compare results

with those obtained by other clinicians^{22–26} a Kaplan-Meier analysis was performed (Figure 12). A statistically significant difference of implant survival related

to insertion site was detected. Implants placed into healed bone had a better outcome (100%) than those placed immediately into extraction sites (92.5%). To the

TABLE 1
Description of failed implants

Patients	Sex	Age	No. of Failed Implants	Failure Time (mo)	Diameter (mm)	Length (mm)	Bone
1	Male	24	2	2	6.50	15	D2
2	Male	28	1	2	5.50	15	D2
3	Female	31	1	3	4.50	15	D4
4	Male	37	1	3	6.50	15	D2
5	Female	40	1	4	4.50	15	D3

TABLE 2
Life-table analysis

Time Interval (y)	No. of Implants	No. of Failures, Crestal Bone Loss	Proportion of Implants Failed in the Single Year Interval	Proportion of Implants Surviving the Year Interval (Success Rate)	Cumulative Success Rate (%)
1	106	0	0	100	100
2	106	0	0	100	100
3	106	2*	1.89	98.1	98.1
4	104	1*	0.96	99.4	97.2
5	103	0	0	100	97.2

best of our knowledge, no previous report has addressed this issue. The decreased success rate related to post-extraction sites may be due to several causes. Among them are low bone-to-implant-contact, possible surface contamination, and low primary stability. Bone quality is usually considered one of the more relevant factors related to long-term success of implants.²⁹ In this series, D1 bone showed a statistically significant better survival rate (100%) in comparison to implants placed in D4 quality bone (95.5%, $P < .05$). As reported by different authors,²²⁻²⁶ low bone quality is a major risk factor in implant survival. The mandible is commonly regarded as a better implant site than the maxilla.³¹ In this study, the survival rate was 100% and 94.6% for the mandible and the maxilla, respectively ($P = .319$). The 18 implants placed in the anterior mandible did not show signs of failure.

Length, diameter, and surface are the most studied implant-related variables. Regarding length, the authors found that implants longer than 13 mm and shorter than 13 mm have survival rates of 96.97% and 94.87%, respectively. These values are borderline ($P = .624$) and support the generally accepted concept that longer implants, up to a certain point, give more primary stability and may be more appropriate in

immediate loading. In this study, large diameter implants (>4.5 mm) had a worse trend compared to those of a smaller diameter. This may be due both to excessive depletion of trabecular bone from the implant site or to stress patterns related to increased implant surface area.

With regard to surface, the SAE implants (76 cases) had a success rate of 94.03%, while the HA-coated implants (17 cases) had a success rate of 94.12% (Figure 11). No statistically significant differences were found between the two surfaces.

Finally, a high success rate was reported in a 5-year follow-up period (Table 2) by using crestal bone loss as an outcome variable. According to the authors' success criteria¹⁹ (ie, patients with bone resorption <1.5 mm after the first year of loading and <0.2 mm per year from the second year onwards), 3 additional failures were recorded. The cumulative success rate at the end of the time interval was 97.2%.

CONCLUSION

In conclusion, the present report has shown that immediate non-occlusal loading of single implants is a reliable surgical procedure. The overall success rate is high and appears stable

over time. Immediate loading of single implants can be done in immediate post-extraction sites and low bone quality sites, but is associated with a higher level of risk than implants inserted in healed sites with good bone quality. In addition, implant diameter, implant length, and location in the jaw may affect the implant's long-term success.

ACKNOWLEDGMENTS

This work was partially supported by the National Research Council (CNR), Rome, Italy; by the Ministry of Education, University and Research (MIUR), Rome, Italy; and by AROD (Research Association for Dentistry and Dermatology), Chieti, Italy.

REFERENCES

1. Adell R, Lekholm U, Rockler B, Branemark P-I. A 15-year study of osseointegration implants in the treatment of the edentulous jaw. *Int J Oral Surg.* 1981;10:387-416.
2. Babbush CA, Kent J, Misiek D. Titanium plasma-sprayed (TPS) screw implants for the reconstruction of the edentulous mandible. *J Oral Maxillofac Surg.* 1986;44:274-282.
3. Buser D, Schroeder A, Sutter F, Lang NP. The new concept of ITI hollow-screw implants: part 2. Clinical aspects, indications, and early clinical results. *Int J Oral Maxillofac Implants.* 1988;3:173-181.
4. Henry P, Rosenberg J. Single-stage surgery for rehabilitation of the edentu-

- lous mandible. Preliminary results. *Pract Periodont Aesthet Dent*. 1994;6:1–8.
5. Chiapasco M, Gatti C, Rossi E, Haeflinger W, Markwalder TH. Implant-retained mandibular overdentures with immediate loading. A retrospective multicenter study on 226 consecutive cases. *Clin Oral Implants Res*. 1997;8:48–57.
 6. Gatti C, Haeflinger W, Chiapasco M. Implant-retained mandibular overdentures with immediate loading: a prospective study of ITI implants. *Int J Oral Maxillofac Implants*. 2000;15:383–388.
 7. Randow K, Ericsson I, Nilner K, Petersson A, Glantz PO. Immediate functional loading of Branemark dental implants. An 18-months clinical follow-up study. *Clin Oral Implants Res*. 1999;10:8–15.
 8. Balshi TJ, Wolfinger GL. Immediate loading of Branemark implants in edentulous mandibles: a preliminary report. *Implant Dent*. 1997;6:83–88.
 9. Schnitman PA, Wöhrle PS, Rubenstein JE. Immediate fixed interim prostheses supported by two-stage threaded implants: methodology and results. *J Oral Implantol*. 1990;16:96–105.
 10. Schnitman PA, Wöhrle PS, Rubenstein JE, Da Silva JD, Wang N-H. Ten year results for Branemark implants immediately loaded with fixed prostheses at implant placement. *Int J Oral Maxillofac Implants*. 1997;12:495–503.
 11. Tarnow DP, Emtiaz S, Classi A. Immediate loading of threaded implants at stage 1 surgery in edentulous arches: ten consecutive case report with 1- to 5-year data. *Int J Oral Maxillofac Implants*. 1997;12:319–324.
 12. Degidi M, Piattelli A. Immediate functional and non-functional loading of dental implants: a 2- to 60-month follow-up study of 646 titanium implants. *J Periodontol*. 2003;74:225–241.
 13. Cooper L, Felton AD, Kugelberg CF, Ellner S, Chaffee N, Molina AL, Moriarty JD, Paquette D, Palmqvist U. A multicenter 12-month evaluation of single-tooth implants restored 3 weeks after 1-stage surgery. *Int J Oral Maxillofac Implants*. 2001;16:182–192.
 14. Ericsson I, Nilson H, Lindh T, Nilner K, Randow K. Immediate functional loading of Branemark single tooth implants. An 18 months' clinical pilot follow-up study. *Clin Oral Implants Res*. 2000;11:26–33.
 15. Wöhrle PS. Single-tooth replacement in the aesthetic zone with immediate provisionalization: fourteen consecutive case reports. *Pract Periodont Aesthetic Dent*. 1998;10:1107–1114.
 16. Andersen E, Haanaes HR, Knutsen BM. Immediate functional loading of single-tooth ITI implants in the anterior maxilla: a prospective 5-years pilot study. *Clin Oral Implants Res*. 2002;13:281–287.
 17. Quirynen M, van Steenberghe D, Jacobs R, Schotte A, Darius P. The reliability of pocket probing around screw-type implants. *Clin Oral Implants Res*. 1991;2:186–192.
 18. Quirynen M, Naert I, van Steenberghe D, Teerlinck J, Dekeyser C, Theuniers G. Periodontal aspects of osseointegrated fixtures supporting an overdenture. A 4-year retrospective study. *J Clin Periodontol*. 1991;18:719–728.
 19. Albrektsson T, Zarb GA. Determinants of correct clinical reporting. *Int J Prosthodont*. 1998;11:517–521.
 20. Dawson-Saunders B, Trapp RG. *Basic and Clinical Biostatistic*. Norwalk, CT: Appleton & Lange; 1994.
 21. Misch CE. Density of bone: effect on treatment plans, surgical approach, healing, and progressive bone loading. *Int J Oral Implantol*. 1990;6(2):23–31.
 22. Cooper L, Felton DA, Kugelberg CF, Ellner S, Chaffee N, Molina AL, Moriarty JD, Paquette D, Palmqvist U. A multicenter 12-month evaluation of single-tooth implants restored 3 weeks after 1-stage surgery. *Int J Oral Maxillofac Implants*. 2001;16:182–192.
 23. Hui E, Chow J, Li D, Liu J, Wat P, Law H. Immediate replacement of single-tooth implant with Branemark system: preliminary report. *Clin Implant Dent Relat Res*. 2001;3:79–86.
 24. Andersen E, Haanaes HR, Knutsen BM. Immediate loading of single-tooth ITI implants in the anterior maxilla: a prospective 5-year pilot study. *Clin Oral Implants Res*. 2002;13:281–287.
 25. Kan JY, Rungcharassaeng K, Lozada J. Immediate placement and provisionalization of maxillary anterior single implants: 1-year prospective study. *Int J Oral Maxillofac Implants*. 2003;18:31–39.
 26. Lorenzoni M, Pertl C, Zhang K, Wimmer G, Wegscheider WA. Immediate loading of single-tooth implants in the anterior maxilla. Preliminary results after one year. *Clin Oral Implants Res*. 2003;14:180–187.
 27. Chausu G, Chausu S, Tzohar A, Dayan D. Immediate versus non-immediate implantation. A clinical report. *Int J Oral Maxillofac Implants*. 2001;16:267–272.
 28. Ledermann PD. New Ledermann screw [in German]. *Quintessenz*. 1988;39(5):799–815.
 29. Szmukler-Moncler S, Piattelli A, Favero GA, Dubruille JH. Considerations preliminary to the application of early and immediate loading protocols in dental implantology. *Clin Oral Implants Res*. 2000;11:12–25.
 30. Cochran DL, Morton D, Weber HP. Consensus statements and recommended clinical procedures regarding loading protocols for endosseous dental implants. *Int J Oral Maxillofac Implants*. 2004;19(suppl):109–113.