

# HISTOLOGIC EVALUATION OF A PROVISIONAL IMPLANT RETRIEVED FROM MAN 7 MONTHS AFTER PLACEMENT IN A SINUS AUGMENTED WITH CALCIUM SULPHATE: A CASE REPORT

Giovanna Iezzi, DDS, PhD; Elisabetta Fiera, DDS; Antonio Scarano, DDS, MD; Gabriele Pecora, MD, DDS; Adriano Piattelli, MD, DDS

Little is known about the in vivo healing processes at the interface of implants placed in different grafting materials. For optimal sinus augmentation, a bone graft substitute that can regenerate high-quality bone and enable the osseointegration of load-bearing titanium implants is needed in clinical practice. Calcium sulphate (CaS) is one of the oldest biomaterials used in medicine, but few studies have addressed its use as a sinus augmentation material in conjunction with simultaneous implant placement. The aim of the present study was to histologically evaluate an immediately loaded provisional implant retrieved 7 months after simultaneous placement in a human sinus grafted with CaS. During retrieval bone detached partially from one of the implants which precluded its use for histologic analysis. The second implant was completely surrounded by native and newly formed bone, and it underwent histologic evaluation. Lamellar bone, with small osteocyte lacunae, was present and in contact with the implant surface. No gaps, epithelial cells, or connective tissues were present at the bone–implant interface. No residual CaS was present. Bone–implant contact percentage was  $55\% \pm 8\%$ . Of this percentage, 40% was represented by native bone and 15% by newly formed bone. CaS showed complete resorption and new bone formation in the maxillary sinus; this bone was found to be in close contact with the implant surface after immediate loading.

**Key Words:** calcium sulphate, osseointegration, provisional dental implants, transitional dental implants

**Giovanna Iezzi**, DDS, PhD, is a research fellow at the Dental School, University of Chieti-Pescara, Italy.

**Elisabetta Fiera**, DDS, is in private practice in Lecce, Italy, and a visiting professor at the Dental School, University of Chieti-Pescara, Italy.

**Antonio Scarano**, DDS, MD, is a researcher at the Dental School, University of Chieti-Pescara, Italy.

**Gabriele Pecora**, MD, DDS, is in private practice in Rome, Italy.

**Adriano Piattelli**, MD, DDS, is a professor of oral pathology and medicine at the Dental School, University of Chieti-Pescara, Italy. Address correspondence to Dr Piattelli at Via F. Sciucchi 63, 66100 Chieti, Italy (e-mail: apiattelli@unich.it).

## INTRODUCTION

Restal bone resorption and pneumatization of the maxillary sinuses can often result in an inadequate volume of bone for implant placement. Several bone substitutes have been used to augment the sinus floor area<sup>1–11</sup> with the aim of obtaining a quantity of bone tissue sufficient for mechanical support and integration of the implants.<sup>3</sup> Little is known about the healing processes at the interface of implants placed in different grafting

materials in humans.<sup>1-5</sup> For optimal sinus augmentation, a bone graft substitute that can regenerate high-quality bone and enable the osseointegration of load-bearing implants is needed in clinical practice.<sup>5</sup> Calcium sulphate (CaS) is one of the oldest biomaterials and has been used extensively in different fields.<sup>12-23</sup> In periodontology, it has been used as a barrier in the treatment of molar furcation defects and for root coverage.<sup>24-26</sup> High success rates have been reported with its use in sinus augmentation procedures.<sup>11</sup> In orthopedics, it has been used to achieve vertebral fusion,<sup>27,28</sup> treat nonunions and fractures with osseous defects,<sup>29</sup> and augment large osseous defects in animal models.<sup>30-37</sup> CaS has excellent handling properties, has high biocompatibility, and is osteoconductive.<sup>37</sup> No adverse effects on bone formation or the presence of an inflammatory response have been reported.<sup>30,37</sup> CaS has been reported to release calcium ions while rapidly resorbing *in vivo*.<sup>37</sup> In animal models, complete CaS resorption has been observed to occur by 6 weeks in rabbits<sup>32</sup> and 13 weeks in dogs.<sup>30</sup> The ultimate proof of the efficacy of a bone substitute is found only through histology.<sup>38</sup> Clinical studies are certainly relevant, but they do not provide information on the nature of the bone-implant interface<sup>38</sup>; only histology can provide information on the tissue response and the degree of osseointegration.<sup>39,40</sup> Results have been published on implant integration in concert with sinus augmentation procedures in experimental animals<sup>4</sup>; animal experiments cannot, however, be extrapolated to predict clinical or histologic results in humans.<sup>39</sup> Only a few articles have evaluated dental implant integration after sinus grafting in man.<sup>5,8,9,10,38-42</sup> Small-diameter implants have been used as a provisional treatment to provide immediate prosthesis support during the healing period of submerged implants.<sup>43,44</sup> With this technique, it is possible to provide patients with a less costly, less complicated, and less surgically intensive treatment.<sup>43,44</sup> These implants are usually retrieved, and they can be evaluated to provide useful information about the events at the interface.

The aim of the present study was to histologically evaluate an immediately loaded provisional implant retrieved 7 months after simultaneous placement in a human sinus augmented with CaS.

#### MATERIALS AND METHODS

A 44-year-old male nonsmoker presented with extensive periodontal disease primarily involving the maxillary molars (Figure 1). These teeth were extracted. The height of the subantral residual bone was on average 4 to 5 mm (Figure 2). Bilateral sinus lift augmentation was

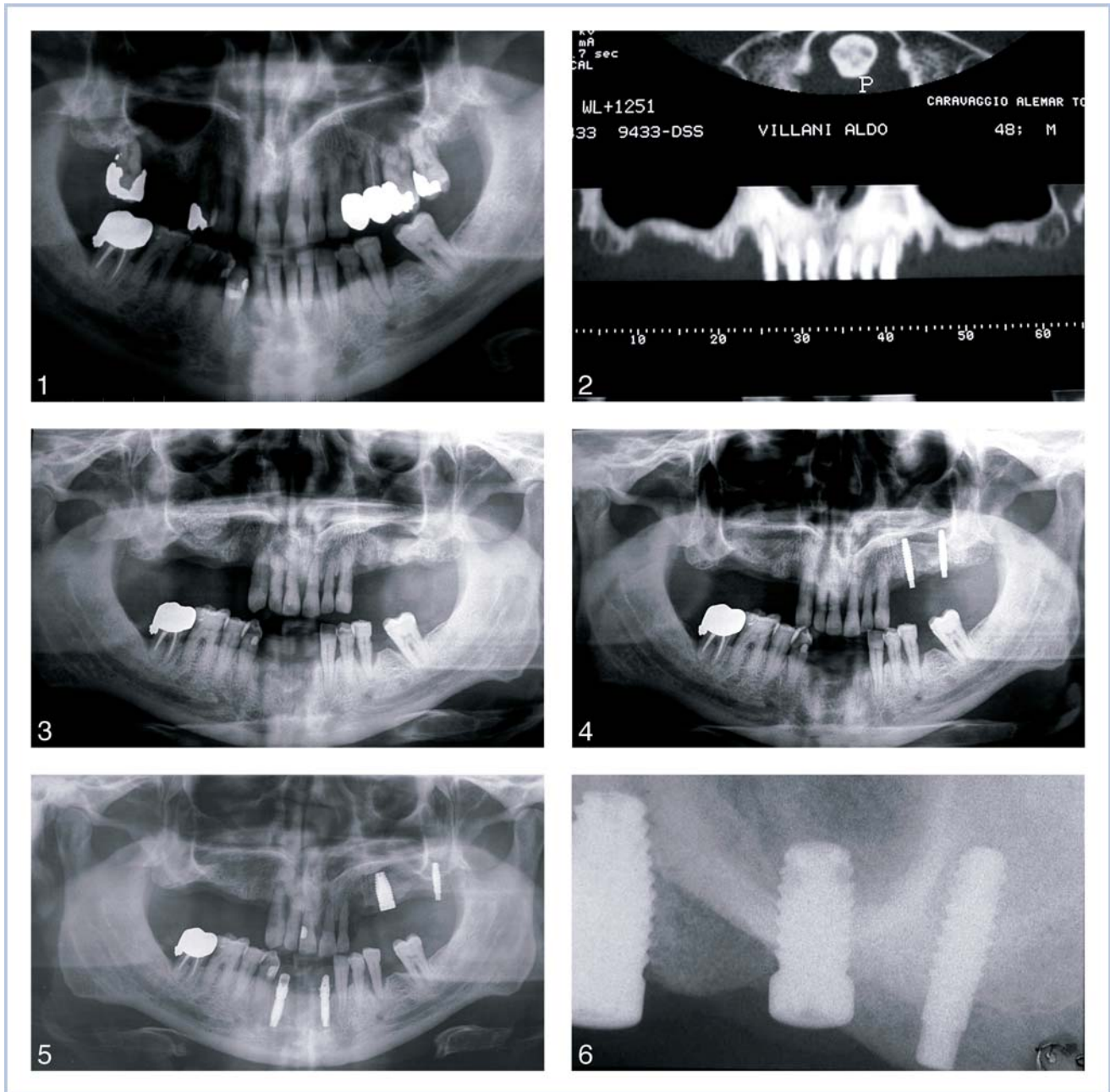
performed using CaS (Surgiplaster Sinus, Classimplant, Rome, Italy) (Figure 3). Two provisional implants (2.5 × 13 mm) (Silhouette LaserLok, BioloK International, Deerfield Beach, Fla) were simultaneously placed and used to support a provisional prosthesis (Figure 4). After a 7-month healing period the provisional implants were retrieved with a 4-mm trephine, and 3 definitive submerged implants (BioloK International) were placed (Figures 5 and 6). During retrieval bone detached partially from one of the implants, and this fact precluded its use for histologic analysis. The second implant was completely surrounded by native and newly formed bone, and it underwent histologic evaluation.

#### Specimen processing

The implant and surrounding tissues were washed in saline solution and immediately fixed in 4% paraformaldehyde and 0.1% glutaraldehyde in 0.15 M cacodylate buffer at 4°C and pH 7.4 to be processed for histology. The specimen was processed to obtain thin ground sections (Precise 1 Automated System, Assing, Rome, Italy).<sup>45</sup> The specimen was dehydrated in an ascending series of alcohol rinses and embedded in a glycolmethacrylate resin (Technovit 7200 VLC, Kulzer, Wehrheim, Germany). After polymerization the specimen was cut longitudinally into sections approximately 150 µm thick with a high-precision diamond disc and then ground down to about 30 µm in thickness with a specially designed grinding machine. A total of 3 slides were obtained and stained with acid fuchsin and toluidine blue. The slides were observed in normal transmitted light and polarized-light microscopy (Leitz Laborlux, Leitz, Wetzlar, Germany). Histomorphometry was carried out using a light microscope (Laborlux S, Leitz) connected to a high-resolution video camera (3CCD, JVC KY-F55B, JVC, Yokohama, Japan) and interfaced to a monitor and PC (Intel Pentium III 1200 MMX, Intel, Santa Clara, Calif). This optical system was associated with a digitizing pad (Matrix Vision GmbH, Oppenweiler, Germany) and a histometry software package with image-capturing capabilities (Image-Pro Plus 4.5, Media Cybernetics Inc, Immagini & Computer Snc, Milano, Italy).

#### RESULTS

At low-power magnification, it was possible to see that native and newly formed bone, with small osteocyte lacunae, was present around and in contact with the implant surface (Figure 7). No gaps, epithelial cells, or connective tissues were present at the bone-implant interface, and the bone was always in close and tight

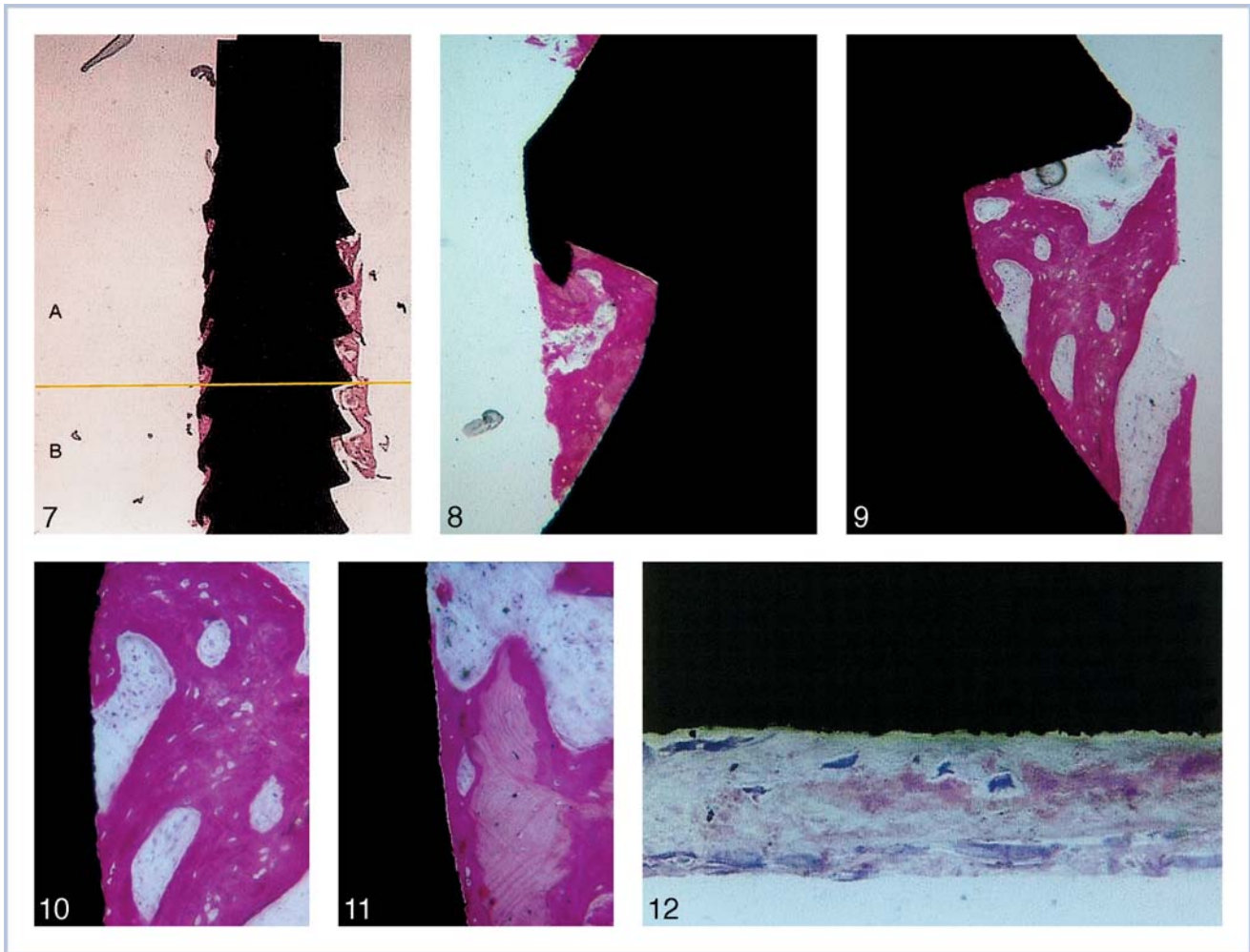


FIGURES 1–6. FIGURE 1. Panoramic radiograph of the patient at first clinical presentation. FIGURE 2. Computerized tomography scan: the atrophy of posterior maxilla can be observed. FIGURE 3. Panoramic radiograph after tooth extraction and sinus augmentation with calcium sulphate. FIGURE 4. Provisional implants placed in the left posterior maxilla. FIGURE 5. The provisional implants were retrieved after 7 months, and the definitive implants were placed. FIGURE 6. Periapical radiograph of the definitive implants.

contact with the implant surface. No inflammatory cell infiltrate was present at the bone–implant interface. No epithelial downgrowth was present. In some areas of the interface, it was possible to observe the presence of unorganized woven bone. Haversian canals were absent. No residual CaS was present (Figure 8). In some areas, wide marrow spaces were present near the implant surface (Figure 9). At higher magnification,

osteoblasts secreting osteoid matrix were present near the bone–implant interface (Figure 10). Cortical mature bone was present near the implant surface, and bone undergoing remodeling was in direct contact with the implant surface (Figure 11). Under higher magnification, it was possible to observe a few osteoblasts secreting osteoid matrix that was undergoing mineralization at the level of the apex (Figure 12). A large





FIGURES 7–12. FIGURE 7. At low-power magnification, it is possible to see that bone is present around and in contact with the implant. The line divides native bone from newly formed bone (A) Native bone. (B) Newly formed bone. (Acid fuchsin and toluidine blue, magnification  $\times 12$ ). FIGURE 8. Higher magnification of Figure 7 (area A). Newly formed trabecular bone with large osteocyte lacunae was present close to the implant surface. No residual calcium sulphate is present. (Acid fuchsin and toluidine blue, magnification  $\times 50$ ). FIGURE 9. Higher magnification of Figure 7 (area A). Cortical mature bone is present near the implant surface, and bone undergoing remodeling is in direct contact with the implant surface. (Acid fuchsin and toluidine blue, magnification  $\times 100$ ). FIGURE 10. Higher magnification of Figure 7 (area B). High magnification of the coronal portion of the bone–implant interface. Active osteoblasts secreting osteoid matrix are present. No biomaterial is present. (Acid fuchsin and toluidine blue, magnification  $\times 100$ ). FIGURE 11. Higher magnification of Figure 7 (area B). Newly formed bone in close contact with the implant surface. Wide marrow spaces are present. No calcium sulphate is present. (Acid fuchsin and toluidine blue, magnification  $\times 50$ ). FIGURE 12. Higher magnification of Figure 7 (area B). Osteoblasts (arrows) secreting osteoid matrix are observed in the apical portion of the implant. (Acid fuchsin and toluidine blue, magnification  $\times 400$ ).

quantity of vessels was present in the marrow spaces around the implant perimeter. The percentage of bone–implant contact was  $55\% \pm 8\%$ . Of this percentage, 40% was represented by native bone and 15% by newly formed bone.

#### DISCUSSION

The selection of a material in sinus augmentation procedures is of special interest to clinicians.<sup>6</sup> Two questions are important in sinus augmentation procedures in man: the ability of the newly formed bone to

obtain functional osseointegration with the implants and the fate of the graft material.<sup>6</sup>

It would certainly be interesting to know the extent of the perimeter of a dental implant, placed in a grafted sinus, that is covered by newly formed bone in close contact with the implant surface.<sup>46</sup> Moreover, an understanding of the mechanisms and rate of resorption of the grafted materials is clinically important.<sup>47</sup> A bone substitute should be able to form new bone and then completely be resorbed and replaced by newly formed bone.<sup>47,48</sup> Autologous bone could be considered an ideal graft because it has osteoinductive

and osteoconductive properties, contains growth factors, and has a scaffold effect on the transfer of osteogenic cells.<sup>49</sup> The drawbacks of autologous bone use is the frequent need for an additional procedure, with its increased costs and increased morbidity; moreover, autogenous bone has been reported to be rapidly resorbed, and this might compromise implant placement.<sup>48</sup> Some reports have indicated that there is a similar percentage of osseointegration in implants placed in sites augmented with anorganic bovine bone as in sites augmented with autogenous bone grafts.<sup>49–52</sup>

Only a few studies are available in the literature about histologic results of implants placed into augmented sinuses. Valentini et al<sup>5</sup> found an intimate, direct bone–implant contact in the grafted area as well as in the pre-existing bone; the bone at the interface was primarily lamellar with only a few areas of woven bone. Rosenlicht and Tarnow<sup>41</sup> demonstrated that an implant placed simultaneously at the time of a sinus augmentation procedure with anorganic bovine bone can osseointegrate and remain osseointegrated after 2+ years of loading. A very low degree or complete lack of osseointegration of microimplants placed in sinuses grafted with radiated mineralized cancellous allografts was found after a 6- to 14-month healing period.<sup>40</sup> In a previous study, we found that an implant retrieved 4 years after placement in a sinus augmented with anorganic bovine bone showed intimate direct contact between bone and implant without any interposition of the graft material particles and with a high bone–implant contact percentage.<sup>42</sup> The timing for the resorption and ultimate replacement of these graft materials with vital bone is not yet completely understood.<sup>47,48</sup>

In the present specimen, no residual CaS was apparent in any of the histologic sections after 7 months. No adverse inflammatory response was present.

### CONCLUSION

Histomorphometry showed CaS to be a quickly resorbed biomaterial that was replaced by the formation of new bone in a maxillary sinus; this bone was in close contact with the immediately loaded implant surface.

Other human histologic specimens retrieved from grafted sinuses after longer time periods will certainly help to clarify the question of biomaterial resorption over time and of the potential of regenerated bone to achieve and maintain osseointegration with dental implants. Provisional implants help the patients to avoid the inconveniences of wearing a denture, and

they can, moreover, provide useful information after retrieval.

### ACKNOWLEDGMENTS

This work was supported in part by the Ministry of Education, University and Research, Rome, Italy, and by the Research Association for Dentistry and Dermatology, Chieti, Italy.

### REFERENCES

1. McNeill SR, Cobb CM, Rapley JW, Glaros AG, Spencer P. In vivo comparison of synthetic osseous graft materials. A preliminary study. *J Clin Periodontol.* 1999;26:239–245.
2. Yildirim M, Spiekermann H, Biesterfeld, Edelhoff D. Maxillary sinus augmentation using xenogenic bone substitute material Bio-Oss in combination with venous blood. A histologic and histomorphometric study in humans. *Clin Oral Implants Res.* 2000;11:217–229.
3. Artzi Z, Nemcovsky CE, Dayan D. Bovine-HA spongiosa blocks and immediate implant placement in sinus augmentation procedures. Histopathological and histomorphometric observations on different histological stainings in 10 consecutive patients. *Clin Oral Implants Res.* 2002;13:420–427.
4. Haas R, Mailath G, Dortbudack O, Watzek G. Bovine hydroxyapatite for maxillary sinus augmentation: analysis of interfacial bond strength of dental implants using pull-out tests. *Clin Oral Implants Res.* 1998;9:117–122.
5. Valentini P, Abensur D, Densari D, Graziani JN, Hammerle CHF. Histological evaluation of Bio-Oss in a 2-stage sinus floor elevation and implantation procedure. A human case report. *Clin Oral Implants Res.* 1998;9:59–64.
6. Landi L, Pretel RW, Hakimi NM, Setayesh R. Maxillary sinus floor elevation using a combination of DFDBA and bovine-derived porous hydroxyapatite: a preliminary histologic and histomorphometric report. *Int J Periodontics Restorative Dent.* 2000;20:575–583.
7. Froum SJ, Tarnow DP, Wallace SS, Rohrer MD, Cho SC. Sinus floor elevation using anorganic bovine bone matrix (OsteoGraf/N) with and without autogenous bone: a clinical, histologic, radiographic, and histomorphometric analysis—part 2 of an ongoing prospective study. *Int J Periodontics Restorative Dent.* 1998;18:529–543.
8. Whitaker JM, James RA, Lozada J, Cordova C, Garey DJ. Histological response and clinical evaluation of heterograft and allograft materials in the elevation of the maxillary sinus for the preparation of endosteal dental implant sites, simultaneous sinus elevation and root form implantation. An eight-month autopsy report. *J Oral Implantol.* 1989;15:141–144.
9. Garey DJ, Whitaker JM, James RA, Lozada JL. The histologic evaluation of the implant interface with heterograft and allograft materials: an eight-month autopsy report. Part II. *J Oral Implantol.* 1991;17:404–408.
10. Sennerby L, Lundgren S. Histologic aspects of simultaneous implant and graft placement. In: Jensen OT, ed. *The Sinus Bone Graft.* Chicago, Ill: Quintessence Publishing Co; 1999:95–105.
11. De Leonardis D, Pecora GE. Augmentation of the maxillary sinus with calcium sulphate: one-year clinical report from a prospective longitudinal study. *Int J Oral Maxillofac Implants.* 1999;14:869–878.

12. Pietrzak WS, Ronk R. Calcium sulphate bone void filler: a review and a look ahead. *J Craniofac Surg*. 2000;11:327–333.
13. Gitelis S, Piasecki P, Turner T, Haggard W, Charters J, Urban R. Use of a calcium sulphate-based bone graft substitute for benign bone lesions. *Orthopedics*. 2001;24:162–166.
14. Al Ruhaimi KA. Effects of adding calcium sulphate to grafting materials in early bone regeneration in osseous defects in rabbits. *Int J Oral Maxillofac Implants*. 2000;15:859–864.
15. Kelly CM, Wilkins RM, Gitelis G, Hartjen C, Watson JT, Kim PT. The use of a surgical grade calcium sulphate as a bone graft substitute. Results of a multicenter study. *Clin Orthop Relat Res*. 2001;382:42–50.
16. Bier SJ, Sinensky MC. The versatility of calcium sulphate: resolving periodontal challenges. *Compend Contin Educ Dent*. 1999;20:655–661.
17. Alexander DI, Manson NA, Mitchell MJ. Efficacy of calcium sulphate plus decompression bone in lumbar and lumbosacral spinal fusion: preliminary results in 40 patients. *Can J Surg*. 2001;44:262–266.
18. Ricci JL, Alexander H, Nadkarni P, et al. Biological mechanisms of calcium sulphate replacement by bone. In: Davies JE, ed. *Bone Engineering*. Toronto, Canada: Em Squared Inc; 2000:332–344.
19. Tay BK, Patel VV, Bradford DS. Calcium sulphate and calcium phosphate-based bone substitutes. Mimicry of the mineral phase of bone. *Orthop Clin North Am*. 1999;30:615–623.
20. Orsini M, Orsini G, Benloch D, et al. Comparison of calcium sulphate and autogenous bone graft to bioabsorbable membranes plus autogenous bone graft in the treatment of intrabony periodontal defects. A split-mouth study. *J Periodontol*. 2001;72:296–302.
21. Strocchi R, Orsini G, Iezzi G, et al. Bone regeneration with calcium sulphate: evidence for an increased angiogenesis in rabbits. *J Oral Implantol*. 2002;28:273–278.
22. Orsini G, Ricci J, Scarano A, et al. Bone defect healing with calcium sulphate particles and cement: an experimental study in rabbit. *J Biomed Mater Res B Appl Biomater*. 2004;68:199–208.
23. Guarnieri R, Pecora G, Fini M, et al. Medical grade calcium sulphate hemihydrate in healing of human extraction sockets. Clinical and histological observations at 3 months. *J Periodontol*. 2004;75:902–908.
24. Anson D. Calcium sulphate augmented soft tissue root coverage adjacent to connective tissue grafting: a new technique. *Int J Periodontics Restorative Dent*. 2003;23:337–343.
25. Maragos P, Bissada NF, Wang R, Cole BP. Comparison of three methods using calcium sulphate as a graft/barrier material for the treatment of class II mandibular molar furcation defects. *Int J Periodontics Restorative Dent*. 2002;2:493–501.
26. Harris RJ. Clinical evaluation of a composite bone graft with a calcium sulphate barrier. *J Periodontol*. 2004;75:685–692.
27. Hadjipaulou AG, Simmons JW, Yang J, Nicodemus CL, Esch O, Simmons DJ. Plaster of Paris as an osteoconductive material for interbony vertebral fusion in mature sheep. *Spine*. 2000;25:10–15.
28. Hadjipaulou AG, Simmons JW, Tzermiadanos MN, Katonis PG, Simmons DJ. Plaster of Paris as bone substitute in spinal surgery. *Eur Spine J*. 2001;10(Suppl 2):S186–S196.
29. Borrelli J Jr, Prickett WD, Ricci WM. Treatment of nonunions and osseous defects with bone grafts and calcium sulphate. *Clin Orthop Relat Res*. 2003;411:245–254.
30. Turner TM, Urban RM, Gitelis S, Haggard WO, Richelsoph K. Resorption evaluation of calcium sulphate in a canine maxillary defect. *Orthopedics*. 2003;26(5 Suppl):S577–S579.
31. Urban RM, Turner TM, Hall DJ, Infanger S, Cheema N, Lim TH. Healing of large defects treated with calcium sulphate pellets containing demineralised bone matrix particles. *Orthopedics*. 2003;26(5 Suppl):S581–S585.
32. Jamali A, Hilpert A, Debes J, Afshar P, Rahban S, Holmes R. Hydroxyapatite/calcium carbonate (HA/CC) vs plaster of Paris: a histomorphometric and radiographic study in a rabbit tibial model. *Calcif Tissue Int*. 2002;71:172–178.
33. Moed BR, Willson Carr SE, Craig JG, Watson JT. Calcium sulphate used as a bone graft substitute in acetabular fracture fixation. *Clin Orthop Relat Res*. 2003;410:303–309.
34. Walsh WR, Morberg P, Yu Y, et al. Response of a calcium sulphate bone graft substitute in a confined cancellous defect. *Clin Orthop Relat Res*. 2003;406:228–236.
35. Turner TM, Urban RM, Hall DJ, Cheema N, Lim TH. Restoration of large bone defects using a hard-setting injectable putty containing demineralised bone particles compared to cancellous autograft bone. *Orthopedics*. 2003;26(5 Suppl):S561–S565.
36. Turner TM, Urban RM, Hall DJ, et al. Osseous healing using injectable calcium sulphate-based putty for the delivery of demineralised bone matrix and cancellous bone chips. *Orthopedics*. 2003;26(5 Suppl):S571–S575.
37. Stubbs D, Deakin M, Chapman-Sheath P, et al. In vivo evaluation of resorbable bone graft substitutes in a rabbit tibial model. *Biomaterials*. 2004;25:5037–5044.
38. De Lange G, Tadjoein E. Fate of the HA coating of loaded implants in the augmented sinus floor: a human case study of retrieved implants. *Int J Periodontics Restorative Dent*. 2002;22:287–296.
39. Proussaefs P, Olivier HS, Lozada J. Histologic evaluation of a 12-year-old threaded hydroxyapatite-coated implant placed in conjunction with subantral augmentation procedure: a clinical report. *J Prosthet Dent*. 2004;92:17–22.
40. Jensen OT, Sennerby L. Histologic analyses of clinically retrieved titanium microimplants placed in conjunction with maxillary sinus floor augmentation. *Int J Oral Maxillofac Implants*. 1998;13:513–521.
41. Rosenlicht JL, Tarnow DP. Human histologic evidence of integration of functionally loaded implants placed simultaneously with sinus augmentation: a case report 2 1/2 years postplacement. *J Oral Implantol*. 1999;25:7–10.
42. Scarano A, Pecora G, Piattelli M, Piattelli A. Osseointegration in a sinus augmented with bovine porous bone mineral: histological results in an implant retrieved 4 years after insertion. A case report. *J Periodontol*. 2004;75:1161–1166.
43. Balkin BE, Steflik DE, Naval F. Mini-dental implant insertion with the auto-advance technique for ongoing applications. *J Oral Implantol*. 2001;27:32–37.
44. Froum SJ, Simon H, Cho SC, Elian N, Rohrer MD, Tarnow DP. Histologic evaluation of bone-implant contact of immediately loaded transitional implants after 6 to 27 months. *Int J Oral Maxillofac Implants*. 2005;20:54–60.
45. Piattelli A, Scarano A, Quaranta M. High-precision, cost-effective cutting system for producing thin sections of oral tissues containing dental implants. *Biomaterials*. 1997;18:577–579.
46. Wetzel AC, Stich H, Caffesse RG. Bone apposition onto oral implants in the sinus area filled with different grafting materials. A histological study in beagle dogs. *Clin Oral Implants Res*. 1995;6:155–163.
47. Artzi Z, Tal H, Dayan D. Porous bovine bone mineral in healing of human extraction sockets. Part 1: histomorphometric evaluations at 9 months. *J Periodontol*. 2000;71:1015–1023.
48. Hallman M, Lederlund A, Linsskog S, Lundgren S, Sennerby L. A clinical histologic study of bovine hydroxyapatite in combination with autogenous bone and fibrin glue for maxillary

sinus floor augmentation. Results after 8 months of healing. *Clin Oral Implants Res.* 2001;12:135–143.

49. Merckx MAW, Maltha JC, Stoelinga PJW. Assessment of the value of anorganic bone additives in sinus floor augmentation: a review of clinical reports. *Int J Oral Maxillofac Surg.* 2003;32:1–6.

50. Schlegel KA, Fichtner G, Schultze-Mosgau S, Wiltfang J. Histologic findings in sinus augmentation with autogenous bone chips versus a bovine bone substitute. *Int J Oral Maxillofac Implants.* 2003;18:53–58.

51. Yildirim M, Spiekermann H, Biesterfeld S, Edelhoff D. Maxillary sinus augmentation using xenogenic bone substitute material Bio-Oss in combination with venous blood. A histologic and histomorphometric study in humans. *Clin Oral Implants Res.* 2000;11:217–229.

52. Valentini P, Abensur D. Maxillary sinus floor elevation for implant placement with demineralized freeze-dried bone and bovine bone (Bio-Oss): a clinical study of 20 patients. *Int J Periodontics Restorative Dent.* 1997;17:233–241.