

ELECTRONIC PERCUSSIVE TESTING OF THE STABILITY OF AN IMMEDIATELY PROVISIONALIZED IMPLANT PLACED INTO A FRESH EXTRACTION SOCKET: A PILOT EVALUATION

Ira H. Orenstein, DDS; Daniel E. MacDonald, DMD, MSD; Anita C. Tao, DDS; Harold F. Morris, DDS, MS

It is important to achieve primary stabilization of dental implants that will be immediately loaded. Noninvasive devices that test the stability of immediately provisionalized implants placed into fresh extraction sockets are discussed. A titanium threaded implant was placed into a fresh extraction socket of a patient's nonrestorable mandibular right canine. The implant received an interim restoration immediately following its placement. The stability of the bone-implant complex was evaluated from the day of implant insertion through day 246 using an electronic percussive testing instrument. During the first month the bone-implant complex became progressively less stable reaching a peak measured level of instability at 30 days postimplantation. This was followed by progressive stabilization first measured on day 46 as the implant continued to osseointegrate. These findings suggest that the bone-implant complex became less stable during the first month after implant placement and was followed by a period of progressive stabilization reflecting bone maturation around the implant. A search of the literature found similar results in a study of single-stage implants (not immediately provisionalized) using resonance frequency analysis. The known sequence of wound healing around dental implants is reviewed to explain the findings of this pilot evaluation. Studies that use noninvasive testing devices to assess implant stability at placement and during healing may provide information that can help to optimize implant treatment outcomes.

Key Words: dental implant, primary stability, noninvasive tests, immediate provisional prosthesis, implant mobility

Ira H. Orenstein, DDS, is a staff dentist at the James J. Peters VA Medical Center, Bronx, NY, and an assistant clinical professor at the Division of Restorative Dentistry, Columbia University School of Dental Medicine, New York, NY. Address correspondence to Dr Orenstein at James J. Peters VA Medical Center, Dental Service (160), 130 West Kingsbridge Rd, Bronx, NY 10468 (e-mail: ira.orenstein@med.va.gov). Daniel E. MacDonald, DMD, MSD, is an assistant clinical professor in the Division of Periodontics, Columbia University School of Dental Medicine, New York, NY; an associate research scientist at Fu School of Graduate Engineering, Columbia University, New York, NY; an associate research scientist at the Hospital for Special Surgery affiliated with the Weill Medical College of Cornell University, New York, NY; and a periodontist at the Dental Service, James J. Peters VA Medical Center, Bronx, NY. Anita C. Tao, DDS, is a former general practice dental resident at the Mount Sinai/James J. Peters VA Medical Center, Bronx, NY. Harold F. Morris, DDS, MS, is a staff prosthodontist at the VA Medical Center, Ann Arbor, Mich, and a professor in the Department of Restorative Dentistry, Temple University, School of Dentistry, Philadelphia, Pa.

INTRODUCTION

The 2-stage endosseous root-form implant protocol proposed by Branemark et al¹ has been used to predictably restore the functional and esthetic needs of partially and fully edentulous patients. Numerous modifications of the original technique have evolved during the last several decades. It is now often possible to place an interim restoration on an implant immediately following its placement. Schnitman and coworkers² deviated from the usual 2-stage protocol by placing implants that immediately sup-

ported mandibular fixed interim prostheses. Other investigators^{3,4} reported on immediately loaded 2-stage and single-stage implants, respectively, to replace single missing teeth.

For the patient who requires the extraction of an anterior tooth, immediate implant insertion with concurrent placement of an interim restoration has been shown to be a highly predictable treatment consideration.^{5,6} While there are potential functional, esthetic, and emotional benefits associated with the placement and provisional restoration of an implant immediately following tooth extraction, there exists the potential to overload and compromise or lose the implant.

It is important to obtain primary stability (immediate mechanical fixation) of a dental implant. This is particularly true when a dental implant is placed into a fresh extraction socket and immediately provisionalized. Inadequate primary stabilization will result in excessive mobility leading to fibrous tissue encapsulation and exfoliation of the implant. Overcompression of the osteotomy site during implant placement, however, may result in bone microfractures, ischemia, and bone necrosis. Factors that influence primary implant stability include bone density, implant geometry, composition and surface characteristics, and operator skill.^{7,8}

Clinical analyses of early wound healing may help evaluate the course of osseointegration. Radiographic studies are 2-dimensional and lack adequate resolution to provide information about early healing. Invasive tests such as torque and pull-out, while appropriate for laboratory studies, cannot be used in the clinical setting. Noninvasive tests that can assess implant stability at placement and during the osseointegration period may be of clinical value. Two types of noninvasive tests are dynamic vibration analysis (Resonance Frequency Analysis, eg Osstell Mentor, Integration Diagnostics, AB, Gothenburg, Sweden) and electronic percussive testing (Periotest, Siemans AG, Bensheim, Germany).

Resonance frequency analysis (RFA) objectively measures the stability of the bone-implant complex using a tuning fork-like transducer device attached to the implant or abutment.⁹ Resonance frequency (RF) values correlate positively with implant stability and negatively with abutment height and marginal bone resorption.¹⁰ Unfortunately, RFA cannot be applied to an interim or definitive restoration as the transducer must be screwed directly to an implant or abutment in order to operate the instrument.

Electronic percussive testing (EPT) has been shown to provide reproducible data that quantify the stability of the bone-implant complex.¹¹⁻¹⁴ In an *in vitro* study,

Manz and coworkers¹⁵ reported that EPT provided good intra-examiner reliability and repeatability. They advised, however, that caution should be exercised when interpreting results from different examiners using different instruments. Conversely, Derhami and coworkers¹⁶ found that EPT provided good interexaminer and good interinstrumental reliability. Measurements values, however, may be affected by handpiece angulation, vertical point of measurement on the test object, horizontal distance of the plunger from the test object, and abutment length.¹⁶ It is therefore imperative that the examiner standardize the orientation of the handpiece and the point of contact. Unlike RFA, EPT can be used to examine a patient's interim or final implant/abutment-supported restoration.

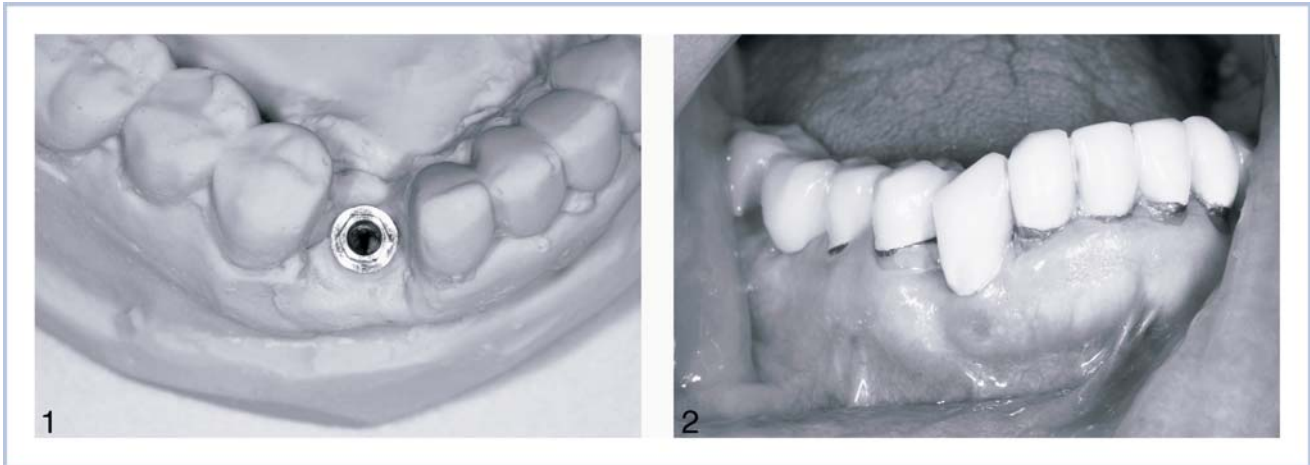
This pilot evaluation describes a procedure during which an implant was placed into a fresh extraction socket, immediately provided with an interim restoration, and monitored for changes in the stability of the bone-implant complex using EPT commencing the day of implant placement.

MATERIALS AND METHODS

A patient presented for a routine dental examination and was found to have extensive decay under the crown of the mandibular right canine. The decay extended well below the crest of bone and the tooth was deemed unrestorable. The treatment options along with their associated benefits and risks were carefully reviewed with the patient. The patient consented to have an implant placed at the time of tooth extraction to be followed immediately by the placement of an interim abutment and crown.

An interim customized abutment and crown were prepared from study casts for insertion at the time of tooth extraction and implant placement (Figure 1). In the event adequate primary stability of the implant could not be achieved upon insertion, a provisional acrylic removable partial denture was also fabricated.

The mandibular right canine was extracted uneventfully. Every effort was made to select an implant that would best fill the volume of the extraction socket in order to achieve primary stability. A 4 × 15-mm Branemark (MK III, Nobel Biocare USA, Inc, Yorba Linda, Calif) implant was placed in the extraction socket immediately following site preparation. The custom abutment was hand-tightened onto the implant and the interim crown was relined, adjusted, and luted with provisional cement (Temp-Bond NE, Kerr USA, Romulus, Mich) (Figure 2).



FIGURES 1 AND 2. FIGURE 1. The mandibular right canine was removed from the stone model and replaced by an implant analog in the anticipated orientation of the proposed implant. This allowed fabrication of a provisional abutment and restoration. Figure 2. The provisional abutment and restoration were delivered immediately following tooth extraction and implant placement. The interim restoration was kept out of occlusion.

Electronic percussive testing (EPT) was performed immediately following delivery of the interim abutment and crown. The EPT device (Periotest) was composed of a microcomputer with an attached handpiece that housed a percussion rod. The handpiece was held perpendicular to the sample being tested and the percussion rod impacted the object 16 times over a 4-second interval. The microcomputer analyzed the rate of deceleration of the rod as it rebounded from the object. In general, the more stable the implant or tooth is, the faster the rod will decelerate. The microcomputer converted this infor-

mation into a periostest value (PTV) and recorded it in the form of a digital display and audio readout. PTVs can range from -8 (clinically firm) to $+50$ (very loose).¹³ A range of -8 to $+9$ corresponds to 0 on the Miller index with no clinical visual evidence of mobility.¹³ For dental implants, a PTV of $+10$ or greater indicates a loose abutment or lack or loss of osseointegration. Median PTVs for osseointegrated root-form implants have been reported to be close to or below 0.¹⁴

The same clinician and unit were used throughout the study to maximize the reproducibility of the measurements. Several measurements were recorded at each interval and averaged. Care was taken to standardize the orientation of the handpiece. The plunger of the instrument's handpiece was oriented parallel to the floor and perpendicular to the facial aspect of the provisional crown just coronal to the free gingival margin for all recordings. The tip of the handpiece was positioned 1 to 2 mm from the surface of the crown. PTVs were obtained at several intervals throughout the entire interim restoration phase of treatment commencing the day of implant placement to day 246.

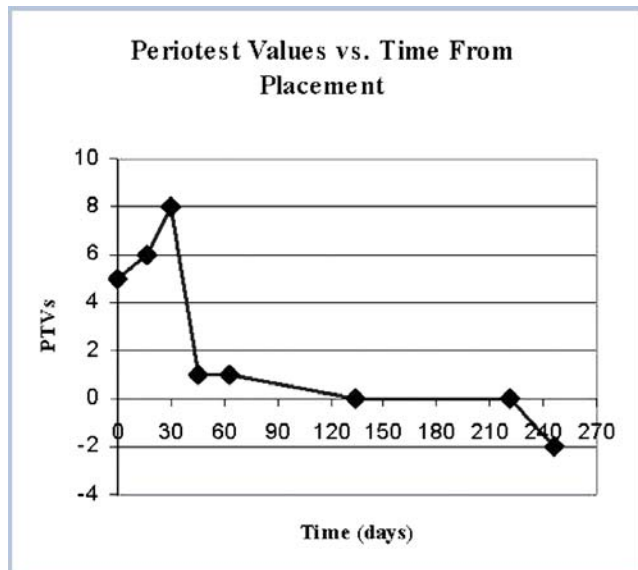


FIGURE 3. Periostest values were obtained for the immediately placed and provisionalized implant on the day of implant placement and at several other data points through day 246.

RESULTS

Healing was uneventful. The PTV at implant placement was $+5$, suggesting that good primary stability was achieved (Figure 3, Table). Periostest values were $+6$ and $+8$ on days 17 and 30, respectively, suggesting decreased stability of the bone-implant complex. This trend reversed, however, when a $+1$ PTV was obtained on day 46. Stability continued to improve to day 246, reaching -2 PTV.

TABLE

Periotest values over time for an immediately placed and provisionalized implant

Placement Time (days)	Periotest Values From Time of Implant Placement
0	5
17	6
30	8
46	1
63	1
134	0
221	0
246	-2

DISCUSSION

Electronic percussive testing provides the ability to measure subclinical mobility and therefore stability of the bone-implant complex in a manner that minimizes subjectivity. An implant was placed into a fresh extraction site and immediately provided with an interim restoration. The recorded PTVs suggest that the bone-implant complex became less stable during the first month after implant placement and was followed by a period of progressive stabilization.

This instrument may provide more information about the bone-implant complex than would be obtained by visual clinical examination alone. The findings in this pilot study are supported by the findings of Cranin and coworkers,¹⁷ who reported an inverse correlation between PTV recordings and implant stability when they examined 290 dental implants. In that study, however, the instrument could not reliably be used to detect the degree of crestal bone loss around implants. This shortcoming may be explained by the findings of Truhlar and coworkers,¹⁴ who reported on the PTV recordings of 2212 implants. The mean range of PTVs for bone qualities I to IV was less than 2. This would suggest that the instrument may lack the sensitivity required to detect very subtle changes in the bone-implant complex such as pericervical bone changes.¹⁷ Nevertheless, the instrument may be clinically useful for monitoring gross changes that occur during osseointegration.

Similar observations of early implant mobility followed by progressive stabilization have been reported using other research modalities. Branemark et al¹⁸ performed torque and pull-out tests in rat tibial metaphyses over time. These analyses showed that the stability of the bone-implant complex remained weak but constant during the first 4 weeks, followed by an increase in stability at 4 to 16 weeks. Barewal and coworkers¹⁹ monitored 27 single-stage implants that were placed in human posterior maxillae and mandibles (not immediately provisionalized) for changes in

implant stability from their time of insertion using RFA. The lowest mean implant stability was found at 3 weeks postplacement. Our observations using electronic percussive testing of an immediately provisionalized implant correlate positively with Barewal and colleagues' study¹⁹ using resonance frequency analysis. These findings suggest that there exists an interval between primary and secondary stability during which the mobility of the implant increases. This may be explained by understanding the sequence of wound healing events surrounding dental implants. When a dental implant is placed into a prepared bony site, its surface is initially coated with a fibrin clot followed by the formation of a loosely organized collagenous matrix with numerous interspersed blood cells.²⁰ Early osteoid formation is observed by day 14.^{21,22} Mineralization continues from days 14 through 21 with a distinct, poorly calcified interface zone that separates the nearly mineralized bone surface from the implant.^{20,23} This dense intervening organic matrix develops between the implant and bone and continues to mineralize until all that remains is a thin, partially calcified nonstructured ground substance composed of proteoglycans.²⁴⁻²⁶

Bone remodeling is subject to the amount of microstrain that is placed upon it.²⁷⁻²⁹ Below a minimum microstrain threshold, demineralization and bone loss occurs. Microstrain above a certain threshold produces hypertrophy (increased mineralization and bone growth). Microstrain beyond a microdamage threshold leads to fatigue failure (overload). Immediate or early physiologic loading of implants may therefore help to optimize the remodeling of bone.

Another factor that can potentially affect the course of osseointegration is the bony environment into which an implant is placed. Because of the very nature of placing a round, cylindrical object into an oval fresh extraction site, not all surfaces of the implant will necessarily make direct contact with bone. Titanium screw-type implants placed into the extraction sockets of humans were examined histologically at 6 months and 12 months postplacement.³⁰ The results showed that the degree of osseointegration did not differ between an implant placed directly into mature bone versus into a fresh extraction socket, provided the bone-to-implant gap was less than 2 mm. A large defect around the implant would facilitate the ingrowth of soft tissue into the area, compromising the amount of bone-implant contact. The PTV recording obtained immediately following implant placement suggests that primary stability was achieved, being derived from mechanical retention of the implant screw threads engaging the walls of the extraction socket/osteotomy site. The increasing PTVs (greater

mobility) observed during the period up to 30 days postimplant insertion was most likely caused by the bone remodeling process that resulted in resorption followed by apposition. Conversely, the dramatic reduction in PTVs measured after 30 days suggests sufficient bone-implant contact as a result of osseointegration. The implant continued to stabilize with time as the bone remodeled and matured, suggesting that microstrains were within physiologic limits.^{16–18} The final mobility recording was on day 246 (PTV = -2), at which point a new custom abutment and a porcelain-fused-to-metal crown were placed.

In this pilot evaluation, the recorded mobility was greatest on day 30, at which time soft tissue healing was complete. Increased patient comfort and masticatory function coincidental with this critical time of maximum implant mobility could result in implant overload. Future noninvasive mobility studies would employ greater numbers of implants to help determine at what point an implant is most vulnerable to overload and when implants can be immediately provisionalized without compromise. Noninvasive mobility studies can also address the effects that variables, such as implant geometry, surface characteristics, and surface treatments, may have on the course of osseointegration.

CONCLUSIONS

Electronic percussive testing demonstrated that an immediately placed and provisionalized implant progressively lost stability during the first month after placement, then increased stability through the end of the recording period. These findings were consistent with the histologic sequence of wound healing that takes place around dental implants. Future clinical studies using noninvasive techniques to assess an implant's stability from the time of placement may help to optimize implant design and treatment outcomes.

REFERENCES

1. Branemark PI, Adell R, Breine U, Hansson BO, Lindstrom J, Ohlsson A. Intra-osseous anchorage of dental prostheses. I. Experimental studies. *Scan J Plast Reconstr Surg.* 1969;3:81–100.
2. Schnitman PA, Wohrle PS, Rubenstein JE. Immediate fixed interim prostheses supported by two-stage threaded implants: methodology and results. *J Oral Implantol.* 1990;16:96–105.
3. Ericsson I, Nilson H, Lindh T, Nilner K, Randow K. Immediate functional loading of Branemark single tooth implants. An 18 months' clinical pilot follow-up study. *Clin Oral Implants Res.* 2000;11:26–33.
4. Andersen E, Haanaes HR, Knutsen B. Immediate loading of single-tooth ITI implants in the anterior maxilla: a prospective 5-year pilot study. *Clin Oral Impl Res.* 2002;13:281–287.
5. Schirotti G. Immediate tooth extraction, placement of a Tapered Screw-Vent implant, and provisionalization in the esthetic zone: a case report. *Implant Dent.* 2003;12:123–131.
6. Garber DA, Salama MA, Salama H. Immediate total tooth replacement. *Compend Contin Educ Dent.* 2001;22:210–218.
7. Meredith N. A review of nondestructive test methods and their application to measure the stability and osseointegration of bone anchored endosseous implants. *Crit Rev Biomed Eng.* 1998;26:275–291.
8. Meredith N. Assessment of implant stability as a prognostic determinant. *Int J Prosthodont.* 1998;11:491–501.
9. Meredith N, Alleyne D, Cawley P. Quantitative determination of the stability of the implant-tissue interface using resonance frequency analysis. *Clin Oral Implants Res.* 1996;7:261–267.
10. Meredith N, Book K, Friberg B, et al. Resonance frequency measurements of implant stability in vivo. *Clin Oral Implants Res.* 1997;8:226–233.
11. Manz MC, Morris HF, Ochi S. An evaluation of the Periotest system. Part I: Examiner reliability and repeatability of readings. Dental Implant Clinical Group (Planning Committee). *Implant Dent.* 1992;1:142–146.
12. Walker L, Morris HF, Ochi S. Periotest values of dental implants in the first 2 years after second-stage surgery: DICRG interim report no. 8. Dental Implant Clinical Research Group. *Implant Dent.* 1997;6:207–212.
13. Schulte W, Lukas D. Periotest to monitor osseointegration and to check the occlusion in oral implantology. *J Oral Implantol.* 1993;19:23–32.
14. Truhlar RS, Lauciello F, Morris HF, Ochi S. The influence of bone quality on Periotest values of endosseous dental implants at stage II surgery. *J Oral Maxillofac Surg.* 1997;55(12 Suppl 5):55–61.
15. Manz MC, Morris HF, Ochi S. An evaluation of the Periotest system. Part 1: examiner reliability and repeatability of readings. *Implant Dent.* 1992;1:142–146.
16. Derhami K, Wolfaardt JF, Faulkner G, Grace M. Assessment of the Periotest device in baseline mobility measurements of craniofacial implants. *Int J Oral Maxillofac Implants.* 1995;10:221–229.
17. Cranin AN, DeGrado J, Kaufman M, et al. Evaluation of the Periotest as a diagnostic tool for dental implants. *J Oral Implantol.* 1998;24:139–146.
18. Branemark R, Ohnell LO, Nilsson P, Thomsen P. Bio-mechanical characterization of osseointegration during healing: an experimental in vivo study in the rat. *Biomaterials.* 1997;18:969–978.
19. Barewal RM, Oates TW, Meredith N, Cochran DL. Resonance frequency measurement of implant stability in vivo on implants with sandblasted and acid-etched surfaces. *Int J Oral Maxillofac Implants.* 2003;18:641–651.
20. Masuda T, Salvi GE, Offenbacher S, Felton DA, Cooper LF. Cell and matrix reactions at titanium implants in surgically prepared rat tibiae. *Int J Oral and Maxillofac Implants.* 1997;12:472–485.
21. Dhert WJ, Thomsen P, Blomgren AK, Esposito M, Ericson LE, Verbout AJ. Integration of press-fit implants in cortical bone: a study on interface kinetics. *J Biomed Mater Res.* 1998;41:574–583.
22. Sennerby L, Thomsen P, Ericson LE. Early tissue response to titanium implants inserted in rabbit cortical bone. I. Light microscopic observations. *J Mater Sci Mater Med.* 1993;4:240–250.
23. Sennerby L, Thomsen P, Ericson LE. Early tissue response to titanium implants inserted in rabbit cortical bone. II. Ultrastructural observations. *J Mater Sci Mater Med.* 1993;4:494–502.
24. Linder L, Albrektsson T, Branemark PI, et al. Electron microscopic analysis of the bone-titanium interface. *Acta Orthop Scand.* 1983;54:45–52.
25. Stefflik DE, Parr GR, Sisk AL, et al. Osteoblast activity at the dental implant-bone interface: transmission electron microscopic

and high voltage electron microscopic observations. *J Periodontol.* 1994;65:404–413.

26. Steflik DE, Corpe RS, Young TR, Buttle K. In vivo evaluation of the biocompatibility of implanted biomaterials: morphology of the implant-tissue interactions. *Implant Dent.* 1998;7:338–350.

27. Carter DR, Caler WE. Cycle-dependent and time-dependent bone fracture with repeated loading. *J Biomech Eng.* 1983;105:166–170.

28. Frost HM. Transient-steady state phenomena in micro-damage physiology: a proposed algorithm for lamellar bone. *Calcif Tissue Int.* 1989;44:367–381.

29. Frost, HM. Some ABC's of skeletal pathophysiology. 5. Microdamage physiology. *Calcif Tissue Int.* 1991;49:229–231.

30. Paolantonio M, Dolci M, Scarano A, et al. Immediate implantation in fresh extraction sockets. A controlled clinical and histological study in man. *J Periodontol.* 2001;72:1560–1571.