

# SANDBLASTED/ACID-ETCHED VS SMOOTH-SURFACE IMPLANTS: IMPLANT MOBILITY AND CLINICAL REACTION TO EXPERIMENTALLY INDUCED PERI-IMPLANTITIS IN BEAGLE DOGS

Rodrigo Tadashi Martines, DDS; Wilson Roberto Sendyk, DDS, MSc, PhD; Alfredo Gromatzky, DDS, MSc, PhD; Patricia Ramos Cury, DDS, MSc, PhD

This study uses a sandblasted/acid-etched implant vs a smooth-surface implant to compare implant mobility and clinical reactions of peri-implant tissues to experimentally induced peri-implantitis in Beagle dogs. The right and left mandibular premolars were extracted from 5 Beagle dogs, and 2 smooth-surface (SS) implants and 2 sandblasted/acid-etched (SLA) implants were placed in each animal. After 120 days, healing abutments were connected. Fifteen days later, the prosthetic abutments were connected, the hygiene regimen was suspended, and peri-implantitis was induced by the insertion of cotton ligatures into the soft tissue around the implants. At baseline and 30, 60, and 90 days later, clinical attachment level (CAL), probing depth (PD), and mobility (MO) were measured. Probing depth increased significantly in the SLA group alone when baseline PD was compared with 30-, 60-, and 90-day evaluations ( $P < .05$ ). No significant differences were noted between the 2 implant groups ( $P > .05$ ). The loss in CAL was significant in both groups when the baseline value was compared with 30-, 60-, and 90-day evaluations ( $P < .02$ ). Comparison between the 2 implant groups revealed a greater loss in CAL in the SLA group at the 90-day evaluation period ( $P = .04$ ). A significant increase in mobility was seen in both groups when baseline values and 90-day evaluations were compared ( $P < .04$ ). However, no statistically significant differences were noted between the 2 implant groups ( $P > .05$ ). Experimentally induced peri-implantitis results in a greater loss of CAL in SLA implants than in SS implants in dogs; however, no differences in mobility or in PD have been noted between the 2 implant groups.

**Key Words:** dental implants, peri-implantitis, sandblasted/acid-etched surface, smooth surface

**Rodrigo Tadashi Martines, DDS**, is a Master's degree Student at the University of Santa Amaro, School of Dentistry, in São Paulo, Brazil. Address correspondence to Dr Martines at the Department of Periodontics and Implantology, School of Dentistry, University of Santo Amaro, Rua das Uvaías, 101 apto 103, Saúde, São Paulo SP, Brazil, Cep 04055-110. (e-mail: tdmartines@yahoo.com)

**Wilson Roberto Sendyk, DDS, MSc, PhD**, is Chairman and Professor and **Alfredo Gromatzky, DDS, MSc, PhD**, is Assistant Professor of the Department of Periodontics and Implantology, School of Dentistry, University of Santo Amaro, São Paulo, Brazil.

**Patricia Ramos Cury, DDS, MSc, PhD**, is Director of the Master's degree program in periodontics, Department of Periodontics, São Leopoldo Mandic Dental Research Center, Campinas SP, Brazil.

## INTRODUCTION

Over the past few decades, an improved understanding of the various parameters that influence osseointegration has resulted in high predictability and clinical success of dental implants. However, reports on the effects of various implant designs and surface coatings on peri-implant inflammation have caused considerable controversy. Whether implant design and surface charac-

teristics can influence bone loss around diseased implants remains unknown.

Tillmanns et al<sup>1,2</sup> evaluated 3 different dental implants (hydroxyapatite-coated, titanium plasma-sprayed, and machined titanium-alloy surfaces) used after ligature-induced peri-implantitis in dogs. They found no differences among the 3 implant types in terms of clinical attachment level, pocket probing depth, or bone density; however, greater mobility and an increase in vertical bone loss were noted with titanium-alloy implants when these were compared with hydroxyapatite-coated and titanium plasma-sprayed implants. Jovanovic et al<sup>3</sup> reported greater peri-implant bone resorption around hydroxyapatite-coated vs uncoated implants. Shibli et al<sup>4</sup> found no effect when they compared peri-implant bone loss associated with the use of ligature-induced peri-implantitis in 4 different surfaces—commercially pure implants, titanium plasma-sprayed implants, hydroxyapatite-coated implants, or acid-etched implants. Various studies have reported a lack of effect on the development and course of peri-implantitis when different types of coated implants were evaluated.<sup>4-6</sup>

Recently, Watzak et al<sup>7</sup> noted an absence of histomorphometric differences in peri-implant soft tissue of baboons when comparing commercially pure titanium, titanium plasma-sprayed, and sandblasted/acid-etched implants. However, after 1.5 years of functional loading and plaque accumulation, all implants showed severe peri-implant mucositis and less than 0.9 mm bone loss.

The aim of the present study is to compare implant mobility and clinical reactions of the peri-implant mucosa vs experimental peri-implantitis in Beagle dogs when sandblasted/acid-etched (SLA) or smooth-surface (SS) implants were used.

#### MATERIALS AND METHODS

The present study protocol was approved by the University of Santo Amaro Institutional Ethics Committee.

This study was conducted in 5 Beagle dogs aged about 2 years (range, 18 to 30 months) at the beginning of the experiment. The second, third, and fourth premolars on the left and right sides of the mandible were extracted, and the alveoli were allowed to heal for 90 days. Plaque control consisted of brushing the teeth 3 times a week with 0.12% chlorhexidine.

Following the 90-day healing period, fixtures were placed according to the surgical protocols recommended by the manufacturers. Each dog received 2 sandblasted, large grit, acid-etched implants (SLA) of

10 mm height (4.1 mm diameter) (ITI, Straumann, Basel, Switzerland) and 2 SS implants of 11 mm height (4 mm diameter) (STD; Nobel Biocare, Göteborg, Sweden). The implants were placed by an experienced operator in a random mesiodistal order, with the coating level/shoulder coinciding with the alveolar crest of the edentulous mandible on each side of the mandible. The flaps were attached with the use of resorbable sutures (Vycril; Ethicon, Johnson & Johnson, São José dos Campos, Brazil). After an additional 120 days, appropriate healing abutments for each system were placed. Cotton ligatures (GN Injecta, Diadema, Brazil) were placed around abutments cervical to the perimucosal margin, and plaque control was suspended.

After 15 days, an experienced examiner who was unaware of implant distribution used a University of North Carolina periodontal probe (PCP-UNC 15; Hu-Friedy Manufacturing Company, Chicago, Ill) to obtain clinical measurements. An endodontic rubber stopper was adapted to the probe and was slid to the gingival margin; measurements were taken with the use of a caliper (Mitutoyo Corporation, Kanagawa, Japan). Parameters were recorded from the buccal, lingual, distal, and mesial aspects of each implant.

Clinical attachment level (CAL) and probing depth (PD) were measured at baseline (immediately before the induction of peri-implantitis) and at 30, 60, and 90 days after induced peri-implantitis. CAL was measured from the occlusal portion of the abutment to the bottom of the probeable pocket. PD was measured from the peri-implant mucosal margin to the bottom of the probeable pocket.

Concomitantly, a Periotest instrument was used to evaluate the stability of the implants (Siemens, Bensheim, Germany). The handpiece tip was applied 3 mm from the implant shoulder on each facial surface of the abutment, parallel to the floor. Measurements were repeated until the same Periotest value was obtained twice.

Clinical and surgical procedures were performed with the patient under general anesthesia of dihydrothiazine chloral hydrate (0.15 mL/kg) and 25% sodium thiopental solution (0.5 mL/kg), as well as local anesthesia.

In the statistical analysis, differences between the left and right mandibular implants were not significant for any of the parameters measured. Both sides of the mandible were thus pooled for each implant design.

The Wilcoxon test was used to evaluate significant differences in CAL, PD, and implant mobility between and within groups. The significance level was set at 5%. Calculations were performed with the Statistical

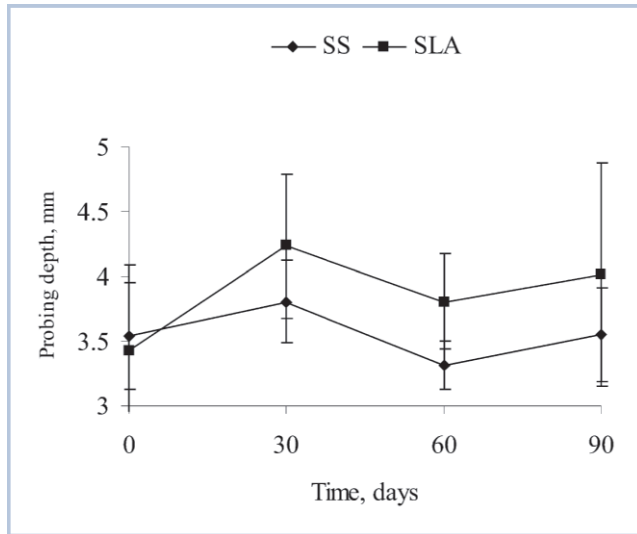


FIGURE 1. Mean increase in probing depth for 2 implant types (smooth-surface [SS] vs sandblasted/acid-etched [SLA]) during the 90-day observation period.

Package for the Social Sciences (SPSS) statistical software package (SPSS Inc, Chicago, Ill).

### RESULTS

Between 30 and 120 days after implantation, 3 SLA and 3 SS implants were lost. The remaining implants healed uneventfully and were included in the subsequent evaluations.

From the time of ligature placement, clinical examination revealed that the peri-implant mucosal tissue exhibited clinical signs of inflammation.

The mean increase in PD was statistically significant in the SLA group alone when the baseline PD was compared with 30-, 60-, and 90-day evaluations ( $P < .05$ ). Probing depth also tended to increase in the SLA group during the time between the 30- and 60-day evaluations. However, no significant differences were noted between implant types ( $P > .05$ ) (Figure 1).

The loss in CAL was significant in both groups when the baseline value was compared with the 30-, 60-, and 90-day evaluations ( $P < .02$ ) and in the SLA group when 60- and 90-day evaluations were compared ( $P < .02$ ). Comparison between the implant groups revealed a greater loss of CAL in the SLA group at the 90-day evaluation period ( $P = .04$ ) (Figure 2).

Mobility was increased significantly in both groups when baseline and 90-day evaluations were compared ( $P < .04$ ). Mobility was also significantly increased in the SLA group when the 30-day evaluation was compared with the 60- and 90-day evaluations ( $P < .04$ ). However, no statistically significant differences

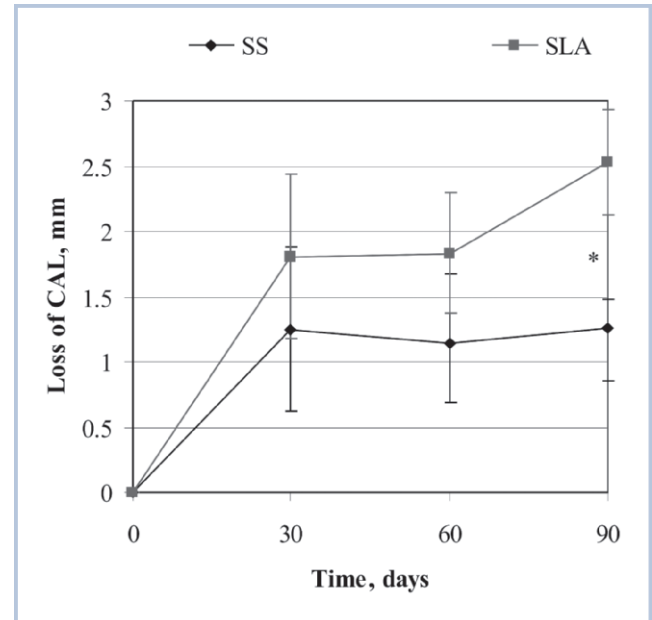


FIGURE 2. Mean loss of clinical attachment level (CAL) for both implant types (smooth-surface [SS] vs sandblasted/acid-etched [SLA] implant) during the 90-day observation period. \* $P < .05$ , on comparison of the 2 implant types; Wilcoxon test.

were noted between the 2 implant groups ( $P > .05$ ) (Figure 3).

### DISCUSSION

The present study shows that experimental peri-implantitis results in a greater loss of CAL with SLA implants than with SS implants. However, no differences in mobility or PD were noted.

Following the induction of peri-implantitis, PD increased significantly only in the SLA group, and a greater loss of CAL was seen in this group at the 90-day examination period. The loss of CAL was significant in both groups. The CAL loss demonstrated here is similar to that seen in monkeys with experimentally induced peri-implantitis.<sup>3</sup> Jovanovic et al<sup>3</sup> reported greater peri-implant bone resorption around hydroxyapatite-coated implants than around uncoated implants. Tilmanns et al<sup>2</sup> noted a smaller loss in CAL, but in contrast to our results, found no differences in CAL loss among 3 implant types (titanium-aluminum-vanadium alloy with a hydroxyapatite coating, commercially pure titanium plasma spray, and machined titanium-alloy surface finish). Other studies have reported no differences in the development and course of peri-implantitis around different types of coated implants.<sup>1,2,4-6</sup> Watzak et al<sup>7</sup> have shown that plaque accumulation and propaga-

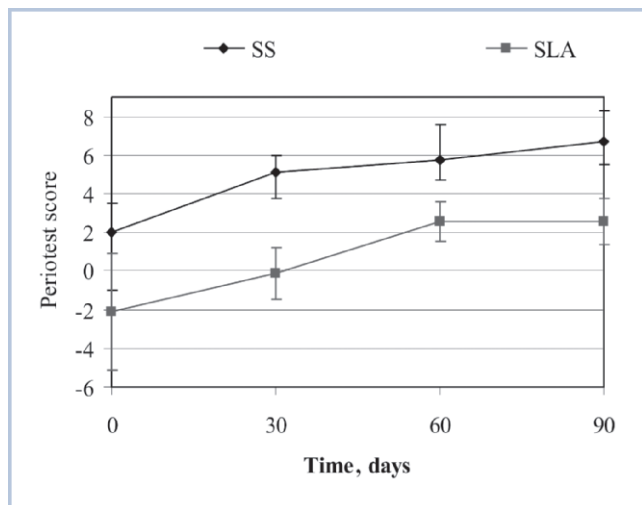


FIGURE 3. Mean Periotest values for both implant types (smooth-surface [SS] vs sandblasted/acid-etched [SLA] implant) during the 90-day observation period.

tion of peri-implant mucositis after 1.5 years of functional loading on SLA-surfaced implants are not influenced by implant design or surface modifications in baboons. To our knowledge, the greater progression of peri-implantitis has not been previously studied. The greater loss of CAL and the significant increase in PD in the SLA group noted here probably are associated with the surface roughness of this implant type. An increase in surface roughness and/or in surface free energy facilitates biofilm formation on restorative materials, and the effect of surface roughness seems to predominate.<sup>8</sup>

For teeth, PD and CAL are widely accepted as parameters that are sufficiently sensitive for periodontal diagnosis. However, the clinical description of peri-implant anatomy and inflammation is controversial and may derive from differences in probe tip location.<sup>1</sup> According to Ericsson and Lindhe,<sup>9</sup> the periodontal probe penetrates beyond the apical termination of the junctional epithelium to reach a level close to the bone crest. However, Quirynen et al<sup>10</sup> have shown that the relationship between probe attachment and bone level is comparable with that around the teeth, and measurements of CAL appear to provide the most sensitive reflection of peri-implant status. In the present study, clinical probing was employed in a longitudinal evaluation of periodontal breakdown; clinical studies have shown that implant failure related to recurrent peri-implant inflammation is associated with increased clinical probing.<sup>11</sup> Thus, independent of probe tip location, in the present study, this measure reliably reflects the progressive breakdown of peri-implant tissues.

Mobility is frequently used as a parameter in the assessment of major attachment changes in teeth. Implant mobility also has been regarded as one of the key parameters of implant success.<sup>12-14</sup> Because osseointegrated implants exhibit functional ankylosis,<sup>15</sup> a more sensitive method has been used to detect minor changes in implant integration over time.<sup>9,16,17</sup> In the present study, both implant groups showed a decrease in implant stability after 90 days, although no statistically significant differences were reported between the 2 implant groups.

For dental implants, a Periotest reading greater than +9 indicates the absence of osseointegration. No discernible movement corresponds to a Periotest score of -8 to +9.<sup>18</sup> In the present study, Periotest values fell between -3 and +13 (mean, +4.89) for the SS group, and between -6 and +12 for the SLA group (mean, +0.72). Before the induction of peri-implantitis, all SS implants showed a Periotest score below +9 and were considered to be osseointegrated. In the SLA group, 1 implant presented a Periotest score of +12 and was lost; however, osseointegration was not lost following induction of peri-implantitis. Two implants in the SS group lost osseointegration following peri-implantitis induction, showing Periotest scores of above +13 at 60 and 90 days; no loss of osseointegration was noted in the SLA group. Tillmanns et al<sup>1</sup> described an increase in implant mobility following experimental peri-implantitis, along with greater mobility measurements for titanium-aluminum-vanadium alloy implants than for hydroxyapatite-coated and pure titanium plasma spray-coated implants. However, their scores were lower than ours (from -3.88 to 0.62 periotest values).

## CONCLUSION

SLA implants provide several clinical advantages such as a single surgical procedure and an improved cost-benefit ratio; in addition, with this approach, the prosthetic phase can begin earlier and the implants are accessible for clinical monitoring during the osseointegration period.<sup>19</sup> However, according to our findings, experimental peri-implantitis results in a greater loss of clinical attachment in this implant type than in SS implants. Long-term clinical trials should be performed to assess the impact of this factor on implant success.

## REFERENCES

1. Tillmanns HW, Hermann JS, Cagna DR, Burgess AV, Meffert RM. Evaluation of three different dental implants in ligature-

- induced peri-implantitis in the beagle dog. Part I. Clinical evaluation. *Int J Oral Maxillofac Implants*. 1997;12:611–620.
2. Tillmanns HW, Hermann JS, Tiffée JC, Burgess AV, Meffert RM. Evaluation of three different dental implants in ligature-induced peri-implantitis in the beagle dog. Part II. Histology and microbiology. *Int J Oral Maxillofac Implants*. 1998;13:59–68.
  3. Jovanovic SA, Kenney EB, Carranza FA Jr, Donath K. The regenerative potential of plaque-induced peri-implant bone defects treated by a submerged membrane technique: an experimental study. *Int J Oral Maxillofac Implants*. 1993;8:13–18.
  4. Shibli JA, Martins MC, Lotufo RF, Marcantonio E Jr. Microbiologic and radiographic analysis of ligature-induced peri-implantitis with different dental implant surfaces. *Int J Oral Maxillofac Implants*. 2003;18:383–390.
  5. Wetzel AC, Vlassis J, Caffesse RG, Hammerle CH, Lang NP. Attempts to obtain re-osseointegration following experimental peri-implantitis in dogs. *Clin Oral Implants Res*. 1999;10:111–119.
  6. Cook SD, Rust-Dawicki AM. In vivo evaluation of CSTI dental implants in the presence of ligature-induced peri-implantitis. *J Oral Implantol*. 1995;21:191–200.
  7. Watzak G, Zechner W, Tangl S, Vasak C, Donath K, Watzek G. Soft tissue around three different implant types after 1.5 years of functional loading without oral hygiene: a preliminary study in baboons. *Clin Oral Implants Res*. 2006;17:229–236.
  8. Teughels W, Van Assche N, Sliepen I, Quirynen M. Effect of material characteristics and/or surface topography on biofilm development. *Clin Oral Implants Res*. 2006;17(suppl 2):68–81.
  9. Ericsson I, Lindhe J. Probing depth at implants and teeth: an experimental study in the dog. *J Clin Periodontol*. 1993;20:623–627.
  10. Quirynen M, van Steenberghe D, Jacobs R, Schotte A, Darius P. The reliability of pocket probing around screw-type implants. *Clin Oral Implants Res*. 1991;2:186–192.
  11. Mombelli A, van Oosten MA, Schurch E Jr, Land NP. The microbiota associated with successful or failing osseointegrated titanium implants. *Oral Microbiol Immunol*. 1987;2:145–151.
  12. Branemark PI, Hansson BO, Adell R, et al. Osseointegrated implants in the treatment of the edentulous jaw: experience from a 10-year period. *Scand J Plast Reconstr Surg Suppl*. 1977;16:1–132.
  13. Adell R, Lekholm U, Rockler B, Branemark PI. A 15-year study of osseointegrated implants in the treatment of the edentulous jaw. *Int J Oral Surg*. 1981;10:387–416.
  14. Smith DE, Zarb GA. Criteria for success of osseointegrated endosseous implants. *J Prosthet Dent*. 1989;62:567–572.
  15. Schroeder A, van der Zypen E, Stich H, Sutter F. The reactions of bone, connective tissue, and epithelium to endosteal implants with titanium-sprayed surfaces. *J Maxillofac Surg*. 1981;9:15–25.
  16. Truhlar RS, Morris HF, Ochi S, Winkler S. Assessment of implant mobility at second-stage surgery with the Periotest: DICRG Interim Report No. 3. Dental Implant Clinical Research Group. *Implant Dent*. 1994;3:153–156.
  17. Berglundh T, Lindhe J, Ericsson I, Marinello CP, Liljenberg B, Thomsen P. The soft tissue barrier at implants and teeth. *Clin Oral Implants Res*. 1991;2:81–90.
  18. Olive J, Aparicio C. Periotest method as a measure of osseointegrated oral implant stability. *Int J Oral Maxillofac Implants*. 1990;5:390–400.
  19. Buser D, Mericske-Stern R, Dula K, Lang NP. Clinical experience with one-stage, non-submerged dental implants. *Adv Dent Res*. 1999;13:153–161.