

# Short-term and long-term effects of rapid maxillary expansion on the nasal soft and hard tissue: A cone beam computed tomography study

Cassie T. Truong<sup>a\*</sup>; Hyeran H. Jeon<sup>b\*</sup>; Puttipong Sripinun<sup>c</sup>; Ann Tierney<sup>d</sup>; Normand S. Boucher<sup>e</sup>

## ABSTRACT

**Objectives:** To evaluate nasal soft and hard tissue changes immediately post-rapid maxillary expansion (RME) and to assess the stability of these changes using cone beam computed tomography (CBCT).

**Materials and Methods:** A total of 35 treatment group (TG) patients (18 girls, 17 boys;  $9.39 \pm 1.4$ ) had a pre-RME CBCT and a post-RME CBCT approximately 66 days after expansion, and 25 patients had a follow-up CBCT 2.84 years later. A total of 28 control group (CG; no RME) patients (16 girls, 12 boys;  $8.81 \pm 1.6$ ) had an initial CBCT and a CBCT an average of 2.25 years later. Soft and hard tissue nasal landmarks were measured in transverse, sagittal, and coronal planes of space on CBCT scans. Differences within the same group were evaluated by paired *t*-tests or Wilcoxon signed-rank tests. Long-term comparisons between TG and CG were evaluated by independent-sample *t*-tests or Wilcoxon rank-sum tests.

**Results:** Immediately post-RME, there were statistically significant mean increases of 1.6 mm of alar base width, 1.77 mm of pyriform height, and 3.57 mm of pyriform width ( $P < .05$ ). CG showed the significant increases over 2.25 years ( $P < .001$ ). Compared with CG, the long-term evaluation of TG demonstrated only pyriform height and pyriform width showed a statistically significant difference ( $P < .01$ ).

**Conclusions:** Although RME produced some significant increase on the nasal soft tissue immediately after expansion, it regressed to the mean of normal growth and development over time. However, long-term evaluation of TG compared with CG showed only pyriform height and pyriform width to be affected by RME. (*Angle Orthod.* 0000;00:000–000.)

**KEY WORDS:** Rapid maxillary expansion (RME); Nasal tissues; Long term; Short term

## INTRODUCTION

Rapid maxillary expansion (RME) is a common way to correct a narrow maxilla in adolescents. In addition, it helps eliminate mandibular shifts upon closure, provides more space for erupting maxillary teeth, and lessens dental arch distortion and potential tooth abrasion from dental interferences.<sup>1–4</sup> The skeletal effects for the maxillary hard tissue changes are well documented, but there are fewer studies that examine RME effects on the nasal soft and hard tissue. Furthermore, the previous studies that have evaluated nasal tissue changes have been limited and contradictory, and utilized a variety of data intake modalities, making their findings unclear.

The earliest study was by Berger et al.<sup>5</sup> in 1999, which analyzed photographic renderings of facial changes associated with maxillary expansion. They found an increase in nasal width post-orthopedic and

<sup>a</sup> Private Practice, Seattle, Wash, USA.

<sup>b</sup> Assistant Professor, Department of Orthodontics, School of Dental Medicine, University of Pennsylvania, Philadelphia, Pa, USA.

<sup>c</sup> Orthodontic Resident, Department of Orthodontics, School of Dental Medicine, University of Pennsylvania, Philadelphia, Pa, USA.

<sup>d</sup> Biostatistician, Center for Clinical Epidemiology and Biostatistics, Perelman School of Medicine, University of Pennsylvania, Philadelphia, Pa, USA.

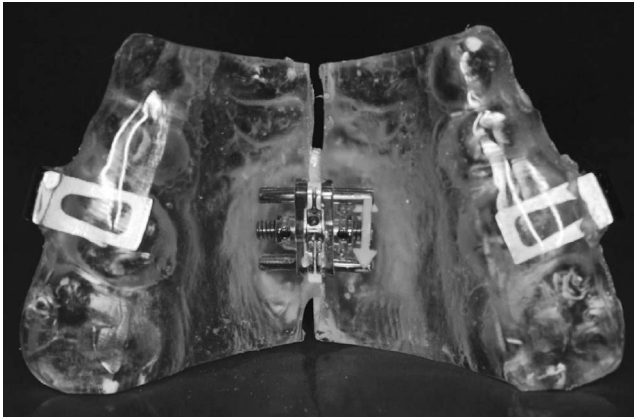
<sup>e</sup> Associate Clinical Professor, Department of Orthodontics, School of Dental Medicine, University of Pennsylvania, Philadelphia, Pa, USA.

Corresponding author: Dr Normand S. Boucher, 333 W. Lancaster Ave., Wayne, PA 19087, USA  
(e-mail: nsjboucher@gmail.com)

Accepted: July 2020. Submitted: February 2020.

Published Online: October 12, 2020

© 0000 by The EH Angle Education and Research Foundation, Inc.



**Figure 1.** All patients of TG were delivered a bonded rapid maxillary expander extending from the primary or permanent canine to the permanent first molar.

surgical expansion that was maintained 1 year after treatment. Filho et al.<sup>6</sup> also used facial analysis to assess nasal morphology in children following RME and found contradictory results to Berger et al.,<sup>5</sup> concluding that RME had no impact on nasal morphology. Johnson et al.<sup>7</sup> used a caliper and clinical measurements reporting significant increases of alar width (defined as greater alar cartilage) in the RME group in age groups 11 to 13 compared with a normative sample group, but this increase did not show a clinically significant effect. Santariello et al.<sup>8</sup> analyzed nasal dimensions in pre-pubertal patients during clinical sessions similar to Johnson et al.<sup>7</sup> and were in agreement that RME induced an increase in alar width. These studies used a variety of methods from photographic analysis to in-person clinical exams and were limited to only evaluating nasal changes immediately following RME. These methods can introduce various errors, including frontal photographic error, examiner bias, and patient movement during clinical exams. Studies that have employed a variety of traditional two-dimensional cephalometrics neglect structures lateral to the midline, cannot measure the transverse dimension, and have difficulty in reliably identifying soft tissue landmarks.

Recent cone beam computed tomography (CBCT) studies introduced a more accurate and reproducible method in evaluating in the transverse dimension. In 2012, Kim et al.<sup>9</sup> was one of the first CBCT studies to evaluate nasal soft tissue changes. This was followed by Badreddine et al.<sup>10,11</sup> in 2018, who studied changes in the noses of mouth-breathing patients using multi-slice computed tomography scans. These studies focused on the short-term nasal soft and hard tissue changes after expansion.

This is the first study to compare the long-term effect of RME on nasal tissue with a nontreatment control

group using CBCT. The goal of this study was to evaluate the short-term and long-term effects of RME on nasal soft and hard tissue and compare the effects with a control group using CBCT.

## MATERIALS AND METHODS

The study consisted of 63 patients, of which 35 patients (18 girls, 17 boys; average age  $9.39 \pm 1.4$ ) were diagnosed with a constricted maxilla, treated with RME, and placed in the treatment group (TG). The remaining 28 patients (16 girls, 12 boys; average age  $8.81 \pm 1.6$ ) were only subjected to routine records and placed in the control group (CG). All patients were evaluated at the private practice office of Dr Boucher. Exclusionary factors included patients with severe skeletal asymmetries, craniofacial anomalies, and syndromic patients and patients with prior orthodontic treatment or any other surgeries in the craniofacial complex. This retrospective study was approved by the Institutional Review Board, University of Pennsylvania, under Institutional Review Board Protocol 829908.

After initial routine records, patients of the TG were delivered a full coverage bonded rapid palatal expander extending from the maxillary primary or permanent canine to the maxillary first molar (Figure 1). The expanders had four predrilled holes in the palatal acrylic prior to cementation to measure the extent of expansion. With a digital caliper, the distance between the anterior and posterior holes were measured and averaged. Patients and parents were instructed to perform two turns per day (0.2 mm/turn) until adequate expansion was reached.

A CBCT was taken as part of the initial (T1 and T1') records of all 63 patients (35 for TG and 28 for CG) on an I-CAT machine (Imaging Sciences International, Hatfield, Pa). For the patients of the TG, immediate post-RME CBCT images (T2) were taken approximately 66 days after initial delivery. A smaller window of exposure was taken at post-RME, decreasing the time from 20 to 10 seconds, halving the amount of radiation exposure to the patients. Fixed comprehensive orthodontic treatment, including wires and brackets, were only placed after post-RME. A subsequent progress CBCT was taken for 25 patients of the TG (T3) 2.84 years after post-RME. Generally, T3 CBCTs were taken for the phase II records when the secondary teeth had erupted, and it was clear that the malocclusion was not fully corrected during the phase I treatment. Progress records as part of phased treatment is the standard of care for most orthodontists and is advocated by the American Board of Orthodontics. One of the reasons for the attrition at T3 was that some patients required no additional treatment after palatal expansion.

**Table 1.** Definition of Soft and Hard Tissue Landmarks<sup>a</sup>

Landmark	ST or HT	Definition
Alar	ST	Most lateral point of the contour of each nostril
Alar base	ST	Most lateral point of the base insertion of each nostril
Nasion soft tissue	ST	Soft tissue point of the most anterior aspect of the frontonasal suture
Pronasale	ST	Most anterior point of the nose soft tissue down the midsagittal plane
Subnasale	ST	Intersection of the nasal septum and upper lip that meet in the midsagittal plane
Nasion	HT	Most anterior aspect of the frontonasal suture
ANS	HT	Anterior tip of the nasal spine
PNS	HT	Most posterior aspect of the palatine bone
Superior pyriform aperture	HT	Most superior point of the bony anterior limitation of the nasal skeletal down the midsagittal plane
Inferior pyriform aperture	HT	Most inferior point of the bony anterior limitation of the nasal skeletal down the midsagittal plane

<sup>a</sup> Landmarks placed in soft tissue (ST) or hard tissue (HT).

The CG consisted of a total of 28 patients who had visited from November 2006 to July 2016 and presented for an orthodontic consultation, where the clinical examination revealed a malocclusion, records were taken, and following the review of records, treatment was not initiated for 1 to 2 years. Some patients were referred to an otolaryngologist for a consultation related to hypertrophy of the adenoids and tonsils, several sought second opinions and returned later, and others postponed treatment for financial reasons. The control patients had skeletal Class 1 or mild to moderate Class 2 attributed to mandibular retrognathia. Most patients had anterior arch perimeter deficiencies. Of 28 patients, 6 had posterior crossbite. Updated records were taken at T3', an average of 2.25 years after T1'.

All CBCTs were anonymized, oriented, and standardized in Dolphin Imaging (version 11.9; Dolphin Imaging & Management Solutions, Chatsworth, Calif). Orientation was completed in three planes of space from the frontal and lateral views. From the frontal, inferior rims of the orbit were placed symmetrically and parallel to the floor. The midsagittal line was placed at the soft tissue of nasion, through the pronasale, to the middle of the chin. From the lateral views, the Frankfort horizontal line (inferior border of the orbital rim to porion) was oriented parallel to the floor. The coronal line was placed just posterior to the condyle. The right lateral view was turned to be superimposed as closely

as possible to the left lateral view without a cant. Soft and hard nasal tissue points were chosen as landmarks that would give accurate measurements of any changes that occurred in the nasal complex post-RME. They are shown and defined in Tables 1 and 2 and Figure 2a,b,c. The landmarks were measured in millimeters on the CBCTs in three dimensions in Dolphin Imaging.

Descriptive statistics of the data, including means (M), standard deviations (SD), and 95% confidential intervals, were calculated for T1, T2, and T3 for the treated group and T1' and T3' for the control group. Differences between timepoints and within a treatment group were evaluated by paired *t*-tests or Wilcoxon signed-rank tests. Long-term comparisons between treatment and control groups were evaluated by independent-sample *t*-tests or Wilcoxon rank-sum tests. Nonparametric tests were used when the Shapiro-Wilk test was statistically significant at a *P* value < .05. *P* values for the 40 pairwise comparisons were adjusted using Hochberg's step-up Bonferroni method and considered statistically significant when < .05. SAS version 9.4 (SAS Institute Inc, Cary, N.C.) was used for these analyses. To assess the reliability of the numerical measurements of all variables, all samples from both groups were repeatedly measured after 2 weeks by the same investigator (P.S.) according to Houston.<sup>12</sup> The power was calculated for detecting group differences in T1 to T3 change in alar base width. Using group sample sizes of 25 and 28 and pooled SDs of 0.879,<sup>13</sup> there was an estimated 98% power to detect a 1-mm difference between groups.

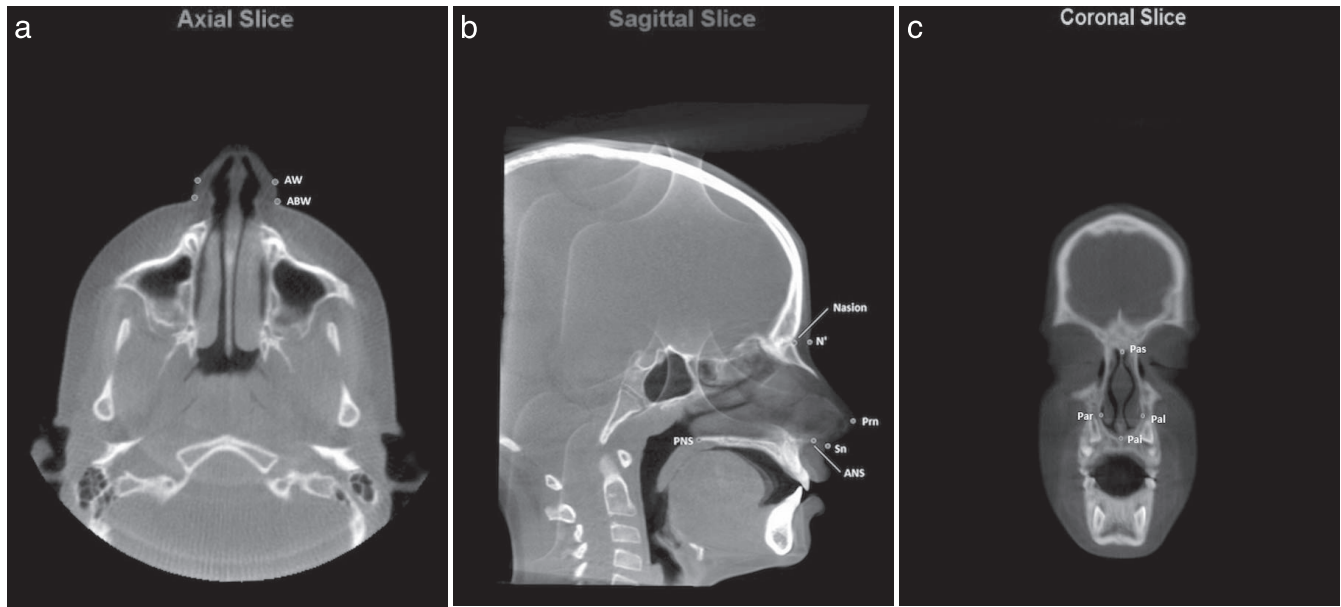
**Table 2.** Description of Measurements

Measurement	Landmark
Alar width	Alar width right–alar width left
Alar base width	Alar base width right–alar base width left
Nasal length	Pronasale–Subnasale
Nasal height	Nasion soft tissue–Subnasale
Nasion–ANS height	Nasion–ANS
ANS–PNS length	ANS–PNS
Pyriform height	Superior pyriform aperture–inferior pyriform aperture
Pyriform width	Par=right pyriform aperture. Pal= left pyriform aperture

## RESULTS

### Immediate Post-RME Nasal Soft and Hard Tissue Changes

Table 3 shows the descriptive statistics of the soft and hard tissue variables for TG. Table 4 depicts the comparison of T1 and T2 values of the soft and hard nasal tissue variables of the TG. At the alar base width,



**Figure 2.** Landmarks in (a) axial, (b) sagittal, and (c) coronal slices. ABW, alar base width; ANS, anterior nasal spine; AW indicates alar width; N', nasion soft tissue; Pas, superior pyriform aperture; Pai, inferior pyriform aperture; Pal, left pyriform aperture; Par, right pyriform aperture; PNS, posterior nasal spine; Prn, pronasale; Sn, subnasale.

there was a mean increase of 1.60 mm ( $P < .0001$ ). For alar width, nasal length, and nasal height, there was an increase of 0.65 mm, 0.14 mm and 0.34 mm, respectively ( $P > .05$ ). With the skeletal tissues, there was an increase of pyriform height of 1.77 mm ( $P < .0001$ ) and of pyriform width of 3.57 mm ( $P < .0001$ ) when comparing T1 and T2 of the TG. For nasion–anterior nasal spine (ANS) height and ANS–posterior nasal spine (PNS) length, there were increases of 1.04 mm and 0.34 mm, respectively ( $P > .05$ ).

### Long-Term Post-RME Nasal Soft and Hard Tissue Changes

To evaluate the long-term effects of RME on the nasal tissue, T2 and T3 values of the TG were examined (Table 4). Of 35 at T1, there were 22 at T2 and 25 at T3. Alar base width and pyriform height measurements that significantly increased immediately post-RME remained stable during a span of 2.58 years

when compared with T3. There were increases in nasal height (+3.92 mm) and nasion–ANS height (+2.75 mm) and a decrease in pyriform width (−1.07 mm) ( $P < .05$ ), possibly attributed to vertical growth and skeletal transverse relapse during the follow-up period.

### Long-Term Comparison of TG vs CG

Table 5 shows the descriptive statistics of the soft and hard tissue variables for CG. Table 6 depicts the comparison of T1' and T3' values of the soft and hard nasal tissue variables of the CG. The control group showed significant differences regarding all measurements except pyriform width from T1' to T3', demonstrating the effect of growth (Table 6). The increase in pyriform width was 0.30 mm ( $P = .056$ ). Table 7 illustrates the comparison of changes that occurred between T1 and T3 (TG) and T1' and T3' (CG). There was no significant difference in the nasal soft and hard

**Table 3.** Descriptive Statistics of the Soft and Hard Tissue Variables for TG<sup>a</sup>

	T1	T2	T3
No. of sample	35	22	25
Alar width	31.03 ± 2.3	31.86 ± 2.5	33.76 ± 3.1
Alar base width	31.25 ± 2.2	32.89 ± 2.6	33.73 ± 2.9
Nasal length	14.93 ± 1.6	15.02 ± 1.8	16.32 ± 1.6
Nasal height	47.45 ± 3.6	47.90 ± 3.2	52.1 ± 3.6
Nasion–ANS height	44.65 ± 3.7	45.79 ± 4.0	49.06 ± 3.4
ANS–PNS length	48.47 ± 3.0	50.02 ± 2.8	48.50 ± 3.1
Pyriform height	36.64 ± 3.2	38.81 ± 3.5	40.37 ± 2.8
Pyriform width	22.38 ± 1.7	26.60 ± 1.6	24.74 ± 1.9

<sup>a</sup> Values are mean ± SD. Measurements for parameters are shown in mm.



**Table 4.** Comparison of the Soft and Hard Tissue Variables for TG<sup>a</sup>

Variables	T1 to T2 (n = 22)				T2 to T3 (n = 22)				T1 to T3 (n = 25)			
	Mean	SD	95% CI	P Value	Mean	SD	95% CI	P Value	Mean	SD	95% CI	P Value
Alar width	0.65	1.1	0.15 to 1.15	.166	1.08	1.7	0.02 to 2.13	.4138	2.17	2.0	1.33 to 3.02	.0005 <sup>b*</sup>
Alar base width	1.60	1.2	1.06 to 2.14	<.0001 <sup>*</sup>	-0.21	0.7	-0.64 to 0.22	.7246	1.95	1.8	1.18 to 2.71	.0006 <sup>b*</sup>
Nasal length	0.14	1.5	-0.52 to 0.80	.7246	0.96	0.9	0.39 to 1.53	.0580	1.40	1.1	0.94 to 1.87	<.0001 <sup>b*</sup>
Nasal height	0.34	1.7	-0.44 to 1.12	.7246	3.92	1.4	2.99 to 4.85	<.0001 <sup>*</sup>	4.39	1.9	3.62 to 5.16	<.0001 <sup>c*</sup>
Nasion-ANS height	1.04	1.7	0.29 to 1.80	.1195	2.75	1.8	1.51 to 3.98	.0107 <sup>*</sup>	3.89	1.7	3.17 to 4.61	<.0001 <sup>b*</sup>
ANS-PNS length	0.34	1.2	-0.21 to 0.89	.7246 <sup>c</sup>	0.80	1.0	0.17 to 1.43	.1956	0.89	1.2	0.40 to 1.38	.0187 <sup>b*</sup>
Pyriform height	1.77	1.1	1.27 to 2.26	<.0001 <sup>*</sup>	1.36	1.5	0.43 to 2.29	.1170	3.37	1.1	2.92 to 3.82	<.0001 <sup>b*</sup>
Pyriform width	3.57	1.2	3.04 to 4.10	<.0001 <sup>*</sup>	-1.07	0.8	-1.60 to -0.53	.0192 <sup>*</sup>	2.66	1.0	2.24 to 3.09	<.0001 <sup>b*</sup>

<sup>a</sup> 95% CI indicates 95% confidence interval.

<sup>b</sup> Paired *t*-test.

<sup>c</sup> Wilcoxon rank-sum test.

\* Statistically significant at Hochberg *P* values < .05.

tissue measurements except for pyriform height and pyriform width attributed to the RME (*P* < .05).

### Intraexaminer Reliability

After all sample remeasurements by the same investigator (P.S.) at least 2 weeks apart, the intraclass correlation coefficients were calculated and ranged from 0.976 to 0.999, which assured the reproducibility of all measurements.

### DISCUSSION

Based on the intimate relationship of the maxilla and the nasal cavity,<sup>14</sup> there has been a growing interest for orthodontists to study the effect of expansion on the nasal anatomy and its impact on nasal physiology relative to the airway. In this study, the nasal soft and hard tissue changes after RME and the stability of these changes were examined. In addition, the use of CBCT scans was a more reliable way to diagnose and analyze the changes that occurred during expansion.

The short-term effect outcomes showed a 1.6 mm increase of the alar base width, which was closer to the underlying skeletal change. This was in agreement with previous studies showing less than 2 mm widening of the alar base.<sup>5,7,15</sup> Studies that were reliant

**Table 5.** Descriptive Statistics of the Soft and Hard Tissue Variables for CG<sup>a</sup>

	T1'	T3'
No. of sample	28	28
Alar width	30.80 ± 2.8	32.63 ± 3.1
Alar base width	31.44 ± 2.5	32.73 ± 2.9
Nasal length	14.90 ± 2.2	15.63 ± 2.1
Nasal height	46.81 ± 3.65	49.68 ± 4.4
Nasion-ANS height	44.25 ± 3.1	46.95 ± 3.9
ANS-PNS length	47.00 ± 3.0	48.09 ± 3.4
Pyriform height	36.38 ± 3.0	38.30 ± 3.3
Pyriform width	22.40 ± 2.0	22.70 ± 2.2

<sup>a</sup> Values are mean ± SD. Measurements for parameter are shown in mm.

on facial photographs and in-person clinical measurements reported various outcomes. Baysal et al.<sup>13</sup> reported that alar base width was greater by approximately 1 mm in the RME treatment group after a 6-month retention period. Badreddine et al.<sup>11</sup> reported that, after RME, the alar base width, alar width, and height of the nasal soft tissues increased, whereas changes did not occur in the control group. Berger et al.<sup>5</sup> reported a 2-mm increase in alar width, which was maintained 1 year after tooth-borne expansion. Johnson et al.<sup>7</sup> reported that alar base width increased 1.98 mm in the treated group compared with the control group, but the difference might not be clinically significant on the impact to the whole face. On the contrary, Filho et al.<sup>6</sup> showed no impact on nasal morphology using facial analysis, concluding that RME was incapable of influencing the nasal soft tissues. Torun reported no significant differences observed in soft tissue alar base, nostril width, nostril height, and nasolabial angle.<sup>16</sup> Discrepancies in the extent of nasal soft tissue changes with RME may be attributable to different measurement methods, expansion protocols, age groups, and/or amounts of expansion. Another potential side effect after RME could be the development of a dorsal hump,<sup>5,17,18</sup> which was not found in the patients in this study. The short-term nasal hard tissue change showed a significant increase in pyriform height and width, which was consistent with Badreddine et al.,<sup>10,11</sup> Cordasco et al.,<sup>19</sup> Palaisa et al.,<sup>20</sup> and Fastuca et al.<sup>21</sup>

For the long term, this study examined how RME affected patients' nasal growth in comparison with the nontreatment CG. The differences between T1 and T3 values in the TG ( $\Delta$  T1-T3, average 2.84 years) was compared with the differences between T1' and T3' in the CG ( $\Delta$  T1'-T3', average 2.25 years). There were no statistically significant differences across all measurements except for the nasal hard tissue pyriform height and pyriform width. This suggests that the significant soft tissue changes that occurred during expansion

**Table 6.** Comparison of the Soft and Hard Tissue Variables for CG

	T1' to T3' (n = 28)			
	Mean	SD	95% CI	P Value
Alar width	1.83	1.5	1.26–2.40	<.0001 <sup>a*</sup>
Alar base width	1.29	1.4	0.76–1.81	.0006 <sup>a*</sup>
Nasal length	0.94	0.8	0.62–1.27	<.0001 <sup>a*</sup>
Nasal height	2.87	2.0	2.11–3.63	<.0001 <sup>b*</sup>
Nasion–ANS height	2.70	1.9	1.98–3.42	<.0001 <sup>a*</sup>
ANS–PNS length	1.10	1.3	0.61–1.58	<.0001 <sup>b*</sup>
Pyriform height	1.92	1.2	1.46–2.38	<.0001 <sup>b*</sup>
Pyriform width	0.30	0.5	0.11–0.49	.0558

<sup>a</sup> Paired *t*-test.<sup>b</sup> Wilcoxon rank-sum test.\* Statistically significant at Hochberg *P* values < .05.

will, over time, regress to the mean of normal growth and development. In other words, the significant nasal soft tissue changes were immediate, and RME did not have a long-lasting impact on an adolescent's nasal soft tissue anatomy. This may be attributed to continuous growth of the nose and soft tissue elasticity. In the CG without RME (average age  $8.81 \pm 1.6$ ), a significant increase over all nasal soft and hard tissue measurements except pyriform width ( $P = .056$ ) was observed during the follow-up period, which was supported by other studies.<sup>22,23</sup> The amount of change in pyriform height and pyriform width in TG showed a significant difference compared with CG, probably attributed to the RME effect. The long term RME effect on the nasal hard tissue is supported by previous studies. Long-term maintenance of a significant increase in nasal cavity width for 12 months<sup>24</sup> and 5 years<sup>25</sup> were reported in studies and a previous systematic review.<sup>26</sup>

Immediate and long-term changes after RME in growing patients showed a significant increase in nasal cavity dimension and volume, reducing the resistance of nasal airflow.<sup>26–31</sup> In this study, the RME group showed  $3.57 \pm 1.2$  mm (immediate) and  $2.66 \pm 1.0$  mm increases of pyriform width in 2.84 years, which were consistent with other studies.<sup>32</sup> In a previous systemic review,<sup>32</sup> RME increased nasal geometry and the increase in transverse nasal measurements ranged from 2 to 4 mm. RME increased the nasal cavity volume by about 0.10% of the pre-expansion volume.<sup>19</sup> In addition, Izuka et al.<sup>33</sup> reported that RME positively impacted the quality of life of mouth-breathing patients with maxillary atresia by increasing the nasal cavity volume significantly and reducing subsequent respiratory symptoms. Interestingly, RME increased the mucociliary clearance in patients who had maxillary atresia, having positive effects on nasal physiology and increasing nasal cavity volume.<sup>14</sup> On the other hand, Langer et al.<sup>34</sup> concluded that RME did not influence nasal resistance in their long-term evaluation. Itikawa et al.<sup>35</sup> and Matsumoto et al.<sup>36</sup> examined the effects of

**Table 7.** Long-Term Comparison of Changes of the Soft and Hard Tissue Variables Between T1 and T3 (TG) and T1' and T3' (CG)

	Changes, Mean $\pm$ SD		
	CG (n = 28)	TG (n = 25)	P Value
Alar width	$1.83 \pm 1.5$	$2.17 \pm 2.0$	.7246 <sup>a</sup>
Alar base width	$1.29 \pm 1.4$	$1.95 \pm 1.8$	.7246 <sup>a</sup>
Nasal length	$0.94 \pm 0.8$	$1.40 \pm 1.1$	.7246 <sup>a</sup>
Nasal height	$2.87 \pm 2.0$	$4.39 \pm 1.9$	.0728 <sup>b</sup>
Nasion–ANS height	$2.70 \pm 1.9$	$3.89 \pm 1.7$	.2013 <sup>a</sup>
ANS–PNS length	$1.10 \pm 1.3$	$0.89 \pm 1.2$	.7246 <sup>b</sup>
Pyriform height	$1.92 \pm 1.2$	$3.37 \pm 1.1$	.0014 <sup>b*</sup>
Pyriform width	$0.30 \pm 0.5$	$2.66 \pm 1.0$	<.0001 <sup>a*</sup>

<sup>a</sup> Independent-sample *t*-test.<sup>b</sup> Wilcoxon rank-sum test.\* Statistically significant at Hochberg *P* values < .05.

RME on nasal cavity dimensions of young children and observed a significant increase in nasal transverse bony width. However, no difference in nasal volume was detected as a result of mucosal compensation. Nasal bony expansion was followed by a mucosal compensation at a 3-month follow-up study using acoustic rhinometry and rhinomanometry.<sup>37</sup> In the current study, the change of nasal mucosal tissue could not be examined precisely using CBCT. Furthermore, the wide variability of the nasal mucosa, which is influenced by several factors such as nasal cycle, body posture, age, infection, exercise, medication, and ultradian rhythm, made it very difficult to compare.<sup>38–41</sup> Therefore, the effect of RME on airway should be carefully interpreted, and RME cannot be indicated only for the improvement of nasal breathing because of the wide variability of individual responses.<sup>28</sup>

CBCT is being widely used in orthodontic field for diagnosis and treatment planning, and it is considered as one of the most reliable methods for evaluating facial soft and hard tissue changes.<sup>9,42</sup> It has several strengths including lower costs, lower radiation dose, shorter scanning time, and overall accuracy compared with conventional multislice computed tomography scans.<sup>43–46</sup> In addition, CBCT allows the simultaneous evaluation of both skeletal and related soft tissue changes. Previously, studies used several different methods to evaluate nasal soft tissue changes, including photography,<sup>5</sup> in-person clinical measurements,<sup>47</sup> three-dimensional facial scans,<sup>21</sup> and tomography,<sup>16</sup> showing the wide range of outcomes. For those reasons, CBCT was used to assess the changes in the nasal soft and hard tissue in this study.

This study had some limitations resulting from the retrospective design. There was attrition in T2 and T3. Not all treatment groups had T1, T2, and T3 records. Possible reasons for attrition were described in the Material and Methods section. In addition, the power analysis was based on soft tissue changes after RME

and not on the control group as the reference value for a control group was not found. However, the sample size was large enough to detect statistically significant findings.

## CONCLUSIONS

- The results of this study suggest that, although RME produces some significant increase on the nasal soft tissue immediately after treatment, in the long-term this gain appears to be clinically similar to that observed in untreated control patients.
- The significant increase on the nasal hard tissue immediately after RME was maintained at long-term follow-up. There was a statistically significant difference in nasal hard tissue change between TG and CG at long-term follow-up attributed to the RME effect.
- A well-controlled future prospective study is recommended to overcome the current limitations from the retrospective study design.
- This is the first study to compare the long-term effect of RME on nasal tissue with a nontreatment CG using CBCT.

## DISCLOSURE

This work was supported by the Orthodontic Faculty Development Fellowship Award from the American Association of Orthodontists Foundation (Dr Jeon).

## ACKNOWLEDGMENTS

The authors thank Dr. Diana Carvel for assistance in the measurement of the scans.

## REFERENCES

1. Haas AJ. The treatment of maxillary deficiency by opening the midpalatal suture. *Angle Orthod.* 1965;35:200–217.
2. Haas AJ. Palatal expansion: just the beginning of dentofacial orthopedics. *Am J Orthod.* 1970;57(3):219–255.
3. Haas AJ. Long-term posttreatment evaluation of rapid palatal expansion. *Angle Orthod.* 1980;50(3):189–217.
4. Lagravere MO, Major PW, Flores-Mir C. Long-term dental arch changes after rapid maxillary expansion treatment: a systematic review. *Angle Orthod.* 2005;75(2):155–161.
5. Berger JL, Pangrazio-Kulbersh V, Thomas BW, Kaczynski R. Photographic analysis of facial changes associated with maxillary expansion. *Am J Orthod Dentofacial Orthop.* 1999; 116(5):563–571.
6. Silva Filho OG, Lara TS, Ayub PV, Ohashi AS, Bertoz FA. Photographic assessment of nasal morphology following rapid maxillary expansion in children. *J Appl Oral Sci.* 2011; 19(5):535–543.
7. Johnson BM, McNamara JA, Bandeen RL, Baccetti T. Changes in soft tissue nasal widths associated with rapid maxillary expansion in prepubertal and postpubertal subjects. *Angle Orthod.* 2010;80(6):995–1001.
8. Santariello C, Nota A, Baldini A, Ballanti F, Cozza P. Analysis of rapid maxillary expansion effects on nasal soft tissues widths. *Minerva Stomatol.* 2014;63(9):307–314.
9. Kim KB AD, Araújo EA, Behrents RG. Evaluation of immediate soft tissue changes after rapid maxillary expansion. *Dental Press J Orthod.* 2012;17(5):157–164.
10. Badreddine FR, Fujita RR, Alves F, Cappellette M Jr. Rapid maxillary expansion in mouth breathers: a short-term skeletal and soft-tissue effect on the nose. *Braz J Otorhinolaryngol.* 2018;84(2):196–205.
11. Badreddine FR, Fujita RR, Cappellette M Jr. Short-term evaluation of tegumentary changes of the nose in oral breathers undergoing rapid maxillary expansion. *Braz J Otorhinolaryngol.* 2018;84(4):478–485.
12. Houston WJ. The analysis of errors in orthodontic measurements. *Am J Orthod.* 1983;83(5):382–390.
13. Baysal A, Ozturk MA, Sahan AO, Uysal T. Facial soft-tissue changes after rapid maxillary expansion analyzed with 3-dimensional stereophotogrammetry: a randomized, controlled clinical trial. *Angle Orthod.* 2016;86(6):934–942.
14. Babacan H, Doruk C, Uysal IO, Yuces S. Effects of rapid maxillary expansion on nasal mucociliary clearance. *Angle Orthod.* 2016;86(2):250–254.
15. Altindis S, Toy E, Basciftci FA. Effects of different rapid maxillary expansion appliances on facial soft tissues using three-dimensional imaging. *Angle Orthod.* 2016;86(4):590–598.
16. Torun GS. Soft tissue changes in the orofacial region after rapid maxillary expansion: a cone beam computed tomography study. *J Orofac Orthop.* 2017;78(3):193–200.
17. Haas AJ. Rapid expansion of the maxillary dental arch and nasal cavity by opening the midpalatal suture. *Angle Orthod* 1961;31(2):73–90.
18. Kilic N, Kiki A, Oktay H, Erdem A. Effects of rapid maxillary expansion on Holdaway soft tissue measurements. *Eur J Orthod.* 2008;30(3):239–243.
19. Cordasco G, Nucera R, Fastuca R, et al. Effects of orthopedic maxillary expansion on nasal cavity size in growing subjects: a low dose computer tomography clinical trial. *Int J Pediatr Otorhinolaryngol.* 2012;76(11):1547–1551.
20. Palaisa J, Ngan P, Martin C, Razmus T. Use of conventional tomography to evaluate changes in the nasal cavity with rapid palatal expansion. *Am J Orthod Dentofacial Orthop.* 2007;132(4):458–466.
21. Fastuca R, Campobasso A, Zecca PA, Caprioglio A. 3D facial soft tissue changes after rapid maxillary expansion on primary teeth: a randomized clinical trial. *Orthod Craniofac Res.* 2018;21(3):1–6.
22. Burke PH, Hughes-Lawson CA. Stereophotogrammetric study of growth and development of the nose. *Am J Orthod Dentofacial Orthop.* 1989;96(2):144–151.
23. Ferrario VF, Sforza C, Poggio CE, Schmitz JH. Three-dimensional study of growth and development of the nose. *Cleft Palate Craniofac J.* 1997;34(4):309–317.
24. Compadretti GC, Tasca I, Bonetti GA. Nasal airway measurements in children treated by rapid maxillary expansion. *Am J Rhinol.* 2006;20(4):385–393.
25. Baccetti T, Franchi L, Cameron CG, McNamara JA Jr. Treatment timing for rapid maxillary expansion. *Angle Orthod.* 2001;71(5):343–350.
26. Lagravere MO, Major PW, Flores-Mir C. Long-term skeletal changes with rapid maxillary expansion: a systematic review. *Angle Orthod.* 2005;75(6):1046–1052.

27. Lagravere MO, Heo G, Major PW, Flores-Mir C. Meta-analysis of immediate changes with rapid maxillary expansion treatment. *J Am Dent Assoc.* 2006;137(1):44–53.
28. Baratieri C, Alves M Jr, de Souza MM, de Souza Araujo MT, Maia LC. Does rapid maxillary expansion have long-term effects on airway dimensions and breathing? *Am J Orthod Dentofacial Orthop.* 2011;140(2):146–156.
29. Hershey HG, Stewart BL, Warren DW. Changes in nasal airway resistance associated with rapid maxillary expansion. *Am J Orthod.* 1976;69(3):274–284.
30. Basciftci FA, Mutlu N, Karaman AI, Malkoc S, Kucukkolbasi H. Does the timing and method of rapid maxillary expansion have an effect on the changes in nasal dimensions? *Angle Orthod.* 2002;72(2):118–123.
31. Wertz RA. Skeletal and dental changes accompanying rapid midpalatal suture opening. *Am J Orthod.* 1970;58(1):41–66.
32. Alyessary AS, Othman SA, Yap AUJ, Radzi Z, Rahman MT. Effects of non-surgical rapid maxillary expansion on nasal structures and breathing: a systematic review. *Int Orthod.* 2019;17(1):12–19.
33. Izuka EN, Feres MF, Pignatari SS. Immediate impact of rapid maxillary expansion on upper airway dimensions and on the quality of life of mouth breathers. *Dental Press J Orthod.* 2015;20(3):43–49.
34. Langer MR, Itikawa CE, Valera FC, Matsumoto MA, Anselmo-Lima WT. Does rapid maxillary expansion increase nasopharyngeal space and improve nasal airway resistance? *Int J Pediatr Otorhinolaryngol.* 2011;75(1):122–125.
35. Itikawa CE, Valera FC, Matsumoto MAN, Lima WTA. Effect of rapid maxillary expansion on the dimension of the nasal cavity and on facial morphology assessed by acoustic rhinometry and rhinomanometry. *Dental Press J Orthod.* 2012;17(4):129–133.
36. Matsumoto MA, Itikawa CE, Valera FC, Faria G, Anselmo-Lima WT. Long-term effects of rapid maxillary expansion on nasal area and nasal airway resistance. *Am J Rhinol Allergy.* 2010;24(2):161–165.
37. Enoki C, Valera FC, Lessa FC, Elias AM, Matsumoto MA, Anselmo-Lima WT. Effect of rapid maxillary expansion on the dimension of the nasal cavity and on nasal air resistance. *Int J Pediatr Otorhinolaryngol.* 2006;70(7):1225–1230.
38. Bazargani F, Magnuson A, Ludwig B. Effects on nasal airflow and resistance using two different RME appliances: a randomized controlled trial. *Eur J Orthod.* 2018;40(3):281–284.
39. Kahana-Zweig R, Geva-Sagiv M, Weissbrod A, Secundo L, Soroker N, Sobel N. Measuring and characterizing the human nasal cycle. *PLoS One.* 2016;11(10):e0162918.
40. Hasegawa M, Kern EB. The human nasal cycle. *Mayo Clin Proc.* 1977;52(1):28–34.
41. Gungor A, Moinuddin R, Nelson RH, Corey JP. Detection of the nasal cycle with acoustic rhinometry: techniques and applications. *Otolaryngol Head Neck Surg.* 1999;120(2):238–247.
42. Lee KC, Perrino M. Alar width changes due to surgically-assisted rapid palatal expansion: a meta-analysis. *J Orthod Sci.* 2017;6(4):115–122.
43. Palomo JM, Rao PS, Hans MG. Influence of CBCT exposure conditions on radiation dose. *Oral Surg Oral Med Oral Pathol Oral Radiol Endod.* 2008;105(6):773–782.
44. El H, Palomo JM. Measuring the airway in 3 dimensions: a reliability and accuracy study. *Am J Orthod Dentofacial Orthop.* 2010;137(4 suppl):S50 e51–e59; discussion S50–S52.
45. Kwong JC, Palomo JM, Landers MA, Figueroa A, Hans MG. Image quality produced by different cone-beam computed tomography settings. *Am J Orthod Dentofacial Orthop.* 2008;133(2):317–327.
46. Osorio F, Perilla M, Doyle DJ, Palomo JM. Cone beam computed tomography: an innovative tool for airway assessment. *Anesth Analg.* 2008;106(6):1803–1807.
47. de Assis DS, Duarte MA, Goncalves ES. Clinical evaluation of the alar base width of patients submitted to surgically assisted maxillary expansion. *Oral Maxillofac Surg.* 2010;14(3):149–154.