

Changes in the condylar head after orthognathic surgery in Class III patients: a retrospective three-dimensional study

Betul Nazli Gulcek^a; Elvan Onem Ozbilen^b; Sibel Biren^c

ABSTRACT

Objectives: To evaluate the axial and dimensional changes of the condylar head after orthognathic surgery, including Le Fort I and bilateral sagittal split ramus osteotomies, and to assess condylar remodeling through three-dimensional (3D) surface superimposition.

Materials and Methods: Twenty-four patients (15 females, 9 males; mean age: 32.22 ± 6.92 years) with skeletal Class III deformity were included in the study. Cone-beam computed tomography data obtained in the preoperative (T0) and postoperative (T1) periods were examined using Mimics and 3-Matic software. The height, depth, and width of the condylar head and its angular changes were measured. The volumes of the 3D reconstructed models were calculated, and remodeling amounts were evaluated through regional surface superimposition. Statistical significance was set at $P < .05$.

Results: Following the surgery, there was a significant decrease in the size of condyles ($P < .05$). An inward rotation of the condyles was found in the axial plane (T0: $79.60 \pm 6.01^\circ$, T1: $76.6 \pm 6.48^\circ$, $P < .05$). The maximum resorption, maximum apposition, mean remodeling, and mean absolute remodeling were -2.63 ± 1.23 mm, 1.15 ± 0.4 mm, -0.30 ± 0.34 mm, and 0.73 ± 0.43 mm, respectively. No correlation was found between the angular changes and remodeling parameters or linear and volumetric changes of the condylar head ($P > .05$).

Conclusions: Condyles undergo a remodeling process with a resorptive character following orthognathic surgery, without clinically significant effects in the present study. (*Angle Orthod.* 0000;00:000–000.)

KEY WORDS: Condylar head; Cone-beam computed tomography; Orthognathic surgery; Remodeling; Superimposition

INTRODUCTION

Orthognathic surgery provides an improvement in facial esthetics, airway, and temporomandibular joint (TMJ) functions as well as correction of dental and skeletal malocclusions. The effect of orthognathic surgery on the TMJ has been discussed extensively. One of the main concerns is that the resorption/

remodeling process seen in mandibular condyles after orthognathic surgery can affect postoperative stability and compromise results.

Among orthognathic surgery procedures, bilateral sagittal split ramus osteotomy (BSSRO) is one of the most common, and it has many advantages, such as increased contact between the bony segments, rigid fixation, and rapid recovery of oral functions.¹ However, rigid fixation may cause major changes in the condylar position and condylar axis as well as create temporomandibular disorders.² Several studies^{3,4} have elucidated the changes in the position of the condyles after mandibular setback surgery and its effects on TMJ morphology. These positional and accompanying morphological changes did not seem to cause TMJ dysfunction because the changes, such as condylar remodeling, glenoid fossa remodeling, and repositioning of the condyles in the fossa, occurred within the limits of the natural adaptation mechanism that alleviated the incidence of TMJ dysfunction.^{5,6} Howev-

^a Private Practice, Kartal, Istanbul, Turkey.

^b Assistant Professor, Department of Orthodontics, Faculty of Dentistry, Marmara University, Istanbul, Turkey.

^c Professor, Department of Orthodontics, Faculty of Dentistry, Istanbul Kent University, Istanbul, Turkey.

Corresponding author: Dr Elvan Onem Ozbilen, Marmara Universitesi Basibuyuk Saglik Yerleskesi, Dis Hekimligi Fakultesi, Ortodonti Anabilim Dalı, 9/34854 Maltepe, Istanbul, Turkey (e-mail: elvanonem89@gmail.com)

Accepted: October 2022. Submitted: May 2022.

Published Online: November 21, 2022

© 0000 by The EH Angle Education and Research Foundation, Inc.

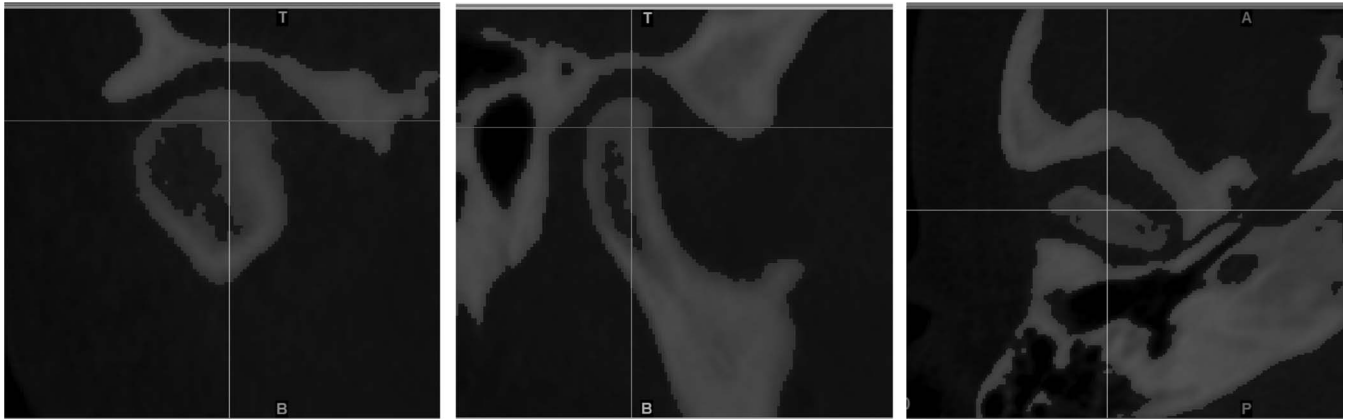


Figure 1. Manual editing.

er, only a few studies⁶⁻⁸ have examined physiological condylar head remodeling after orthognathic surgery and found predominance of bone resorption in patients with skeletal Class III deformity using cone-beam computed tomography (CBCT) data.

Cranial base superimposition on CBCT images has been used frequently to evaluate the effects of orthognathic surgery on the TMJ. However, with this superimposition technique, only the positional changes of the mandibular condyles can be evaluated, and condylar remodeling cannot be assessed.^{9,10} Instead, the regional superimposition technique is preferred to evaluate condylar remodeling, as it eliminates the deviations caused by possible displacement.^{11,12}

The purpose of the present study was to evaluate the possible axial and dimensional changes of the condylar head with angular, linear, and volumetric measurements in patients with skeletal Class III malocclusion treated with double-jaw orthognathic surgery. In addition, the type and amount of remodeling of the condyles were investigated by regional surface superimposition of three-dimensional (3D) reconstructed models.

MATERIALS AND METHODS

Study Design and Sample

The present retrospective study was approved by the Ethical Committee of Marmara University, Faculty of Dentistry (07.08.2020, 2020/54, Istanbul, Turkey). The sample size was calculated using G*Power 3.1.9.2 software (Heinrich-Heine-University, Düsseldorf, Germany).⁶ The analysis indicated that a minimum of 20 patients was required (± 0.3 deviations, 95% confidence level, 80% power).

The material of the study consisted of records of 24 individuals (15 females, 9 males; mean age: 32.22 ± 6.92 years) selected from the archives of Marmara University, Department of Orthodontics. The inclusion

criteria were as follows: (1) skeletal Class III patients ($N\perp A < -1$ mm, $SNB > 80^\circ$, Wits appraisal < -1 mm), (2) normal vertical growth pattern (inner angles: $396 \pm 3^\circ$), (3) BSSRO + Le Fort I, and (4) presence of preoperative (T0: immediately before surgery) and postoperative (T1: 4 months after the surgery on average) CBCT images. The exclusion criteria were (1) severe jaw asymmetry, (2) congenital anomaly, genetic syndrome, and (3) history of trauma or pathology in the maxillofacial region. According to the anamnesis forms, patients did not report any temporomandibular disorder symptoms before surgery, and no problem was encountered in the TMJ during the surgery.

Data Collection, Management, and Analyses

CBCT images were taken using an Iluma Imtec Imaging Machine (3M, Ardmore, Pa). The Digital Imaging and Communications in Medicine (DICOM) data were transferred to Mimics v.23.0 software (Materialize, Leuven, Belgium). First, a head mask was created with a threshold value for bony structures (minimum 226, maximum 3071 Hounsfield units). Then the mandibular condylar area was separated from the cranial base by the manual editing tool in axial, sagittal, and coronal sections (Figure 1). Definitions of the anatomical landmarks and measurements are shown in the Supplementary Table and Figures 2a–c and 3a–c.¹³ In order not to be affected by possible positional changes after the operation, linear measurements were evaluated by measuring direct distances.

In order to determine the amount and type of remodeling in the mandibular condyles, initially the postoperative ramus area was cut from the upper part of the BSSRO incision line with a plane parallel to the Frankfort horizontal plane (FHP). The cut right and left postoperative condyles were approximated to the preoperative condyles by marking the coronoid and

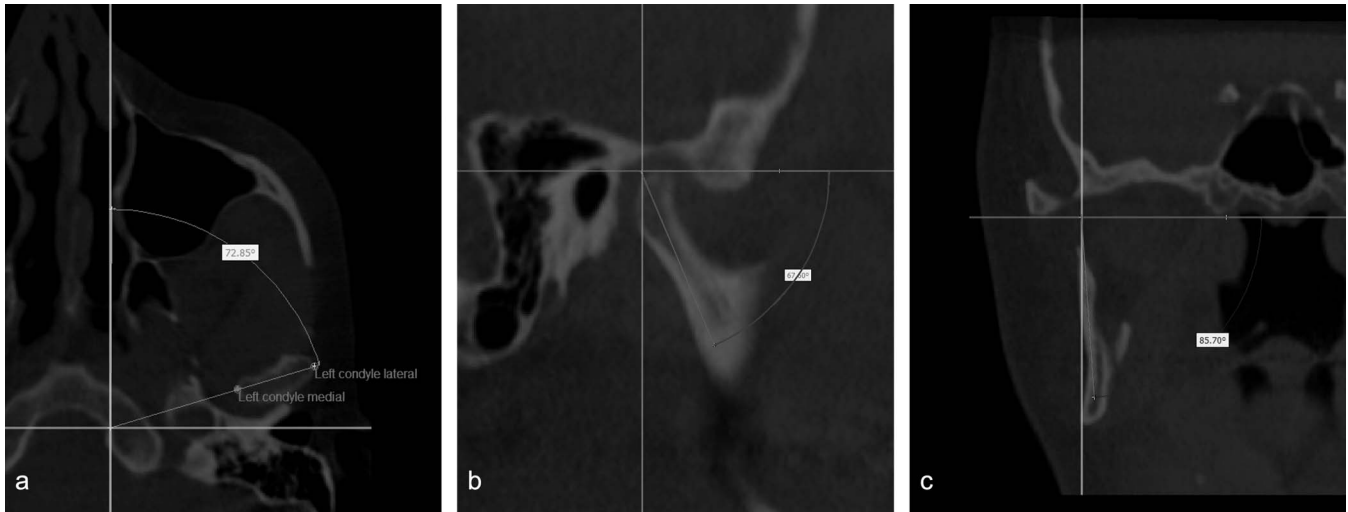


Figure 2. (a) Axial, (b) sagittal, and (c) coronal condylar angles.

inferior sigmoid notch points. The approximated images were transferred to 3-Matic software (Materialize), and the final surface superimposition was made using the best-fit algorithm (Figure 4a,b).

Following superimposition, a new plane passing through the inferior sigmoid notch point and parallel to the FHP was created. The condylar area above that plane was separated, and preoperative and postoperative condyles were segmented and compared using the “part comparison” tool in the software for each condyle separately. 3D deviation analyses were performed. After “part comparison,” the software

created a histogram and color map (Figure 5). In the histogram, the maximum apposition, maximum resorption, mean remodeling, and mean absolute remodeling (root mean square; RMS) values were given as remodeling parameters (Supplementary Table).

In addition, the maxillary advancement and mandibular setback amounts were measured as the horizontal displacement of A and B points according to a posterior reference plane parallel to the true vertical line passing through the Sella point. All measurements were repeated after 14 days by the same examiner (BNG).

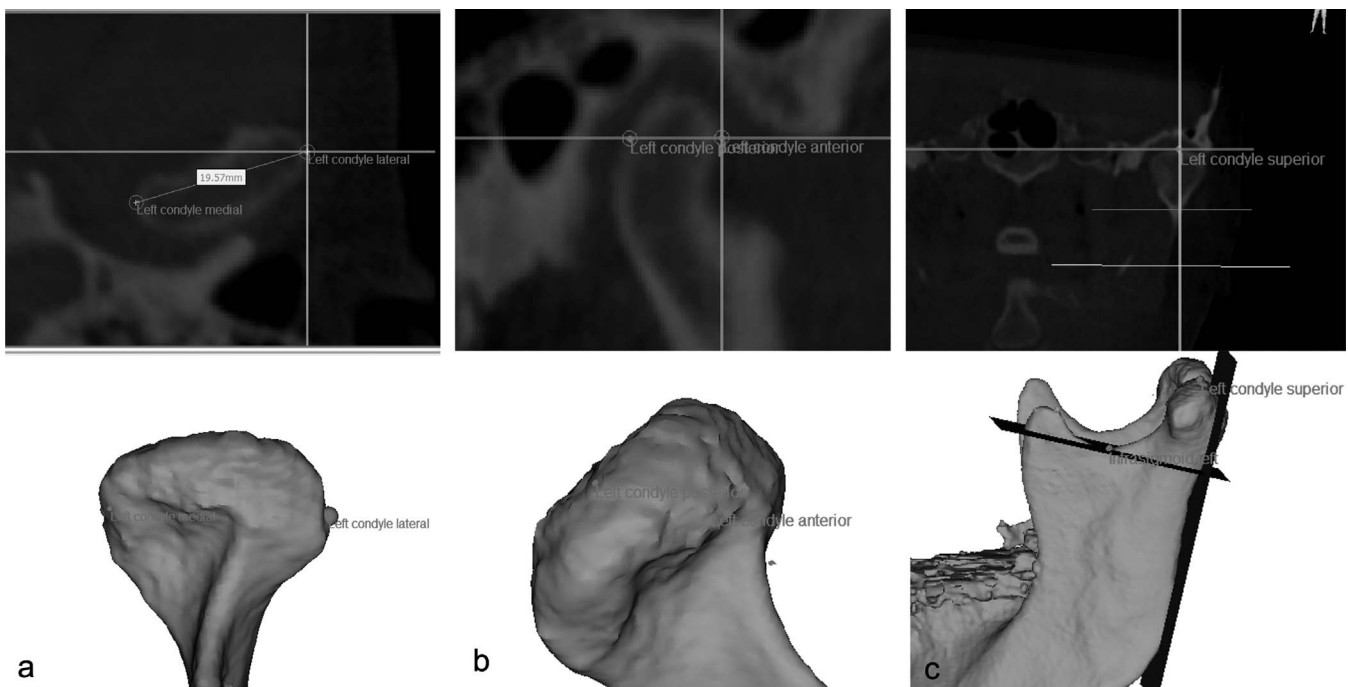


Figure 3. (a) Condylar width. (b) Condylar depth. (c) Condylar height.

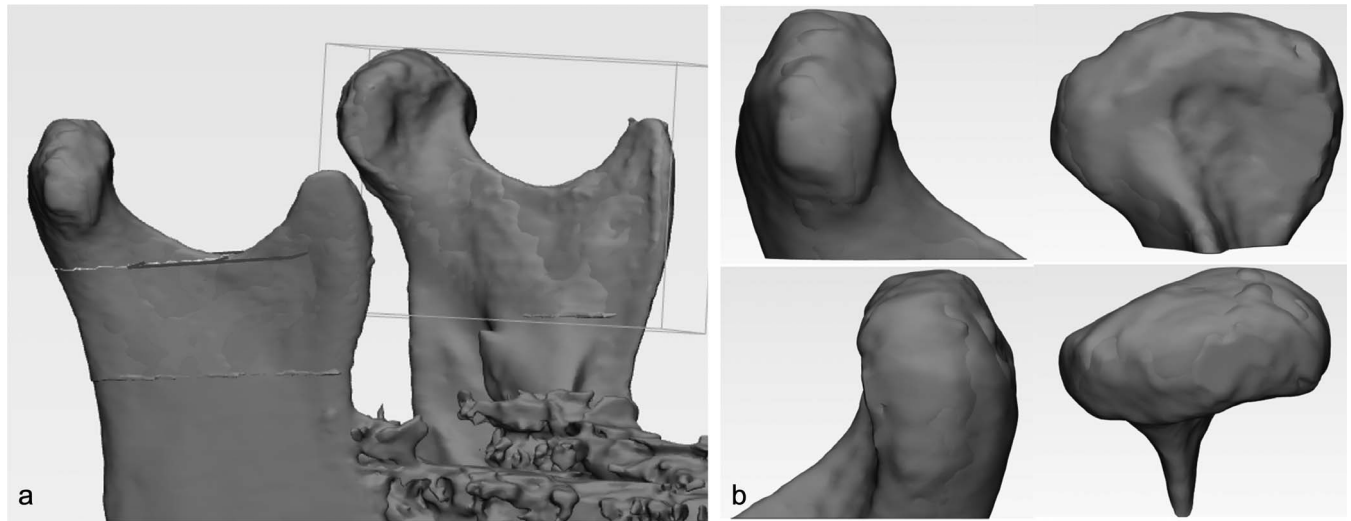


Figure 4. (a) Superimposed and (b) segmented condyles.

Statistical Analysis

Statistical analysis was performed using the Number Cruncher Statistical System (NCSS) 2007 Statistical Software package program (NCSS, Kaysville, Utah). Conformity of the parameters to the normal distribution was examined with the Shapiro-Wilk test. The paired samples *t*-test was used for the comparison of variables with a normal distribution before and after the surgery, and the Pearson correlation test was used

to determine relationships among the variables. Statistical significance was set at $P < .05$.

RESULTS

The demographic variables, duration between pre-operative and postoperative CBCT images, and descriptive statistics for the initial skeletal values of the patients are shown in Table 1. The mean maxillary advancement and mandibular setback amounts were 4.08 ± 2.04 mm and 4.76 ± 2.04 mm, respectively

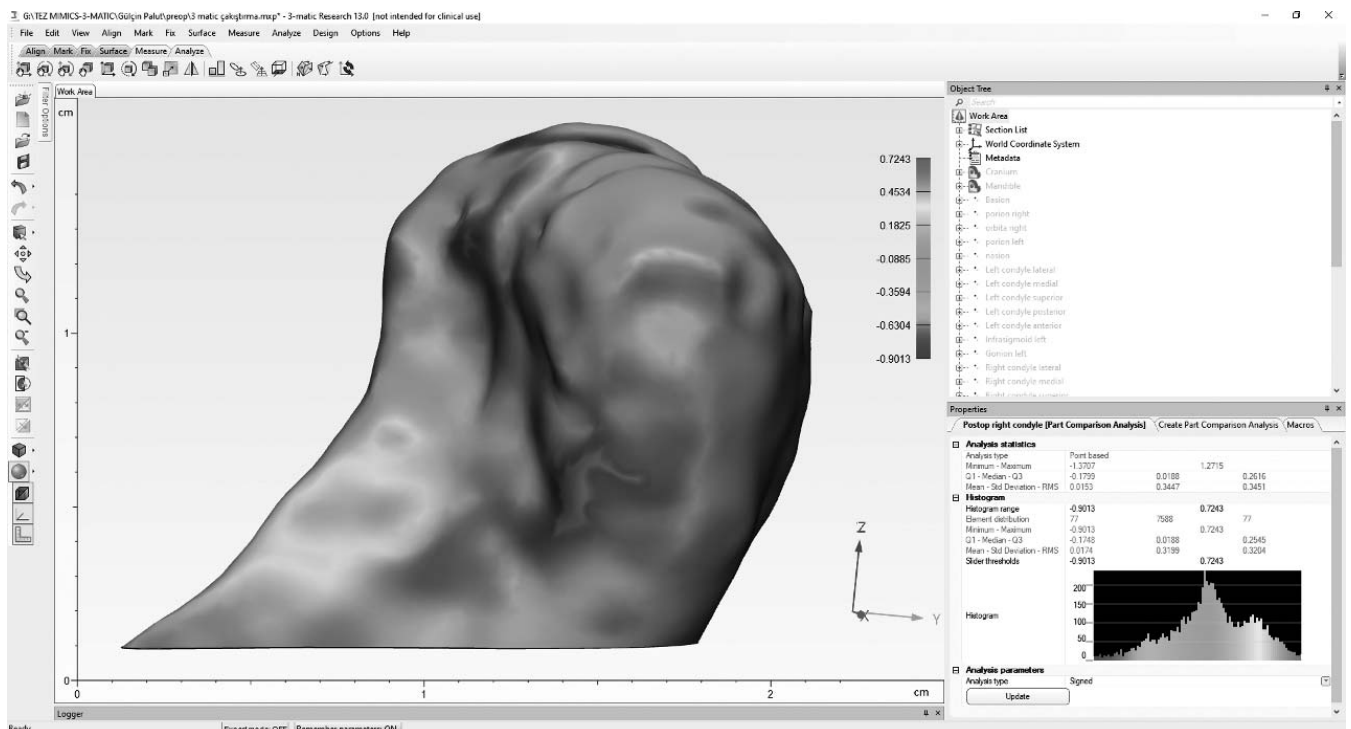


Figure 5. Color map and histogram data.

Table 1. Descriptive Statistics for the Study Group^a

	N
Gender	9 (37.50%) Male 15 (62.50%) Female
	Mean ± SD
Age (Years)	32.22 ± 6.92
Preoperative skeletal values	
SNA (°)	79.2 ± 4.38
SNB (°)	82 ± 4.89
Wits (mm)	-10.53 ± 3.92
N ₁ A (mm)	-4.35 ± 3.29
Inner angles (°)	394.92 ± 7.13
GoMeSN (°)	37.75 ± 6.47
T0-T1 (months)	4.74 ± 1.25
Surgical movements (mm)	
Maxillary advancement	4.08 ± 2.04 (maximum: 8.92; minimum: 1.03)
Mandibular setback	4.76 ± 2.04 (maximum: 8.42; minimum: 1.00)

^a T0 indicates preoperative period; T1, postoperative period; and SD, standard deviation.

(Table 1). The intraclass correlation coefficients of all parameters ranged from 0.993 to 0.999, showing a high level of agreement.

Evaluation of Angular, Linear, and Volumetric Measurements

No statistically significant differences were observed in the measurements between the right and left condyles. This allowed for the unification of both condylar measurements; next, a single value was used for each patient.

The only statistically significant change for angular measurements was seen in the “axial condylar angle,” which was decreased after surgery (T0: 79.60 ± 6.01°; T1: 76.60 ± 6.48°, $P < .001$). No statistically significant differences were observed in the “sagittal and coronal condylar angles” between T0 and T1 ($P > .05$) (Table 2).

After orthognathic surgery, “condylar height,” “condylar depth,” and “condylar width” decreased significantly ($P < .05$ and $P < .001$; Table 2). The condylar volume also showed a statistically significant decrease

after surgery (T1: 1577.71 ± 578.78 mm³) compared to the preoperative value (T0: 1753.82 ± 571.99 mm³, $P < .001$) (Table 2).

Remodeling Parameters

Descriptive data of remodeling parameters before and after orthognathic surgery are shown in Table 3. The maximum resorption, maximum apposition, mean remodeling, and RMS were -2.63 ± 1.23 mm, 1.15 ± 0.4 mm, -0.30 ± 0.34 mm, and 0.73 ± 0.43 mm, respectively.

Correlation Analyses

When the correlation between the condylar angular changes and remodeling parameters was evaluated, no significant correlation was found ($P > .05$) (Table 4). Additionally, no statistically significant correlation was found between the condylar angular changes and linear and volumetric changes of the condylar head ($P > .05$) (Table 4).

DISCUSSION

Positional changes in the condyles caused by orthognathic surgery create physical pressure on the condylar surface, and as a result, condylar remodeling occurs as an adaptation to the new functional requirements.¹⁴ Post-operative instability is usually the result of pre-existing, unrecognized and untreated TMJ pathology or conditions due to orthognathic surgery, such as joint damage after excessive, invasive surgery or overloading of the TMJ.¹⁵ Even without these conditions, severe condylar changes and deterioration in skeletal stability can be observed, the cause of which is still mostly unknown.¹⁶ There are still very few studies that analyze postoperative condylar remodeling using 3D reconstruction and condylar superimposition technique in skeletal Class III patients.⁶⁻⁸ For this reason, in the present study, we aimed to evaluate the dimensional changes of the condylar head and the type and amount of remodeling of the condyles by regional surface superimposition.

Table 2. Evaluation of the Angular, Linear, and Volumetric Changes of the Condylar Head After Orthognathic Surgery^a

	T0, Mean ± SD	T1, Mean ± SD	P
Axial condylar angle, °	79.60 ± 6.01	76.60 ± 6.48	.0001***
Sagittal condylar angle, °	77.21 ± 4.58	77.54 ± 4.56	.589
Coronal condylar angle, °	83.96 ± 2.76	84.21 ± 3.36	.494
Condylar height, mm	19.74 ± 3.04	19.51 ± 3.06	.048*
Condylar depth, mm	7.34 ± 1.04	6.99 ± 1.13	.0001***
Condylar width, mm	19.67 ± 2.59	19.12 ± 2.75	.0001***
Condylar volume, mm ³	1753.82 ± 571.99	1577.71 ± 578.78	.0001***

^a T0 indicates preoperative period; T1, postoperative period; and SD, standard deviation.

* $P < .05$; *** $P < .001$; paired-samples *t*-test.

Table 3. Descriptive Data of the Remodeling Parameters of the Condyles^a

Parameter	Minimum	Maximum	Average	SD
Maximum resorption	-4.76	-0.68	-2.63	1.23
Maximum apposition	0.39	2.44	1.15	0.41
Mean remodeling	-1.05	0.14	-0.30	0.34
Mean absolute remodeling (RMS)	0.24	1.66	0.73	0.43

^a SD indicates standard deviation; RMS, root mean square.

The axial condylar angle showed a significant decrease after surgery, on average, 3° in the present study. Ha et al.,⁶ Park et al.,⁸ and Kim et al.¹⁷ reported decreases of 5.74°, 6.16°, and 5.04°, respectively, in the right axial condylar angle and decreases of 5.33°, 5.22°, and 5.84°, respectively, in the left axial condylar angle after Class III orthognathic surgery. In other studies,^{8,18-20} inward rotation of the condyles in the axial plane was reported after BSSRO. Similarly, a significant decrease in the axial condylar angle caused inward rotation of the condyles in the present study.

No statistically significant difference was observed in the sagittal condylar angle in the present study, as was the case in some previous studies.^{6,8,17,19,21} However, Ueki et al.¹⁸ and Hsu et al.²⁰ reported a decrease in the sagittal condylar angle after surgery, which means that the condyles rotated backward in the sagittal plane. In contrast, Kim et al.²² stated that the condyles rotated forward after the surgery. When the coronal condylar angles were evaluated, no significant change was found, as was the case in the studies of Kim et al.^{17,21} However, Podčernina et al.¹⁹ found a significant increase, which had resulted in a mesial bend of the condyles. The differences in the findings have been attributed to differences in the methods used for positioning of the condyles, the type of internal fixation, the direction and amount of surgical movement, and the interaction of many other factors.

According to the present study, an average 0.23-mm decrease in the height, 0.35-mm decrease in the depth, and 0.55-mm decrease in the width of the condyles were observed. In the studies of Ha et al.⁶ and Park et al.,⁸ although a significant decrease had been found in condylar height in the sagittal and coronal planes (as was the case in the current study), no significant change in depth and width of the condyle in the axial plane was reported. Additionally, Park et al.⁸ found the linear changes of the condylar head in the range of 0.5 mm and reported that these changes had no adverse effect on the structure of the condylar head. However, linear measurements at the condylar head in those studies^{6,8} were measured separately in x, y, and z coordinates. The displacement of the proximal segment after the operation may affect these linear

Table 4. Correlations Between the Condylar Angular Changes and the Remodeling Parameters and Condylar Head Changes^a

	Axial Condylar Angle T0-T1 Difference	Sagittal Condylar Angle T0-T1 Difference	Coronal Condylar Angle T0-T1 Difference
Remodeling parameters			
Maximum resorption			
<i>r</i>	.071	.010	.09
<i>P</i>	.631	.948	.543
Maximum apposition			
<i>r</i>	.011	.037	-.055
<i>P</i>	.942	.805	.711
Mean remodeling			
<i>r</i>	.071	.021	.039
<i>P</i>	.631	.887	.790
Mean absolute remodeling (RMS)			
<i>r</i>	-.057	.088	-.053
<i>P</i>	.703	.553	.719
Condylar head changes			
Condylar height T0-T1 difference			
<i>r</i>	.037	-.092	-.202
<i>P</i>	.803	.536	.168
Condylar depth T0-T1 difference			
<i>r</i>	-.272	-.019	.159
<i>P</i>	.061	.900	.281
Condylar width T0-T1 difference			
<i>r</i>	-.279	-.217	-.104
<i>P</i>	.055	.138	.482
Condylar volume T0-T1 difference			
<i>r</i>	.054	-.098	-.073
<i>P</i>	.718	.509	.620

^a T0 indicates preoperative period; T1, postoperative period; and RMS, root mean square; *r* indicates Pearson correlation coefficient.

measurements made in different coordinates. For this reason, in the present study the direct distance was measured between the anatomical landmarks so that the effect of possible changes of the proximal segment on linear measurements was prevented.

Because the mandibular condyles adapt to the changing functional stimuli after orthognathic surgery, the changes in condylar volume may change postoperative stability. Xi et al.²³ reported that the loss of more than 17% of the condylar volume was a sign of pathological condylar resorption. In the present study, the mean condylar volume in the postoperative period was found to be approximately 176 mm³ lower than in the preoperative period, which constituted approximately 10% of the total volume. Podčernina et al.¹⁹ also reported a 5.3% reduction in condylar volume in a 1-year follow up after double-jaw surgery.

In the current study, the maximum amount of resorption was -2.63 ± 1.23 mm, and the maximum amount of apposition was 1.15 ± 0.41 mm, on average. The mean amount of remodeling showed a resorption value of -0.3 ± 0.34 mm, while RMS was 0.73 ± 0.43 mm. Although a predominance of bone resorption was observed in the present study, bone

apposition was also found in the condyles, which is supported by previous findings.^{6-8,24} Condylar axis rotation, changed mechanical loading, and rigid fixation might affect the condylar head and create different bone resorption and apposition areas as a result of its trabecular pattern and mineralization.^{3,4,6,8,18}

Correlation analysis was also performed between the condylar angular changes and remodeling parameters, which showed no significant relationship. In addition, no significant correlation was observed between the axial condylar angle change and changes in the linear and volumetric measurements of the condyles. On the contrary, previous studies^{7,8} suggested that the inward rotation of the condyle seen in the axial plane following mandibular setback surgery may be an important factor that induces remodeling. An et al.⁷ reported a positive correlation between the inward rotation of the condyles and RMS after the surgery, which meant that as the inward rotation of the condyles in the axial plane increased, the amount of condylar remodeling increased, independent of the apposition and resorption pattern. The change in the long axis of the condyle was related to remodeling caused by pressure loading in the condyle and glenoid fossa. Different results among previous studies and the present study may be attributed to the fact that the amount of change in the axial condylar angle was slightly less in the current study compared to the other studies.^{6,18}

Individual adaptation capacity is associated with many factors, which may create resorptive changes as a result.²⁵ Although many patients can adapt to occlusion and condylar positions that are not considered ideal, the physiological adaptation range should be investigated further in orthognathic surgery patients because surgery changes the stomatognathic environment.

In the present study, more than one surgeon performed the surgeries, which is a confounder for the study in terms of possible different techniques in condyle stabilization. Judgement of the natural physiological condylar position by the surgeon plays a crucial role in postoperative TMJ stability, and positioning the condyles in the glenoid fossa has been hypothesized^{8,20} to lead to remodeling; however, none of the previous studies evaluated the effect of different positioning techniques on condylar remodeling. Another limitation of this study was that the patients in the present study had normal vertical growth patterns, and there were no significant changes in vertical facial height, which might also affect the condylar response. Future studies with different extents of sagittal and vertical skeletal movements should be completed to assess the impact of these variables on the condyles.

CONCLUSIONS

- In the present study, following orthognathic surgery, the axial condylar angle decreased, resulting in inward rotation of the condyles.
- A remodeling process with a resorptive pattern was found in the condyles after orthognathic surgery, according to the 3D deviation analyses, supporting a decrease in condylar height, depth, width, and volume.
- No correlation was found between the condylar angular changes and remodeling parameters or with the linear and volumetric changes of the condylar head.
- However, in the present study no clinically significant effects were noted as a result of the resorptive pattern in the condyles following surgery.

SUPPLEMENTAL DATA

Supplementary Table 1 is available online.

REFERENCES

1. Wolford LM. The sagittal split ramus osteotomy as the preferred treatment for mandibular prognathism. *J Oral Maxillofac Surg.* 2000;58:310–312.
2. Timmis DP, Aragon SB, Van Sickels JE. Masticatory dysfunction with rigid and nonrigid osteosynthesis of sagittal split osteotomies. *Oral Surg Oral Med Oral Pathol.* 1986;62:119–123.
3. Hoppenreijts TJ, Freihofer HP, Stoelinga PJ, Tuinzing DB, van't Hof MA. Condylar remodelling and resorption after Le Fort I and bimaxillary osteotomies in patients with anterior open bite: a clinical and radiological study aesthetic and reconstructive surgery. *Int J Oral Maxillofac Surg.* 1998;27:81–91.
4. Papachristou DJ, Papachroni KK, Papavassiliou GA, et al. Functional alterations in mechanical loading of condylar cartilage induces changes in the bony subcondylar region. *Arch Oral Biol.* 2009;54:1035–1045.
5. Voudouris JC, Woodside DG, Altuna G, et al. Condyle-fossa modifications and muscle interactions during Herbst treatment, Part 2. Results and conclusions. *Am J Orthod Dentofacial Orthop.* 2003;124:13–29.
6. Ha M-H, Kim Y-I, Park S-B, Kim S-S, Son W-S. Cone-beam computed tomographic evaluation of the condylar remodeling occurring after mandibular set-back by bilateral sagittal split ramus osteotomy and rigid fixation. *Korean J Orthod.* 2013;43:263–270.
7. An S-B, Park S-B, Kim Y-I, Son W-S. Effect of post-orthognathic surgery condylar axis changes on condylar morphology as determined by 3-dimensional surface reconstruction. *Angle Orthod.* 2014;84:316–321.
8. Park S-B, Yang Y-M, Kim Y-I, Cho B-H, Jung Y-H, Hwang D-S. Effect of bimaxillary surgery on adaptive condylar head remodeling: metric analysis and image interpretation using cone-beam computed tomography volume superimposition. *J Oral Maxillofac Surg.* 2012;70:1951–1959.
9. Cevidanes LHS, Bailey LJ, Tucker GR Jr, et al. Superimposition of 3D cone-beam CT models of orthognathic surgery patients. *Dentomaxillofac Radiol.* 2005;34:369–375.

10. de Oliveira Ruellas AC, Tonello C, Gomes LR, et al. Common 3-dimensional coordinate system for assessment of directional changes. *Am J Orthod Dentofacial Orthop.* 2016;149:645–656.
11. Koerich L, Burns D, Weissheimer A, Claus JDP. Three-dimensional maxillary and mandibular regional superimposition using cone beam computed tomography: a validation study. *Int J Oral Maxillofac Surg.* 2016;45:662–669.
12. Schilling J, Gomes LCR, Benavides E, et al. Regional 3D superimposition to assess temporomandibular joint condylar morphology. *Dentomaxillofac Radiol.* 2014;43:20130273.
13. Hilgers ML, Scarfe WC, Scheetz JP, Farman AG. Accuracy of linear temporomandibular joint measurements with cone beam computed tomography and digital cephalometric radiography. *Am J Orthod Dentofacial Orthop.* 2005;128:803–811.
14. Bouletreau P, Frey R, Breton P, Freidel M. Focus on the effect of orthognathic surgery on condylar remodeling. *Rev Stomatol Chir Maxillofac.* 2004;105:283–288.
15. Wolford LM, Cardenas L. Idiopathic condylar resorption: diagnosis, treatment protocol, and outcomes. *Am J Orthod Dentofacial Orthop.* 1999;116:667–677.
16. De Clercq CA, Neyt LF, Mommaerts MY, Abeloos JV, De Mot BM. Condylar resorption in orthognathic surgery: a retrospective study. *Int J Adult Orthod Orthognath Surg.* 1994;9:233–240.
17. Kim Y-I, Jung Y-H, Cho B-H, et al. The assessment of the short-and long-term changes in the condylar position following sagittal split ramus osteotomy (SSRO) with rigid fixation. *J Oral Rehabil.* 2010;37:262–270.
18. Ueki K, Marukawa K, Nakagawa K, Yamamoto E. Condylar and temporomandibular joint disc positions after mandibular osteotomy for prognathism. *J Oral Maxillofac Surg.* 2002;60:1424–1432.
19. Podčernina J, Urtāne I, Pirttiniemi P, Šalms Ģ, Radziņš O, Aleksejūnienė J. Evaluation of condylar positional, structural, and volumetric status in Class III orthognathic surgery patients. *Medicina (Kaunas).* 2020;56:672.
20. Hsu L-F, Liu Y-J, Kok S-H, et al. Differences of condylar changes after orthognathic surgery among Class II and Class III patients. *J Formos Med Assoc.* 2022;121:98–107.
21. Kim Y-I, Cho B-H, Jung Y-H, Son W-S, Park S-B. Cone-beam computerized tomography evaluation of condylar changes and stability following two-jaw surgery: Le Fort I osteotomy and mandibular setback surgery with rigid fixation. *Oral Surg Oral Med Oral Pathol Oral Radiol Endod.* 2011;111:681–687.
22. Kim Y-J, Oh K-M, Hong J-S, et al. Do patients treated with bimaxillary surgery have more stable condylar positions than those who have undergone single-jaw surgery? *J Oral Maxillofac Surg.* 2012;70:2143–2152.
23. Xi T, Schreurs R, van Loon B, et al. 3D analysis of condylar remodelling and skeletal relapse following bilateral sagittal split advancement osteotomies. *J Craniomaxillofac Surg.* 2015;43:462–468.
24. Vandeput AS, Verhelst PJ, Jacobs R, Shaheen E, Swennen G, Politis C. Condylar changes after orthognathic surgery for Class III dentofacial deformity: a systematic review. *Int J Oral Maxillofac Surg.* 2019;48:193–202.
25. Papadaki ME, Tayebaty F, Kaban LB, Troulis MJ. Condylar resorption. *Oral Maxillofac Surg Clin North Am.* 2007;19:223–234.