

Analysis of lingual en masse retraction combining a C-lingual retractor and a palatal plate

Jun-Shik Kim^a; Seong-Hun Kim^b; Yoon-Ah Kook^c; Kyu-Rhim Chung^d; Gerald Nelson^e

ABSTRACT

Objectives: To analyze the results of employing en masse retraction of the maxillary anterior dentition using palatal temporary skeletal anchorage devices (TSADs) as the exclusive source of anchorage.

Materials and Methods: A retrospective clinical investigation supported by preliminary case reports was performed comparing pretreatment cephalometric radiographs with those taken after en masse retraction of the six anterior teeth. The sample consisted of 35 nongrowing patients with an average age of 22.9 years. The average retraction period was 10 months (range, 6–15 months). No brackets or bands were placed on the posterior dentition during retraction. A total of 35 C-palatal plates (C-plates) were used as the only source of anchorage for maxillary anterior retraction with the C-lingual retractor (C-retractor), thereby eliminating the need for bonded or banded anchor teeth. The cephalometric radiographs were analyzed for differences between pretreatment and postretraction variables that included skeletal, dental, and soft tissue relationships.

Results: Significant incisor and canine retraction was achieved in all patients, and the upper posterior teeth did not show significant mesial drifting during the retraction period. According to the length of the lever arm of the C-retractor, tooth movement showed different directions.

Conclusions: En masse retraction of the six anterior teeth with good torque control and effective intrusion is possible using palatal TSADs as the only source of anchorage. (*Angle Orthod.* 2011;81:662–669.)

KEY WORDS: En masse retraction; Lingual orthodontics; C-lingual retractor; C-palatal plate; Biocreative therapy; Skeletal anchorage

INTRODUCTION

Adult orthodontics is an increasing part of esthetic dentistry. In these cases, clinicians often prefer to minimize treatment time with fixed appliances due to

the stress on the periodontal support system.^{1–3} Segmental orthodontics can be a good choice for this,^{4,5} and biocreative therapy for anterior retraction offers a further advantage since fixed posterior appliances are not necessary.^{6–15}

^a Postgraduate student, Department of Orthodontics, College of Dentistry, Kyung Hee University, Seoul, Korea.

^b Associate Professor, Department of Orthodontics, College of Dentistry, Kyung Hee University, Seoul, Korea.

^c Professor and Chairman, Division of Orthodontics, The Catholic University of Korea, Seoul, Korea.

^d Private practice, Seoul, Korea.

^e Clinical Professor, Department of Orofacial Science, Division of Orthodontics, The University of California San Francisco, San Francisco, Calif.

Corresponding author: Seong-Hun Kim, DMD, MSD, PhD, Department of Orthodontics, College of Dentistry, Kyung Hee University, #1 Hoegi-dong, Dongdaemun-gu, Seoul 130-701, Republic of Korea (e-mail: bravortho@hanmail.net and bravortho@khu.ac.kr)

Accepted: December 2010. Submitted: October 2010.

Published Online: March 14, 2011

© 2011 by The EH Angle Education and Research Foundation, Inc.

Orthodontists often choose to remove premolars to retract crowded or protrusive anterior teeth. Location and management of the center of resistance with respect to retraction force vectors (Cres) is critical.^{16–18} A recent study reported the Cres of six anteriors to be located 13.5 mm posteriorly and 9 mm superiorly from the center of the lingual archwire, similar to the estimate of Melsen et al.¹⁷ Using this, the clinician can estimate the length of a power arm that would provide controlled lingual crown tipping, root tipping, or bodily movement of the anterior segment.¹⁸

When using a mini-implant or mini-plate to enhance anchorage, it has been reported that in a full fixed appliance, the anterior teeth retract but the posterior teeth show unwanted distal movement due to friction in the archwire/bracket interface.^{19–21} Biocreative therapy was developed to enable retraction without involving

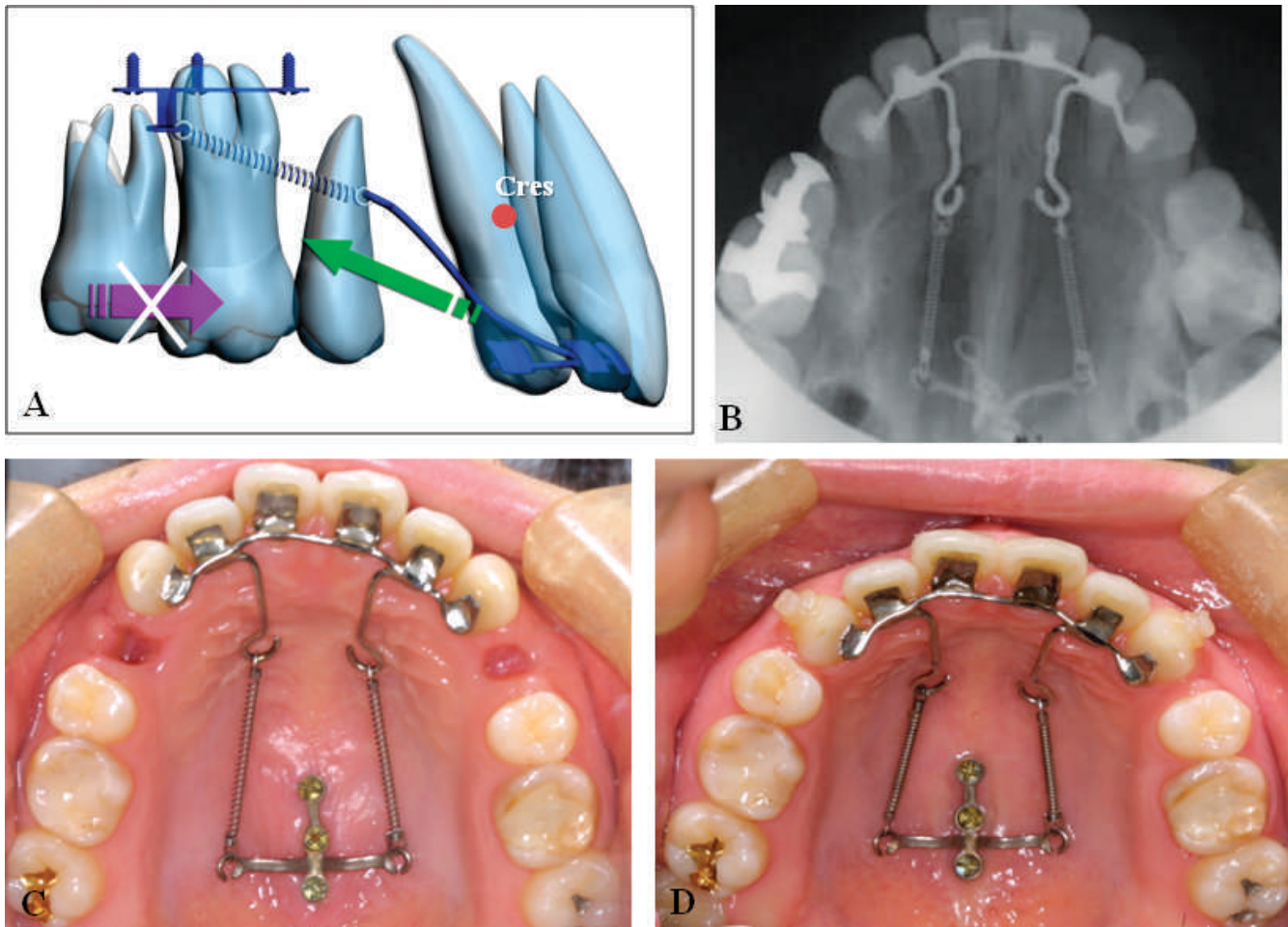


Figure 1. (A) Schematic illustration of lingual biocreative therapy. (B) Occlusal view of C-lingual retractor and C-palatal plate combined en masse retraction. (C, D) Intraoral photographs immediately after force application and after anterior retraction.

the posterior segments and thus avoid such side effects.⁶⁻¹⁴ The C-implant supports some osseointegration and accomplishes controlled anterior retraction with a <1 mm change in the posterior unbracketed segments. Normal home care is possible for these patients since the posterior teeth are free of appliances.⁹

Biocreative therapy can be used to simplify conventional orthodontic biomechanics, to discourage unnecessary use of complex orthodontic devices, and to facilitate orthodontic tooth movement by using orthodontic/orthopedic force against skeletal anchorage. Sometimes biocreative therapy can be employed to maximally utilize a perisegmental corticotomy and/or osteotomy under local anesthesia to overcome severe skeletal discrepancies.

When faced with at least two years of orthodontic treatment, many patients will delay or avoid starting because of concern about the appearance of labial brackets. Such concerns brought the development of lingual orthodontics and invisible orthodontics. How-

ever, torque control is not easy with traditional lingual orthodontics.²² The C-lingual retractor and C-palatal plate is ideal for patients who have lip protrusion and need maximum anchorage (Figure 1).^{13,14} The C-lingual retractor is bonded to the lingual surfaces of the upper six anteriors, providing excellent esthetics.^{23,24} The C-palatal plate is fixed near the median palatal suture with mini-implants and removes the need for upper posterior orthodontic appliances as anchorage for 3-dimensional retraction of the upper anteriors. This system, called lingual biocreative therapy, provides patients with esthetic treatment, rapid and controlled retraction without deepening the overbite, and reasonable comfort with no required compliance. Posterior teeth are not disturbed by friction in the appliance.^{13,14}

The aim of the present study was to analyze the treatment effects of lingual biocreative therapy, anchorage preservation, and axial inclination of the anterior segment when employing the C-lingual retractor.

Table 1. Demographic Distribution of the Subjects^a

No.	Sex	Age	Malocclusion	Extraction	Retraction Period, mo	Finishing Method	Treatment Period, mo
1	M	25 y 3 mo	I	#14, 24, 34, 44	10	FA	15
2	F	22 y 5 mo	II	#14, 24, 34, 44	15	TP	16
3	F	16 y	II	#14, 24, 34, 44	19	TP	21
4	F	22 y 1 mo	I	#14, 24, 34, 44	8	FA	13
5	F	30 y	II	#14, 24, 34, 44	12	FA	23
6	F	23 y 4 mo	I	#14, 24, 34, 44	11	FA	22
7	F	25 y 1 mo	I	#14, 24, 34, 44	7	FA	20
8	F	19 y 11 mo	I	#14, 24, 34, 44	6	FA	18
9	F	24 y 1 mo	I	#14, 24, 34, 44	10	FA	23
10	F	23 y 10 mo	II	#14, 24, 34, 44	12	FA	20
11	F	20 y 1 mo	I	#14, 24, 34, 44	11	FA	28
12	F	24 y	I	#14, 24, 34, 44	8	FA	27
13	F	26 y	I	#14, 24, 34, 44	9	FA	21
14	F	25 y 4 mo	II	#14, 24, 35, 45	11	FA	29
15	F	22 y 1 mo	I	#14, 24, 35, 45	7	FA	19
16	F	23 y 5 mo	I	#14, 24, 34, 44	8	FA	21
17	F	24 y 10 mo	II	#14, 24, 35, 45	12	FA	20
18	F	23 y 4 mo	II	#14, 24, 35, 45	7	FA	21
19	F	18 y 4 mo	I	#14, 24, 34, 44	7	FA	22
20	F	25 y 4 mo	I	#14, 24, 34, 44	7	FA	20
21	F	19 y 7 mo	II	#14, 24, 34, 44	11	FA	24
22	F	24 y 10 mo	I	#14, 24, 34, 44	8	FA	19
23	F	17 y 9 mo	II	#14, 24, 35, 45	12	FA	28
24	F	23 y 10 mo	I	#14, 24, 34, 44	13	FA	27
25	F	22 y 9 mo	I	#14, 24, 34, 44	9	FA	22
26	F	24 y 6 mo	II	#14, 24, 34, 44	13	FA	24
27	F	26 y	I	#14, 24, 34, 44	6	FA	22
28	F	24 y 9 mo	I	#14, 24, 34, 44	12	TP	14
29	F	23 y	I	#14, 24, 34, 44	12	FA	16
30	M	22 y 4 mo	I	#14, 24, 34, 44	14	FA	21
31	F	24 y 1 mo	II	#14, 24, 34, 44	11	FA	17
32	F	25 y 3 mo	I	#14, 24, 34, 44	9	FA	15
33	F	19 y 11 mo	II	#14, 24, 34, 44	9	FA	16
34	M	16 y	II	#14, 24, 34, 44	8	FA	18
35	M	23 y 7 mo	I	#14, 24, 34, 44	7	FA	19

^a F indicates female; M, male; TP, tooth positioner; FA, fixed orthodontic appliance.

MATERIALS AND METHODS

Retrospective data were obtained from pretreatment and postretraction lateral cephalograms of 35 patients who met the following criteria: (1) nongrowing patients with no to mild anterior crowding, (2) treatment planning included upper first premolar and lower premolar extractions, (3) the C-plate was the sole source of anchorage and all anterior teeth were bonded as a unit to the C-retractor, and (4) no appliances were placed in the upper posterior dentition during the retraction phase of treatment. This preliminary report and associated data were reviewed by the Institutional Review Board at the St Mary's Hospital of The Catholic University of Korea.

The subjects' ages at start of treatment, the duration of active treatment, and the number of subjects are shown in Table 1. The sample consisted of 31 females and 4 males. The mean age of the subjects at the start of the treatment was 22.9 years (range, 16 years to 25 years 4 months). Twenty-two subjects had cepha-

lometric values that indicated a Class I bimaxillary dentoalveolar protrusion, while 13 subjects had a Class II skeletal pattern. Thirty subjects had both the first premolar extractions, and five subjects had upper first premolar and lower second premolar extraction. All patients were treated by two clinicians at a single location.

Lingual Biocreative Therapy Using a C-Retractor and C-Plate

Treatment was initiated with the placement of an upper C-retractor and a C-plate in the maxilla and leveling the lower anterior dentition. The C-retractor is made of a 0.036-inch stainless-steel wire soldered to mesh brackets that consolidate the anterior segment into a single unit to which forces were directly applied from the C-plate (Gebrüder Martin GmbH & Co KG, Tuttlingen, Germany; Jin-Biomed Co, Bucheon, Korea). The C-retractor was fabricated on a cast of the patient while estimating the location of Cres. The

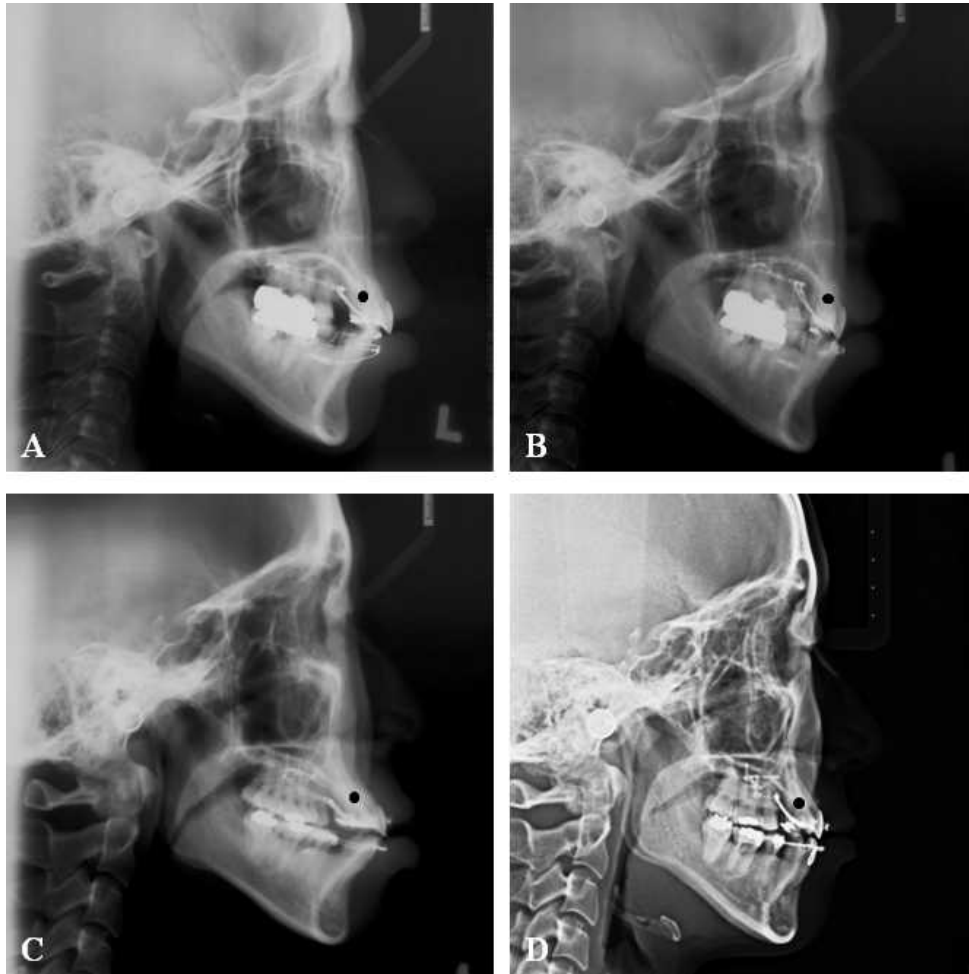


Figure 2. Treatment progress lateral cephalograms. (A, B) Group 1 patients (SN-U1 $<105^\circ$) needed more bodily teeth movement than controlled tipping movement, so a longer lever arm of C-retractor was recommended (about 10 mm vertically from the FA-point on the lingual surface of the upper six anteriors). (C, D) Group 2 with severe anterior protrusion (SN-U1 $>105^\circ$) needed controlled lingual tipping, so a shorter lever arm was recommended. The lever arm of the retractor was located between the upper central incisor and lateral incisor.

fabrication and clinical application of the C-retractor and the surgical procedure for C-plate placement have been explained in previous reports.^{13,14} After extraction of the upper first premolars and lower premolars, the C-plate and C-retractor were connected with Ni-Ti springs, producing a force of 200 g per side (total 400 g).

We determined the best vertical length of the retractor arm by considering the angle of SN-U1 (Figure 2). Group 1 of 14 patients (SN-U1 $<105^\circ$)²⁵ needed more bodily teeth movement than controlled tipping movement, so a long lever arm of the C-retractor (about 10 mm vertically from the FA point on the lingual surface of the upper six anteriors) was applied. Group 2 with severe anterior protrusion (SN-U1 $>105^\circ$) needed controlled lingual tipping, so a shorter lever arm (about 7 mm) was recommended. The lever arm of the retractor was located between the upper central and lateral incisors.

Patients visited the clinic every six to eight weeks during the anterior retraction period. The retraction of the lower anterior dentition was accomplished by conventional methods. During the retraction period, no intermaxillary elastics were applied. For 32 patients and after the en masse retraction period, 0.022×0.028 -inch fixed orthodontic appliances were bonded to the upper teeth for finishing details. Three patients used tooth positioners for final settling. At the end of active treatment, the C-plate was removed. Minor inflammation present under the device healed rapidly.

Cephalometric headfilms were analyzed. Soft tissue, skeletal, and dental measurements have been explained in previous studies. The cephalometric measurements we used are shown in Figures 3 and 4.

Statistical Analysis

The means and standard deviations for the 19 variables were calculated. Pretreatment to postretrac-

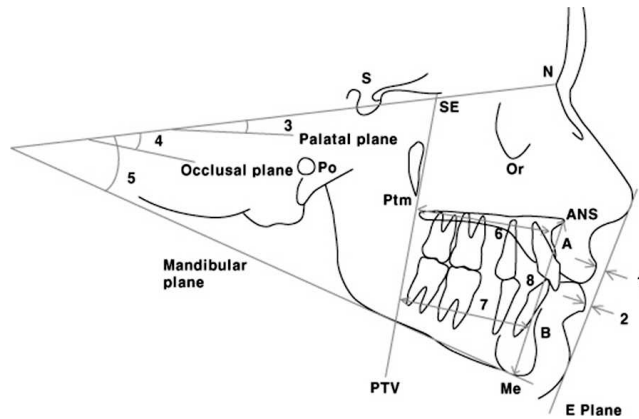


Figure 3. Soft tissue and skeletal cephalometric analysis. 1: upper lip to E-line; 2: lower lip to E-line; 3: SN to palatal plane angle (SN-PP); 4: SN-anatomic occlusal plane angle (SN-Occ); 5: SN to mandibular plane angle (SN-Mn); 6: pterygoid vertical plane to A point distance (PTV-A); 7: pterygoid vertical plane to B point distance (PTV-B); 8: lower anterior face height (LAFH; ANS-Me).

tion changes for each variable were analyzed with paired *t*-tests. A *t*-test was also used to evaluate the treatment difference between group 1 and group 2. To evaluate tracing and measurement errors, the experimental procedures of the records of 15 patients (30 sets of cephalograms) were repeated three weeks later. Results of the Pearson correlation coefficient, used to compare the second measurement to the first for each variable, showed greater than 0.97 at the 95% confidence interval.

RESULTS

The mean retraction period was 10 months (range, 6–15 months). The mean treatment period was 20.6 months (range, 13–29 months). The mean, range, and significance of changes in the soft tissue, skeletal, and dental measurements between pretreatment and postretraction are listed in Tables 2 and 3.

A statistically significant difference was found between pretreatment and postretraction measurements in the anterior dentition (Table 2). Sella-nasion to the upper incisor axis (SN-U1) and the lower incisor axis to the mandibular plane angle (MP-L1) decreased significantly as a result of en masse retraction (SN-U1; $106.19^\circ \rightarrow 95.85^\circ$, MP-L1; $96.89^\circ \rightarrow 86.41^\circ$, $P < .001$). Soft tissue changes were also significant. The upper lip and lower lip to E line moved posteriorly, respectively (upper lip to E line; $3.46 \text{ mm} \rightarrow 0.72 \text{ mm}$, lower lip to E line; $6.35 \rightarrow 2.77 \text{ mm}$). The maxillary molars did not show any statistically significant movement. Point A decreased significantly after anterior retraction (PTV-A; $51.85 \text{ mm} \rightarrow 49.55 \text{ mm}$). The mandibular lingual cortex to mandibular first molar centroid distance (Lc-L6) presented a statistically significant decrease. We divided patients into two groups by criteria of the angle

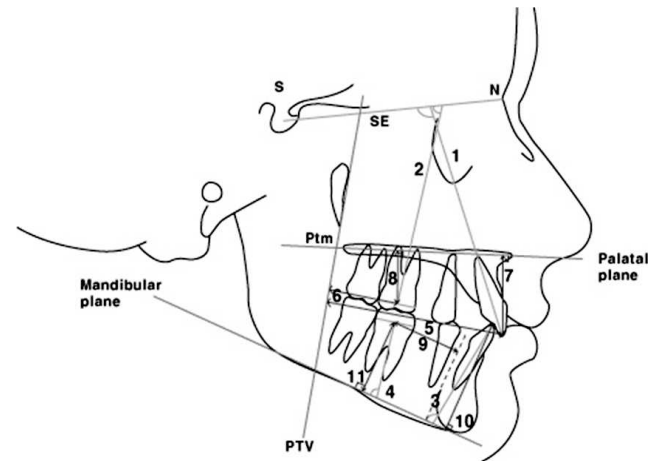


Figure 4. Dental cephalometric analysis: angular and linear measurements. 1: SN to maxillary incisor angle (SN-U1); 2: SN to maxillary first molar angle (SN-U6); 3: mandibular plane to mandibular incisor angle (MP-L1); 4: mandibular plane to mandibular first molar angle (MP-L6); 5: pterygoid vertical plane to maxillary incisor tip distance (PTV-U1); 6: pterygoid vertical plane to maxillary first molar centroid distance (PTV-U6); 7: palatal plane to maxillary incisor tip distance (PP-U1); 8: palatal plane to maxillary first molar centroid distance (PP-U6); 9: mandibular lingual cortex to mandibular first molar centroid distance (LC-L6); 10: mandibular plane to mandibular incisor tip distance (MP-L1); 11: mandibular plane to mandibular first molar centroid distance (MP-L6).

of SN-U1, with 105° as the dividing line. Controlled tipping was evident in the group 2 ($>105^\circ$ group; SN-U1 change; $-12.0^\circ \pm 5.2^\circ$ (group 2) and $-7.8^\circ \pm 5.5^\circ$ (group 1), PTV-U1; $-7.7^\circ \pm 3.2^\circ$ (group 2) and $-5.3^\circ \pm 2.2^\circ$ (group 1; Table 3).

DISCUSSION

Controlling torque in the anterior segment during retraction has always been of interest to orthodontists.^{15,17,26} The biocreative therapy concept has been applied with labial appliances and, in this study, with lingual appliances. Analysis of the center of resistance is the key to designing successful retraction biomechanics. In the labial appliance version, we used conventional brackets and a retraction arch familiar to most in its design. In the lingual version, we consolidated the anterior segment into one unit and used extended arms to produce the favorable vectors and moments and contrary to conventional lingual fixed appliances.¹⁸ Of course, lingual appliances provide the esthetic advantage that would tip the scale for many patients when deciding to proceed with orthodontic treatment. During the retraction process, the lingual biocreative protocol also involves fewer doctor visits and less chair time than the labial biocreative protocol. Friction is not an issue, as it is when posterior appliances and archwires are used.

Table 2. Comparisons of Cephalometric Measurements Between Before (T1) and Postretraction (T2)

Variable	T1		T2		Significance T2-T1
	Mean	95% CI	Mean	95% CI	
Soft tissue					
Upper lip to E line	3.46	-1.2~8.0	0.72	-3.0~4.0	***
Lower lip to E line	6.35	0.0~12.9	2.77	-2.5~10.5	***
Skeletal					
SN-PP	11.03	5.2~17.8	10.8	5.0~17.0	
SN-Occ	22.17	9.5~36.0	22.06	9.0~36.5	
SN-Mn	42.91	33.0~54.0	42.91	33.0~55.2	
PTV-A	51.85	40.0~61.0	49.55	41.0~58.0	***
PTV-B	46.36	32.0~57.5	45.81	33.0~57.8	
ANS-Me	76.09	66~91	75.72	67~87	
Dental angular					
SN-U1	106.19	88.7~118	95.85	79.0~110.8	***
SN-U6	68.58	45.5~82.1	69.67	53.0~81.5	***
MP-L1	96.89	82.7~111.0	86.41	66~111	***
MP-L6	78.48	56.2~90.2	77.13	64.5~97.0	
Dental linear					
PTV-U1	61.62	47.5~71.0	54.79	43.5~66.5	***
PTV-U6	23.47	12~31	23.73	12.5~31.5	
PP-U1	32.72	24~39	31.54	25.5~36.7	**
PP-U6	21.07	10~28	21.08	13.0~25.5	
Lc-L6	20.36	10.5~25	19.33	11.5~25	**
MP-L1	46.81	40~58	45.0	39~51	***
MP-L6	31.31	26~37	31.25	24~37.5	

* $P < .05$; ** $P < .01$; *** $P < .001$.

In this research, the amount of lip retraction during treatment was statistically significant, due to changes in the dimensions of PTV-A, PTV-U1, and the angle of SN-U1. It could be confirmed that the upper anteriors were intruded during retraction by measuring PP-U1.

In the two groups set according to the axis angle of the upper incisor, the $<105^\circ$ group (group 1) had a decrease in the SN-U1 angle of 7.8° , while the $>105^\circ$ group (group 2) showed a decrease of 12.1° . These data confirm that the biomechanics result in expected control of the torque of U1 during retraction. In these lingual biocreative therapy patients, the average decrease of the SN-U1 angle was from 106.19° to 95.85° . Retraction with labial biocreative¹⁰ tended to leave the upper incisors a bit more upright at the end of retraction than the lingual biocreative therapy. In the report by Park et al.,²⁷ the angle of SN-U1 decreased from 112.7° to 104.7° , nicely within the normal range of SN-U1. In the study by Hong et al.,¹⁸ which attempted bodily retraction, the angle of FH-U1 decreased from 114.0° to 109.2° , or by 4.8° . When the goal was controlled tipping, they achieved a decrease in FH-U1 from 123.6° to 111.4° , or 12.2° . These data were similar to our data.

When we investigated labial biocreative therapy, the linear distance PP-U1 increased from 32.5 mm to 33.2 mm, or 0.7 mm. In this study with lingual biocreative therapy, the distance PP-U1 decreased by 1.5 mm. This change confirms that the upper

anteriors were intruded during retraction. In other words, the lingual C-retractor may offer a solution to bite deepening by developing a favorable moment due to a gap between Cres and vectors of retraction force.

During retraction of the upper anteriors, group 2 ($>105^\circ$) showed significantly more controlled tipping than group 1 did. In a previous study of labial biocreative therapy, the angle of SN-U1 decreased by 15.7° , which was similar to that of group 2 ($-12.0^\circ \pm 5.2^\circ$). Group 1 decreased by only $-7.8^\circ \pm 5.5^\circ$, indicating less tipping.

The soft tissue contours were retracted effectively in both groups. There were no differences between both groups in PTV-A, MP-L1, PP-U1, Lc-L6, and MP-L1. This informed us that differences in the angle of SN-U1 had no effect on the retraction of anteriors or the movement of posteriors. The upper posteriors showed no changes in group 2 (SN-U6) and 2.4° mesial tipping in group 1. In group 2, change in the dimension PP-U6 indicated 0.4 mm of distal drift, while group 1 experienced 0.7 mm of mesial drift. We speculate that in G1, the possibility of mesial drift of the upper posteriors was higher because the closure of the extraction space took longer than in group 2 due to less protrusive upper anteriors. This phenomenon can be explained by a mild counterclockwise rotation of the mandible in G1 and the mild clockwise rotation in G2. In our labial biocreative therapy, we used a retraction

Table 3. Comparisons of Differences Between Pretreatment and Postretraction Cephalometric Measurements in SN to U1 <105° Group (Group 1) and SN to U1 >105° Group (Group 2)^a

Variable	Group 1		Group 2		Significance
	Mean	SD	Mean	SD	
Soft tissue					
Upper lip to E line	-2.4	1.1	-2.9	1.3	
Lower lip to E line	-2.9	1.2	-3.9	1.4	
Skeletal					
SN-PP	-0.2	1.5	-0.2	1.8	
SN-Occ	-0.6	2.6	0.2	3.1	
SN-Mn	-0.8	1.5	0.5	1.3	*
PTV-A	-1.1	1.3	-3.0	3.5	
PTV-B	-0.1	1.9	-0.8	2.3	
ANS-Me	0.2	1.5	-0.8	3.7	
Dental angular					
SN-U1	-7.8	5.5	-12.0	5.2	*
SN-U6	2.4	2.9	0.1	3.3	*
MP-L1	-8.1	8.1	-12.0	6.8	
MP-L6	-2.8	6.5	-0.3	7.0	
Dental linear					
PTV-U1	-5.3	2.2	-7.7	3.2	*
PTV-U6	0.8	1.6	-0.1	1.6	
PP-U1	-1.1	1.7	-1.1	2.2	
PP-U6	0.7	1.1	-0.4	1.7	*
Lc-L6	-1.1	1.0	-0.9	2.0	
MP-L1	-1.7	2.1	-1.8	2.7	
MP-L6	0.8	1.0	-0.6	1.8	*

^a Group 1, pretreatment SN-U1 <105°; group 2, pretreatment SN-U1 >105°.

* $P < .05$.

archwire directly into a hole in the implant head and placed a gable bend to apply torque and intrusion during retraction. The incisor was extruded 0.6 mm when retracted. With lingual biocreative therapy, the incisor intruded 1.5 mm because of a better biomechanical relationship between Cres, the location of force-application point, and the vector of force. This is an advantage for patients with a deep bite. The torque of lower central incisors (MP-L1) decreased from 96.89° to 86.41°, which is more upright than the average range (90° ± 2°).

The vertical position of lower central incisors (MP-L1) decreased from 46.81 mm to 45.0 mm (by 1.81 mm), indicating lower incisor intrusion, which was likely assisted by occlusal forces since the lower incisors functioned on the lingual surface of the bonded C-retractor.

This report of successful anterior retraction with the lingual appliances corresponds with previous case reports.¹²⁻¹⁴ In this research, two orthodontists treated 35 premolar extraction patients with forces applied to the C-retractor from the C-plate, anchored by three miniscrews. Considering the magnification and operator error in analysis of cephalograms, we look forward to more accurate studies using models and cone beam computed tomography (CBCT). Our study provides

encouragement for further study of treatment and doctor time required for the complete retraction phase, any changes in periodontal status, and a more accurate way to locate the true center of resistance for retraction of the upper anterior segment.

CONCLUSION

- The analysis confirmed that the system (lingual biocreative therapy) produced excellent and efficient retraction with good control of torque and desired intrusion of the anterior segment, and there was no significant effect on the upper posterior buccal dentition, which had no attachments whatsoever during the retraction.

ACKNOWLEDGMENT

This study is based in part on a research thesis completed at The Catholic University of Korea and was supported by a grant from Kyung Hee University.

REFERENCES

1. Boyd RL, Baumrind S. Periodontal considerations in the use of bonds or bands on molars in adolescents and adults. *Angle Orthod.* 1992;62:117-126.

2. Alexander SA. Levels of root resorption associated with continuous arch and sectional arch mechanics. *Am J Orthod Dentofacial Orthop.* 1996;110:321–324.
3. Melsen B. Biological reaction of alveolar bone to orthodontic tooth movement. *Angle Orthod.* 1999;69:151–158.
4. Burstone CJ. Rationale of the segmented arch. *Am J Orthod.* 1962;48:805–822.
5. Burstone CJ. The segmented arch approach to space closure. *Am J Orthod.* 1982;82:361–378.
6. Chung KR, Cho JH, Kim SH, Kook YA, Cozzani M. Unusual extraction treatment in Class II division 1 malocclusion. *Angle Orthod.* 2007;77:155–166.
7. Chung KR, Kim SH, Kook YA, Sohn JH. Anterior torque control using partial-osseointegrated mini-implants: biocreative therapy type I technique. *World J Orthod.* 2008;9:95–104.
8. Chung KR, Kim SH, Kook YA, Choo HR. Anterior torque control using partial osseointegration based mini-implants: biocreative therapy type II technique. *World J Orthod.* 2008;9:105–113.
9. Kim SH, Hwang YS, Ferreira A, Chung KR. Analysis of temporary skeletal anchorage devices used for en-masse retraction: a preliminary study. *Am J Orthod Dentofacial Orthop.* 2009;136:268–276.
10. Mo SS, Kim SH, Sung SJ, Chung KR, Chun YS, Kook YA, Nelson G. The factors controlling anterior torque during temporary skeletal anchorage devices dependent en masse retraction without posterior appliances: biocreative therapy type I technique. *Am J Orthod Dentofacial Orthop.* In press.
11. Mo SS, Kim SH, Sung SJ, Chung KR, Chun YS, Kook YA, Nelson G. The factors controlling anterior torque during C-implant-dependent en masse retraction without posterior appliances: biocreative therapy type II technique. *Am J Orthod Dentofacial Orthop.* In press.
12. Kim SH, Lee KB, Chung KR, Nelson G, Kim TW. Severe bimaxillary protrusion with adult periodontitis treated by corticotomy and compression osteogenesis. *Korean J Orthod.* 2009;39:54–64.
13. Chung KR, Kook YA, Kim SH, Mo SS, Jung JA. Class II malocclusion treated by combining a lingual retractor and a palatal plate. *Am J Orthod Dentofacial Orthop.* 2008;133:112–123.
14. Chung KR, Jeong DM, Park HJ, Kim SH, Nelson G. Severe bidentoalveolar protrusion patient treated with lingual biocreative therapy using palatal miniplate. *Korean J Orthod.* 2010;40:276–287.
15. Sung SJ, Kim IT, Kook YA, Chun YS, Kim SH, Mo SS. Finite-element analysis of the shift in center of resistance of the maxillary dentition in relation to alveolar bone loss. *Korean J Orthod.* 2009;39:278–288.
16. Chung GM, Sung SJ, Lee KJ, Chun YS, Mo SS. Finite-element investigation of the center of resistance of the maxillary dentition. *Korean J Orthod.* 2009;39:83–94.
17. Melsen B, Fotis V, Burstone CJ. Vertical force considerations in differential space closure. *J Clin Orthod.* 1990;24:678–683.
18. Hong RK, Heo JM, Ha YK. Lever-arm and mini-implant system for anterior torque control during retraction in lingual orthodontic treatment. *Angle Orthod.* 2005;75:129–141.
19. Park HS, Kwon TG. Sliding mechanics with microscrew implant anchorage. *Angle Orthod.* 2004;74:703–710.
20. Park HS, Yoon DY, Park CS, Jeoung SH. Treatment effects and anchorage potential of sliding mechanics with titanium screws compared with the Tweed-Merrifield technique. *Am J Orthod Dentofacial Orthop.* 2008;133:593–600.
21. Upadhyay M, Yadav S, Nagaraj K, Nanda R. Dentoskeletal and soft tissue effects of mini-implants in Class II division 1 patients. *Angle Orthod.* 2009;79:240–247.
22. Liang W, Rong Q, Lin J, Xu B. Torque control of the maxillary incisors in lingual and labial orthodontics: a 3-dimensional finite element analysis. *Am J Orthod Dentofacial Orthop.* 2009;135:316–322.
23. Kim SH, Park YG, Chung KR. Severe Class II anterior deep bite malocclusion treated with a C-lingual retractor. *Angle Orthod.* 2004;74:280–285.
24. Kim SH, Park YG, Chung KR. Severe anterior open bite malocclusion with multiple odontoma treated by C-lingual retractor and horseshoe mechanics. *Angle Orthod.* 2003;73:206–212.
25. Park HS, Lee SK, Kwon OW. Group distal movement of teeth using microscrew implant anchorage. *Angle Orthod.* 2005;75:602–609.
26. Isaacson RJ, Lindauer SJ, Rubenstein LK. Moments with the edgewise appliance: incisor torque control. *Am J Orthod Dentofacial Orthop.* 1993;103:428–438.
27. Park YC, Choi YJ, Choi NC, Lee JS. Esthetic segmental retraction of maxillary anterior teeth with a palatal appliance and orthodontic mini-implants. *Am J Orthod Dentofacial Orthop.* 2007;131:537–544.