

Influence of Surface Characteristics on Survival Rates of Mini-Implants

Karim Chaddad^a; André F.H. Ferreira^b; Nico Geurs^c; Michael S. Reddy^d

ABSTRACT

Objective: To compare the clinical performance and the survival rate of two mini-implant systems with different surface characteristics under immediate orthodontic loading.

Materials and Methods: Seventeen machined titanium (MT) mini-implants and 15 sandblasted, large grit, acid-etched (SLA) mini-implants were placed in 10 patients. The mini-implants were immediately loaded and the patients seen at 7, 14, 30, 60, and 150 days. Clinical parameters such as anatomical location, character of the soft tissue at the screw head emergence, type of mini-implant system, diameter, and length were analyzed. In addition, the insertion torque recorded at the time of insertion was also assessed. Survival rate and clinical parameters were evaluated by the chi-square exact tests using the SAS version 9.1.

Results: The overall survival rate was 87.5%. Over the four failing mini-implants, three were MT and one SLA resulting in an individual survival rate of 82.4% and 93.4%, respectively. In the failure group, all the fixtures had their screw emergence at the oral mucosa and recorded a torque range of less than 15 Ncm. The insertion torque statistically influenced the survival rate of the mini-implants ($P < .05$). Surface treatment, anatomical location, as well as soft tissue emergence were not statistically significant.

Conclusion: Surface characteristics did not appear to influence survival rates of immediately loaded mini-implants.

KEY WORDS: Anchorage; Mini-implants; Loading

INTRODUCTION

Anchorage control is a fundamental aspect of orthodontic biomechanics. Poor anchorage control during therapy may increase treatment time and lead to an unfavorable result.¹ Concerns with commonly used extraoral apparatus include socially unacceptable esthetics, the potential for injury, and an impractical dependence on patient compliance.² The historical success of root-form dental implants to replace missing

teeth^{3,4} supported the migration of implantology into orthodontics. Current interest in utilizing implants as osseous anchors for orthodontics may represent a valuable alternative to conventional methods.⁵

Pioneering data from Linkow,⁶ added to that of later investigators,^{7,8} have demonstrated the utility of implanted anchors in orthodontics. Moreover, the application of orthodontic forces appears to have a positive effect on peri-implant osseous tissue.^{9,10} Initially, large diameter implants were inserted into the alveolar process, the palate, and the retromolar area.¹¹⁻¹⁵ More recently, strategically placed mini-implants, requiring minimally invasive surgery appear to have overcome many of the issues associated with the larger devices. While preliminary data look promising, mini-implants have not equaled the success of root-form devices and concerns regarding design, osseointegration, post-insertion infection, and questions about optimal preload healing time remain subjects for further investigation.¹⁶⁻¹⁹

The purpose of the present study was to evaluate the survival rate and to compare clinical performance of two mini-implant systems with different surface

^a Private practice of periodontics, Austin, Tex.
^b Assistant Professor, Department of Orthodontics, School of Dentistry, University of Alabama at Birmingham, Birmingham, Ala.
^c Associate Professor, Department of Periodontics, University of Alabama at Birmingham, Birmingham, Ala.
^d Professor and Department Chair, Department of Periodontics, University of Alabama at Birmingham, Birmingham, Ala.
Corresponding author: Dr Karim Chaddad, Department of Periodontics, University of Alabama at Birmingham, 1919 7th Ave South, SDB 412, Birmingham, AL 35294 (e-mail: e-mail: kcchaddad@gmail.com)

Accepted: February 2007. Submitted: October 2006.
© 2008 by The EH Angle Education and Research Foundation, Inc.



Figure 1. Machined titanium.

characteristics under immediately applied continuous orthodontic loading.

MATERIALS AND METHODS

The performances of two screw-shaped titanium mini-implant systems were assessed in the present study. The Dual-Top (Jeil Medical Corporation, Seoul, Korea) is a machined pure titanium (MT), self tapping, threaded mini-implant available in diameters of 1.4, 1.6, and 2.0 mm and in lengths of 6.0, 8.0, and 10.0 mm. The insertion protocol recommends either a hand or a motorized screw driver (Figure 1). The C-implant (Implantium Inc, Seoul, Korea) is also a titanium mini-implant with a distinctive characteristic of having a sandblasted, large grit and acid-etched (SLA) surface treatment and a 2-mm machined polished collar. Its 1.8 mm diameter is available in lengths of 8.5, 9.5 and 10.5 mm and can only be inserted with a hand screw driver (Figure 2).

Ten healthy patients, ages 13 to 65 years, whose treatment plan included the use of temporary anchorage devices (TADs), were included in the study. Clin-



Figure 2. Sandblasted, large grit, acid-etched.

ical and radiographic data were analyzed to determine the survival rate of the two mini-implant systems. Data were captured for 32 TADs.

Prior to beginning treatment, standard orthodontic records were obtained for each patient. Treatment plans were then developed through orthodontic and periodontal collaboration. The two mini-implant systems were alternately placed until a minimum of 15 mini-implants were placed for both systems. Some patients received implants from both systems under study while other patients were treated with implants from either the MT or the SLA system.

Immediately prior to the procedure, patients rinsed with a prophylactic mouthwash (0.12% chlorhexidine). Mini-implant patients were placed under local anesthesia; no incision or mucoperiosteal flaps were required for any of the sites. A starter drill, used at 800 rpm under copious irrigation, was utilized to enter the alveolar cortex. The mini-implants were placed using the system-specific screw driver. At the final revolutions of implant placement, a torque ratchet was utilized to identify implants which required greater than 15 Ncm of torque for final seating (Figures 3 and 4). Patients were instructed to continue a twice daily regimen of chlorhexidine rinses for 1 week. Follow-up data were captured at 7, 14, 30, 60, and 150 days after loading.

Following surgical placement, the mini-implants




Figure 3. Torque ratchet.

were immediately loaded with a NiTi coil-spring or an elastic chain generating an initial force magnitude of 50 to 100 g (Figure 5). After 2 weeks of healing, the force was increased reaching a level of 250 g. The orthodontic movements accomplished included molar intrusion, molar uprighting, retraction of protruded anterior teeth, and protraction of posterior teeth.

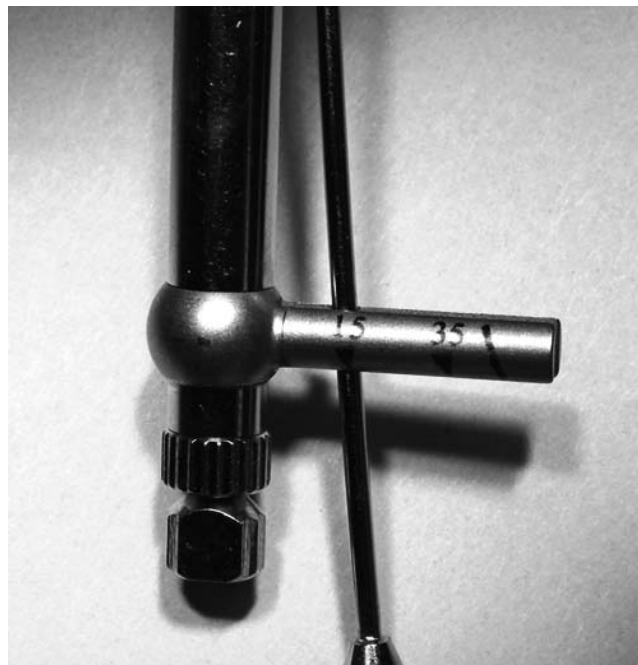


Figure 4. Close-up view of torque ratchet.

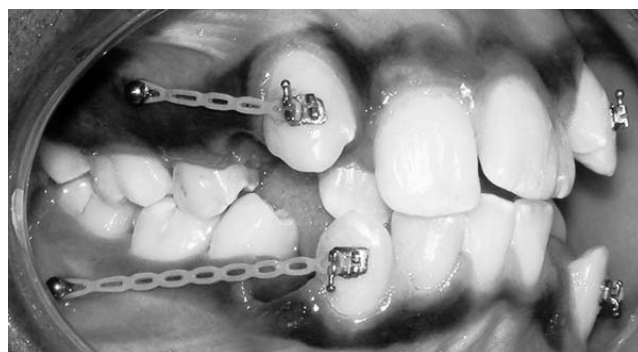

Figure 5. Immediately loaded large grit acid-etched implants.

Anatomical location (posterior maxilla vs posterior mandible), the design (machined titanium vs sand-blasted, acid-etched) and dimensions of each implant, the character of soft tissue at the screw head emergence (keratinized vs oral mucosa), and magnitude of applied orthodontic forces were recorded for each patient. In addition, the torque range at the time of insertion was recorded. A perception of surgical challenge for each type of mini-implant was recorded by the periodontist on a three-point scale (simple, moderate, and difficult). Postsurgical pain encountered for the first few days was recorded by each patient; using a four-point scale (no pain, mild, moderate, severe). During the course of orthodontic treatment, the implant sites were examined at every visit for signs of infection or others complications.

The absence of inflammation or clinically detectable mobility, and the ability to maintain implant stability un-

Table 1. Distribution of the Implants Based on the Surface Treatment and the Location

Assessment	Number of Implants	Percent of Implants
Anatomical location		
Maxilla	17	53.1
Mandible	15	46.9
Soft tissue location		
Keratinized	11	34.4
Oral mucosa	21	65.6
Implant surface		
Machined titanium	17	53.1
Sandblasted, acid-etched	15	46.9

Table 2. Distribution of the Implants in Relation to the Diameter, Length, and Torque Value

Assessment	Number of Implants	Percent of Implants
Implant diameter		
1.4 mm	4	12.5
1.6 mm	9	28.1
1.8 mm	15	46.9
2.0 mm	4	12.5
Implant length		
6 mm	5	15.6
8 mm	7	21.9
8.5 mm	15	46.9
10 mm	5	15.6
Torque range		
<15 Ncm	13	40.6
>15 Ncm	19	59.4

der orthodontic load, identified a successful implant. If an implant failed during the orthodontic treatment, the time from implant insertion to failure diagnosis was also recorded.

Statistical Analysis

Correlation between the two different implant systems and the clinical parameters gathered were evaluated by chi-square exact tests using the SAS version

9.1. The influence of the clinical parameters on the survival rate of the mini-implants was also evaluated using chi-square exact tests.

RESULTS

The overall survival rate was 87.5%. The MT and SLA mini-implant systems had survival rates of 82.5% and 93.5% survival rates, respectively.

Seventeen of the implants placed were MT and 15 were SLA. The distribution of mini-implants based on surface characteristics and location is shown in Table 1. The distribution of mini-implants based on diameter, length, and torque is shown in Table 2. The majority of the mini-implants emerged through the oral mucosa as opposed to the keratinized tissue, and two-thirds had a torque value higher than 15 Ncm at the time of placement.

Surgeon-reported ease of use was significantly different between the two systems favoring the machined titanium type (Table 3). Due to its insertion technique and instrumentation design, most clinicians agreed that MT was easier to use (94.1% rated simple) in comparison to the SLA system (93.3% rated moderate). None of the surgical procedures were considered difficult.

Clinical mobility and peri-implant inflammation were diagnosed on a total of four implants. Two implants failed 14 days after placement and the other two failed after being under loading for 85 days. Torque range appears to be a critical variable for survival. All successful mini-implants had a torque range at insertion greater than 15 Ncm (Table 4).

Although the failed implants were all placed in areas of nonkeratinized tissue with three of them in the posterior maxilla (Table 4), correlations between anatomical location, soft tissue type, and the survival rate were not statistically significant.

Among the MT failure group, two mini-implants had a diameter of 1.6 mm with a length of 10 mm and the third had a diameter of 1.4 mm with a length of 6 mm. Implant dimensions did not influence the survival rate.

Table 3. Correlation Between Surface Characteristic and Clinical Parameters^a

Assessment	Surface Characteristic MT		Surface Characteristic SLA		P value	Significance
	Number	Percent	Number	Percent		
Surgical handling						
Simple	16	94.1	1	6.7	.0001	*
Moderate	1	5.9	14	93.3		
Difficult	0	0.0	0	0.0		
Torque range						
<15 Ncm	6	35.3	7	46.7	.513	NS
>15 Ncm	11	64.7	8	53.3		

^a MT indicates machined titanium; SLA, sandblasted, large grit, acid-etched; NS, not significant.

* $P < .05$.

Table 4. Influence of the Clinical Parameters on the Survival Rate^a

Assessment	Total Number of Implants	Number of Implant Failures	Percent Survival	P value	Significance
Anatomical location				.348	NS
Maxilla	17	3	82.3		
Mandible	15	1	93.3		
Soft tissue emergence				.121	NS
Keratinized	11	0	100.0		
Oral mucosa	21	4	81.1		
Implant diameter				.496	NS
1.4 mm	4	1	75.0		
1.6 mm	9	2	77.8		
1.8 mm	15	1	93.3		
2.0 mm	4	0	100.0		
Implant length				.159	NS
6 mm	5	1	80.0		
8 mm	7	0	100.0		
8.5 mm	15	1	93.3		
10 mm	5	2	60.0		
Surface characteristic				.348	NS
Machined titanium	17	3	82.4		
Sandblasted, acid-etched	15	1	93.4		
Torque range				.004	*
<15 Ncm	13	4	69.2		
>15 Ncm	19	0	100.0		

^a NS indicates not significant.

* $P < .05$.

The only SLA mini-implant failure had a diameter of 1.8 mm and a length of 8.5 mm. Although two-thirds of the failing mini-implants were MT, the survival rate was not statistically affected by the implant surface characteristics.

The majority of the patients (8/10) reported either no postinsertion pain or mild discomfort; two patients, who had teeth extracted at the same appointment, reported moderate pain the first few days. Interestingly, no pain or other symptoms were reported by patients with failing implants.

DISCUSSION

The overall success rate of 87.5% found in this study compares favorably to reports by Park et al,²⁰ and Buchter et al,²¹ who have reported 80% or greater success rates.

Numerous reports in the periodontal literature imply a preference for coated or roughened surface treatments,²²⁻²⁴ suggesting the increased surface area may enhance early osseointegration, even in poor quality bone, and improve survival. Aldikacti,²⁵ examining peri-implant osseous tissue surrounding SLA implants loaded with a continuous force of 200 g for 52 weeks in dogs, found a thicker corticalization of bone trabeculae and an increase in bone opposition.

In other observations, Chung et al²⁶ and Randow et al²⁷ demonstrated successful distal molar movement and en masse retraction of maxillary teeth with the aid

of SLA mini-implants. In these studies, however, the authors recommend a 6- to 8-week preloading healing period.

Early clinical experiences suggested 6 to 12 weeks as an optimal osseointegration period before the orthodontic loading.²⁸ In a more recent study, Lee and Chung²⁹ described the effect of early loading on the osseointegration of an SLA mini-implant in animals and found that premature loading after a 4-week healing period did not adversely affect the process. Interestingly, Deguchi et al³⁰ have demonstrated that mini-implants with as little as 5% bone contact at the bone-implant interface successfully resisted orthodontic force.

Although the survival rate of the SLA mini-implants in this investigation was higher compared with the MT group (93.5% to 82.5%), the correlation between the implant surface characteristics and the rate of success was not statistically significant. These findings suggest that altering an implant surface to create more surface area and increase bone contact may not be the primary consideration when using mini-implants as orthodontic anchors.

In the present study, more than half of the failing mini-implants occurred in the posterior maxilla, but the influence of skeletal topology on the survival rate was not statistically significant. These findings are in agreement with the experiences reported by Huja et al³¹ who found that mini-screws with only 5% bone contact

could resist a force application of 200–300 g. A retrospective examination of 134 titanium screws and 17 plates inserted in 51 patients by Miyawaki's group³² found that thin cortical bone significantly lowered success rate. By contrast, Cheng et al³³ proposed that the high bone density in the posterior mandible might induce overheating during the drilling sequence and, therefore, increase the failure rate.

The anatomical location and inflammation of peri-implant tissue has been shown to affect the survival rate.³⁴ Although statistically insignificant, all failing implants in the present study had a screw emergence in the oral mucosa rather than keratinized gingiva. It must be noted that the number of mini-implants placed through oral mucosa nearly doubled the number of those placed in keratinized tissue (Table 1). Two mini-implants from the four failing ones were placed on the same patient and were able to withstand the immediate orthodontic loading for more than 85 days before they were lost. Poor oral hygiene, resulting in localized inflammation of the surrounding peri-implant tissue, might be a better explanation for the failure rather than immediate function.

Overall dimensions of the devices used in this study were not demonstrated relevant to the survival rate. The smallest mini-implant diameter inserted was 1.4 mm and the shortest length was 6 mm. Miyawaki³² reported the successful fixation of 17 mini-plates with two screws of 2.0 mm diameter and 5 mm length and noted that monocortical insertion with a limited length was sufficient to stabilize the fixtures. Moreover, the same author demonstrated that screws with 1.0 mm diameter or less had a significantly lower success rate in comparison to the 1.5 or 2.3 mm diameter screws.

Recent clinical experiences with dental implants have emphasized the importance of the torque value related to immediate loading. In a study of immediately loaded single tooth implants, Ottoni et al³⁴ reported a 20% reduced risk of failure for every 9.08 Ncm added to the torque range. Degidi et al³⁵ recommended a torque value of more than 25 Ncm for immediate loading of dental implants.

A significant finding of the present study is the range of torque values recorded at the time of placement. All implants placed with a minimum torque value of 15 Ncm survived immediate loading. This finding was statistically significant. Motoyoshi et al³⁶ recommended an implant placement torque range of 5 to 10 Ncm. Their recommendation was based on the fact that higher torque values did not yield higher survival rates. The latter study did not correlate torque values to other variables to account for implant success. Perhaps, if all other variables responsible for implant survival are ideal, insertion torque values smaller than 15 Ncm may be clinically successful.

Although not recorded in this study, the SLA mini-implants presented a higher level of osseointegration at the time of removal. This clinical observation was based on the higher torque necessary for removal of SLA mini-implants when compared with smooth machined titanium implants. Our clinical experience indicates that surface treated (SLA) implants could be advantageous in areas of poor bone quality, and loading should be delayed for 6 to 8 weeks when initial osseointegration has occurred. Additionally, bone density, assessed by torque required for insertion, and ability to control inflammation are perceived as essential to increase the survival rates of mini-implants.

CONCLUSIONS

- Surface characteristics did not appear to influence survival rates of immediately loaded mini-implant.
- A torque value of more than 15 Ncm recorded at the time of insertion appears to be one of the critical variables for mini-implant survival under immediate loading.

REFERENCES

1. Bondermark L, Kurol J. Distalization of the first and second molars simultaneously with repelling magnets. *Eur J Orthod.* 1992;14:264–272.
2. Samuels RH, Breznick N. Orthodontic facebows: safety issues and current management. *J Orthod.* 2002;29(2):101–107.
3. Lekholm U, Zarb GA. Patient selection and preparation. In: Branemark PI, Zarb GA, Albrektsson T, eds. *Tissue Integrated Prosthesis: Osseointegration in Clinical Dentistry.* Chicago, Ill: Quintessence; 1985:199–209.
4. Adell R, Lekholm U, Rockler B, Branemark P. A 15-year study of osseointegrated implants in treatment of the edentulous jaw. *Int J Oral Surg.* 1981;6:387–416.
5. Ödmann J, Lekholm J, Jemt T, Branemark PI, Thilander B. Osseointegrated titanium implants—a new approach in orthodontic treatment. *Eur J Orthod.* 1988;10:98–105.
6. Linkow LI. Implant-orthodontics. *J Clin Orthod.* 1970;4:685–706.
7. Higuchi KW, Slack JM. The use of titanium fixtures for intraoral anchorage to facilitate orthodontic tooth movement. *Int J Oral Maxillofac Implants.* 1991;6:388–344.
8. Ödmann J, Lekholm U, Jemt T, Thilander B. Osseointegrated implants as orthodontic anchorage in the treatment of partially edentulous adult patients. *Eur J Orthod.* 1994;16(3):187–201.
9. Wehrbein H, Diedrich P. Endosseous titanium implants during and after orthodontic load: an experimental study in the dog. *Clin Oral Implants Res.* 1993;4:76–82.
10. Akin-Nergiz N, Nergiz I. Reactions of peri-implant tissues to continuous loading of osseointegrated implants. *Am J Orthod Dentofacial Orthop.* 1998;114(3):292–298.
11. Roberts WE, Marshall KJ, Mozsary PG. Rigid endosseous implant utilized as anchorage to protract molars and close an atrophic extraction site. *Angle Orthod.* 1989;60:135–152.
12. Roberts WE, Nelson CL, Goodacre CJ. Rigid implant anchorage to close a mandibular first molar extraction site. *J Clin Orthod.* 1994;27:693–704.

13. Block MS, Hoffman DR. A new device for absolute anchorage for orthodontics. *Am J Orthod Dentofacial Orthop.* 1995; 3:251–258.
14. Wehrbein H, Merz BR, Diedrich P, Glatzmaier J. The use of palatal implants for orthodontic anchorage: design and clinical application of the Orthosystem. *Clin Oral Implants Res.* 1996;7:410–416.
15. Wehrbein H, Glatzmaier J, Mundwiler U, Diedrich P. The Orthosystem—a new implant system for orthodontic anchorage in the palate. *J Orofac Orthop.* 1996;57:142–153.
16. Kanomi R. Mini-implant for orthodontic anchorage. *J Clin Orthod.* 1997;31:763–767.
17. Bae S, Park HS, Kyung HM, Kwon OW, Sung JH. Clinical application of micro-implant anchorage. *J Clin Orthod.* 2002; 36:298–302.
18. Miyawaki S, Koyama I, Inoue M, Mishima K, Sugahara T, Takano-Yamamoto T. Factors associated with the stability of titanium screws placed in the posterior region for orthodontic anchorage. *Am J Orthod Dentofacial Orthop.* 2003; 124:373–378.
19. Costa A, Raffini M, Melsen B. Miniscrews as orthodontic anchorage: a preliminary report. *Int J Adult Orthodon Orthognath Surg.* 1998;13:201–209.
20. Park HS, Lee SK, Kwon OW. Group distal movement of teeth using microscrew implant anchorage. *Angle Orthod.* 2005;75(4):602–609.
21. Buchter A, Wiechmann D, Koerdt S, Wiesmann HP, Piffko J, Meyer U. Load-related implant reaction of mini-implants used for orthodontic anchorage. *Clin Oral Implants Res.* 2005;16(4):473–479.
22. Jeffcoat MK, McGlumphy EA, Reddy MS, Geurs NC, Proskin HM. A comparison of hydroxyapatite (HA) -coated threaded, HA-coated cylindrical, and titanium threaded endosseous dental implants. *Int J Oral Maxillofac Implants.* 2003;18(3):406–410.
23. Geurs NC, Jeffcoat RL, McGlumphy EA, Reddy MS, Jeffcoat MK. Influence of implant geometry and surface characteristics on progressive osseointegration. *Int J Oral Maxillofac Implants.* 2002;17(6):811–815.
24. Buser D, Nydegger T, Hirt HP, Cochran DL, Nolte LP. Removal torque values of titanium implants in the maxilla of miniature pigs. *Int J Oral Maxillofac Implants.* 1998;13(5): 611–619.
25. Aldikacti M, Acikgoz G, Turk K, Trisi P. Long-term evaluation of sandblasted and acid-etched implants used as orthodontic anchors in dogs. *Am J Orthod Dentofacial Orthop.* 2004;125:139–147.
26. Chung K, Kim SH, Kook Y. C-orthodontic microimplant for distalization of mandibular dentition in Class III correction. *Angle Orthod.* 2004;75(1):119–128.
27. Randow K, Ericsson I, Nilner K, Petersson A, Glantz PO. Immediate functional loading of Branemark dental implants. An 18-month clinical follow-up study. *Clin Oral Implants Res.* 1999;10:8–15.
28. Roberts WE, Smith RK, Zilberman Y, Mozsary PG, Smith RS. Osseous adaptation to continuous loading of rigid endosseous implants. *Am J Orthod.* 1984;86:95–111.
29. Lee SI, Chung KR. The effect of early loading on the direct bone-to-implant surface contact of the orthodontic osseointegrated titanium implant. *Korea J Orthod.* 2001;31:173–185.
30. Deguchi T, Takano-Yamamoto T, Kanomi R, Hartsfield JK, Roberts WE, Garetto LP. The use of small titanium screws for orthodontic anchorage. *J Dent Res.* 2003;82(5):377–381.
31. Huja SS, Litsky AS, Beck FM, Johnson KA, Larsen PE. Pull-out strength of monocortical screws placed in the maxillae and mandibles of dogs. *Am J Orthod Dentofacial Orthop.* 2005;127(3):307–313.
32. Miyawaki S, Koyama I, Inoue M, Mishima K, Sugahara T, Takano-Yamamoto T. Factors associated with the stability of titanium screws placed in the posterior region for orthodontic anchorage. *Am J Orthod Dentofacial Orthop.* 2003; 124:373–378.
33. Cheng SJ, Tseng IY, Lee JJ, Kok SH. A prospective study of the risk factors associated with failure of mini-implants used for orthodontic anchorage. *Int J Oral Maxillofac Implants.* 2004;19(1):100–106.
34. Ottoni JM, Oliveria ZF, Mansini R, Cabral AM. Correlation between placement torque and survival of single-tooth implants. *Int J Oral Maxillofac Implants.* 2005;20:769–776.
35. Degidi M, Piattelli A. Comparative analysis of 702 dental implants subjected to immediate functional loading and immediate nonfunctional loading to traditional healing periods with a follow-up of up to 24 months. *Int J Oral Maxillofac Implants.* 2005;20:99–107.
36. Motoyoshi M, Hirabayashi M, Uemura M, Shimizu N. Recommended placement torque when tightening an orthodontic mini-implant. *Clin Oral Implants Res.* 2006;17(1):109–114.