

Evaluation of maxillary buccal alveolar bone before and after orthodontic alignment without extractions: A cone beam computed tomographic study

Juliana F. Morais^a; Birte Melsen^b; Karina M. S. de Freitas^c; Nuria Castello Branco^a; Daniela G. Garib^d; Paolo M. Cattaneo^e

ABSTRACT

Objectives: To assess the changes in the maxillary buccal alveolar bone during alignment without extractions. Secondly, to evaluate the changes in arch dimensions and buccolingual inclinations of teeth and to identify risk factors for bone loss.

Materials and Methods: Twenty-two adolescents with crowded permanent dentitions were treated without extractions with Damon 3MX brackets. Cone beam computed tomographic scans were taken before treatment (T0) and after alignment (T1). Bone thickness (BT) and height from the cemento-enamel junction to the alveolar crest (BH) were evaluated at the maxillary central incisors, second premolars, and buccal roots of first molars. Changes in all variables from T0 to T1 were assessed. Correlations between bone changes and initial bone thickness, initial arch widths, initial crowding, amount of expansion, amount of tipping, and amount of molar rotation were calculated.

Results: BT decreased and BH increased significantly for the incisors and mesiobuccal root of the first molars. Arch dimensions generally increased together with tipping. Bone loss was correlated with crowding and amount of expansion in the premolar region. Initially thinner BT was correlated with greater apical migration of bone for the incisors.

Conclusions: Nonextraction alignment with self-ligating brackets led to arch expansion associated with tipping of teeth. Expansion related to alignment resulted in horizontal and vertical bone loss at the incisors and mesiobuccal root of the first molars. Thinner BTs and more severe crowding before treatment increased the risk for buccal bone loss. (*Angle Orthod.* 2018;88:748–756.)

KEY WORDS: CBCT; Alveolar bone; Adolescents; Self-ligating; Orthodontics

^a Former PhD Student, Department of Orthodontics, Bauru Dental School, University of São Paulo, Bauru, Brazil.

^b Former Department Chair, Department of Orthodontics, School of Dentistry, Aarhus University, Aarhus, Denmark.

^c Assistant Professor, Department of Orthodontics, Uningá University Center, Maringá, Brazil.

^d Associate Professor, Department of Orthodontics, Bauru Dental School and Hospital for Rehabilitation of Craniofacial Anomalies, University of São Paulo, Bauru, Brazil.

^e Associate Professor, Department of Orthodontics, School of Dentistry, Aarhus University, Aarhus, Denmark.

Corresponding author: Dr Juliana Fernandes de Morais, Department of Orthodontics, Bauru Dental School, University of São Paulo, Alameda Octávio Pinheiro Brisolla 9-75, Bauru - SP - 17012-901, Brazil
(e-mail: julianamorais.orto@gmail.com)

Accepted: March 2018. Submitted: October 2017.

Published Online: June 18, 2018

© 2018 by The EH Angle Education and Research Foundation, Inc.

INTRODUCTION

Alleviation of crowding without extractions and reduction of tooth material can be achieved by distal movement of posterior teeth, expansion of the dental arch, and incisor proclination.¹ However, sagittal expansion beyond the skeletal base boundaries may, according to animal^{2,3} and human^{4–7} studies, constitute a risk for developing bony dehiscence and gingival recession. Transverse expansion can be achieved by relieving the external muscle matrix,⁸ by using buccal pressure with palatal devices,¹ and, more recently, using fixed appliances with broad archwires has been suggested.^{9,10}

Rapid palatal expansion provokes horizontal and vertical reductions in the buccal alveolar bone of premolars and molars according to three-dimensional (3D) studies,^{11,12} whereas the combination of self-ligating brackets with heat-activated superelastic archwires has been alleged to produce a low-force, low-

Table 1. Definitions of Variables and their Abbreviations

Measurements	Abbreviation	Descriptions
Buccal bone thickness at 3 mm	Tooth-3	Buccal bone thickness measured between the facial aspect of the root to the facial aspect of the alveolar bone, at 3 mm from the cemento-enamel junction (CEJ) ^a
Buccal bone thickness at 6 mm	Tooth-6	Buccal bone thickness measured between the facial aspect of the root to the facial aspect of the alveolar bone, at 6 mm from the CEJ ^a
Bone area	Tooth-area	Alveolar bone area delimited apically at 3/4 of the root length from the CEJ, lingually by the tooth root, and buccally by the facial contour of the bone plate. The root length was determined on the postalignment scans ^a
Bone height	BH-tooth	Vertical distance between the facial CEJ and the buccal alveolar bone crest ^a
Arch widths	Tooth-W	Distance between contralateral teeth ^b
Arch length	AL	Distance from the interincisor point and the mean distance between the mesial contact points of the first molars ^b
Buccolingual inclinations	Tooth-inclination	Angles between the mesiodistal plane of each tooth and the occlusal plane ^c
First molar rotations	Rotation-1M	Angle between molar buccal surface at the CEJ level and a line perpendicular to the palatal raphe, measured on a 3-mm-thick axial section
Tooth (root)	I	Central incisors
	C	Canines
	1PM	First premolars
	2PM	Second premolars
	1M	First molars
	mb1M	Mesiobuccal root of first molars
	db1M	Distobuccal root of first molars

^a See Figure 1.

^b See Figure 2.

^c See Figure 3.

friction environment in which the bone follows tooth movement. Thus, orthodontic treatment with self-ligating appliances would allow for greater dental expansion, provoke less incisor proclination, and require fewer extractions than would treatment with conventional appliances.¹⁰ Nevertheless, cone beam computed tomographic (CBCT) studies^{7,13} in nonextraction patients assessing the bone at the maxillary second premolars and at the mandibular incisors have failed to demonstrate that self-ligating appliances promote expansion with torque control and that teeth are followed by the alveolar bone. A more comprehensive study assessing the changes in the buccal bone in both the posterior and anterior regions of the maxilla has not yet been published.

In addition to several claimed advantages, treatment with self-ligating appliances is characterized by simplified and standardized mechanics. Thus, it may be suitable to assess the effect of arch expansion in different patients using this approach, as some of the uncertainties related to different mechanics used during treatment are removed through this standardization. Therefore, this investigation aimed to assess changes in the maxillary buccal alveolar bone during the alignment phase of orthodontic treatment using a self-ligating appliance. Secondarily, the aim of this study was to evaluate changes in arch dimensions and buccolingual inclinations of the teeth and to identify risk factors for bone loss.

MATERIALS AND METHODS

Sample

This study was approved by the Research Ethics Committee of Bauru Dental School, University of São Paulo (No. 136/2010), and written consent to undergo CBCT radiographic examinations and to participate in this investigation was obtained from all patients and from their parents or guardians. The following inclusion criteria were applied to the subjects presenting for treatment at the Orthodontic Department of Bauru Dental School, University of São Paulo, Brazil: (1) Class I or Class II molar relationship; (2) more than 4 mm of crowding in the maxillary arch; (3) full permanent dentition anterior to the first molars; (4) age 11–17 years; (5) healthy periodontium; and (6) no previous orthodontic treatment.

Based on a preliminary power analysis, a minimum sample size of 18 participants was needed to achieve an 80% power of the study with a significance level of .05, aiming to demonstrate a true difference of 2.5 mm² in the buccal bone area of the second premolar, assuming a previously reported standard deviation of 3.6 mm.¹³ All patients were treated with Damon 3MX[®] (Ormco, Glendora, Ca) standard torque brackets with the following archwire sequence: (1) 0.014-inch Damon[®] copper-nickel-titanium (CuNiTi) archwires for at least 10 weeks or until the teeth were passively engaged in all bracket slots, (2) 0.014 × 0.025-inch Damon CuNiTi archwires kept until tooth alignment

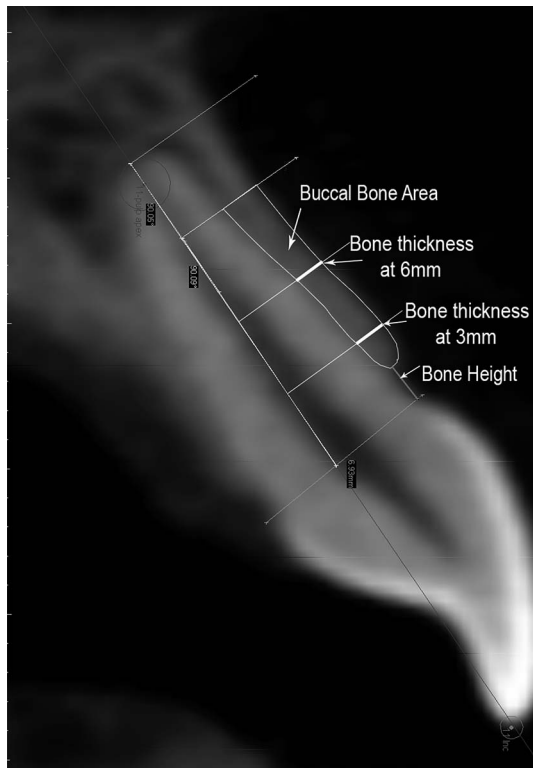


Figure 1. Cross-section imaging of the buccal alveolar bone showing the lines that determined the alveolar bone thickness at 3 and 6 mm from the CEJ, the bone area, and the bone height.

allowed the complete insertion of the archwire in the slots with passive closure of the bracket lid, and (3) 0.019 × 0.025-inch stainless-steel (SS) archwire contoured for maintenance of the arch form developed in the first two phases. Oral hygiene was monitored during this period. Appointment intervals were approximately 5 weeks. No additional interventions, such as interproximal reduction, intermaxillary elastics, or any orthopedic mechanics, were used.

CBCT scans (i-CAT scanner, Imaging Sciences International, Hatfield, USA) were taken before treatment (T0) and a minimum of 4 weeks after insertion of the 0.019 × 0.025-inch SS archwire (T1). The following imaging acquisition parameters were used: 5 mA, 120 kV, field of view (FOV) of 13 cm height × 16 cm diameter, and either 20-second or 40-second exposure time, which generated an isotropic voxel size of 0.3 mm (nine patients) or 0.25 mm (13 patients), respectively. For each patient, the identical scanning protocol was used at T0 and T1. According to the approved protocol, no additional CBCT scan was taken at the end of treatment.

3D Image Processing and Measurements

Each CBCT scan was imported into Mimics software (version 14.01, Materialise, Leuven, Belgium) using the

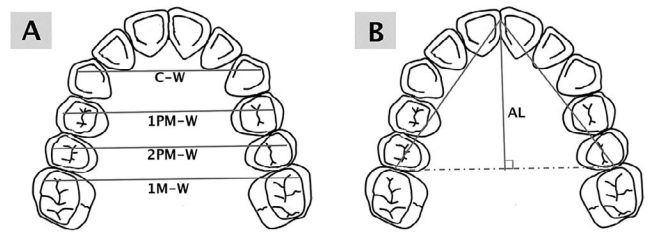


Figure 2. Schematic design showing the measurements of (A) intercanine (C-W), inter-first premolar (1PM-W), inter-second premolar (2PM-W), and intermolar (1M-W) widths and (B) the arch length (AL).

DICOM file format. A prior pilot study was carried out to analyze the sites at which the buccal bone thickness allowed for reliable measurements. Thus, buccal alveolar bone morphology relative to the maxillary central incisor (I), second premolar (2PM), and first molar mesiobuccal (mb1M) and distobuccal (db1M) roots was assessed.

In Mimics, cross sections of 0.3-mm thickness were made so that the axial slices were perpendicular to the long axis of the tooth in the buccolingual direction for each individual tooth/root. The cross sections were generated passing through the pulp apex and crossing the center of the root perpendicular to the alveolar contour at the level of the root cervical third. This can be done regardless of the angulation/rotation of the tooth relative to the alveolar process or the presence of crowding. These cross-section images were imported into the software ImageJ (NIH, Bethesda, Md), within which the following variables were assessed: (1) buccal bone thickness (BT) at 3 and 6 mm from the cemento-enamel junction (CEJ); (2) buccal bone area; and (3) buccal bone height (BH), defined as the distance from the CEJ to the alveolar crest, as described in Table 1 and Figure 1.

The intercanine, inter-first premolar, inter-second premolar, and intermolar widths and the arch length were measured (Figure 2). Buccolingual inclinations of teeth were measured in tooth-based coordinate systems for the central incisors, canines, first and second premolars, and first molars (Figure 3). Molar rotations were measured on 3-mm-thick axial sections built at the buccal CEJ level of each molar, parallel to the palatal plane and interorbital line and perpendicular to the median sagittal plane. All measurements and their respective abbreviations are described in Table 1.

Statistical Analyses

To assess the measurement error, 10 randomly selected postalignment CBCT scans were measured twice by the same operator (JFM) with a 1-week interval between measurements. The random error was calculated by Dahlberg's formula ($S^2 = \Sigma d^2/2n$),¹⁴ where S^2 is the error variance and d is the difference

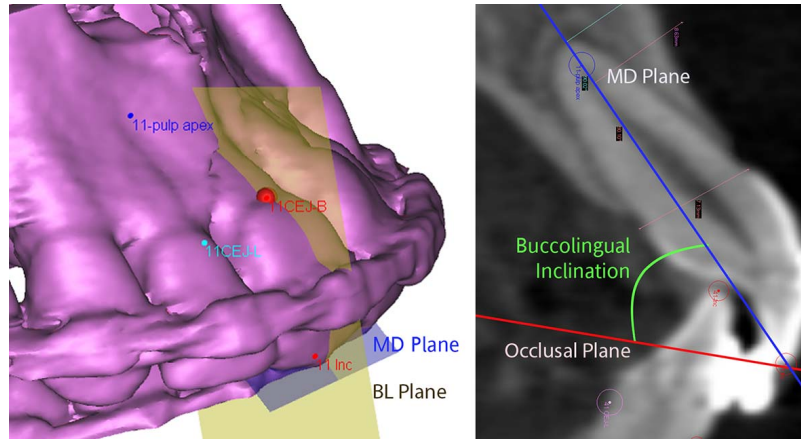


Figure 3. Example of a dental coordinate system, composed of a buccolingual (BL, light grey) and a mesiodistal (MD, dark grey) plane, used to measure buccolingual inclinations of teeth between MD plane and occlusal plane.

between the same variable measured twice. The systematic errors were evaluated using paired *t*-tests.

The normality of distribution of the variables was assessed by Shapiro-Wilks test. Interphase changes (T1–T0) were calculated, and if normally distributed, these were compared using paired *t*-tests; if this was not the case, the Wilcoxon test was used. Changes in BTs at 3 and 6 mm and in bone area expressed as percentages were calculated by the following formula: $(\text{boneT1} - \text{boneT0} / \text{boneT0}) \times 100$.

The influence of initial bone thickness, initial crowding, amount of expansion, amount of tipping, and amount of molar rotation on the changes occurring in bone height and area was evaluated by Pearson correlation coefficient or Spearman correlation. For all tests, the significance level was set at $P < .05$.

RESULTS

Twenty-two consecutive patients matched the inclusion criteria and were enrolled in the study. Descriptive

Table 2. Demographics and Clinical Characteristics of the Sample (N = 22)^a

	Mean	SD
Initial characteristics		
Initial age, y	14.7	1.2
Little Index–maxillary arch, mm	11.3	5.2
Space analysis–maxillary arch, mm	–6.6	3.0
Gender	9 Female & 13 male	
Molar relationship	20 Class I; 2 Class II subdivision	
Treatment times, wk		
Damon 0.014-inch CuNiTi	26.0	9.6
Damon 0.014 × 0.025-inch CuNiTi	16.6	8.0
Stainless-steel 0.019 × 0.025-inch CuNiTi	7.6	4.1

^a SD indicates standard deviation; CuNiTi, copper-nickel-titanium.

statistics of the sample are reported in Table 2. No significant systematic errors of the method were found, and the random error was small (Table 3).

A significant decrease in BT was observed at the incisors 3 mm from the CEJ (–24%) and also in bone area (–13%). The same occurred relative to mb1M,

Table 3. Casual and Systematic Errors Between the First and Second Measurements^a

Variable	Difference First and Second Measurement		Systematic Error <i>P</i>	Casual Error Dahlberg
	Mean	SD		
I-3, mm	0.05	0.07	.071	0.08
I-6, mm	–0.03	0.11	.271	0.11
I-area, mm ²	0.19	1.18	.487	0.82
BH-I, mm	–0.06	0.19	.155	0.19
2PM-3, mm	0.05	0.09	.092	0.10
2PM-6, mm	0.05	0.14	.155	0.14
2PM-area, mm ²	0.38	1.89	.385	1.33
BH-2PM, mm	–0.03	0.16	.421	0.16
mb1M-3, mm	0.10	0.14	.067	0.17
mb1M-6, mm	0.04	0.12	.167	0.12
mb1M-area, mm ²	0.58	1.50	.158	1.10
BH-mb1M, mm	–0.09	0.21	.084	0.21
db1M-3, mm	0.06	0.14	.083	0.15
db1M-6, mm	0.19	0.68	.226	0.13
db1M-area, mm ²	0.43	1.38	.175	1.00
BH-db1M, mm	–0.03	0.16	.470	0.16
C-W, mm	–0.01	0.23	.853	0.16
1PM-W, mm	0.01	0.21	.839	0.14
2PM-W, mm	–0.16	0.42	.265	0.30
1M-W, mm	–0.06	0.55	.729	0.37
Arch length left, mm	0.06	0.19	.336	0.13
Arch length right, mm	–0.17	0.27	.078	0.22
I-inclination, °	0.15	0.64	.296	0.45
C-inclination, °	0.18	1.01	.434	0.71
1PM-inclination, °	0.17	0.68	.281	0.48
2PM-inclination, °	0.41	1.15	.130	0.83
1M-inclination, °	0.04	1.14	.872	0.77
Rotation-1M, °	0.11	1.20	.680	1.17

^a SD indicates standard deviation.

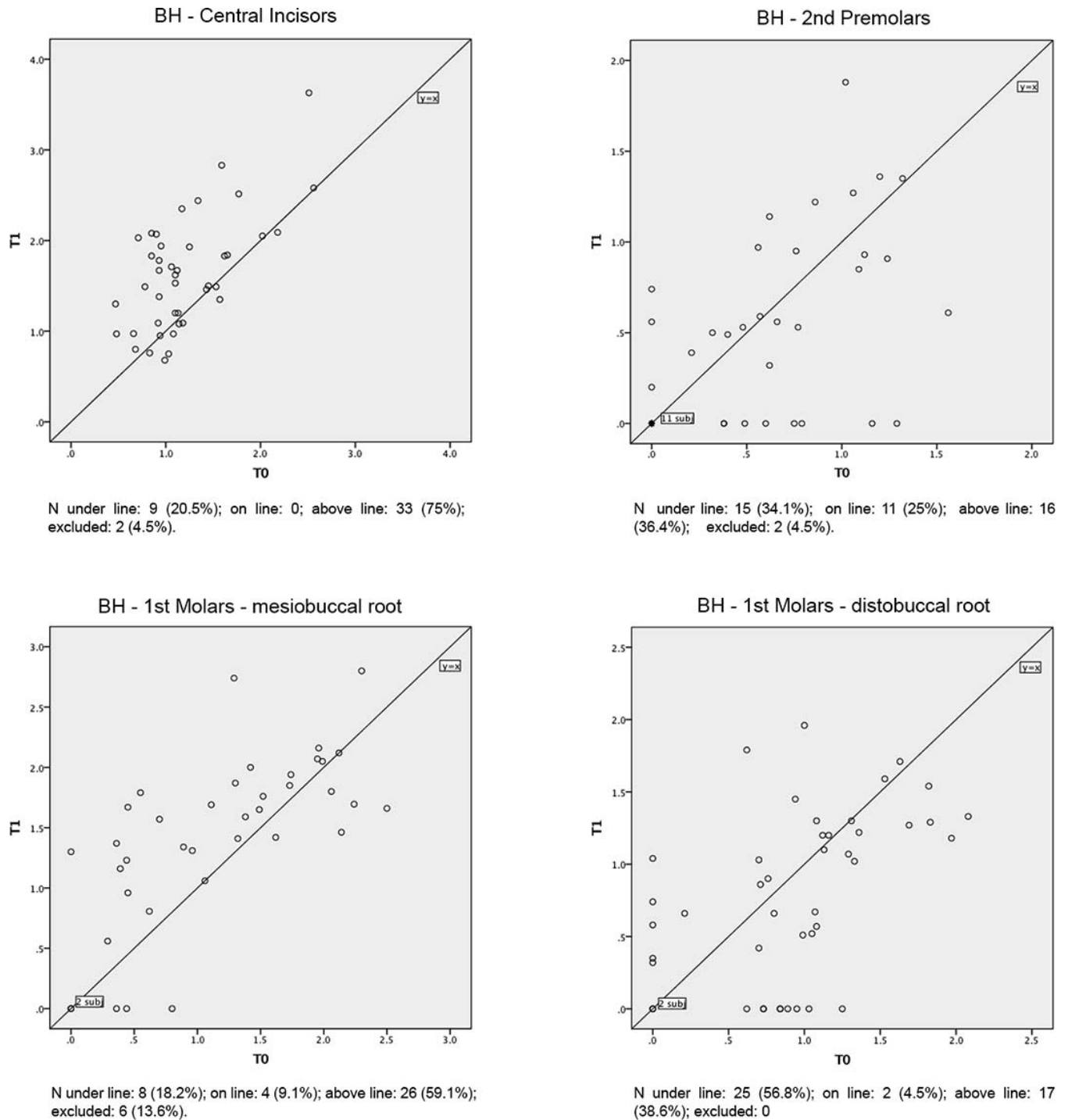


Figure 4. Scatterplots with values for buccal bone heights at T0 and T1.

where BT 3 and 6 mm from the CEJ showed a significant reduction (–36% and –45%, respectively), while bone area decreased 40% (Table 4). Significant apical migration of marginal bone occurred in relation to the incisors (0.4 mm) and mb1Ms (0.3 mm), with high variability. Radiographically, two incisors (4.5%) and six mb1Ms (13.6%) showed roots completely

uncovered buccally after alignment and were excluded in the calculation of changes in BH (Table 4; Figure 4). Apical migration of marginal bone was seen in 75% of central incisors and 59% of mb1Ms. Additionally, more than 20% of patients had bone recession measuring greater than 1 mm related to one tooth or more.

Table 4. Changes (T1–T0) in Alveolar Buccal Bone Thicknesses and Heights from Before Treatment (T0) Until After Alignment (T1)

	T0		T1		T1–T0		(T1–T0)/T0 (%)		P-Value	Ø
	Mean	SD	Mean	SD	Mean	SD	Mean	SD		
I-3, mm	1.0	0.2	0.8	0.4	–0.2	0.3	–23.8	35.3	.000 ^{T****}	5
I-6, mm	1.1	0.4	1.0	0.3	–0.1	0.4	–2.1	31.9	.119 ^T	0
I-area, mm ²	8.1	2.3	6.9	2.2	–1.2	1.7	–13.2	18.6	.000 ^{T****}	0
BH-I, mm	1.2	0.5	1.6	0.6	0.4	0.5			.000 ^{W****}	2
2PM-3, mm	2.3	0.8	2.2	0.6	–0.2	0.7	–1.9	26.8	.162 ^T	0
2PM-6, mm	2.3	1.0	2.2	1.0	0.0	0.7	5.3	39.4	.979 ^W	1
2PM-area, mm ²	19.1	7.8	19.6	7.8	0.4	6.1	6.1	31.7	.578 ^W	0
BH-2PM, mm	0.5	0.5	0.4	0.5	–0.1	0.5			.332 ^W	2
mb1M-3, mm	1.6	0.5	1.1	0.7	–0.6	0.6	–36.3	36.9	.000 ^{T****}	8
mb1M-6, mm	1.5	0.8	0.9	0.9	–0.5	0.7	–44.7	45.2	.000 ^{W****}	14
mb1M-area, mm ²	10.7	5.4	6.4	5.2	–4.3	4.4	–40.4	43.3	.000 ^{T****}	9
BH-mb1M, mm	1.2	0.7	1.4	0.7	0.3	0.6			.012 ^{W*}	6
db1M-3, mm	2.3	0.5	2.3	0.4	0.0	0.4	3.1	18.3	.714 ^T	0
db1M-6, mm	2.2	0.8	2.2	0.9	0.1	0.6	5.9	34.9	.095 ^W	1
db1M-area, mm ²	15.3	5.5	16.0	4.9	0.6	3.4	7.4	24.0	.105 ^W	0
BH-db1M, mm	0.9	0.6	0.8	0.6	–0.1	0.6			.100 ^W	0

^a SD indicates standard deviation; ^T, paired *t*-test; ^W, Wilcoxon test; and Ø, number of sites in which bone was measurable at T0 and became unmeasurable at T1 (in these sites: bone thicknesses [T1] were considered 0 mm; calculation of changes (T1–T0) in bone height was excluded because marginal bone was unreadable at T1).

* Statistically significant at *P* < .05; **** Statistically significant at *P* < .0001.

Maxillary arch widths increased significantly, especially between 1PMs (4.3 mm). The widening occurred mainly with significant buccal tipping. The greatest buccal tipping was seen at 1PMs, while canines and 1Ms exhibited the least amount of tipping. Substantial incisor proclination was observed. Arch length increased 2.1 mm. The molars rotated significantly mesiobuccally during treatment (Table 5).

There was a tendency for greater bone reduction at 2PM in cases of pronounced crowding, but none of the initial parameters accounted for more than 10% of the variation in treatment-related changes (Table 6). Incisors with thinner alveolar bone before treatment showed a tendency to experience greater vertical bone loss. The tendency was reversed relative to db1M, for which thinner initial bone thickness was associated with vertical bone gain (Table 7).

DISCUSSION

The main purpose of this study was to assess the effects on the maxillary buccal alveolar bone of using a passive self-ligating appliance to alleviate crowding with a nonextraction approach. Overall, crowding was resolved by transverse expansion and dental tipping, as previously reported.^{1,13,15–17} Tissue response to orthodontic forces can occur “through the bone” or “followed by the alveolar bone.”¹⁸ In this study, teeth moved mostly “through the alveolar bone” and not centered in the bone, contrary to claims about self-ligating appliances.¹⁰

Buccal alveolar bone showed significant reduction in thickness and height at the central incisors and mb1M, even though a large variation among patients was

noted. Reduction of buccal alveolar bone following orthodontic treatment corroborates results reported in previous CT and CBCT studies.^{7,11,13,19,20} Garlock et al.⁷ reported on average 1.12 mm of buccal bone recession at the mandibular central incisor, with high variability after nonextraction treatment with a self-ligating appliance. Cattaneo et al.¹³ found 12–23% reduction of buccal bone thickness relative to 2PM following nonextraction orthodontic treatment with self-ligating appliances. Similarly, an animal study²¹ demonstrated buccal expansion with a self-ligating appliance occurring with uncontrolled tipping and apical migration of bone. Other methods of maxillary expansion, slow or rapid, have also been shown to result in dehiscences at posterior teeth.^{11,12,20}

Table 5. Changes (T1–T0) in Arch Dimensions and Buccolingual Inclinations from Before Treatment (T0) Until After Alignment (T1)^a

	T0		T1		T1–T0		P-Value
	Mean	SD	Mean	SD	Mean	SD	
C-W, mm	35.0	2.9	36.6	1.6	1.6	2.5	.006 ^{**}
1PM-W, mm	39.7	2.2	44.0	2.1	4.3	1.6	.000 ^{****}
2PM-W, mm	44.8	3.9	48.4	2.5	3.6	2.8	.000 ^{****}
1M-W, mm	50.0	3.9	52.3	3.0	2.3	1.8	.000 ^{****}
Arch length, mm	41.4	2.4	43.7	2.0	2.1	1.4	.000 ^{****}
I-inclination, °	59.1	4.6	53.1	4.4	–6.3 ^b	5.7	.000 ^{****}
C-inclination, °	64.6	8.2	65.1	3.9	0.3	8.6	.721
1PM-inclination, °	82.8	4.0	73.1	4.8	–9.5 ^b	3.9	.000 ^{****}
2PM-inclination, °	78.7	5.1	72.0	4.9	–6.5 ^b	4.9	.000 ^{****}
1M-inclination, °	85.3	5.8	83.8	4.6	–1.1 ^b	4.1	.016 [*]
Rotation-1M, °	81.8	6.5	88.2	5.6	6.3	6.8	.000 ^{****}

^a SD indicates standard deviation. Statistically significant for paired *t*-tests at * *P* < .05; ** *P* < .01; **** *P* < .0001.

^b Negative values for inclination at T1–T0 indicate crown buccal tipping.

Table 6. Correlation Tests Between the Changes in the Buccal Bone Thicknesses (Area) and Their Respective Pretreatment (Initial Bone Thickness-Area and Maxillary Index of Irregularity) and Treatment-Related Parameters (Changes in Buccolingual Tipping and in Arch Dimensions)^a

Correlations	ΔI Area		$\Delta 2PM$ Area		$\Delta mb1M$ Area		$\Delta db1M$ Area	
	<i>R</i>	<i>P</i> -Value	<i>R</i>	<i>P</i> -Value	<i>R</i>	<i>P</i> -Value	<i>R</i>	<i>P</i> -Value
Little index T0	-0.15 ^s	.347	-0.34 ^s	.027*	0.14 ^s	.379	0.24 ^s	.113
Arch dimensions ^b Δ	-0.05 ^s	.752	-0.40 ^s	.009**	-0.44 ^s	.003**	-0.05 ^s	.734
Inclination Δ	-0.23 ^s	.149	-0.01 ^s	.942	-0.12 ^p	.451	-0.28 ^p	.065
Rotation 1M Δ					-0.15 ^s	.340	0.10 ^p	.509

^a *R* indicates correlation coefficient; ^p, Pearson correlation coefficient (two-tailed); ^s, Spearman correlation test (two-tailed); and Δ , treatment changes T1–T0.

^b Each tooth correlated to its respective arch dimension: Incisors (AL), 2PM (2PM-W), mb1M (1M-W), and db1M (1M-W).

* Significant at $P < .05$; ** Significant at $P < .01$.

On the other hand, treating patients with extractions does not seem to assure that bone loss will be avoided. Lund et al.¹⁹ found significant vertical bone loss in patients treated with premolar extractions, especially on the lingual surfaces of the maxillary incisors (1.0–1.3 mm), while on the buccal surfaces of central incisors, premolars, and molars, the mean bone loss was 0.2 mm.

In contrast to the findings of Cattaneo and coworkers,¹³ the bone reduction at 2PM was not significant in the current study. Among various explanations, the large variation in initial BT, the smaller amount of expansion, the shorter treatment duration, and the different methods of measurement may account for this divergence. The largest decrease in BT was found in lingually positioned premolars and was due to initial crowding.

The average increase in arch dimensions was mainly accompanied by tipping, in agreement with previous clinical studies^{13,15–17} analyzing the effect of nonextraction treatment with self-ligating appliances. The lack of torque control reflected the oversize of the bracket slot, as previously demonstrated in laboratory results.²² On the other hand, it is important to underline that a wide range of changes in arch dimensions and dental tipping were observed.

Crowding has been cited⁴ as a risk factor for bone dehiscence. This was confirmed in this study, as patients with severe initial crowding and thin bone exhibited more reduction of BT at the 2PM area. The measurements may not even reflect the severity overall, as the areas relative to canines, which have higher incidence of dehiscence in untreated patients,¹⁹ and 1PMs, which suffered the greatest expansion, could not be measured because bone thickness was below the measurement threshold. Therefore, the risk of dehiscence resulting from correction of crowding by means of large expansions may have been even higher.

Tipping and expansion have been reported^{4,5,7,13} to cause apical migration of marginal buccal bone and reduction in buccal bone thickness. The results showed a correlation between the amount of expansion and the degree of bone reduction at 2PMs and mb1Ms. The degree of tipping was, contrarily, not significantly correlated to changes in the buccal bone thicknesses. This is in agreement with another study²³ in which no correlation between incisor proclination and gingival recession in adults was found. Large variations in bone morphology and changes in tooth inclination made it difficult to identify variables that might have had a significant impact on the expansion with a self-ligating approach.

Table 7. Correlation Tests Between the Changes in the Buccal Bone Heights (BHs) and Initial Bone Morphology (ie, Buccal Bone Thickness [BT]) and Treatment-Related Parameters (Changes in Buccolingual Tipping and in Arch Dimensions)^a

Correlations	$\Delta BH-I$		$\Delta BH-2PM$		$\Delta BH-mb1M$		$\Delta BH-db1M$	
	<i>R</i>	<i>P</i> -Value	<i>R</i>	<i>P</i> -Value	<i>R</i>	<i>P</i> -Value	<i>R</i>	<i>P</i> -Value
BT-3 T0	-0.42 ^s	.005**	0.05 ^s	.754	0.04 ^s	.807	0.44 ^p	.003**
BT-6 T0	-0.00 ^s	.988	0.24 ^s	.143	-0.18 ^s	.298	0.41 ^p	.006**
BT-area T0	0.12 ^s	.443	0.10 ^s	.534	0.01 ^s	.978	0.49 ^p	.001**
Arch dimensions ^b Δ	0.12 ^s	.449	-0.18 ^s	.261	-0.03 ^s	.839	-0.19 ^s	.221
Inclination Δ	-0.05 ^s	.774	0.26 ^s	.096	0.13 ^s	.424	-0.18 ^p	.256
Rotation 1M Δ					0.14 ^s	.395	-0.09 ^p	.573

^a *R* indicates correlation coefficient; ^p, Pearson correlation coefficient (two-tailed); ^s, Spearman correlation test (two-tailed); and Δ , treatment changes T1–T0.

^b Each tooth correlated to its respective arch dimension: Incisors (AL), 2PM (2PM-W), mb1M (1M-W), and db1M (1M-W).

** Significant at $P < .01$.

Pretreatment thinner BTs increased the risk for bone recession at the central incisors. Similar correlations were found previously for molars and premolars when evaluating rapid maxillary expansion.¹¹ The opposite tendency was found at db1Ms, where thinner initial bone thickness was weakly, though significantly, correlated to vertical bone gain. This can be explained by the increase in bone thickness produced by the mesiobuccal rotation caused by the preadjusted molar tube. As a consequence of large variations in both bone morphology and changes in molar rotation among the subjects, this correlation was not significant.

This study was the first to assess the effects of nonextraction alignment with a preadjusted fixed appliance on buccal alveolar bone in the maxillary anterior and posterior areas. CBCT was chosen because, as a 3D imaging method, it enables evaluation of the buccal bone, yet exposes the patients to a lower level of ionizing radiation (as compared to medical CT).²⁴

The accuracy of linear measurements of thin objects in CBCT presents limitations related to the image resolution. This means that it is difficult to detect the presence of bone on the images in sites in which the bone has the same thickness or less than the voxel size.²⁵ The use of smaller FOV and voxel size could offer better image resolution. However, the patients would have been exposed to a higher dose of ionizing radiation. Indeed, a FOV of 13 cm × 16 cm was used; thus, no other radiographs (ie, panoramic or cephalometric) were needed for treatment planning. Additionally, the 0.3-mm voxel size used in this study was considered acceptable for this purpose.^{25–27}

CONCLUSIONS

- Nonextraction alignment with self-ligating appliances generated dental arch expansion associated with tipping of teeth. Significant bone loss (in terms of both thickness and height) was observed at the maxillary central incisors and the mesiobuccal root of the first molars.
- Initial bone thickness, crowding severity, and the amount of expansion during treatment had a weak, though significant, impact on the buccal bone reduction.

REFERENCES

1. Weinberg M, Sadowsky C. Resolution of mandibular arch crowding in growing patients with Class I malocclusions treated nonextraction. *Am J Orthod Dentofacial Orthop.* 1996;110:359–364.
2. Thilander B, Nyman S, Karring T, Magnusson I. Bone regeneration in alveolar bone dehiscences related to orthodontic tooth movements. *Eur J Orthod.* 1983;5:105–114.

3. Wennstrom JL, Lindhe J, Sinclair F, Thilander B. Some periodontal tissue reactions to orthodontic tooth movement in monkeys. *J Clin Periodontol.* 1987;14:121–129.
4. Fuhrmann R. Three-dimensional interpretation of periodontal lesions and remodeling during orthodontic treatment. Part III. *J Orofac Orthop.* 1996;57:224–237.
5. Wehrbein H, Bauer W, Diedrich P. Mandibular incisors, alveolar bone, and symphysis after orthodontic treatment. A retrospective study. *Am J Orthod Dentofacial Orthop.* 1996;110:239–246.
6. Yared KF, Zenobio EG, Pacheco W. Periodontal status of mandibular central incisors after orthodontic proclination in adults. *Am J Orthod Dentofacial Orthop.* 2006;130:6e1–6e8.
7. Garlock DT, Buschang PH, Araujo EA, Behrents RG, Kim KB. Evaluation of marginal alveolar bone in the anterior mandible with pretreatment and posttreatment computed tomography in nonextraction patients. *Am J Orthod Dentofacial Orthop Off Publ Am Assoc Orthod Its Const Soc Am Board Orthod.* 2016;149:192–201.
8. Fränkel R. A functional approach to orofacial orthopaedics. *Br J Orthod.* 1980;7:41–51.
9. Atik E, Akarsu-Guven B, Kocadereli I, Ciger S. Evaluation of maxillary arch dimensional and inclination changes with self-ligating and conventional brackets using broad archwires. *Am J Orthod Dentofacial Orthop Off Publ Am Assoc Orthod Its Const Soc Am Board Orthod.* 2016;149:830–837.
10. Damon DH. The Damon low-friction bracket: a biologically compatible straight-wire system. *J Clin Orthod.* 1998;32:670–680.
11. Garib DG, Henriques JF, Janson G, de Freitas MR, Fernandes AY. Periodontal effects of rapid maxillary expansion with tooth-tissue-borne and tooth-borne expanders: a computed tomography evaluation. *Am J Orthod Dentofacial Orthop.* 2006;129:749–758.
12. Pangrazio-Kulbersh V, Jezdimir B, de Deus Haughey M, Kulbersh R, Wine P, Kaczynski R. CBCT assessment of alveolar buccal bone level after RME. *Angle Orthod.* 2013;83:110–116.
13. Cattaneo PM, Treccani M, Carlsson K, et al. Transversal maxillary dento-alveolar changes in patients treated with active and passive self-ligating brackets: a randomized clinical trial using CBCT-scans and digital models. *Orthod Craniofac Res.* 2011;14:222–233.
14. Dahlberg G. *Statistical Methods for Medical and Biological Students.* New York, NY: Interscience; 1940.
15. Scott P, DiBiase AT, Sherriff M, Cobourne MT. Alignment efficiency of Damon3 self-ligating and conventional orthodontic bracket systems: a randomized clinical trial. *Am J Orthod Dentofacial Orthop.* 2008;134:470e1–470e8.
16. Ong E, Ho C, Miles P. Alignment efficiency and discomfort of three orthodontic archwire sequences: a randomized clinical trial. *J Orthod.* 2010;38:32–39.
17. Pandis N, Polychronopoulou A, Makou M, Eliades T. Mandibular dental arch changes associated with treatment of crowding using self-ligating and conventional brackets. *Eur J Orthod.* 2010;32:248–253.
18. Melsen B. Biological reaction of alveolar bone to orthodontic tooth movement. *Angle Orthod.* 1999;69:151–158.
19. Lund H, Gröndahl K, Gröndahl H-G. Cone beam computed tomography evaluations of marginal alveolar bone before and after orthodontic treatment combined with premolar extractions. *Eur J Oral Sci.* 2012;120:201–211.

20. Corbridge JK, Campbell PM, Taylor R, Ceen RF, Buschang PH. Transverse dentoalveolar changes after slow maxillary expansion. *Am J Orthod Dentofacial Orthop.* 2011;140:317–325.
21. Kraus CD, Campbell PM, Spears R, Taylor RW, Buschang PH. Bony adaptation after expansion with light-to-moderate continuous forces. *Am J Orthod Dentofacial Orthop.* 2014;145:655–666.
22. Brauchli LM, Steineck M, Wichelhaus A. Active and passive self-ligation: a myth? Part 1: torque control. *Angle Orthod.* 2012;82:663–669.
23. Allais D, Melsen B. Does labial movement of lower incisors influence the level of the gingival margin? A case-control study of adult orthodontic patients. *Eur J Orthod.* 2003;25:343–352.
24. Ludlow JB, Ivanovic M. Comparative dosimetry of dental CBCT devices and 64-slice CT for oral and maxillofacial radiology. *Oral Surg Oral Med Oral Pathol Oral Radiol Endod.* 2008;106:106–114.
25. Leung CC, Palomo L, Griffith R, Hans MG. Accuracy and reliability of cone-beam computed tomography for measuring alveolar bone height and detecting bony dehiscences and fenestrations. *Am J Orthod Dentofacial Orthop.* 2010;137:S109–S119.
26. Timock AM, Cook V, McDonald T, et al. Accuracy and reliability of buccal bone height and thickness measurements from cone-beam computed tomography imaging. *Am J Orthod Dentofacial Orthop.* 2011;140:734–744.
27. Tsutsumi K, Chikui T, Okamura K, Yoshiura K. Accuracy of linear measurement and the measurement limits of thin objects with cone beam computed tomography: effects of measurement directions and of phantom locations in the fields of view. *Int J Oral Maxillofac Implants.* 2011;26:91–100.