

Morphological Characteristics of the Symphyseal Region in Adult Skeletal Class III Crossbite and Openbite Malocclusions

Chooryung Judi Chung^a; Sinae Jung^b; Hyoung-Seon Baik^c

ABSTRACT

Objective: To evaluate the relationship of the morphological characteristics of the symphyseal region of adult Class III malocclusion to the differences in overjet and overbite.

Materials and Methods: The basal and symphyseal widths along with the alveolar and symphyseal heights were evaluated using data from the lateral cephalograms of Korean adult male skeletal Class III, divided into crossbite (n = 28) and openbite (n = 41) groups. Korean male normal occlusion samples (n = 32) were used as controls.

Results: The width of the symphyseal region including the basal width, point B width, Id width, symphyseal thickness, and pogonion width were similar in adult Class III crossbite and normal occlusion groups, but significantly less in the adult Class III openbite group ($P < .001$). The alveolar height was similar in the adult Class III crossbite and control groups, but significantly less in the adult Class III openbite group ($P < .05$). However, the symphyseal height was similar in all three groups.

Conclusions: An openbite, rather than a negative overjet, is the major factor influencing the symphyseal morphology in an adult Class III malocclusion.

KEY WORDS: Symphysis; Overjet; Overbite; Morphology; Skeletal Class III; Adult

INTRODUCTION

The morphology of mandibular symphysis is important because it serves as the primary reference for the esthetics of the facial profile and is a determinant in planning the lower incisor position during orthodontic and orthognathic surgery.^{1,2} The factors associated with the symphyseal growth and morphology include the functional neuroskeletal balance,³ masseter muscle thickness,⁴ mandibular plane angle,^{2,5} overbite,^{3,6,7} lower incisor angle,⁸ occlusal hypofunction and its recovery,⁹ inheritance,¹⁰ and more.

During orthodontic treatment, limiting incisor movement within the bone structure is believed to be es-

sential for achieving better results, stability, and periodontal health, as well as for avoiding root resorption.^{11,12} In particular, in the case of a severe adult skeletal Class III malocclusion, the proper amount of decompensation including the labial inclination of the lower incisors is necessary before orthognathic surgery.¹² On the other hand, lingual inclination of the lower incisors is needed for camouflage treatment. Either way, incisor movement confined within the bone is recommended.¹³

The difference in overbite, such as an openbite and normal overbite, is associated with the dimensions of the symphysis.^{3,6} However, the morphological characteristics of the symphysis combined with the different force vectors loaded to the lower incisors, such as in crossbite and Class III openbite have not been fully evaluated. Therefore, this study focused on the morphological characteristics of the symphyseal region in adult skeletal Class III malocclusion with crossbite or openbite and compared them with normal occlusion.

MATERIALS AND METHODS

The pretreatment digital lateral cephalograms of Korean adult male patients (over the age of 18 years) who visited the Orthodontic Clinic of Yonsei University between 2005 and 2006 were classified into either the

^a Instructor, Department of Orthodontics, College of Dentistry, Yonsei University, Seoul, South Korea.

^b Graduate PhD student, Department of Orthodontics, College of Dentistry, Yonsei University, Seoul, South Korea.

^c Professor, Department of Orthodontics, College of Dentistry, Yonsei University, Seoul, South Korea.

Corresponding author: Dr Hyoung-Seon Baik, Department of Orthodontics, College of Dentistry, Yonsei University, 134 Shinchon-Dong, Seodaemun-gu, Seoul, 120-752 South Korea (e-mail: crchung@yumc.yonsei.ac.kr)

Accepted: December 2006. Submitted: October 2006.

© 2007 by The EH Angle Education and Research Foundation, Inc.

Class III crossbite group (mean age 23.2 ± 4.7 years) or the Class III openbite group (mean age 21.3 ± 3.4 years) according to the molar and incisor relationship. The inclusion criteria of the crossbite group were: Angle Class III molar relationship, negative overjet and overbite, but with incisor contact at maximum intercuspation including the edge-to-edge bite. The inclusion criteria of the Class III openbite group were: Angle Class III molar relationship, negative overjet, but without any incisor contact between the central and lateral incisors. The Class III openbite also included samples with deep vertical incisor overlap, but without incisor contact due to the large reverse overjet (>4 mm). After the primary screening process, the incisor relationship was reconfirmed using the orthodontic casts. Any patient with prior orthodontic treatment, tooth loss, abnormal tooth morphology, congenital disorders, or diseases such as rheumatoid arthritis was excluded.

A total of 28 Class III crossbite and 41 Class III openbite cases were collected for the study. In addition, the lateral cephalograms of Korean adult male with normal occlusion (mean age 20.1 ± 3.2 , $n = 32$) collected at the Craniofacial Deformity Center, Yonsei University, were used as the control. The normal occlusion criteria were: Class I molar and canine relationships, a normal range of overjet (2–4 mm) and overbite (2–4 mm) with incisor contact, good alignment without any missing teeth (total of 28 or more) and no prior orthodontic treatment. The cephalograms of the normal occlusion group were obtained from healthy adult volunteers with informed consent according to the World Medical Association's Declaration of Helsinki.

Digital cephalograms were taken at the dental hospital, College of Dentistry, Yonsei University, using Cranex3+ (Soredex, Helsinki, Finland) and converted as a 12-bit DICOM (Digital Imaging and Communications in Medicine) file. The detection of the cephalometric landmarks was conducted directly on the screen-displayed digital image with a mouse-controlled cursor in connection with the computerized program using V-Ceph software (CyberMed Inc, Seoul, Korea) for cephalometric analysis by two experienced orthodontists.

Additional landmarks and measurements were based on previous reports in order to allow a more comprehensive study of the mandibular structure.^{8,14} The symphyseal landmarks are described in Figure 1.

The cephalometric data of the control, Class III crossbite, and Class III openbite groups were examined by analysis of variance (ANOVA) using statistical software (Statview, Cary, NC). The results are presented as a mean \pm SD. $P < .05$ was considered significant.

Duplicate tracings of all 32 landmarks on 15 ran-

domly chosen cephalograms were done at a 2-month interval by the same examiner. The systemic error was evaluated with a paired t test at $P < .05$. No significance was noted in the measurements of the first and the second evaluation.

RESULTS

Cephalometric Characteristics of the Three Groups

Table 1 provides a summary of the skeletal and dental characteristics of the control, Class III crossbite, and Class III openbite groups. The skeletal features of the Class III crossbite group in the anterior-posterior dimension were similar to those of the skeletal Class III openbite group, with a larger SNB, gonial angle, and mandibular body length compared with the control group ($P < .05$). The skeletal Class III openbite group showed higher values for vertical dimension measurements such as the gonial angle, mandibular plane angle, and facial height ratio than the control and Class III crossbite groups ($P < .05$).

The Width of the Symphysis Is Narrower in Class III Openbite

The basal width, point B width, and Id width were similar in the control and Class III crossbite groups. However, the basal width, pogonion width, and Id widths were all significantly lower in the Class III openbite group than in the control and Class III crossbite groups ($P < .05$; Figure 2A; Table 2).

The width parameters distant from the teeth also indicated a similar pattern. While the symphyseal thickness and pogonion width were similar in the control and the Class III crossbite groups, they were significantly lower in the Class III openbite group ($P < .01$; Figure 2B; Table 2).

The Height of the Alveolar Bone Was Lower in the Class III Openbite

The alveolar height was similar in the control and the Class III crossbite groups. However, it was significantly lower in the Class III openbite group ($P < .0001$; Figure 2B; Table 2). The symphyseal height was similar in all three groups. The total height of the symphyseal region was similar in the control and Class III crossbite groups, but was significantly lower in the Class III openbite group ($P < .05$; Figure 3; Table 2).

DISCUSSION

The mandibular bone is strongly influenced by the masticatory function.^{15–18} In particular, the maxillofacial region contains essentially membranous bone and is

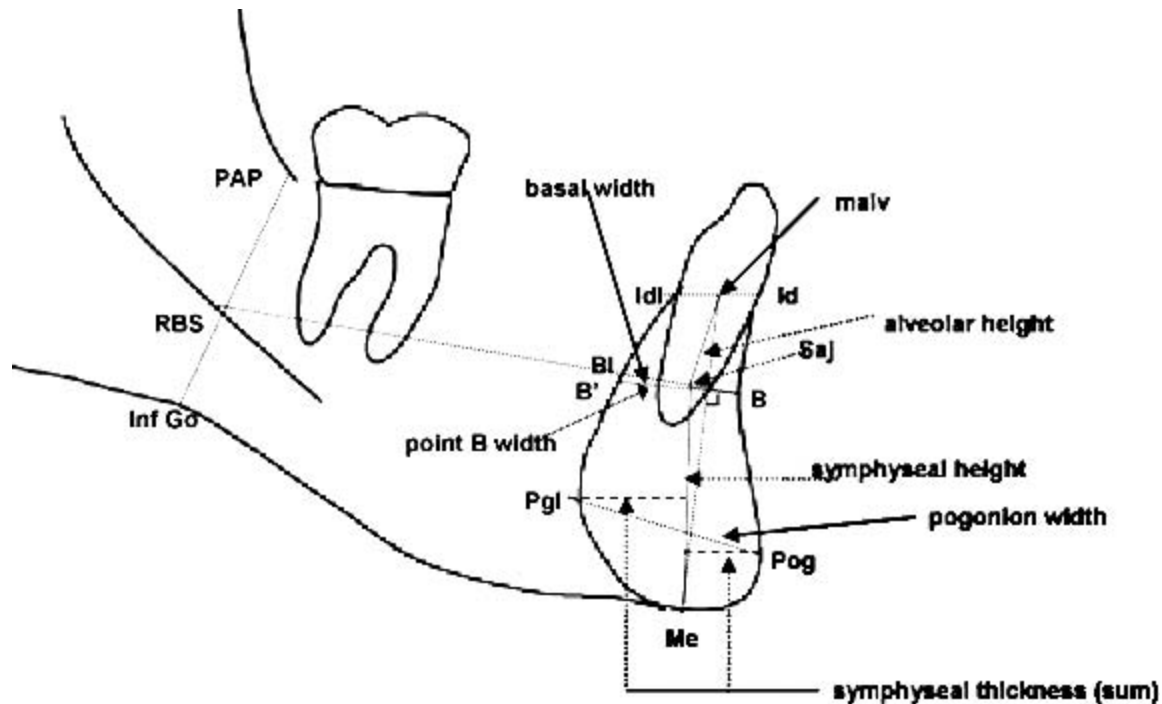


Figure 1. Landmarks and measurements of the symphyseal region. Conventional mandibular landmarks: *Me*, menton; *Pg*, pogonion; *B*, supramentale; *Id*, infradentale; *Idl*, lingual point infradentale. Landmarks based on Suri et al¹⁴: *PAP*, posterior alveolar point, most posteroinferior midplaned point on the anterior border of the ascending ramus; *Inf Go*, inferior gonion, midplaned point on the lower border of the mandible where the convexity at *Go* merges with the concavity of the antegonial notch; *RBS*, ramus body syncline, the point of intersection of a line drawn from *Inf Go* to *PAP* with the cortical outline of the midplaned mandibular nerve; *Bl*, lingual point B, the point of intersection of a line drawn from *RBS* to *B*, with the lingual contour of symphysis; *saj*, symphysis-alveolar junction, the midpoint of a line drawn from *Bl* to *B*; *Pgl*, lingual point pogonion, the highest point on the lingual contour of the symphysis, located by the greatest perpendicular distance from a line drawn from the *saj* to *Me*; *malv*, (midpoint of anterior alveolus), midpoint of a line drawn from *Idl* to *Id*. Landmark base on Nojima et al⁶: *B'*, point on the lingual outline of the symphysis drawn from *B* perpendicular to a line connecting *malv* to *Me*. Mandibular measurements: *alveolar height*, length of a line drawn from *malv* to *saj*; *symphyseal height*, length of a line drawn from *saj* to *Me*; *symphyseal thickness*, the sum of the lengths of the perpendiculars dropped from *Pg* and *Pgl* to a line drawn from *saj* to *Me*; *basal width*, length of a line drawn from *Bl* to *B*.

Table 1. Dental and Skeletal Characteristics of the Control, Class III Crossbite, and Class III Openbite Groups (Mean \pm SD)^a

Measurements	Control (n = 32)		Crossbite (n = 28)		<i>P</i>	Openbite (n = 41)		
	Mean	SD	Mean	SD		Mean	SD	<i>P</i>
Age	20.1	3.2	23.2	4.7		21.3	3.4	
SNA	82.6	2.7	81.3	3.8		80.1	3.6	<i>a</i>
SNB	80.0	3.0	84.3	3.6	<i>a</i>	83.8	4.8	<i>a</i>
ANB difference	2.5	2.1	-3.0	1.9	<i>a</i>	-3.7	3.0	<i>a</i>
Saddle angle	125.4	3.7	122.8	7.0		122.4	4.9	<i>a</i>
Articular angle	147.8	6.3	146.6	8.9		145.1	5.1	
Gonial angle	118.1	7.1	121.5	6.5	<i>a</i>	128.8	6.1	<i>a,b</i>
Anterior cranial base length, mm	74.3	3.1	73.1	3.4		73.1	3.8	
Posterior cranial base length, mm	40.2	3.1	40.0	3.7		39.2	2.9	
Ramal height (mm)	59.7	6.4	60.7	5.4		59.2	5.9	
Mandibular body length, mm	83.6	5.3	87.1	4.2	<i>a</i>	87.9	5.3	<i>a</i>
FH to Mn.plane angle	22.4	5.2	22.6	5.4		27.8	5.3	<i>a,b</i>
Posterior facial height (PFH), mm	96.1	7.5	96.3	6.8		94.1	6.1	
Anterior facial height (AFH), mm	138.6	6.0	139.9	6.9		145.5	6.0	<i>a,b</i>
Facial height ratio	0.7	0.0	0.7	0.0		0.6	0.0	<i>a,b</i>
U1 to SN	108.2	5.9	111.1	6.8		109.6	6.3	
IMPA	97.2	7.3	87.5	7.0	<i>a</i>	81.8	7.3	<i>a,b</i>
Interincisal angle	123.3	8.5	130.4	7.9	<i>a</i>	132.3	8.9	<i>a</i>

^a *a* indicates statistical significance from the control; *b* indicates statistical significance between the crossbite and openbite with *P* < .05.

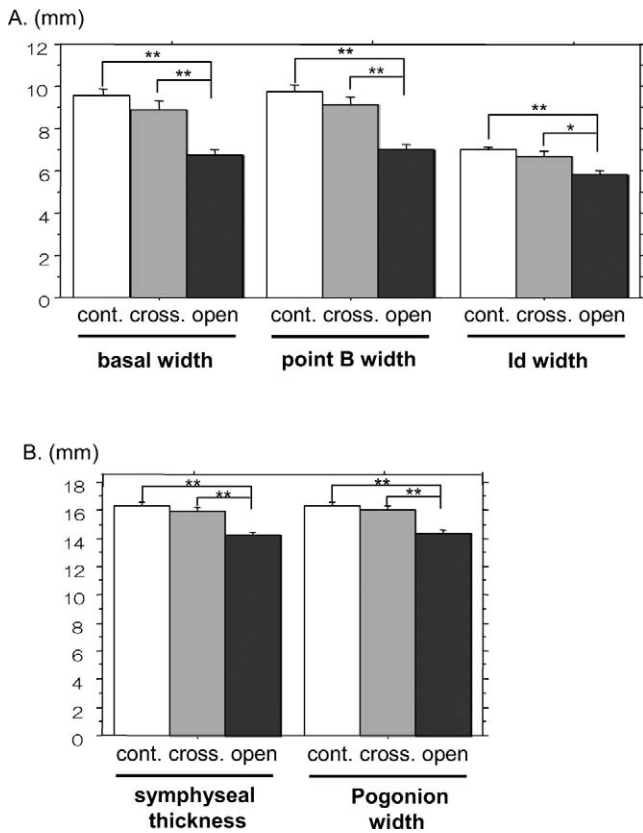


Figure 2. The symphyseal thickness is thinner in Class III openbite. Basal width, point B width, and ld width (A) along with the symphyseal thickness and pogonion width (B) were similar in the control and crossbite groups, while all the measured parameters were significantly lower in the Class III openbite. The data are expressed as mean ± SD. Statistical significance compared to the control with *P < .05 and **P < .0001.

more susceptible to environmental factors such as the stimulating influence of muscles and extrafunctional forces.^{4,19} During the power stroke of mastication, the middle and lower third of the labial aspect of the symphysis is predominantly sheared dorsoventrally, twisted and bent¹⁶ according to the magnitude and position of the bite force.^{15,17} Therefore, it was hypothesized that, due to the difference in bite force direction of the

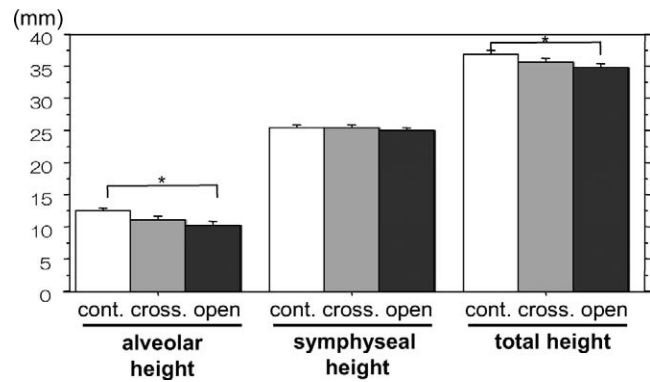


Figure 3. The alveolar height is lower in the Class III openbite. Although the alveolar height and total height was significantly lower in the Class III openbite than in the control and crossbite groups, the symphyseal height was similar in all three groups. The data are expressed as mean ± SD. Statistical significance compared to the control with *P < .05.

mandibular incisors, the morphological characteristics of the mandibular symphysis can vary between the normal overjet/overbite and crossbite, and a negative overjet but with a positive overbite. The difference in the Class III openbite was also evaluated because the overbite is reported to be one of the major factors influencing the symphyseal dimension. The width and height of the mandibular symphysis was only significantly lower in the Class III openbite group indicating that overbite rather than the overjet was the major influencing factor.

Earlier studies on the morphology of the symphyseal region in adult Japanese samples based on the divergence of the mandibular plane angle reported that the alveolar bone thickness negatively correlated with the mandibular plane angle, while the symphyseal thickness distant from the incisors near the base of the mandible was rather stable.^{2,8} However, our results clearly indicate a decrease in thickness not only in the alveolar bone region, but also in the symphyseal thickness in the case of the Class III openbite. This suggests that the basal bone of the symphyseal region can also show an adaptive alteration to achieve a

Table 2. Symphyseal Dimension of the Control, Class III Crossbite, and Class III Openbite Groups (Mean ± SD)^a

Measurements	Control (n = 32)		Crossbite (n = 28)			Openbite (n = 41)		
	Mean	SD	Mean	SD	P	Mean	SD	P
Basal width (B-BI)	9.58	1.85	8.88	1.84	.21	6.74	1.64	** <.0001
Point B width (B-B')	9.76	1.77	9.08	1.94	.25	6.98	1.93	** <.0001
ld width (ld-ldl)	6.98	0.76	6.71	0.94	.47	5.83	1.20	** <.0001
Symphyseal thickness (sum)	16.35	1.32	15.82	1.48	.29	14.22	1.45	** <.0001
Pogonion width (Pog-Pgl)	16.29	1.47	15.79	1.58	.71	14.38	1.49	** <.0001
Alveolar height (malv-Saj)	12.45	2.08	10.88	2.87	.06	10.12	4.01	* <.05
Symphyseal height (Saj-Me)	25.48	1.83	25.39	1.93	.68	25.06	2.49	.42
Total height (malv-Me)	36.93	2.78	35.52	2.52	.22	34.78	3.49	* <.05

^a * P < .05; ** P < .0001.

functional neuroskeletal balance in the craniofacial complex due to the absence of an incisor contact.^{3,4,6,9}

Patients with a vertical growth pattern, openbite, and high mandibular plane angle were reported to have a similar⁸ or larger vertical dimension of the symphysis.^{2,6} However, these results were rather conflicting. The alveolar height and total height of the symphyseal region were lower in the Class III openbite in our study. The bone actively responds to loading or mechanical stimulation and undergoes remodeling.^{20–24} In the case of a long bone, the amount of bone formation is lower during unloading while the amount of bone resorption is higher resulting in a decrease in the total bone mass.^{24–26} In the maxillofacial region, the absence of incisor contact can induce compensatory tooth eruption along with the elongation of the alveolar bone, which causes an increase in the alveolar height, particularly in growing adolescents as previously reported.^{9,27–30}

In contrast, in the cases of tooth loss, infraocclusion due to ankylosis or denture wear, vertical height and bone volume of the alveolar bone may also decrease in the long term.^{31–35} Therefore, the net result of the bone dimension in response to a prolonged openbite is quite difficult to define. Compared with many studies on the morphological characteristics of openbite malocclusion in adolescents, this study mainly focused on adult samples. The compensatory lengthening of the lower anterior alveolar height was reported to be limited.³⁰ Therefore, it is possible that the persistence of the openbite and the loss of incisor contact/function in the long term, as our adult samples might have caused a decrease in the vertical dimension of the alveolar bone region.

Differing from the symphyseal width, the symphyseal height was similar in the Class III openbite group and control. The attachment of the geniohyoid and genioglossus muscle at the basal level of the symphyseal area with muscle activation during oral function might have influenced this result. Parafunctional habits including the tongue, have also been reported to be associated with the compensatory mechanism of a high angle malocclusion.²⁸ However, this limited study did not include evaluation parameters for the tongue or the soft tissue.

Recently, occlusal hypofunction was shown to suppress alveolar and jaw bone formation while its recovery induced an enhancement in bone formation. This suggests the positive influence of occlusal function on alveolar and jaw bone formation during the growth period.⁹ Clinically, early treatment for a skeletal Class III malocclusion is quite controversial due to the unpredictable growth of the mandible. It would be interesting to determine if early intervention during the growth period to recover or to maintain the overbite would at

least enhance the thickness of the symphysis in the long term, even though it may not be sufficient to fully compensate for the anterior-posterior discrepancy.

CONCLUSIONS

- The width of the symphyseal region is similar in adult Class III crossbite and normal occlusion groups, but significantly lower in the adult Class III openbite group.
- The alveolar height is similar in the adult Class III crossbite and control groups, but significantly lower in the adult Class III openbite group. However, the symphyseal height was similar in all three groups.
- This suggests that unloading due to the openbite, rather than a negative overjet, is the major factor influencing the symphyseal morphology in an adult Class III malocclusion.

ACKNOWLEDGMENT

This study was supported by the Craniofacial Deformity Center of Yonsei University Dental Hospital

REFERENCES

1. Buschang PH, Julien K, Sachdeva R, Demirjian A. Childhood and pubertal growth changes of the human symphysis. *Angle Orthod.* 1992;62:203–210.
2. Tanaka R, Suzuki H, Maeda H, Kobayashi K. Relationship between an inclination of mandibular plane and a morphology of symphysis [in Japanese]. *Nippon Kyosei Shika Gakai Zasshi.* 1989;48:7–20.
3. Haskell BS. The human chin and its relationship to mandibular morphology. *Angle Orthod.* 1979;49:153–166.
4. Kubota M, Nakano H, Sanjo I, Satoh K, Sanjo T, Kamegai T, Ishikawa F. Maxillofacial morphology and masseter muscle thickness in adults. *Eur J Orthod.* 1998;20:535–542.
5. Eroz UB, Ceylan I, Aydemir S. An investigation of mandibular morphology in subjects with different vertical facial growth patterns. *Aust Orthod J.* 2000;16:16–22.
6. Ceylan I, Eroz UB. The effects of overbite on the maxillary and mandibular morphology. *Angle Orthod.* 2001;71:110–115.
7. Beckmann SH, Kuitert RB, Prah-Anderesen B, Segner D, The RP, Tuinzing DB. Alveolar and skeletal dimensions associated with overbite. *Am J Orthod Dentofacial Orthop.* 1998;113:443–452.
8. Nojima K, Nakakawaji K, Sakamoto T, Isshiki Y. Relationships between mandibular symphysis morphology and lower incisor inclination in skeletal class III malocclusion requiring orthognathic surgery. *Bull Tokyo Dent Coll.* 1998;39:175–181.
9. Shimomoto Y, Iwasaki Y, Chung CY, Muramoto T, Soma K. Effects of occlusal stimuli on alveolar/jaw bone formation. *J Dent Res.* 2007;86:47–51.
10. Garn SM, Lewis B, Vicinus JH. The inheritance of symphyseal size during growth. *Angle Orthod.* 1963;33:222–231.
11. Handelman CS. The anterior alveolus: its importance in limiting orthodontic treatment and its influence on the occurrence of iatrogenic sequelae. *Angle Orthod.* 1996;66:95–110.
12. Proffit WR, Whilte RPJ, Sarver DM. *Contemporary Treat-*

- ment of *Dentofacial Deformity*. New York, NY: Elsevier Inc; 2003.
13. Mulie RM, Hoeve AT. The limitations of tooth movement within the symphysis studied with laminagraphy and standardized occlusal films. *J Clin Orthod*. 1976;10:882–893, 886–889.
 14. Suri S, Ross RB, Tompson BD. Mandibular morphology and growth with and without hypodontia in subjects with Pierre Robin sequence. *Am J Orthod Dentofacial Orthop*. 2006;130:37–46.
 15. Hylander WL. In vivo bone strain in the mandible of Galago crassicaudatus. *Am J Phys Anthropol*. 1977;46:309–326.
 16. Hylander WL. Stress and strain in the mandibular symphysis of primates: a test of competing hypotheses. *Am J Phys Anthropol*. 1984;64:1–46.
 17. Koriath TW, Hannam AG. Deformation of the human mandible during simulated tooth clenching. *J Dent Res*. 1994;73:56–66.
 18. Koriath TW, Hannam AG. Mandibular forces during simulated tooth clenching. *J Orofac Pain*. 1994;8:178–189.
 19. Dulkan J. Secondary cartilage: a misnomer? *Am J Orthod*. 1972;62:15–41.
 20. Currey JD. The many adaptations of bone. *J Biomech*. 2003;36:1487–1495.
 21. Burger EH, Klein-Nulend J. Microgravity and bone cell mechanosensitivity. *Bone*. 1998;22:127S–130S.
 22. Vico L, Lafage-Proust MH, Alexandre C. Effects of gravitational changes on the bone system in vitro and in vivo. *Bone*. 1998;22:95S–100S.
 23. Frost HM. Wolff's Law and bone's structural adaptations to mechanical usage: an overview for clinicians. *Angle Orthod*. 1994;64:175–188.
 24. Rodan GA. Mechanical loading, estrogen deficiency, and the coupling of bone formation to bone resorption. *J Bone Miner Res*. 1991;6:527–530.
 25. Bikle DD, Halloran BP. The response of bone to unloading. *J Bone Miner Metab*. 1999;17:233–244.
 26. Ishijima M, Rittling SR, Yamashita T, Tsuji K, Kurosawa H, Nifuji A, Denhardt DT, Noda M. Enhancement of osteoclastic bone resorption and suppression of osteoblastic bone formation in response to reduced mechanical stress do not occur in the absence of osteopontin. *J Exp Med*. 2001;193:399–404.
 27. Beckmann SH, Segner D. Changes in alveolar morphology during open bite treatment and prediction of treatment result. *Eur J Orthod*. 2002;24:391–406.
 28. Betzenberger D, Ruf S, Pancherz H. The compensatory mechanism in high-angle malocclusions: a comparison of subjects in the mixed and permanent dentition. *Angle Orthod*. 1999;69:27–32.
 29. Fields HW, Proffit WR, Nixon WL, Phillips C, Stanek E. Facial pattern differences in long-faced children and adults. *Am J Orthod*. 1984;85:217–223.
 30. Kuitert R, Beckmann S, Van Loenen M, Tuinzing B, Zentner A. Dentoalveolar compensation in subjects with vertical skeletal dysplasia. *Am J Orthod Dentofacial Orthop*. 2006;129:649–657.
 31. Schwartz-Dabney CL, Dechow PC. Edentulation alters material properties of cortical bone in the human mandible. *J Dent Res*. 2002;81:613–617.
 32. Carlsson GE. Responses of jawbone to pressure. *Gerodontology*. 2004;21:65–70.
 33. Bodic F, Hamel L, Lerouxel E, Basle MF, Chappard D. Bone loss and teeth. *Joint Bone Spine*. 2005;72:215–221.
 34. Saffar JL, Lasfargues JJ, Cherruau M. Alveolar bone and the alveolar process: the socket that is never stable. *Periodontol 2000*. 1997;13:76–90.
 35. Karkazis HC, Lambadakis J, Tsihlikis K. Cephalometric evaluation of the changes in mandibular symphysis after 7 years of denture wearing. *Gerodontology*. 1997;14:101–105.