

Case Report

Distal Movement of Maxillary Molars Using a Lever-arm and Mini-implant System

Seung-Min Lim^a; Ryoon-Ki Hong^b

ABSTRACT

Recently, many studies have been reported on distal molar movement using temporary anchorage devices. However, the side effects of distal movement, such as distal tipping, rotation, or extrusion, are still unsolved. This article describes the use of the lever-arm and mini-implant system for controlled distal movement of maxillary molars and two clinical cases in which patients were treated with this system. Mini implants are needed to control the point of force application in the posterior area with no anchorage loss. When the length of the lever arm and the position of the mini implant are adjusted, the desired line of action of the distal force is determined with respect to the center of resistance of maxillary molars. The lever-arm and mini-implant system is useful not only for absolute anchorage, but also for three-dimensional control during distal movement of the upper molars.

KEY WORDS: Molar distal movement; Absolute anchorage; Lever-arm and mini-implant system; Line of action of the distal force; Center of resistance

INTRODUCTION

Since the early 1980s, intraoral appliances for distal molar movement have been introduced to minimize the need for patient compliance. These include the repelling magnet,¹⁻⁵ coil springs on a continuous arch wire,^{6,7} superelastic nickel-titanium arch wires,⁸ coil springs on a sectional arch wire (Jones jig,⁹⁻¹³ distal jet,¹⁴⁻¹⁶ Keles slider^{17,18}), and springs in beta titanium alloy (pendulum,¹⁹⁻²⁵ K-loop,²⁶ intraoral bodily molar distalizer²⁷).

Intraoral distal force appliances are designed to apply continuous reciprocal forces on maxillary molars, which also cause mesial reactive forces on the anterior anchoring teeth. Thus, anchorage loss, such as upper protrusion or increased overjet, also occurs. In addition, the distal tipping^{10-13,15,16,20-23,25,27} and extrusion^{10-15,20,23,24,27} of the maxillary first molar have been reported to occur when molars are moved distally with a conventional intraoral appliances.

Recently, many studies on distal molar movement using temporary anchorage devices have been re-

ported. Byloff et al²⁸ designed a Graz implant-supported pendulum appliance. Keleş et al²⁹ used a Keles slide appliance with osseointegrated palatal implant, instead of a Nance button. Carano et al³⁰ devised a distal-jet combined with a miniscrew anchorage system. Karaman et al³¹ and Gelgör et al³² combined distal force mechanics using a compressed coil spring with an intraosseous screw. Kircelli et al³³ used a pendulum appliance with an intraosseous screw. During upper molar distal movement, the temporary anchorage devices prevent side effects on anterior anchoring teeth by eliminating reactive forces from the distal force appliances. However, the side effects of the distal movement of teeth, such as distal tipping, rotation, or extrusion, are still unresolved.

The purpose of this report is to introduce a new distal force system that prevents the side effects on the upper molar caused by conventional distal movement systems and to demonstrate the effectiveness of this new system in two clinical cases.

Application of the Lever-Arm and Mini-Implant System

Case 1

A 27-year-old Korean woman presented with the chief complaint of severely rotated maxillary canine teeth. The patient exhibited the straight profile and Angle Class II molar relationship (Figure 1). Arch forms

^a Private practice, Seoul, South Korea.

^b Department Head, Chong-A Dental Hospital, Orthodontics, Seoul, South Korea.

Corresponding author: Dr Seung-Min Lim, S dental clinic, No. 666-6, Sinsa Dong, Gangnam-Gu, Seoul, 135-897, South Korea (e-mail: sm720928@hotmail.com)

Accepted: December 2006. Submitted: October 2006.

© 2008 by The EH Angle Education and Research Foundation, Inc.

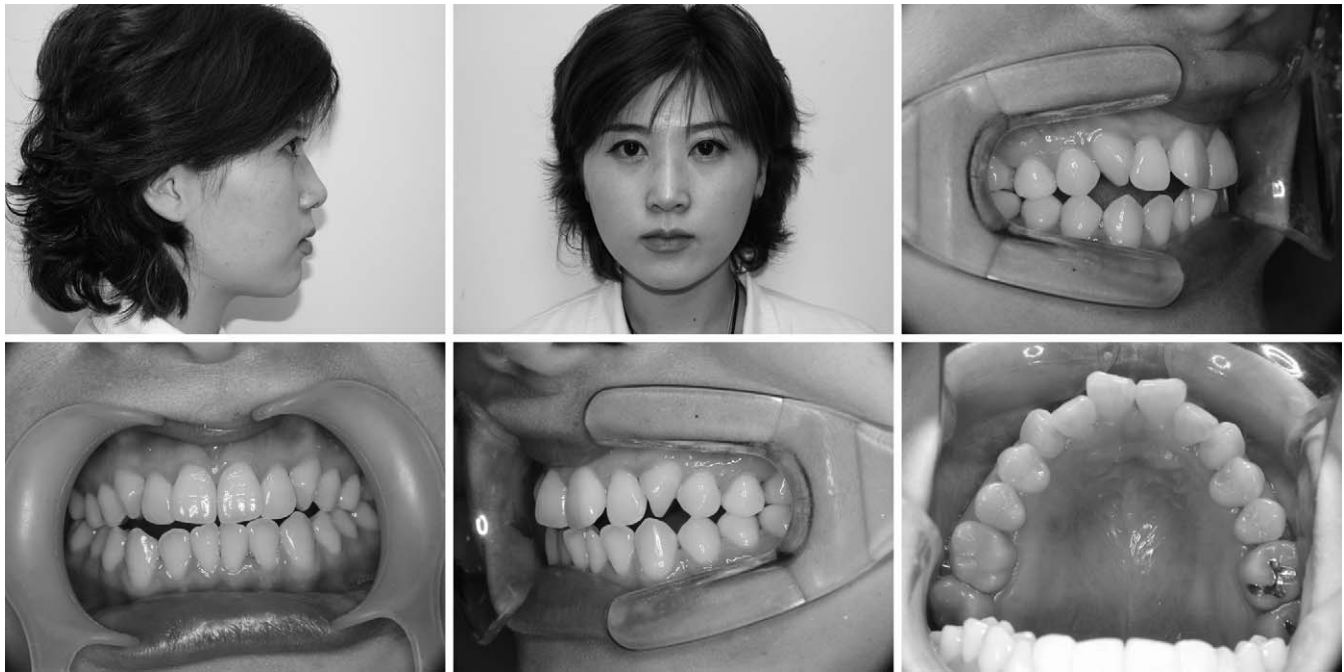

Figure 1. Pretreatment facial and intraoral photographs.

of upper and lower arches were tapered and ovoid, respectively, and an anterior open bite was observed. There were 7.5-mm and 1.8-mm arch-length discrepancies in the upper and lower arches, respectively. Cephalometric analysis disclosed a Class II skeletal relationship and a dolichofacial pattern (Table 1).

Our treatment plan was to use the lever-arm and mini-implant system for maxillary distal molar movement to correct the Class II molar relationship and to resolve maxillary crowding.

Because openbite and a hyperdivergent pattern were observed, the extrusion of the molar during distal

movement would lead to the clockwise rotation of the mandible. Thus, the vertical levels of all the mini-implant heads and lever arms were adjusted to have an intrusive force applied during distal movement (Figure 2). With elastic chain modules, 150 g force was bilaterally applied from the buccal side, and 300 g force was applied from the palatal side. In addition, a 0.9-mm stainless steel transpalatal arch (TPA) was expanded to correct bilateral upper posterior dental constriction and fixed appliances were bonded on the mandibular dentition.

After six months a super Class I molar relationship was achieved. The buccal mini implants were removed, fixed appliances were bonded on the maxillary dentition, and aligning and leveling were carried out. To prevent relapse of the distal molar movement and expansion, a TPA was kept in the mouth, and a mild force was continuously applied from the palatal mini implant.

During the distal movement and expansion of the upper molars, torque control of the upper first molar was achieved with a TPA and palatal intrusive force. However, because the palatal intrusive force was not applied to the upper second molar, there was concern that the relatively low position of the lingual cusp of the upper second molar could create possible balancing interference and could result in inadequate settling of the posterior occlusion. Therefore, during the second stage of the fixed orthodontic therapy, distal extension hooks were bonded to the TPA and lingual buttons were bonded to lingual side of the upper sec-

Table 1. Cephalometric Summary

Measurement ^a	Pretreatment	Posttreatment
Skeletal		
SNA (°)	75.3	75.3
SNB (°)	71.3	72.4
ANB (°)	4	2.9
FMA (°)	31.4	30.2
NPo-FH (°)	87.7	88.2
Dental		
U ₁ to FH (°)	110	113.9
FMIA (°)	58.1	54.2
Overbite (mm)	-1	2
Overjet (mm)	2.9	4.2
MO-MS (mm)	25	23.5
Soft tissue		
Upper lip to E-line (mm)	0.3	-1.1
Lower lip to E-line (mm)	0.1	0

^a MO-MS is the perpendicular dropped from the mesial cusp of the maxillary first molar onto the palatal plane.

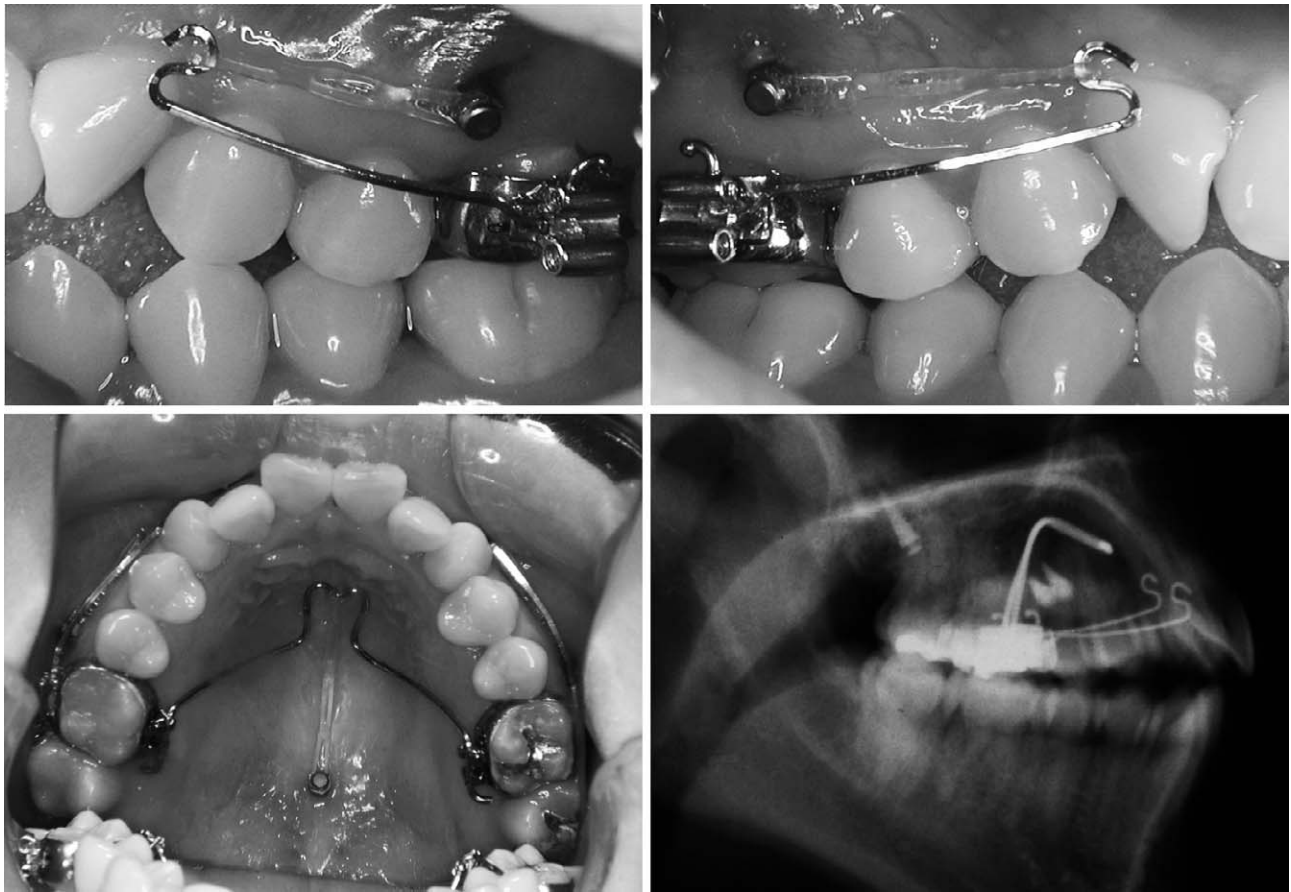


Figure 2. Lever-arm and mini-implant system established in maxillary arch. The vertical levels of all the mini-implant heads and lever-arms were adjusted to have intrusive force applied during distal molar movement.

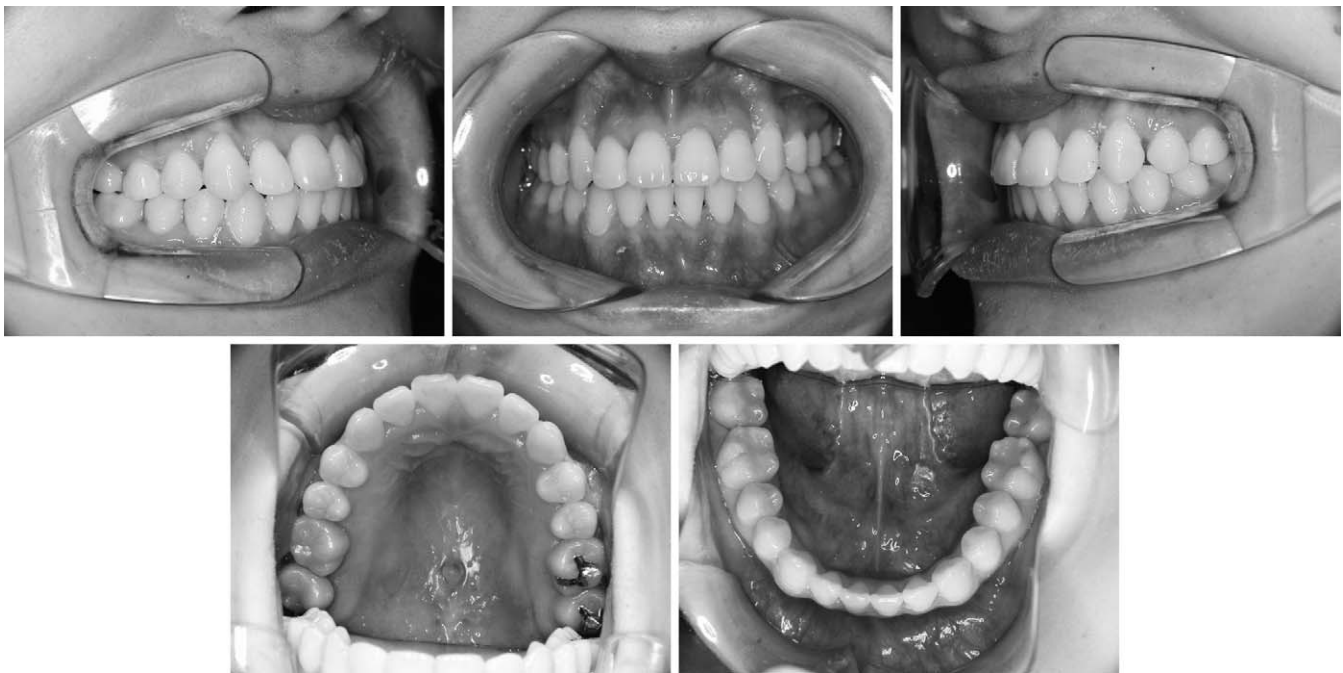

Figure 3. Posttreatment intraoral photographs.

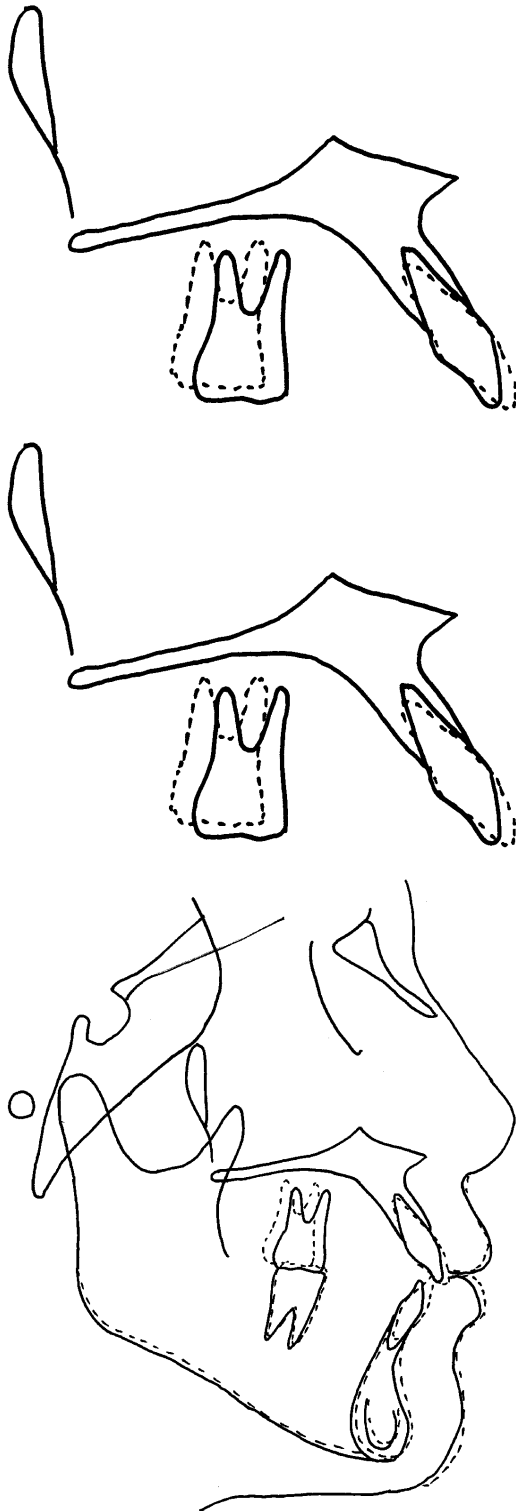


Figure 4. Superimpositions of cephalometric tracings before and after treatment.

ond molars. After the TPA was inserted, an elastic chain module was put between the hook and the button for intrusion of the palatal cusp of the upper second molar.

The fixed appliances were debonded 14 months after the treatment started. An ideal Class I canine and molar relationship was achieved with normal overbite and overjet (Figure 3). On the cephalometric superimposition before and after treatment, 3.4 mm bodily distal movement and 1.5 mm of intrusion of the maxillary molars were achieved and a slight upward and forward rotation of mandible was obtained (Figure 4).

Case 2

A 26-year-old Korean man presented with the chief complaint of upper anterior spacing and lip protrusion. The patient exhibited a convex profile and Angle Class II division 1 malocclusion (Figure 5). Maxillary right and left lateral incisors were peg laterals. Maxilla spacing was 6.0 mm, and there was a 3.5-mm arch-length discrepancy in the mandible; the lower right first molar was positioned 2.0 mm mesially to the left molar. Cephalometric analysis disclosed a Class II skeletal relationship and a mesofacial pattern (Table 2).

Our first treatment plan was extracting the upper first and lower second premolars. However, the patient refused to have the premolars extracted. Alternatively, we planned to move the upper molars distally, parallel to the occlusal plane, and to apply a distal force to the lower right molar from the buccal side with the lever-arm and mini-implant system. The fixed appliances were bonded to the upper anterior teeth and lower dentitions, and the molars were moved distally as mentioned (Figure 6).

After seven months, a super Class I molar relationship was achieved. However, the maxillary first molars were moved to the distal with a slight distal tipping. The buccal mini implants were removed and the fixed appliances were bonded on the upper premolars to align and level the maxillary dentition. To induce distal root movement of the tipped upper first molars, a distal force was applied with the midpalatal mini-implant and palatal lever-arm system.

The treatment advanced for another eight months and ended after 15 months of active treatment. After the treatment, the convex profile was improved, and satisfactory occlusion was achieved (Figure 7). The superimposition of cephalometric tracings before and after treatment showed 3.9 mm of bodily distal movement of the maxillary molars without an increase in the mandibular plane angle (Figure 8).

Lever-Arm and Mini-Implant System Construction

As depicted in Figure 9, the first maxillary molars were banded with a 0.022-inch double combination tube welded on the buccal side and a 0.032×0.032 -inch lingual bracket on the palatal side. Also, the maxillary second molars were bonded with a 0.022-inch

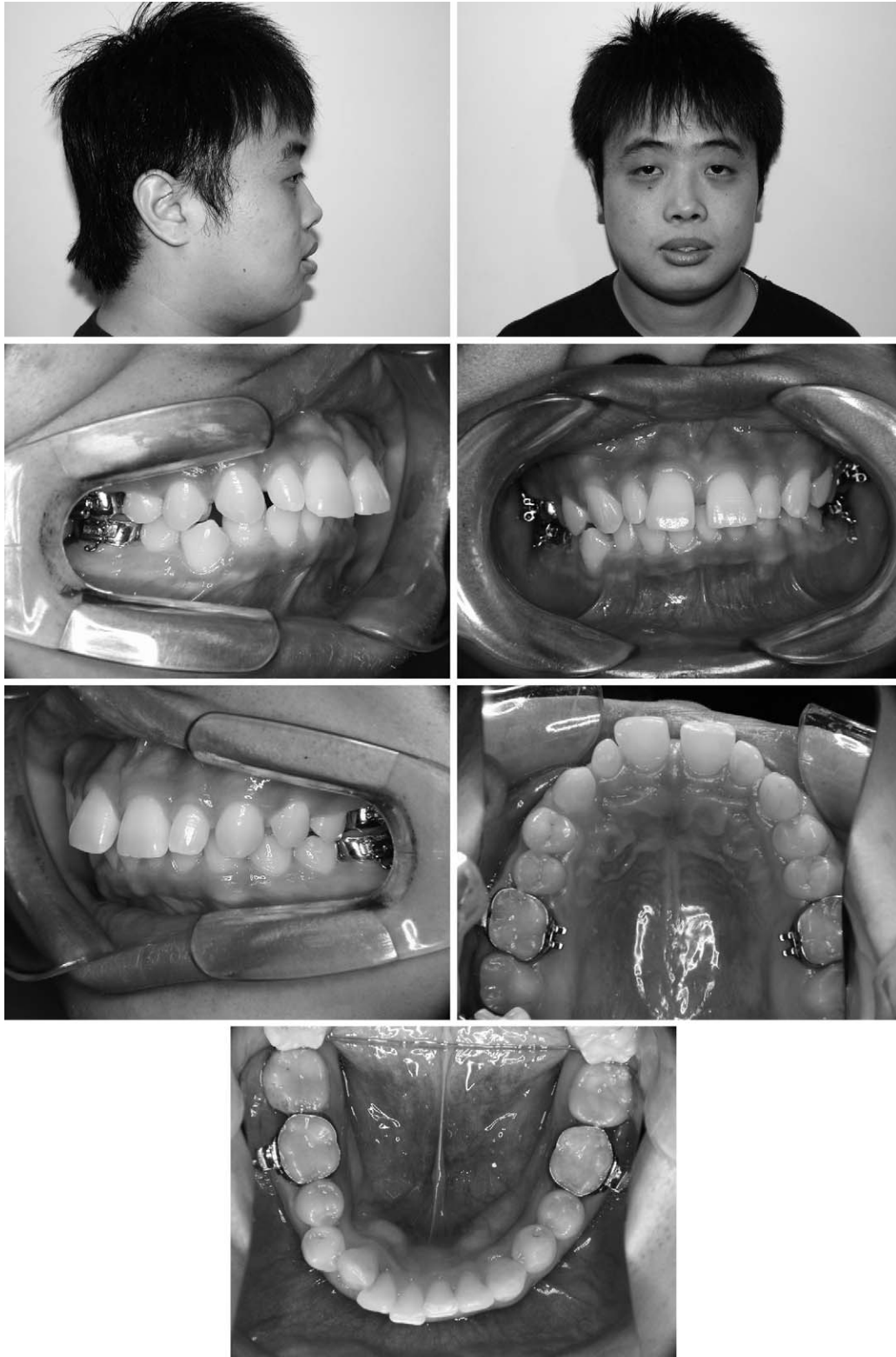


Figure 5. Pretreatment facial and intraoral photographs.

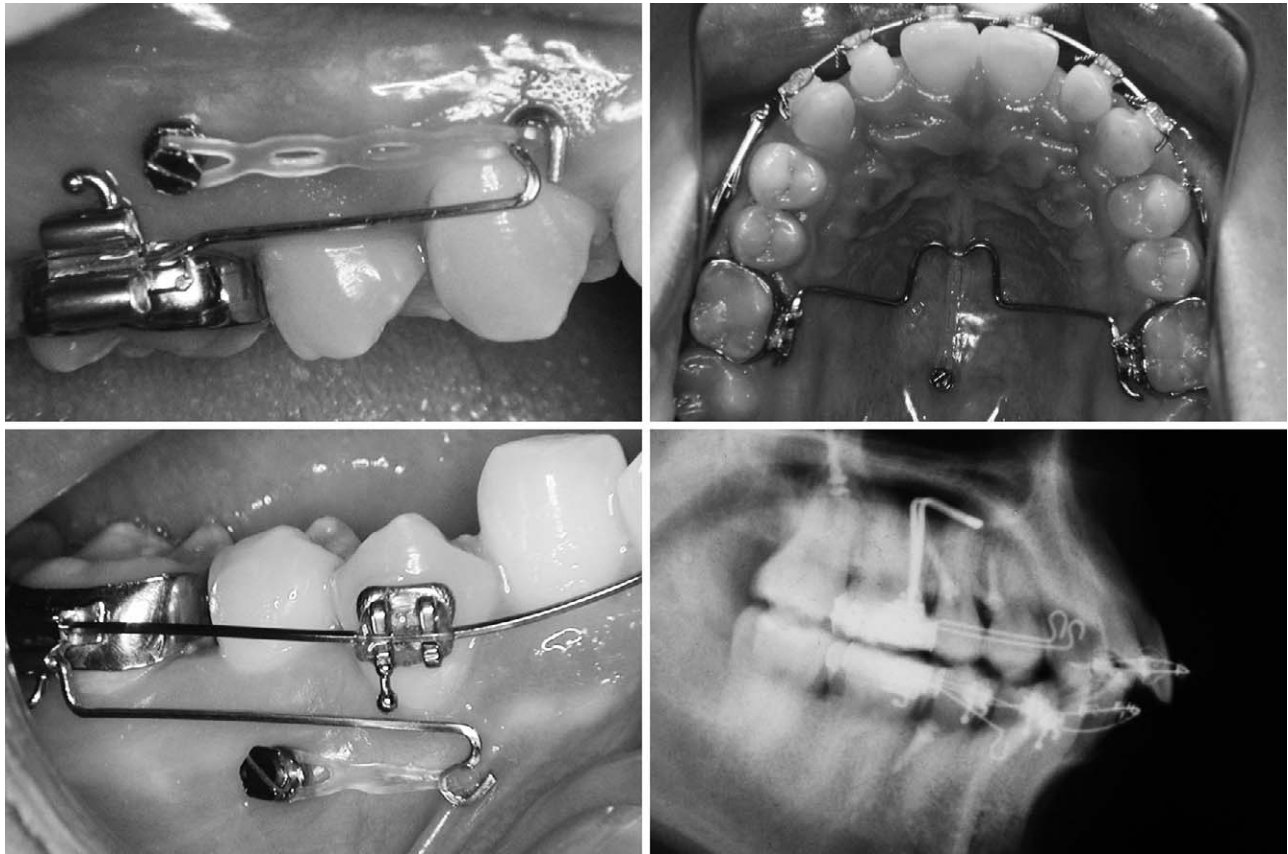


Figure 6. Lever-arm and mini-implant system established in upper and lower arch.

tube. A 0.032×0.032 -inch or 0.9-mm stainless steel TPA was used as the palatal lever arm. When a 0.9-mm stainless steel TPA is used, the portion engaged in the lingual bracket is ground with a green stone bur

to reduce the diameter of the 0.9-mm stainless steel wire. The buccal lever arm was made of 0.019×0.025 -inch stainless steel wire.

The mini implants were inserted manually with a

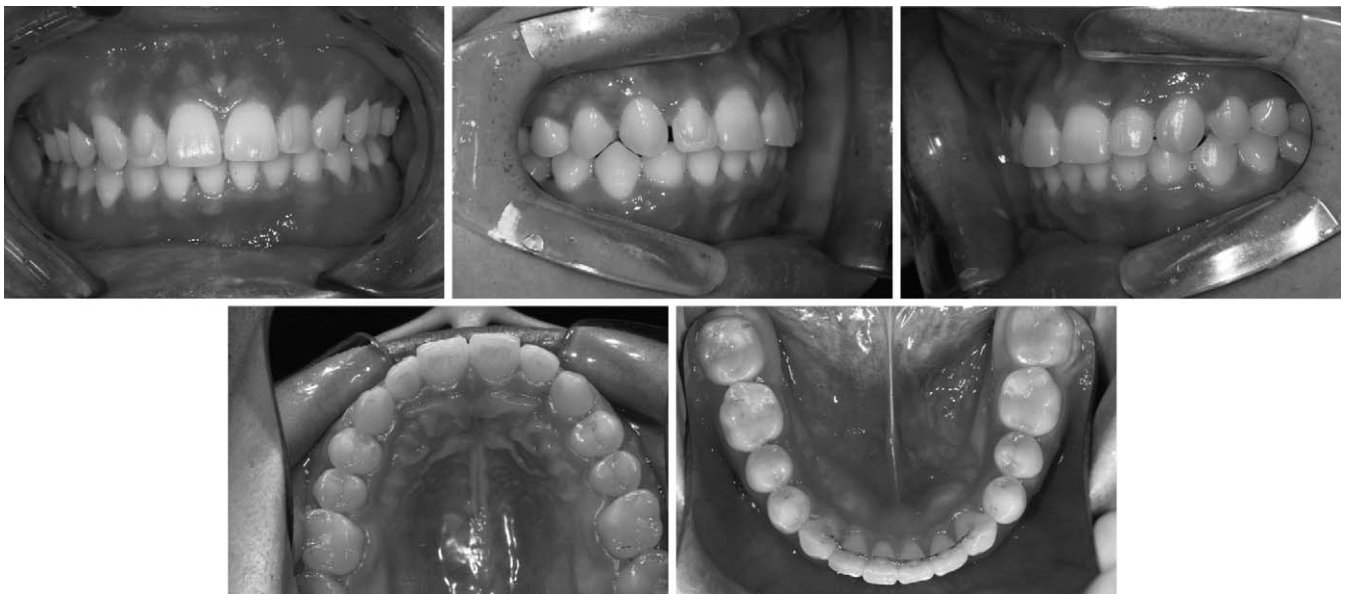


Figure 7. Posttreatment intraoral photographs.

Table 2. Cephalometric Summary

Measurement ^a	Pretreatment	Posttreatment
Skeletal		
SNA (°)	81.9	81.6
SNB (°)	77.4	76.9
ANB (°)	4.5	4.7
FMA (°)	15.2	15.5
NPo-FH (°)	91.9	91.2
Dental		
U ₁ to FH (°)	127.7	116.9
FMIA (°)	51.3	54.2
Overbite (mm)	5.3	2.1
Overjet (mm)	7.3	3.5
MO-MS (mm)	28	28
Soft tissue		
Upper lip to E-line (mm)	4.4	2.1
Lower lip to E-line (mm)	6.9	5.1

^a MO-MS is the perpendicular dropped from the mesial cusp of the maxillary first molar onto the palatal plane.

screwdriver under local anesthesia directly through the mucosa without any flap dissection. The positions of the mini implants and the buccal and palatal lever arms were determined by referring to the lateral cephalogram and the maxillary model.

Biomechanics

It is almost impossible to apply direct orthodontic force to the center of resistance of the tooth. A simple and effective method for translation is to apply two forces at some distance from the center of resistance. If the resultant force passes through the center of resistance, bodily movement is acquired. By applying one force on the crown from the buccal side and applying the other force on the root apex level from the palatal side, the resultant force may pass through the center of resistance and cause no rotational movement.

Following this principle, lever-arm and mini-implant systems were constructed on the buccal and palatal sides to produce a desirable distal force (Figure 9). If the buccal and palatal distal force passes through the center of resistance of the molar and is parallel to the occlusal plane, bodily movement is obtained (Figure 9A). As shown in Figure 9B, the bodily movement accompanying intrusion was achieved by adjusting the length of the lever arms and the position of the mini implants on the buccal and palatal sides. Because the forces are applied from both the buccal and palatal sides, it facilitates the rotational control of the molar during distal movement (Figure 9C).

DISCUSSION

Conventional intraoral distal movement appliances have several defects. First, in the sagittal plane, the

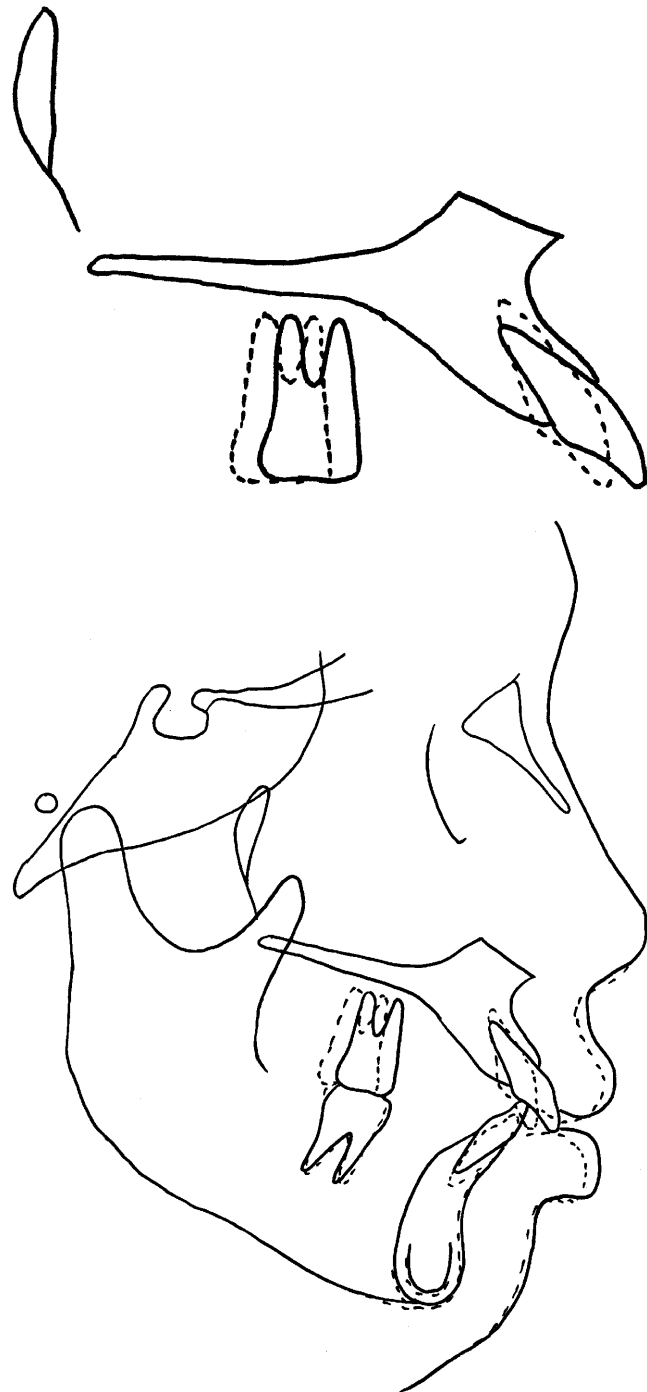

Figure 8. Superimpositions of cephalometric tracings before and after treatment.

anchor unit, such as a palatal wire frame connecting the first and second premolars or acrylic coverage, cannot perfectly prevent reciprocal mesial force, thus causing anchorage loss and intraoral mucosa irritation. Also, distal tipping of the maxillary first molar occurs. Second, in the vertical plane, most intraoral distal movement appliances have a tendency to extrude the maxillary molars, thus increasing the mandibular plane

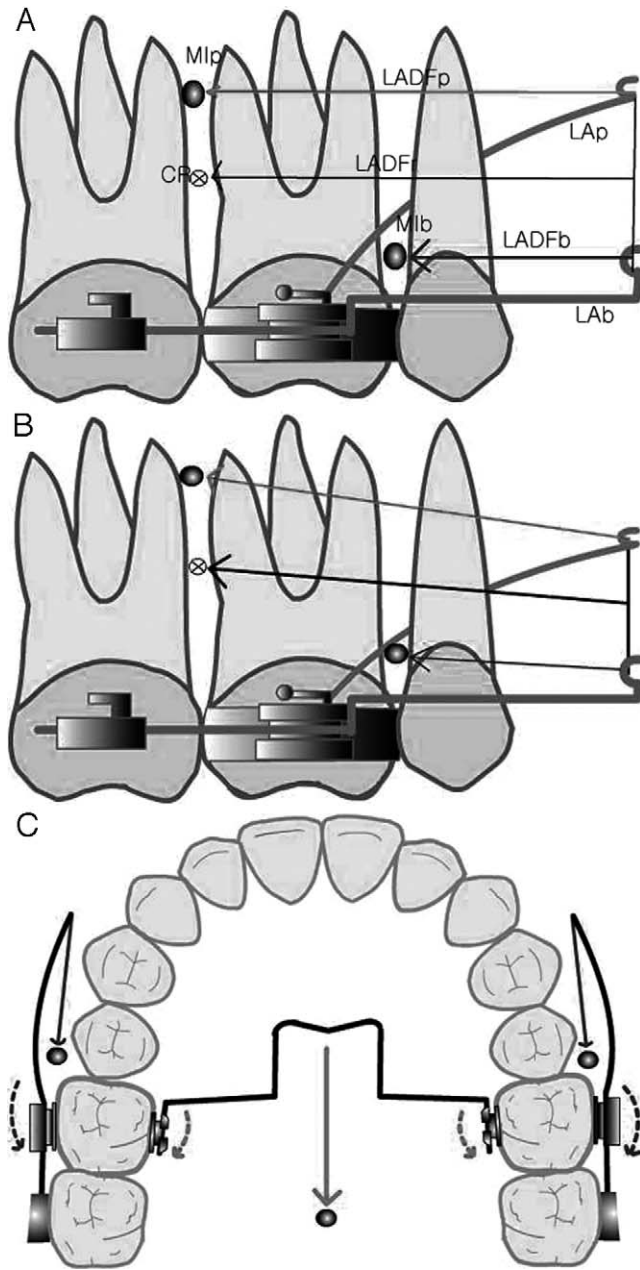


Figure 9. Diagram of the lever-arm and mini-implant system for upper molar distal movement. LAB indicated buccal lever-arm; LAp, palatal lever arm; Mlb, buccal mini-implant; Mlp, palatal mini-implant; LADFb, line of action of the distal force on the buccal side; LADFP, line of action of the distal force on the palatal side; LADFr, resultant line of action of the distal forces on the buccal and palatal sides; and CR, center of resistance of the upper molars. (A) The resultant line of action of the distal forces on the buccal and palatal sides passes through the center of resistance of the upper molars and is parallel to the occlusal plane. (B) The resultant line of action of the distal forces on the buccal and palatal sides passes through the center of resistance of the upper molars with an intrusive component. (C) Application of the distal force on both the buccal and palatal sides facilitates the rotational control of the upper molar during distal movement.

angle.^{10–15,20,23,24,27} Third, in the transverse plane, the force is applied from the buccal or palatal side, inducing rotation of the molars. In addition, it is difficult to appropriately cope with the situation when the molars need to be expanded.

Recently, many studies^{28–33} of distal molar forces using temporary anchorage devices such as palatal implants, intraosseous screws, or miniscrews have been reported to compensate for the weak points of conventional intraoral distal force appliances. In these studies, temporary anchorage devices are combined with conventional intraoral appliances or are used directly to avoid anchorage loss during distal upper molar movement. Although these devices may provide absolute anchorage, it is challenging to obtain an ideal force system.

The weaknesses of aforementioned distal force appliances can be overcome with the use of the lever-arm and mini-implant system. With the lever-arm and mini-implant system, both absolute anchorage and an ideal force system are achievable during distal movement. First, in the sagittal plane, the force is applied directly to the molar without the reciprocal force, thus eliminating the possibility of the anchorage loss of premolars and anterior teeth. Also, because the net force passes through the center of resistance of the upper molar, bodily movement can be acquired. Second, in the vertical plane, a desirable force direction is feasible by adjusting the buccal and palatal heights of the lever arms and mini implants, thus producing simultaneous distal and intrusive movement. Third, in the transverse plane, the rotational control and, if necessary, the expansion of molars are simultaneously acquired by using a 0.032×0.032 -inch or 0.9-mm stainless steel TPA and applying force from both the buccal and palatal sides during distal movement.

In the patient described in case 1, who demonstrated a dolichofacial pattern, the heights of the buccal and palatal lever arms and mini implants were controlled to induce both distal movement and intrusion of the upper molars. Approximately 3.4 mm bodily distal movement and 1.5 mm of intrusion of the upper molars were obtained and a slight upward and forward rotation of the mandible was achieved because intrusion of the upper molars.

In the patient described in case 2, who demonstrated a mesofacial pattern, the lever arm and mini implant system was adjusted to have the resultant distal force pass at the midroot region of the upper molars. However, the maxillary molars were moved distally with a slight distal tipping. The distal tipping of the upper molars was corrected by a palatal lever-arm and mini-implant system that can apply the distal force above the center of resistance of the upper molars without prolonging the treatment duration.

CONCLUSION

- The mini implant, in conjunction with a lever arm, can be used to control the point of force application and produce the desirable three-dimensional control of molars during distal molar movement.

REFERENCES

- Blechman AM. Magnetic force systems in orthodontics. *Am J Orthod.* 1985;87:201–210.
- Gianelly AA, Vaitas AS, Thomas WM. The use of magnets to move molars distally. *Am J Orthod Dentofacial Orthop.* 1989;96:161–167.
- Itoh T, Tokuda T, Kiyosue S, Hirose T, Matsumoto M, Chaconas SP. Molar distalization with repelling magnets. *J Clin Orthod.* 1991;25:611–617.
- Bondemark L, Kurol J. Distalization of maxillary first and second molars simultaneously with repelling magnets. *Eur J Orthod.* 1992;14:264–272.
- Bondemark L, Kurol J, Bernhold M. Repelling magnets versus superelastic nickel-titanium coils in simultaneous distal movement of maxillary first and second molars. *Angle Orthod.* 1994;64:189–198.
- Gianelly A, Bednar J, Dietz V. Japanese NiTi coils used to move molars distally. *Am J Orthod Dentofacial Orthop.* 1991;99:564–566.
- Gianelly A. Distal movement of the maxillary molars. *Am J Orthod Dentofacial Orthop.* 1998;114:66–72.
- Locatelli R, Bednar J, Dietz V, Gianelly A. Molar distalization with superelastic NiTi wire. *J Clin Orthod.* 1992;26:277–279.
- Jones R, White J. Rapid class II molar correction with an open coil jig. *J Clin Orthod.* 1992;26:661–664.
- Gulati S, Kharbanda OP, Prakash H. Dental and skeletal changes after intraoral molar distalization with sectional jig assembly. *Am J Orthod Dentofacial Orthop.* 1998;114:319–327.
- Runge ME, Martin JT, Bukai F. Analysis of rapid molar distal movement without patient cooperation. *Am J Orthod Dentofacial Orthop.* 1999;115:153–157.
- Haydar S, Üner O. Comparison of Jones jig molar distalization appliance with extraoral traction. *Am J Orthod Dentofacial Orthop.* 2000;117:49–53.
- Brickman CD, Sinha PK, Nanda RS. Evaluation of the Jones jig appliance for distal molar movement. *Am J Orthod Dentofacial Orthop.* 2000;118:526–534.
- Carano A, Testa M. The distal jet for upper molar distalization. *J Clin Orthod.* 1996;30:374–380.
- Ngantung V, Nanda RS, Bowman J. Posttreatment evaluation of the distal jet appliance. *Am J Orthod Dentofacial Orthop.* 2001;120:178–185.
- Bolla E, Muratore F, Carano A, Bowman J. Evaluation of maxillary molar distalization with the distal jet: a comparison with other contemporary methods. *Angle Orthod.* 2002;72:481–494.
- Keles A. Maxillary unilateral molar distalization with sliding mechanics: a preliminary investigation. *Eur J Orthod.* 2001;23:507–515.
- Keles A, Pamukcu B. Bilateral maxillary molar distalization with sliding mechanics: Keles slider. *World J Orthod.* 2002;3:57–66.
- Hilgers JJ. The pendulum appliance for class II non-compliance therapy. *J Clin Orthod.* 1992;26:700–703.
- Ghosh J, Nanda RS. Evaluation of an intraoral maxillary molar distalization technique. *Am J Orthod Dentofacial Orthop.* 1996;110:639–646.
- Byloff FK, Darendeliler MA. Distal molar movement using the pendulum appliance. Part 1: clinical and radiological evaluation. *Angle Orthod.* 1997;67:249–260.
- Byloff FK, Darendeliler MA. Distal molar movement using the pendulum appliance. Part 2: the effects of maxillary molar root uprighting bends. *Angle Orthod.* 1997;67:261–270.
- Bussick TJ, McNamara JA. Dentoalveolar and skeletal changes associated with the pendulum appliance. *Am J Orthod Dentofacial Orthop.* 2000;117:333–343.
- Joseph AA, Butchard CJ. An evaluation of the pendulum “distalizing” appliance. *Semin Orthod.* 2000;6:129–135.
- Chaquás-Asensi J, Kalra V. Effects of the pendulum appliance on the dentofacial complex. *J Clin Orthod.* 2001;35:254–257.
- Kalra V. The K-loop molar distalization appliance. *J Clin Orthod.* 1995;24:298–301.
- Keles A, Sayinsu K. A new approach in maxillary molar distalization: intraoral bodily molar distalizer. *Am J Orthod Dentofacial Orthop.* 2000;117:39–48.
- Byloff FK, Karcher H, Clar E, Stoff F. An implant to eliminate anchorage loss during molar distalization: a case report involving the Graz implant-supported pendulum. *Int J Adult Orthod Orthognath Surg.* 2000;15:129–137.
- Keleş A, Erverdi N, Sezen S. Bodily distalization of molars with absolute anchorage. *Angle Orthod.* 2003;73:471–482.
- Carano A, Velo S, Leone P, Siciliani G. Clinical applications of the miniscrew anchorage system. *J Clin Orthod.* 2005;39:9–24.
- Karaman AI, Başsiftçi FA, Polat O. Unilateral distal molar movement with an implant-supported distal jet appliance. *Angle Orthod.* 2002;72:167–174.
- Gelgör IE, Büyükyılmaz T, Karaman AI, Dolanmaz D, Kalaycı A. Intraosseous screw-supported upper molar distalization. *Angle Orthod.* 2004;74:836–848.
- Kircelli BH, Pektaş ZÖ, Kircelli C. Maxillary molar distalization with a bone-anchored pendulum appliance. *Angle Orthod.* 2006;76:650–659.