

# Long-term evaluation of rapid maxillary expansion and bite-block therapy in open bite growing subjects: A controlled clinical study

Manuela Mucedero<sup>a</sup>; Dimitri Fusaroli<sup>b</sup>; Lorenzo Franchi<sup>c</sup>; Chiara Pavoni<sup>a,d</sup>; Paola Cozza<sup>e,f</sup>; Roberta Lione<sup>a,d</sup>

## ABSTRACT

**Objective:** To evaluate the long-term effects of rapid maxillary expansion (RME) and posterior bite block (BB) in prepubertal subjects with dentoskeletal open bite.

**Materials and Methods:** The treatment group (TG) comprised 16 subjects (14 girls, 2 boys) with dentoskeletal open bite with a mean age of  $8.1 \pm 1.1$  years treated with RME and BB. Three consecutive lateral cephalograms were available before treatment (T1), at the end of the active treatment with the RME and BB (T2), and at a follow-up observation at least 4 years after the completion of treatment (T3). The TG was compared with a control group (CG) of 16 subjects (14 girls, 2 boys) matched for sex, age, and vertical skeletal pattern. An independent sample *t*-test was used to compare the T1 to T3, T1 to T2, and T2 to T3 cephalometric changes between the TG and the CG.

**Results:** In the long term, the TG showed a significantly greater increase in overbite (+1.8 mm), reduced extrusion of maxillary and mandibular molars (-3.3 mm), and, consequently, a significant decrease in facial divergence (-2.8°) when compared with untreated subjects.

**Conclusions:** The RME and BB protocol led to successful and stable recovery of positive overbite in 100% of the patients considered. Correction of open bite was associated with reduced extrusion of maxillary and mandibular molars with a significant improvement in vertical skeletal relationships when compared with the CG. (*Angle Orthod.* 2018;88:523–529.)

**KEY WORDS:** Open bite; Long term; Rapid maxillary expansion; Bite block

## INTRODUCTION

Anterior open bite is a malocclusion characterized by a deficiency in the normal vertical overlap between antagonist incisal edges when the posterior teeth are in occlusion. The prevalence rate of anterior open bite ranges from 1.5% to 11% among different age and ethnic groups.<sup>1</sup> In younger children, anterior open bite can be caused by one factor or a combination of factors such as sucking habits, enlarged tonsils or adenoids, tongue position, constricted maxilla, and skeletal open bite growth pattern.<sup>2</sup>

In nonnutritive sucking patients, treatment consists of removing the etiologic factor and in controlling the habit, allowing the teeth to erupt into a normal position.<sup>3–5</sup> A palatal crib is the most common device used to promote normal development of the anterior segment.<sup>1,5</sup>

To the contrary, in skeletal open bite malocclusion, patients display backward and downward rotation of the mandible, increased vertical growth of posterior dentoalveolar structures, increased lower anterior

<sup>a</sup> Research Fellow, Department of Clinical Sciences and Translational Medicine, University of Rome "Tor Vergata," Rome, Italy.

<sup>b</sup> Graduate student, Department of Clinical Sciences and Translational Medicine, University of Rome "Tor Vergata," Rome, Italy.

<sup>c</sup> Assistant Professor, Department of Surgery and Translational Medicine, University of Florence, Florence, Italy.

<sup>d</sup> Research Fellow, Department of Dentistry, University Nostra Signora del Buon Consiglio, Tirana, Albania.

<sup>e</sup> Professor and Department Chair, Department of Clinical Sciences and Translational Medicine, University of Rome "Tor Vergata," Rome, Italy.

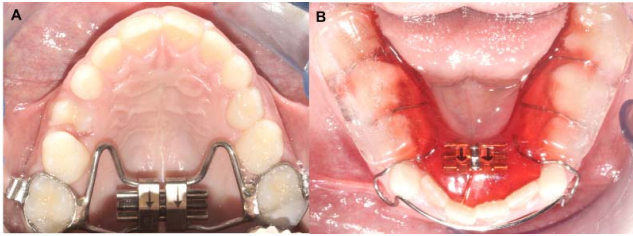
<sup>f</sup> Head, Department of Dentistry, University Nostra Signora del Buon Consiglio, Tirana, Albania.

Corresponding author: Dr Roberta Lione, Department of Clinical Sciences and Translational Medicine, University of Rome "Tor Vergata," Via Montpellier, 1 00133 Rome, Italy (e-mail: robertalione@yahoo.it)

Accepted: February 2018. Submitted: October 2017.

Published Online: April 23, 2018

© 2018 by The EH Angle Education and Research Foundation, Inc.



**Figure 1.** (A) Rapid maxillary expander. (B) Posterior bite block appliance.

facial height, and a narrow maxillary arch.<sup>6,7</sup> Several authors<sup>1,6,8-10</sup> emphasized that a skeletal open bite should be treated in the mixed dentition to take advantage of active growth by expanding the maxillary arch and preventing further vertical growth of the upper and lower posterior dentoalveolar regions.

Few studies have been published addressing the effectiveness of early treatment of skeletal open bite. Sankey et al.<sup>8</sup> evaluated an early nonextraction treatment approach for growing patients with severe vertical skeletal dysplasia and maxillary deficiency. Thirty-eight children treated with lip seal exercises, bonded palatal expander, and banded lower Crozat/lip bumper were compared with a control group (CG). Treatment significantly enhanced condylar growth, altered it to a more anterosuperior direction, and produced anterior mandibular rotation 2.7 times greater than the controls.

Schulz et al.<sup>11</sup> investigated the effect of vertical chin-cup (V-CC) therapy during an initial rapid maxillary expansion (RME) phase followed by fixed orthodontic therapy in growing subjects with mild-to-severe hyperdivergent facial patterns. The V-CC was most effective during the initial RME phase and of little benefit during the fixed appliance phase.

Baccetti et al.<sup>12</sup> investigated the role of treatment timing on the effectiveness of V-CC therapy in conjunction with a bonded RME. Treatment during the adolescent growth spurt induced more favorable changes than early intervention, with a greater reduction of facial divergence and supplementary growth of the mandibular ramus.

The use of RME in association with a posterior bite block (BB) has been proposed to control the vertical dimension by avoiding the extrusion of both mandibular and maxillary molars.<sup>13-15</sup> Passive BB was demonstrated to be effective in decreasing the divergence between the palatal and mandibular planes.<sup>16-18</sup>

However, no previous study analyzed the effects of RME and BB for the early treatment of anterior dentoskeletal open bite patients with no oral habits. Therefore, the aim of the study was to evaluate the long-term stability of RME and BB therapy in growing

subjects with anterior dentoskeletal open bite when compared with a CG with untreated open bite.

## MATERIALS AND METHODS

The treated group (TG) comprised 16 subjects (14 girls, 2 boys) with a mean age of  $8.1 \pm 1.1$  years who were treated consecutively at the Department of Orthodontics of the University of Rome, "Tor Vergata." The inclusion criteria included no sucking habits, overbite  $<0$  mm, posterior transverse interarch discrepancy  $\geq 3$  mm,<sup>19</sup> Frankfort horizontal to mandibular plane angle greater than  $26^\circ$ ,<sup>20</sup> full eruption of first permanent molars and of maxillary and mandibular incisors (to prevent the "pseudo-open bite" due to undererupted permanent incisors),<sup>21</sup> no permanent teeth extracted before or during treatment, and three consecutive lateral cephalograms of good quality with adequate landmark visualization. The cephalograms were taken before treatment (T1), at the end of the active treatment with RME and BB (T2), and at a follow-up observation at least 4 years after the completion of treatment (T3) using a modern cephalostat with 1.5 m of focus/film distance. This project was approved by the ethical committee at the University of Rome, "Tor Vergata" (protocol number 234/16), and informed consent was obtained from parents.

Each patient underwent a treatment protocol with RME soldered to bands on the second deciduous molars or on the first permanent molars. The expansion screw was activated once a day until the palatal cusps of the maxillary posterior teeth approximated the buccal cusps of the mandibular posterior teeth. The RME was left in place for at least 8 months as a passive retainer stabilizing the expansion reached during screw activation. No removable appliance was applied after RME removal. The BB appliance was constructed in the form of a Schwartz plate for the lower arch with posterior occlusal resin splints of 5-mm thickness (Figure 1).<sup>17</sup> The removable mandibular BB was prescribed for 12 months to control the vertical dimension. The patients were instructed to wear the BB 24 hours a day. As in studies involving any removable device, compliance varied among patients. Therefore, a single investigator conducted a face-to-face interview with each patient to assess his or her cooperation. Compliance was appraised with a 3-point Likert-type scale (poor, moderate, good)<sup>22</sup>: poor compliance was reported when the patient wore the BB at night only, moderate compliance occurred when the patient wore the BB at night and during the day at home, and good compliance was assessed when the patient wore the BB full time as suggested by the clinician.

All subjects were at a prepubertal stage of skeletal maturity according to the cervical vertebral maturation

**Table 1.** Demographics of the Treated and Control Groups

	Age at T1, y		Age at T2, y		Age at T3, y		T1–T2 Interval, y		T2–T3 Interval, y		T1–T3 Interval, y	
	Mean	SD	Mean	SD	Mean	SD	Mean	SD	Mean	SD	Mean	SD
Treated group (n = 16, 14 girls, 2 boys)	8.1	1.1	9.6	1.2	13.5	1.4	1.6	0.5	3.9	1.7	5.4	1.5
Control group (n = 16, 14 girls, 2 boys)	8.3	1.2	9.6	1.4	13.3	1.2	1.3	0.8	3.7	1.7	5.0	1.4

y indicates years; SD, standard deviation.

method (CS 1 or CS 2) at T1.<sup>23</sup> The overall observation period was  $5.4 \pm 1.5$  years, which included a follow-up period of at least 4 years, during which the RME and BB patients could be treated with fixed appliances. No active biomechanics or vertical elastics to extrude the incisors were applied during fixed appliance therapy. No intraoral Class II elastics were used.

All subjects had reached postpubertal skeletal maturity at T3 (CS 4–6). The stages of cervical vertebral maturation were determined by a calibrated examiner (Dr Franchi) trained in this method. All patients were in the permanent dentition at T3. The therapy was considered successful when the overbite was greater than 0 mm.

A CG of 16 subjects (14 girls, 2 boys) with untreated anterior open bite was retrieved from the American Association of Orthodontists Foundation Craniofacial Growth Legacy Collection (<http://www.aaoflegacycollection.org>). Demographic data of the examined samples are reported in Table 1.

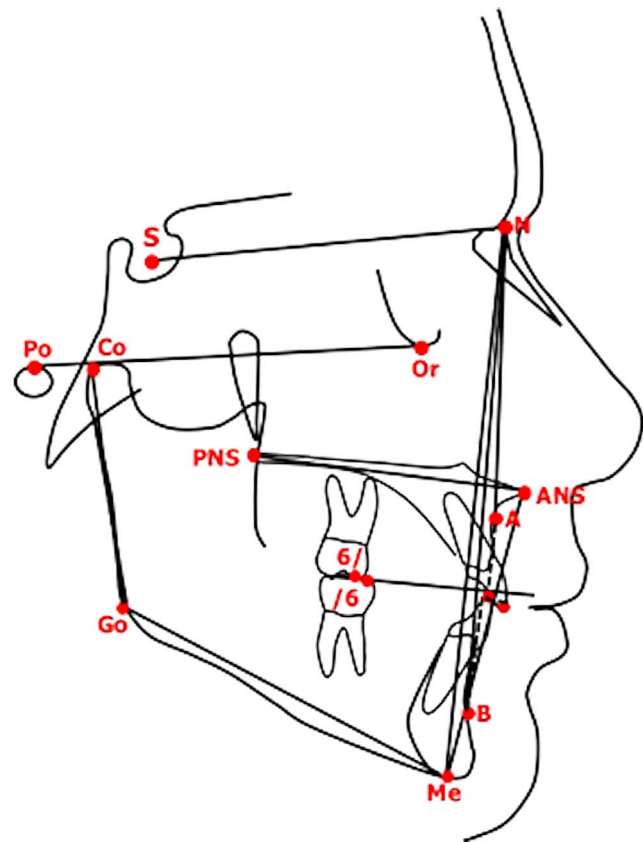
Cephalometric software (Viewbox, version 4.0, dHAL Software, Kifissia, Greece) was used for a customized digitization regimen used for the cephalometric evaluation. Lateral cephalograms of the TG and CG were standardized with regard to magnification factor by setting this at 0%. The cephalometric reference points, lines, and angles (six linear, five angular measurements) used in the analysis are shown in Figure 2. The sum of maxillary first molar to palatal plane and mandibular first molar to mandibular plane was also evaluated at the three observation times.

### Statistical Analysis

Since no study in the literature investigating the long-term effects of RME and BB was available, the power of the study was calculated for an effect size 1.0<sup>24</sup> for the primary outcome variable overbite, with an alpha level of 0.05. The power of the study was 0.8. To determine the method error, measurements on the lateral cephalograms of both the TG and CG were performed by one trained examiner (Dr Fusaroli) and repeated after an interval of approximately 2 weeks. A paired *t*-test was used to compare the two measurements (systematic error). The magnitude of the random

error was calculated by using the method of moments' estimator.<sup>25</sup>

The primary aim of the study was to evaluate the long-term effects of RME and BB. Therefore, statistical between-group comparisons were calculated for the craniofacial starting forms at T1 and for the T1–T3 changes. In the presence of normally distributed data (Kolmogorov-Smirnov test), statistical between-group comparisons were performed with independent-sample *t*-tests. If data were not normally distributed, statistical between-group comparisons were carried out with the



**Figure 2.** Cephalometric points, lines, and angles used in analysis: SNA; SNB; ANB; A to occlusal plane (AO); B to occlusal plane (BO); Frankfort horizontal (Po-Or) to mandibular plane (Me-Go) angle (FMA); palatal plane (ANS-PNS) to mandibular plane (Me-Go) angle; lower anterior facial height (ANS-Me); mandibular ramus height (Co-Go); overbite; maxillary first molar (6/1) to palatal plane (ANS-PNS); mandibular first molar (1/6) to mandibular plane (Me-Go); sum = maxillary first molar to palatal plane + mandibular first molar to mandibular plane.

**Table 2.** Descriptive Statistics and Statistical Comparisons (Independent-Samples *t*-Tests) of the Starting Forms (Cephalometric Values at T1)

Variable	Treated Group		Control Group		Difference	P Value	95% CI of the Difference	
	Mean	SD	Mean	SD			Lower	Upper
	Median	25/75	Median	25/75				
Age, y	8.1	1.1	8.3	1.2	-0.2	.583	-1.1	0.6
SNA, °	79.7	2.6	81.2	2.9	-1.5	.120	-3.5	0.4
SNB, °	75.1	2.5	75.9	2.5	-0.8	.373	-2.6	1.0
ANB, °	4.6	1.8	5.3	2.0	-0.7	.280	-2.1	0.6
WITS, mm	-1.8	3.0	-1.6	2.7	-0.2	.865	-2.3	1.9
FMA, °	29.5	4.5	29.8	2.9	-0.3	.821	-3.0	2.4
Palatal plane to mandibular plane°	33.7	3.6	32.0	3.6	1.7	.203	-1.0	4.3
ANS-Me, mm	60.2	4.2	58.9	5.3	1.3	.435	-2.1	4.8
Co-Go, mm	43.3	3.6	43.2	3.0	0.1	.946	-2.3	2.5
Overbite, mm	-2.6	1.2	-2.9	1.2	0.3	.447	-0.6	1.2
Maxillary first molar to palatal plane, mm	17.3	1.9	17.5	1.7	-0.2	.655	-1.6	1.0
Mandibular first molar to mandibular plane, mm	25.7	2.0	25.7	2.1	0.0	.939	-1.5	1.4
Sum, mm <sup>a</sup>	42.1	40.8/44.7	42.8	41.7/44.1	-0.7	.642		

<sup>a</sup> Sum indicates maxillary first molar to palatal plane + mandibular first molar to mandibular plane; y, years; SD, Standard deviation; P<0.05; 25/75, 25th percentile/75th percentile.

Mann-Whitney test. As secondary statistical analysis, between-group comparisons for the T1–T2 and T2–T3 changes also were performed.

All statistical computations were performed by using specific software (SigmaStat 3.5, Systat Software, Point Richmond, Calif).

## RESULTS

The analysis of compliance of the treated subjects (use of BB) showed that none had poor cooperation, six had moderate cooperation, and the remaining 10 patients had good compliance. As a result, cooperation was good in 62.5% of the patients.

No systematic error was found between the repeated cephalometric values. The random error varied from 0.18° (SNB angle) to 0.35° (FMA) for angular measurements and from 0.15 mm (Co-Go) to 0.26 mm

(ANS-Me) for linear measurements. No significant between-group differences were found at T1 for any cephalometric variables (Table 2). For the dentoskeletal features at baseline (T1), the vertical skeletal dimension was increased in all subjects, and the sagittal intermaxillary relationship was skeletal Class II in both groups. In the follow-up observation after 5 years (T3), all 16 subjects (100%) in the TG showed a corrected overbite with a significantly greater increase in overbite of 1.8 mm in the TG compared with the untreated subjects. The comparison of long-term changes (T1–T3; Table 3) revealed a significantly greater decrease of the vertical skeletal relationships in treated subjects when compared with the CG (Frankfort horizontal to mandibular plane angle: -2.8°). The TG exhibited a significantly smaller extrusion of both maxillary (maxillary first molar to palatal plane: -1.9 mm) and mandibular first molars (mandibular first

**Table 3.** Descriptive Statistics and Statistical Comparisons (Independent-Samples *t*-Tests) of the T1–T3 Changes in the Treated Group vs the Control Group

Variable	Treated Group		Control Group		Difference	P Value	95% CI of the Difference	
	Mean	SD	Mean	SD			Lower	Upper
	Mean	SD	Mean	SD				
Age, y	5.4	1.5	5.0	1.4	0.4	.394	-0.6	1.5
SNA, °	0.1	1.2	-0.1	1.8	0.2	.682	-0.9	1.3
SNB, °	1.8	1.6	0.9	1.6	0.9	.127	-0.3	2.0
ANB, °	-1.7	2.0	-1.0	1.4	-0.7	.279	-1.9	0.6
WITS, mm	-0.6	3.3	1.0	3.0	-1.6	.157	-3.9	0.7
FMA, °	-0.5	1.6	2.3	1.7	-2.8	.000*	-4.0	-1.6
Palatal plane to mandibular plane, °	-2.2	2.5	-2.5	1.7	0.3	.709	-1.3	1.8
ANS-Me, mm	5.1	4.8	6.3	2.8	-1.2	.366	-4.1	1.6
Co-Go, mm	7.0	2.4	8.6	2.9	-1.6	.109	-3.5	0.4
Overbite, mm	3.9	1.5	2.1	1.4	1.8	.002*	0.8	2.9
Maxillary first molar to palatal plane, mm	2.7	1.6	4.6	1.9	-1.9	.004*	-3.2	-0.6
Mandibular first molar to mandibular plane, mm	2.6	1.1	3.9	1.5	-1.3	.009*	-2.3	-0.3
Sum, mm <sup>a</sup>	5.2	2.5	8.5	2.8	-3.3	.002*	-5.1	-1.3

<sup>a</sup> Sum indicates maxillary first molar to palatal plane + mandibular first molar to mandibular plane. y, years; SD Standard deviation; \*P<0.05.

**Table 4.** Descriptive Statistics and Statistical Comparisons (Independent-Samples *t*-Tests) of the T1–T2 Changes in the Treated Group vs the Control Group

Variable	Treated Group		Control Group		Difference	<i>P</i> Value	95% CI of the Difference	
	Mean	SD	Mean	SD			Lower	Upper
Age, y	1.6	0.5	1.3	0.8	0.3	.185	−0.2	0.8
SNA, °	0.0	0.7	0.5	2.3	−0.5	.400	−1.7	0.7
SNB, °	0.7	1.1	0.7	2.5	0.0	.986	−1.4	1.4
ANB, °	−0.7	1.3	−0.2	1.0	−0.5	.240	−1.4	0.4
WITS, mm	−0.1	1.1	0.3	2.7	−0.4	.599	−1.9	1.1
FMA, °	−0.9	0.8	1.0	1.0	−1.9	<b>.000*</b>	−2.6	−1.3
Palatal plane to mandibular plane, °	−1.1	1.8	−0.9	2.3	−0.2	.742	−1.7	1.3
ANS-Me, mm	1.5	2.3	1.3	1.2	0.2	.676	−1.0	1.6
Co-Go, mm	2.5	1.8	2.4	3.0	0.1	.887	−1.7	1.9
Overbite, mm	2.8	1.1	0.8	1.4	<b>2.0</b>	<b>.000*</b>	1.1	3.0
Maxillary first molar to palatal plane, mm	0.5	0.6	1.2	1.3	−0.7	.058	−1.4	0.0
Mandibular first molar to mandibular plane, mm	0.6	0.7	1.2	1.1	−0.6	.058	−1.3	0.0
Sum, mm <sup>a</sup>	1.1	1.2	2.4	1.9	−1.3	<b>.026*</b>	−2.5	−0.2

<sup>a</sup> Sum indicates maxillary first molar to palatal plane + mandibular first molar to mandibular plane. y years; SD Standard deviation; \**P*<0.05.

molar to mandibular plane: −1.3 mm) compared with the CG. At T2, the prevalence rate of success for recovery of positive overbite was 63% (10 subjects) in the TG, while in the CG, spontaneous correction was not observed in any subject.

Active treatment with RME and BB (T1–T2 interval; Table 4) was effective in correcting dental open bite with a significantly greater increase in overbite in the TG vs the CG (+2.0 mm). The TG showed a significantly greater decrease of facial divergence when compared with the CG (−1.9°). The improvement of the dental open bite was associated with a significantly smaller increase in the sum of the upper and lower molar extrusion in the TG in comparison with the CG (−1.3 mm). No significant differences in posttreatment changes (T2–T3) were found between the TG and CG (Table 5).

**DISCUSSION**

The aim of the study was to evaluate the long-term stability of RME and BB therapy in growing children with anterior dentoskeletal open bite when compared with subjects who had untreated open bite.

The CG matched the TG for skeletal vertical dysplasia, amount of negative overbite, chronologic age and skeletal maturation at different time points, and gender distribution. Although historical CGs might have some limitations,<sup>26</sup> the use of historical controls was due to the ethical concern to leave children with anterior open bite untreated to collect a contemporary CG. Another limitation of the present study was the relatively small number of patients with anterior dentoskeletal open bite and the group being predominantly female. It should be stressed, however, that dentoskeletal open bite is a rare condition in the

**Table 5.** Descriptive Statistics and Statistical Comparisons (Independent-Samples *t*-Tests or Mann-Whitney Test) of the T2–T3 Changes in the Treated Group vs the Control Group

Variable	Treated Group		Control Group		Difference	<i>P</i> Value	95% CI of the Difference	
	Mean	SD	Mean	SD			Lower	Upper
	Median	25/75	Median	25/75				
Age, y	3.9	1.7	3.7	1.7	0.2	.828	−1.1	1.4
SNA, °	0.1	0.8	−0.7	1.8	0.8	.159	−0.3	1.8
SNB, °	1.1	1.5	0.2	2.2	0.9	.204	−0.5	2.3
ANB, °	−0.5	−1.5/−0.1	−0.4	−1.7/0.3	−0.1	.780		
WITS, mm	−0.5	3.2	0.8	3.1	−1.3	.282	−3.5	1.1
FMA, °	0.4	1.2	1.3	1.4	−0.9	.076	−1.8	0.1
Palatal plane to mandibular plane, °	−1.1	1.7	−1.6	2.6	0.5	.498	−1.0	2.1
ANS-Me, mm	3.5	3.6	5.1	2.8	−1.6	.189	−3.9	0.8
Co-Go, mm	4.5	2.5	6.2	4.2	−1.7	.177	−4.2	0.8
Overbite, mm	1.1	0.9	1.3	1.3	−0.2	.622	−1.0	0.6
Maxillary first molar to palatal plane, mm	2.2	1.5	3.4	1.9	−1.2	.052	−2.4	0.0
Mandibular first molar to mandibular plane, mm	2.0	1.0	2.7	1.7	−0.7	.180	−1.7	0.3
Sum, mm <sup>a</sup>	4.2	2.2	6.1	3.1	−1.9	.058	−3.8	0.1

<sup>a</sup> Sum indicates maxillary first molar to palatal plane + mandibular first molar to mandibular plane. y, years; SD, Standard deviation; *P*<0.05; 25/75, 25th percentile/75th percentile.

general population,<sup>4</sup> with a higher prevalence rate in females.<sup>27</sup>

Hyperdivergent open bite patients present with three-dimensional skeletal and dentoalveolar problems related to both the maxilla and the mandible. This kind of growth pattern occurs when vertical growth in the molar region is greater than growth at the condyle. It has been reported that hyperdivergent open bite is often associated with a narrower maxilla, increased prevalence rate of posterior crossbites, and atypical swallowing.<sup>10</sup> Therefore, early treatment must address problems pertaining to the dentoalveolar and skeletal structures of both jaws and functional disturbances. The early treatment of anterior dentoskeletal open bite should include orthopedic expansion of the maxillary arch and limitation of posterior dentoalveolar height increases by controlling the eruption of posterior teeth.<sup>8,28</sup> However, relapse is common after treatment with orthodontics alone, and one reason is the fact that vertical growth and eruption of the posterior teeth may continue until the late teenage years, with the vertical growth of the maxilla being the last stage of maturation.<sup>14,18</sup> Long-term studies reporting the success of early treatment in subjects with anterior dentoskeletal open bite are scarce in the literature.<sup>29</sup> Effectiveness and long-term stability of available treatment modalities are critical issues because of the lack of strong scientific evidence.<sup>1,30</sup>

In the present study, at the end of active therapy (T2) and at long-term follow-up (T3), all treated subjects showed a corrected positive overbite (overbite at T2: +0.2 mm; overbite at T3: +1.3 mm) and a decreased facial divergence (FMA T2–T1: –0.9°; FMA T3–T1: –0.5°). Several studies described downward movement of the maxilla, posterior rotation of the mandible, and opening of the mandibular plane angle as side effects of RME.<sup>31</sup> In the present investigation, RME and BB therapy were effective in the correction of anterior dentoskeletal open bite by minimizing tipping and extrusion of the posterior maxillary teeth.

During the active phase of treatment from T1 to T2, control of excessive vertical growth in the dentoalveolar segments provided by acrylic coverage of the posterior arch induced an anterior rotation of the mandible (FMA –2.8° in TG vs CG). In particular, the reduced increase in the vertical skeletal dimension was associated with a smaller extrusion of both the maxillary and mandibular first molars. Although the changes of these values were not statistically significant, the sum of reduced upper and lower molar extrusion was both statistically and clinically significant (–3.3 mm), positively affecting the mandibular vertical position. These findings are in agreement with those reported by Cinsar et al.<sup>7</sup> and Albogha et al.,<sup>28</sup> who tested the effects of magnetic and coil spring BB

cemented for a short period in growing children with anterior open bite.

After the completion of the active phase of treatment, no statistically significant differences were observed between the TG and CG during the posttreatment T2–T3 interval (Table 5). Thus, according to these results, it seems that the hyperdivergent treated patients recovered their growth pattern in both dental and skeletal structures. When analyzing the overall long-term interval T1–T3, the effects of the treatment, however, remained effective in controlling posterior dental eruption and in limiting the increases of vertical skeletal dimension. However, further investigations with larger sample size are needed.

## CONCLUSIONS

- The treatment protocol with RME and BB was effective in the correction of negative overbite in growing children.
- The TG exhibited reduced extrusion of maxillary and mandibular molars and, consequently, a significant improvement in the vertical skeletal dimension when compared with untreated open bite subjects.
- The effects of early treatment with RME and BB were stable at long-term follow-up.

## REFERENCES

1. Pisani L, Bonaccorso L, Fastuca R, Spena R, Lombardo L, Caprioglio A. Systematic review for orthodontic and orthopedic treatments for anterior open bite in the mixed dentition. *Prog Orthod*. 2016;17:28.
2. Krey KF, Dannhauer KH, Hierl T. Morphology of open bite. *J Orofac Orthop*. 2015;76:213–224.
3. Lopes-Freire GM, Cárdenas AB, Suarez de Deza JE, Ustrell-Torrent JM, Oliveira LB, Boj Quesada JR Jr. Exploring the association between feeding habits, non-nutritive sucking habits, and malocclusions in the deciduous dentition. *Prog Orthod*. 2015;16:43.
4. Ngan P, Fields HW. Open bite: a review of etiology and management. *Pediatr Dent*. 1997;19:91–98.
5. Mucedero M, Franchi L, Giuntini V, Vangelisti A, McNamara JA Jr, Cozza P. Stability of quad-helix/crib therapy in dentoskeletal open bite: a long-term controlled study. *Am J Orthod Dentofacial Orthop*. 2013;143:695–703.
6. Işcan HN, Dinçer M, Gültan A, Meral O, Taner-Sarisoy L. Effects of vertical chin cap therapy on the mandibular morphology in open-bite patients. *Am J Orthod Dentofacial Orthop*. 2002;122:506–511.
7. Çinsar A, Alagha AR, Akyalçın S. Skeletal open bite correction with rapid molar intruder appliance in growing individuals. *Angle Orthod*. 2007;77:632–639.
8. Sankey WL, Buschang PH, English J, Owen AH. Early treatment of vertical skeletal dysplasia: the hyperdivergent phenotype. *Am J Orthod Dentofacial Orthop*. 2000;118:317–327.
9. English JD. Early treatment of skeletal open bite malocclusions. *Am J Orthod Dentofacial Orthop*. 2002;121:563–565.

10. Buschang PH, Sankey W, English JD. Early treatment of hyperdivergent open-bite malocclusions. *Semin Orthod.* 2002;8:130–140.
11. Schulz SO, McNamara JA Jr, Baccetti T, Franchi L. Treatment effects of bonded RME and vertical-pull chin cup followed by fixed appliance in patients with increased vertical dimension. *Am J Orthod Dentofacial Orthop.* 2005;128:326–336.
12. Baccetti T, Franchi L, Schulz SO, McNamara JA Jr. Treatment timing for an orthopedic approach to patients with increased vertical dimension. *Am J Orthod Dentofacial Orthop.* 2008;133:58–64.
13. Işcan HN, Akkaya S, Koralp E. The effects of the spring-loaded posterior bite-block on the maxillo-facial morphology. *Eur J Orthod.* 1992;14:54–60.
14. Kuster R, Ingervall B. The effect of treatment of skeletal open bite with two types of bite-blocks. *Eur J Orthod.* 1992;14:489–499.
15. Lione R, Franchi L, Cozza P. Does rapid maxillary expansion induce adverse effects in growing subjects? *Angle Orthod.* 2013;83:172–182.
16. Işcan HN, Sarisoş L. Comparison of the effects of passive posterior bite-blocks with different construction bites on the craniofacial and dentoalveolar structures. *Am J Orthod Dentofacial Orthop.* 1997;112:171–178.
17. Lione R, Kiliaridis S, Noviello A, Franchi L, Antonarakis GS, Cozza P. Evaluation of masseter muscles in relation to treatment with removable bite-blocks in dolichofacial growing subjects: a prospective controlled study. *Am J Orthod Dentofacial Orthop.* 2017;151:1058–1064.
18. Feres MF, Abreu LG, Insabralde NM, Almeida MR, Flores-Mir C. Effectiveness of the open bite treatment in growing children and adolescents: a systematic review. *Eur J Orthod.* 2016;38:237–250.
19. Tollaro I, Baccetti T, Franchi L, Tanasescu CD. Role of posterior transverse interarch discrepancy in Class II, Division 1 malocclusion during the mixed dentition phase. *Am J Orthod Dentofacial Orthop.* 1996;110:417–422.
20. Riolo ML, Moyers RE, McNamara JA Jr, Hunter WS. *An Atlas of Craniofacial Growth: Cephalometric Standards From the University School Growth Study.* Monograph 2. Craniofacial Growth Series. Ann Arbor, Mich: Center for Human Growth and Development, University of Michigan; 1974.
21. Graber TM, Rakosi T, Petrovic A. *Dentofacial Orthopedics With Functional Appliances.* St Louis, Mo: Mosby; 1997.
22. Slakter MJ, Albino JE, Fox RN, Lewis EA. Reliability and stability of the orthodontic patient cooperation scale. *Am J Orthod.* 1980;78:559–563.
23. Baccetti T, Franchi L, McNamara JA Jr. The cervical vertebral maturation (CVM) method for the assessment of optimal treatment timing in dentofacial orthopedics. *Semin Orthod.* 2005;11:119–129.
24. Cohen J. A power primer. *Psychol Bull.* 1992;112:155–159.
25. Springate SD. The effect of sample size and bias on the reliability of estimates of error: a comparative study of Dahlberg's formula. *Eur J Orthod.* 2012;34:158–163.
26. Pandis N. Use of controls in clinical trials. *Am J Orthod Dentofacial Orthop.* 2012;141:250–251.
27. Worms FW, Meskin LH, Isaacson RJ. Open-bite. *Am J Orthod.* 1971;59:589–595.
28. Albogha MH, Takahashi I, Sawan MN. Early treatment of anterior open bite: comparison of the vertical and horizontal morphological changes induced by magnetic bite-blocks and adjusted rapid molar intruders. *Korean J Orthod.* 2015;45:38–46.
29. Lagravere MO, Major PW, Flores-Mir C. Long-term skeletal changes with rapid maxillary expansion: a systematic review. *Angle Orthod.* 2005;75:1046–1052.
30. Lentini-Oliveira DA, Carvalho FR, Rodrigues CG, et al. Orthodontic and orthopedic treatment for anterior open bite in children. *Cochrane Database Syst Rev.* 2014;(2):CD005515.
31. Chung CH, Font B. Skeletal and dental changes in the sagittal, vertical, and transverse dimensions after rapid palatal expansion. *Am J Orthod Dentofacial Orthop.* 2004;126:569–575.