

Clinical Considerations for Dental Management of Children with Molar-Root Incisor Malformations

Min Jin Kim*/ Ji-Soo Song**/ Young-Jae Kim***/ Jung-Wook Kim****/ Ki-Taeg Jang*****/ Hong-Keun Hyun*****

Molar root-incisor malformation (MRIM) or molar-incisor malformation (MIM) is a new type of dental anomaly characterized by dysplastic roots of permanent first molars, occasionally second primary molars, and the crowns of maxillary central incisors. MRIM involving permanent first molars and second primary molars is characterized by normal crowns with short, thin, and narrow roots, whereas MRIM involving permanent maxillary central incisors exhibits constrictions of the crown in the cervical area. In the first case, we extracted the affected first permanent molars at the optimal timing to minimize space deficiencies and induce space closure. In addition, composite resin restorations were performed on the anterior central incisors. In the second case, a mandibular lingual arch was used to stabilize the affected teeth in order to mitigate discomfort by reducing rotational biting forces.

Keywords: Molar root-incisor malformation, Molar-incisor malformation, Root malformation

INTRODUCTION

Molar root-incisor malformation (MRIM) is a new type of non-inheritable root malformation of first permanent molars characterized by normal crown morphology with a significantly constricted pulp chamber¹⁻³ and short, tapered roots.^{1,3,4} An abnormally mineralized plate, termed a cervical mineralized diaphragm (CMD), is observed at the cemento-enamel junction of the affected teeth, which may be associated with thin, narrow, and short root malformations of first molars.^{1,2,4} It was reported that this type of root malformation could also be found in second primary molars or present as a wedge-shaped defect at the cervical area of the crown in affected maxillary incisors.^{3,4} While molar-incisor malformation (MIM) is one of the suggested terms for these malformations,^{3,4} Wright *et al.*⁵ termed this new unique phenotype Molar Root-Incisor Malformation (MRIM) instead of MIM in order to prevent confusion with other molar-incisor malformations such as Molar-Incisor Hypomineralization (MIH).

MRIM can be differentially diagnosed from other diseases exhibiting root malformations. Dentin dysplasia type I is a hereditary disease that can affect the entire dentition, while MRIM is a non-hereditary disease localized to certain teeth.^{3,4,6,7} Regional odontodysplasia and MRIM are related in that both are non-hereditary and localized to a certain area. However, regional odontodysplasia exhibits thin enamel, large pulp chambers, and affects several adjacent teeth, while MRIM exhibits none of these phenotypes.^{4,8,9} MIH is also similar to MRIM in that both are localized to the first permanent molar and maxillary incisors. However, teeth affected by MIH have compromised enamel with normal roots, while those affected by MRIM exhibit normal enamel with abnormal roots.¹⁰

From the Department of Pediatric Dentistry, Dental Research Institute, School of Dentistry, Seoul National University, Seoul, Republic of Korea.

*Min Jin Kim, DDS.

**Ji-Soo Song, DDS, PhD.

***Young-Jae Kim, DDS, MSD, PhD.

****Jung-Wook Kim, DDS, MSD, PhD.

*****Ki-Taeg Jang, DDS, MSD, PhD.

*****Hong-Keun Hyun, DDS, MSD, PhD.

Send all correspondence to:

Hong-Keun Hyun

Department of Pediatric Dentistry, School of Dentistry, Dental Research Institute

Seoul National University

101 Daehakno, Jongno-gu, Seoul 03080, Republic of Korea

Phone:+ 82-2-2072-3395

E-mail: hegel@snu.ac.kr

The etiological factors of MRIM have yet to be clearly identified, but there is a consensus that MRIM is related to systemic diseases such as neurological compromises or other factors including exposure to medications during the neonatal period, 1-2 years of age,^{3,4} or during the first year of postnatal life.¹ Infections of the central nervous system generally increase body temperature and require the administration of various drugs including antibiotics for management, which may cause enamel hypoplasia.¹¹ However, MRIM-affected molars exhibit normal crown morphology with abnormal roots regardless of the time of onset. Therefore, it is likely that there are secondary contributing factors for MRIM.⁵

First permanent molars are critical for the proper development of dentition and provide sufficient occlusal support and mastication in the permanent dentition. However, due to the difficulties in understanding the etiology of MRIM, there have only been a few studies suggesting possible management options for patients with MRIM. The aim of this study was to identify the clinical characteristics and prognoses of two patients with MRIM and to provide clinical considerations for treatment options including the extraction or preservation of the affected teeth.

Case 1

A seven-year-old boy was referred to the Seoul National University Dental Hospital for root resorption of the mandibular second primary molar and root malformation of the first permanent molar. The patient had a medical history of one-week hospitalization due to a neonatal brain hemorrhage and a history of MRI scans one month and one year after birth. At the first dental visit, root malformations of every second primary molar and first permanent molar were identified on panoramic radiograph (Fig. 1A). The patient's

previous dentist reported that a pulpectomy procedure for the upper right primary central incisor was performed due to its deep caries at four years and nine months of age. The upper left primary central incisor also had dental caries that did not show pulpal involvement, which had been exfoliated spontaneously several months before the first visit to our clinic. There was no known history of dental trauma or oral habits, which was not based on evidence because there were no previous radiographs available for comparison. However, the unerupted permanent central incisors exhibited a cervical notch of the crown on the radiograph (Fig. 1B). The first permanent molars had yet to erupt into the mouth, and there was early loss of the lower right second primary molar. The lower left second primary molar exhibited a high degree of root resorption and increased mobility, and the affected primary molar was extracted at that time. After nine months, the patient re-visited the clinic and was using only the first primary molars and the newly emerged first permanent molars in the lower dentition for mastication. After the full eruption of the lower first permanent molars, a lingual arch space maintainer was placed to stabilize the first permanent molars and to prevent discomfort resulting from their mobility when chewing, rather than to prevent further space loss. After three years, we confirmed that the lower permanent third molar tooth germ was at Demirjian stage A and the lower permanent second molars were ready to emerge. After taking a panoramic radiograph (Fig. 1C), extractions of the bilateral permanent first molars were performed to allow for the eruption of the lower second premolars into the extraction spaces. The extraction spaces were closed with the eruption of the second premolars and the second permanent molars after one year and three months (Fig. 1D). We performed a micro CT analysis (SkyScan 1172, Bruker-microCT, Kontich, Belgium) of the extracted affected

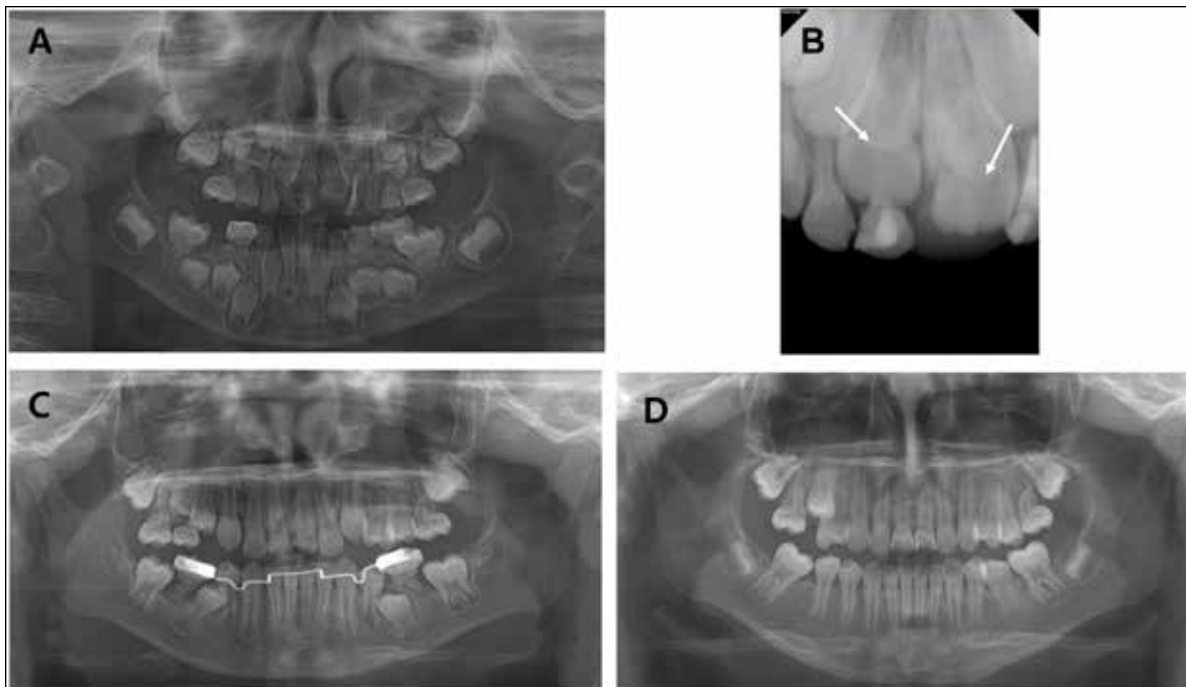


Figure 1. Case 1. (A) Panoramic radiograph and (B) periapical radiograph of a seven-year-old boy with MRIM at the first visit. The bilateral permanent maxillary central incisors had a notch-shaped defect on the crown (white arrow). (C) Three years and nine months later, a panoramic radiograph was taken before the extraction of the symptomatic mandibular first molar. (D) One year and three months after the extraction, space closure was accomplished.

teeth. A constricted cervical region with short, thin, and narrow roots and a mineralized plate were observed at the cemento-enamel junction (Fig. 2A).

In addition, a cone beam computed tomography examination was performed and showed that there were pulp stones in the pulp cavity of the maxillary central incisor (Fig. 2B). Both maxillary central incisors exhibited short clinical crown length, curvature in the labial direction, and wedge-shaped defects in the cervical area (Figs. 2B and 2C and 3A). Approximately half of the labial crowns of both incisors were still covered by gingiva at ten years and eight months (Fig. 3A). At eleven years and ten months, 3/4ths of the crown was erupted and the marginal gingiva was located below the defect of the crown. Since marginal gingivitis and esthetic problems were observed at the defect area, a gingivectomy using an electro-surgical unit (Sensimatic 600SE, Parkell, NY, USA) was performed. After a two-month healing period, the marginal gingiva exhibited no inflammation. After taking clinical photos (Fig. 3B), composite resin restorations for the incisors were performed. Caries detected at the cervical notch were removed with a high speed 1/4-round bur and water without exposure of the pulp. The cavity preparation was lined and light-cured with a resin-modified calcium silicate material (Theracal, Bisco, Chicago, IL, USA) for pulp protection prior to the placement of the composite resin. In order to preserve the remaining

sound tooth structure, we carefully prepared the crown and minimally removed the incisal edge and proximal surface. Metafil CX (Sun Medical, Shiga, Japan) A2 shade composite resin was used to restore the malformed crown and light-cured for 40 seconds on each composite layer less than 2 mm thick and polished using the Sof-Lex disc system (3M ESPE, St. Paul, MN, USA) under rubber dam isolation. After six months, the resin restoration was well-maintained without any clinical symptoms (Fig. 3C).

Case 2

A six-year-old girl complained of discomfort when biting. She had a history of premature birth at 32 weeks (1.94 kg, 44 cm) and had been nursed in the neonatal intensive care unit for 15 days. A cranial ultrasound, echocardiography, pulmonary examinations, and blood tests were performed right after birth and two weeks after birth. No specific systemic diseases were discovered during the examinations. Radiographic images showed that the affected second primary molars were almost rootless, and the first permanent molars had dysplastic roots without any discomfort or mobility (Fig. 4A). Buccal tilting and severe mobility of the lower left second primary molar were observed. Premature loss of the second primary molar was anticipated, and a lingual arch was installed to stabilize the first permanent molars. The MRIM-affected second primary molars

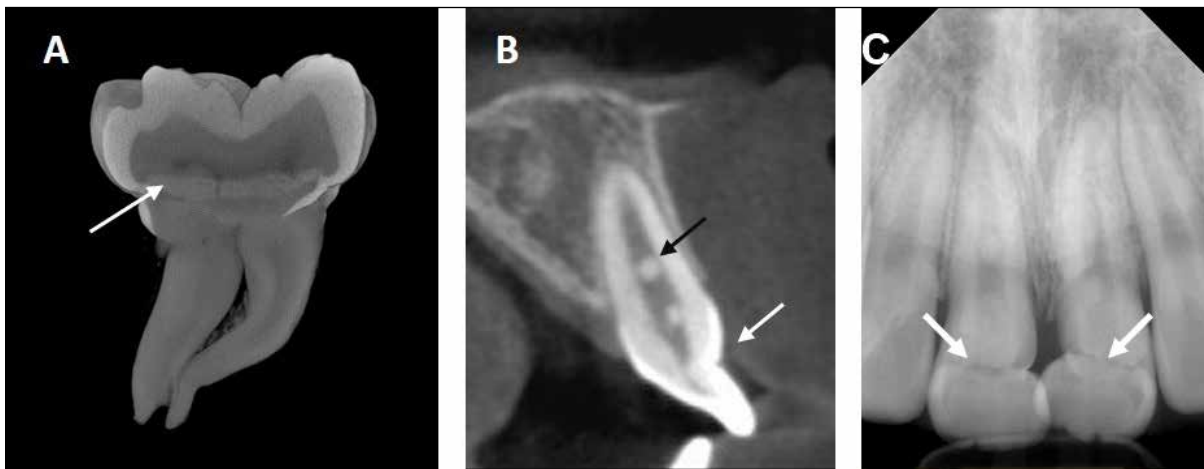


Figure 2. Case 1. (A) Sagittal section of the Micro CT image. Extracted lower right first permanent molar exhibiting cervical mineralized diaphragms (white arrow). (B) Sagittal section from the CBCT showing pulp stones of the maxillary central incisor (black arrow), labial curvature, and wedge-shaped defects (white arrow). (C) Periapical radiograph showing the MRIM affected maxillary central incisors. The white arrow indicates a wedge-shaped defect on the one-third portion of the crown.

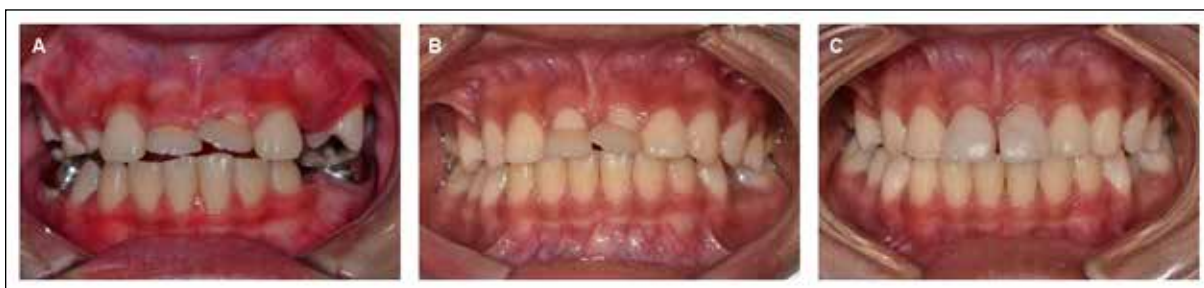

Figure 3. Case 1, Intraoral photograph. (A) At ten years and eight months of age, approximately half of the labial aspect of the crowns of the maxillary central incisors were still covered by gingival tissue. (B) A gingivectomy was performed when 3/4th of the crowns were erupted. Both incisors exhibit good gingival margins two months after the gingivectomy. (C) Composite resin restorations were performed for the incisors. The incisor crowns were in good condition six months after the restorations were performed.

Downloaded from http://meridian.allenpress.com/jcpd/article-pdf/44/1/55/2466749/1053-4625-44_1_10.pdf by guest on 18 September 2024

were lost during follow-up. After treatment with a lingual arch for over two years, there was no tooth mobility or tenderness to bite on the affected permanent molar. It was observed that the succedaneous second premolars erupted spontaneously and replaced the second primary molars without any loss of space (Fig. 4B). It was planned that the lingual arch be retained if the patient did not experience discomfort on the affected teeth due to their root resorption caused by the eruption of the second permanent molars.

DISCUSSION

MRIM or MIM is generally characterized by a normal-shaped molar crown with root malformation.¹⁻⁴ Pain and mobility of the affected tooth with alveolar bone loss around the affected molar root may be observed in MRIM without any signs of caries or crown deformities. Previous studies have also reported that MRIM-affected molars may have weak root support and an increased possibility of furcation exposure due to the prolonged mesial angulation of the first molar, thus increasing the risk of periodontal problems, subgingival caries, and abscess formation.^{3,12}

In Case 1, the first permanent molars presented a marked mesial eruption pathway before they erupted at the first visit (Fig. 1A). The mesial encroachment of the lower right and left first permanent molar crowns into the distal root of the second primary molars and the insufficient root development of the second primary molars could have possibly contributed to the loss of the lower left and right second primary molars. In terms of extraction or maintenance, Case 1 involved the extractions of the affected mandibular first permanent molars with poor prognosis during the eruption stage of the second premolars, resulting in the successful guidance of space closure. The ideal timing for extractions of affected first permanent molars has been reported to be at the chronological ages of 8-10 years,¹³ while subsequent studies have argued that the developmental stage of the second permanent molar, the mesial angulation of the second molar, and the presence of the third molar are also critical factors that must be considered.^{14,15} In Case 1, there was insufficient space for second premolar eruption, and the extraction of the first molar was performed at age 11 when the third molar tooth germ was at Demirjian stage A and the second permanent molar exhibited mesial angulation and calcification in the bifurcation area. Although it was thought to be late considering the chronological age, the spaces were successfully closed through the eruption of the second permanent premolar and molar.

Enamel defects on succedaneous teeth can be related either to mechanical injuries to primary predecessors¹⁶ or to the presence of

periradicular infection in the predecessor primary tooth before the pulpectomy procedure.¹⁷ It should be remembered that the crown dysplasia of the upper permanent central incisors may also be caused by the trauma or the infection of the previous primary incisors in Case 1 if it is not based on evidence including previous radiographs. In previous studies, maxillary incisors affected by MRIM can be easily identified because of their short clinical crown lengths, buccal curvatures, and v-shaped notches at 1/3-1/2 of the labial cervical area of the crown.^{3,5,18,19} and we also have observed the same findings in Case 1 (Figs. 2B and 2C and 3A). Most of the incisors have esthetic problems, gingivitis, and even caries due to the difficulty in keeping the notch area clean.^{3,5} Therefore, crown restorations with good gingival margins are necessary for the affected incisors. Previous studies have reported that some of the maxillary incisors affected by MRIM exhibited *dens invaginatus* and pulpal obstructions without caries.⁵ Interestingly, pulp stones in the pulp cavity of the affected incisors were observed through sagittal CT radiographs (Fig. 2B), the first of its kind reported on MRIM affected teeth to our knowledge. We performed a gingivectomy to contour the crown and clearly visualize the gingival margin for the placement of a composite resin restoration when more than 3/4ths of the crown including the area of the notch was exposed. A gingivectomy with electrosurgery was helpful to quickly stop the bleeding and easily contour the crown in the cervical area through the elimination of gingival marginal inflammation that could lead to inaccurate identification of the cervical line of the affected gingiva. Minimal preparation of the crown and indirect pulp treatment with a cavity liner could be recommended in order to minimize the risk of endodontic treatment and to preserve the tooth structure and its vitality.

Case 2 showed that even severely affected first permanent molars could be preserved through lower lingual arch stabilization if no periodontal issues were present. We planned to maintain and stabilize the first permanent molars until the second permanent molar was able to replace the function of the affected first permanent molars because early extraction of the first permanent molar could have resulted in several complications including severe tipping eruption of the mandibular second permanent molar, over eruption of the opposing upper permanent molar, incomplete space closure, poor mesial contact area of the second molar, and poor mastication.²⁰ Therefore, a lingual arch was used to prevent the premature loss of the mandibular second primary molar and to maintain the first molar in order to distribute the forces concentrated on the molars in the distal area of the second primary molar. The patient experienced

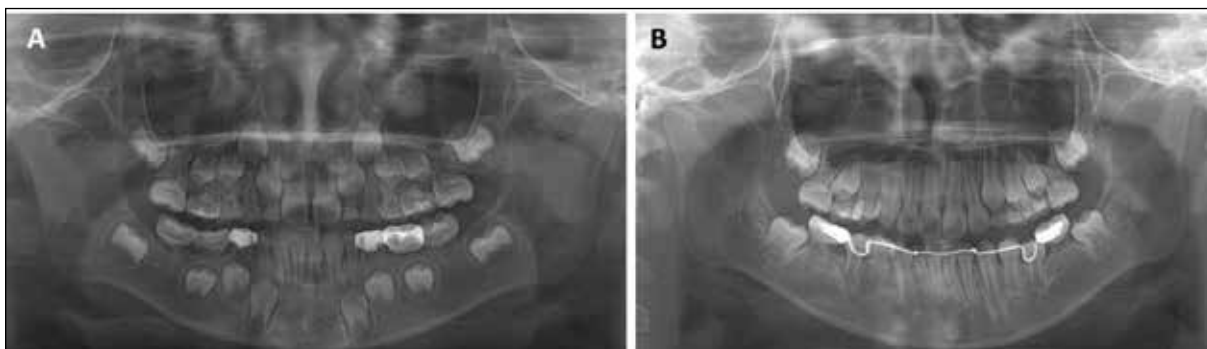


Figure 4. Case 2. (A) Panoramic radiograph of a six-year-old girl with MRIM at the first visit. (B) Two years after installation of the lingual arch, the second premolars replaced the second primary molars.

no pain, mobility, functional limitations, and periodontal problems with the affected teeth. The third molar tooth germ was not clearly identified during the early follow-up period. The affected molars may be extracted strategically if necessary for orthodontic or prosthodontic treatment in the future even if they are asymptomatic.

If the second primary molar is also affected as seen in Cases 1 and 2, its morphological characteristics including diminished root formation at the cervical area may cause the mesial encroachment of the adjacent first permanent molar. This condition may also cause the mesial rotation of the first permanent molar, eruption space deficiency, or impaction of the succedaneous second premolars and early loss if unable to be diagnosed early.² As observed in the CT images (Fig. 2A), the radiopaque mineralized plate at the cemento-enamel junction is a typical characteristic found in teeth affected by MRIM.¹ According to a previous study with histopathological analysis, the radiopaque plates consist of moderately mineralized collagen fibers and connective tissue which may be evidence that the dental follicle could be considered as the possible origin of this plate.¹ Damage to the vascular plexus at the base of the dental papilla during crown development may enable serum and/or fluid to enter the follicular interstitial spaces, creating calcified globules or CMD.¹ Consequently, CMD may act as a mechanical obstacle inhibiting normal dentinogenesis and root development. MRIM-affected molars with short and malformed roots may not erupt on time and may not guide the adjacent teeth to the right eruption pathway shown as in Cases 1 and 2.

Permanent first molars are important for mastication and occlusion, and problems involving these teeth are considered to negatively influence the growth of a patient.³ The purpose of splinting two affected permanent molars with lingual arch in Cases 1 and 2 is to decrease three-dimensional movement, distribute occlusal forces to the immobile tooth, and reduce discomfort.^{21,22} Cross-arch splints are recommended versus unilateral splints, which are vulnerable to movement in the facio-lingual direction.²² The lingual arch is a cross-arch, passive stabilization appliance with a long span in the mixed dentition. Therefore, it may be less harmful to be linked to the first molar on the opposite side. It may also reduce rotational biting forces and mitigate discomfort during biting. It may be meaningful if the lingual arch could help patients with their masticatory function without discomfort until the eruption of premolars to aid in chewing function. However, further studies are necessary to determine the clinical benefits of using a lingual arch for first permanent molars affected with MRIM.

CONCLUSION

MRIM is associated with clinical problems such as space loss, mesial encroachment of the distal tooth, spontaneous pain, gingivitis, and/or poor incisor esthetics. Therefore, clinicians must be able to diagnose MRIM early with the help of radiographs including a panoramic radiograph to determine whether to extract or preserve the affected teeth depending on the clinical features. Symptoms of the affected molar, eruption path of the second permanent molar, developmental stage of the second and third permanent molars, and overall space deficiency should be comprehensively considered before performing extractions. A composite resin restoration for affected maxillary central incisors with minimal preparation and cavity liner placement may also be considered after a gingivectomy at the appropriate time.

REFERENCES

1. Witt CVA, Hirt T, Rutz G, Luder HU. Root malformation associated with a cervical mineralized diaphragm—a distinct form of tooth abnormality?. *Oral Surg Oral Med Oral Pathol Oral Radiol* 117(4): 311-319, 2014.
2. Luder HU. Malformations of the tooth root in humans. *Front Physiol* 27: 4-5, 2015.
3. Lee HS, Kim SH, Kim SO, Lee JH, Choi HJ, Jung HS, Song JS. A new type of dental anomaly: molar-incisor malformation (MIM). *Oral Surg Oral Med Oral Pathol Oral Radiol* 118(1): 101-109, 2014.
4. Lee HS, Kim SH, Kim SO, Choi BJ, Cho SW, Park W, Song JS. Microscopic analysis of molar-incisor malformation. *Oral Surg Oral Med Oral Pathol Oral Radiol* 119(5): 544-552, 2015.
5. Wright JT, Curran A, Kim KJ, Yang YM, Nam SH, Shin TJ, Hyun HK, Kim YJ, Lee SH, Kim JW. Molar root-incisor malformation: considerations of diverse developmental and etiologic factors. *Oral Surg Oral Med Oral Pathol Oral Radiol* 121(2): 164-172, 2016.
6. O Carroll MK, Duncan WK, Perkins TM. Dentin dysplasia: review of the literature and a proposed subclassification based on radiographic findings. *Oral Surg Oral Med Oral Pathol* 72(1): 119-125, 1991.
7. Toomarian L, Mashhadiabbas F, Mirkarimi M, Mehrdad L. Dentin dysplasia type I: a case report and review of the literature. *J Med Case Rep* 4: 1-6, 2010.
8. Fanibunda KB, Soames JV. Odontodysplasia, gingival manifestations, and accompanying abnormalities. *Oral Surg Oral Med Oral Pathol Oral Radiol Endod* 81(1): 84-88, 1996.
9. Crawford PJ, Aldred MJ. Regional odontodysplasia: a bibliography. *J Oral Pathol Med* 18(5): 251-263, 1989.
10. Weerheijm KL. Molar Incisor Hypomineralisation (MIH). *Eur J Paediatr Dent* 4(3): 115-120, 2003.
11. Crombie F, Manton D, Kilpatrick N. Aetiology of molar-incisor hypomineralization: a critical review. *Int J Paediatr Dent* 19(2): 73-83, 2009.
12. McCreedy C, Robbins H, Newell A, Mallya SM. Molar-incisor malformation: Two cases of a newly described dental anomaly. *J Dent Child* 83(1): 33-37, 2016.
13. Thunold K. Early loss of the first molars 25 years after. *Rep Congr Eur Orthod Soc* 349-365, 1970.
14. Cobourne MT, Williams A, Harrison M. National clinical guidelines for the extraction of first permanent molars in children. *Br Dent J* 217(11): 643-648, 2014.
15. Patel S, Ashley P, Noar J. Radiographic prognostic factors determining spontaneous space closure after loss of the permanent first molar. *Am J Orthod Dentofacial Orthop* 151(4): 718-726, 2017.
16. Skaare AB, Maseng Aas AL, Wang NJ. Enamel defects in permanent incisors after trauma to primary predecessors: inter-observer agreement based on photographs. *Dent Traumatol* 29(2):79-83, 2013.
17. Coll JA, Sadrian R. Predicting pulpectomy success and its relationship to exfoliation and succedaneous dentition. *Pediatr Dent* 18(1):57-63, 1996.
18. Yue W, Kim E. Nonsurgical endodontic management of a Molar-Incisor Malformation-affected mandibular first molar: A case report. *J Endod* 42(4): 664-668, 2016.
19. Brusevold IJ, Bie TMG, Baumgartner CS, Das R, Espelid I. Molar incisor malformation in six cases: Description and diagnostic protocol. *Oral Surg Oral Med Oral Pathol Oral Radiol* 124(1): 52-61, 2017.
20. Welbury R, Duggal MS, Hosey MT. *Paediatric Dentistry*, 4th edition. Oxford, UK: Oxford university press, 284-288, 2012.
21. Kathariya R, Devanoorkar A, Golani R, Shetty N, Vallakarla V, Bhat MY. To Splint or Not to Splint: The Current Status of Periodontal Splinting. *J Int Acad Periodontol* 18(2): 45-56, 2012.
22. Bernal G, Carvajal JC, Muñoz-Viveros CA. A review of the clinical management of mobile teeth. *J Contemp Dent Pract* 3(4): 10-22, 2002.