

# Distal Migration and Ectopic Eruption of the Mandibular First Premolar: Case Report

Avia Fux-Noy\*

*Migration describes the movement of an unerupted tooth within the bone when normal eruption is prevented and the tooth leaves its normal site of development. This report describes a case of distal migration and ectopic eruption of the mandibular first premolar in an 8.5-year-old boy. Following early extraction of the primary second molar, the first premolar migrated distally through the extraction site of the primary second molar and erupted into occlusion just mesial of the permanent first molar.*

**Keywords:** Migration, Ectopic eruption, First premolar

## INTRODUCTION

Tooth dislocation, which is the eruption of a tooth in a position ordinarily occupied by another tooth, may result from migration. This process takes place only when normal eruption is prevented and the tooth leaves its normal site of development within the bone<sup>1</sup>. Intrabony migration (also referred to as intraosseous migration), is the movement of an unerupted tooth within the bone<sup>1-4</sup>. This is a rare and unusual developmental dental anomaly that occurs only in the permanent dentition of the lower jaw<sup>1,2</sup>. It involves the mandibular lateral incisor, the canine, and the second premolar. The mechanism that causes tooth migration is still obscure<sup>1-3</sup>.

Migration may occur as a result of a localized pathologic process, such as a cystic lesion or an odontoma, a supernumerary tooth, severe crowding, or retained primary teeth. Displacement from the normal path of eruption may occur, however, for unknown reasons, with no clear relationship between the displaced permanent tooth and the usually cited etiologic factors<sup>1</sup>. Some reports suggest that canine migration is congenitally inherited<sup>1,2</sup>. Distal displacement and intrabony migration of the mandibular second premolar are idiopathic<sup>1</sup>.

This report describes a case of distal migration and ectopic eruption of the mandibular first premolar, following early extraction of the primary second molar.

## Case report

A healthy six-year-old boy arrived at the dental clinic complaining that “a filling fell out”. Clinical examination revealed that the mandibular right primary second molar was mobile, with pathological root resorption, deep and extensive caries. Radiographic examination demonstrated root resorption and periradicular bone resorption (Fig.1). The tooth was diagnosed with extensive coronal caries and chronic periapical abscess and could not be restored. A week later the tooth was extracted. A band and loop space maintainer was cemented two weeks post-extraction.

The patient was invited to periodic follow-up examinations every six months, but arrived after nine and 16 months. Uneven root resorption of the primary first molar was detected in the bite-wing radiograph after 16 months (Fig.2). The distal root was resorbed almost completely, while the mesial root was not resorbed.

Thirteen months later, the patient arrived with a complaint that “the permanent tooth erupted into the loop of the space maintainer”. Clinical examination revealed eruption of the premolar. The space maintainer was removed (fig.3). Radiographic examinations (Fig.4) revealed that the erupting tooth was the first premolar.

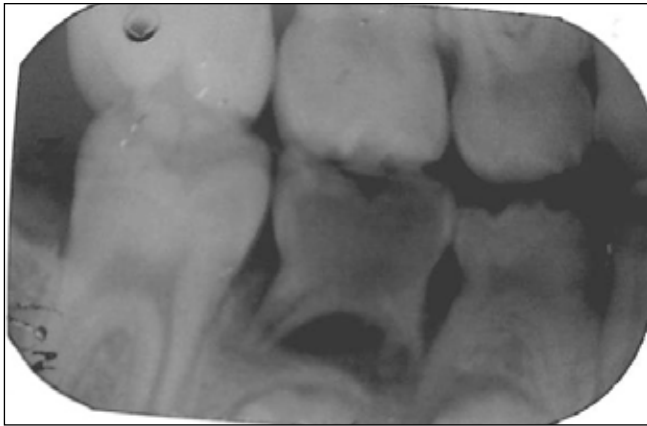
\* Avia Fux-Noy, DMD, Department of Pediatric Dentistry, the Hebrew University- Hadassah School of Dental Medicine, Jerusalem, Israel.

Send all Correspondence to:

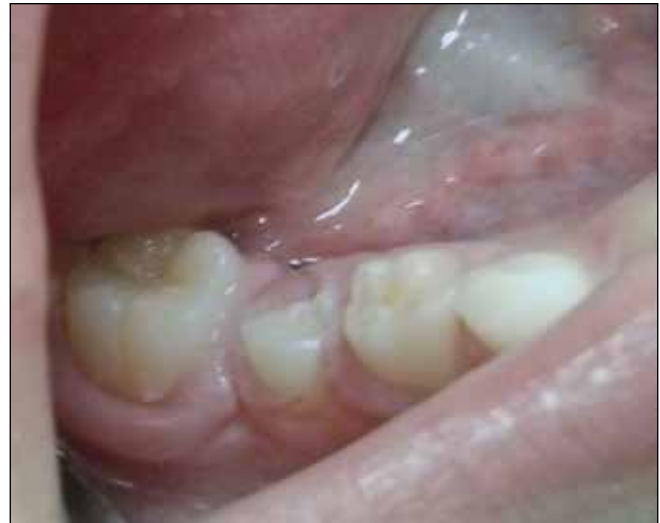Avia Fux-Noy, Department of Pediatric Dentistry, Hadassah School of Dental Medicine, P.O.Box 12272, Jerusalem 9112102, Israel.

Phone: 972-2-6776135

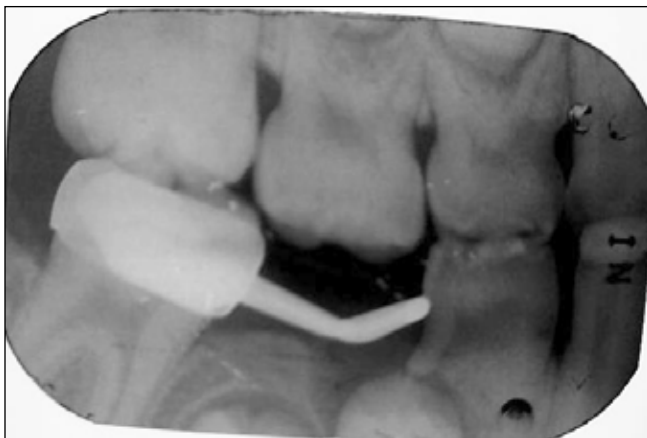E-mail: Aviyh\_cl3@hadassah.org.il



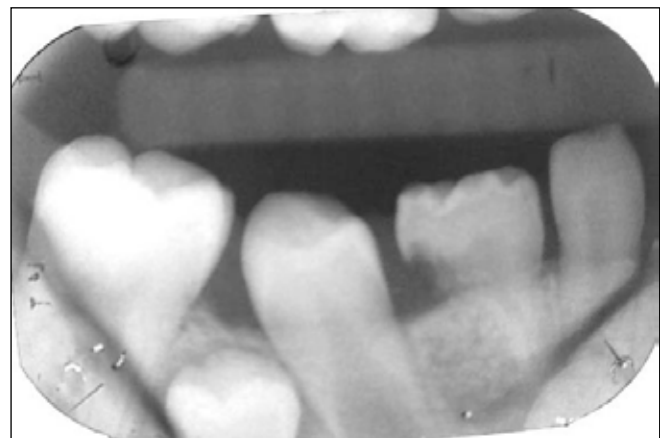
**Figure 1:** Right bite-wing radiograph, demonstrating deep and extensive caries and periradicular bone resorption of the mandibular primary second molar.



**Figure 3:** Clinical appearance immediately after removal of the space maintainer.



**Figure 2:** Right bite-wing radiograph after 16 months, demonstrating distal root resorption of the mandibular primary first molar.



**Figure 4:** Radiographic image, demonstrating eruption of the mandibular first premolar, distal to the first primary molar.

## DISCUSSION

This report describes a case of distal migration and ectopic eruption of the mandibular first premolar. Fixed space maintainers are usually indicated to maintain the space created by unilateral/bilateral premature loss of primary teeth in one of the arches. Though the band and loop is widely used in cases of early extraction of the second primary molar<sup>5</sup>, this is the first report of distal migration and ectopic eruption of the first premolar in patients in whom this appliance was used.

Since the distal root of the primary first molar was resorbed and the primary second molar was extracted early, the first premolar migrated distally to the extraction site of the second primary molar, and then erupted into occlusion just mesial of the permanent first molar.

We would expect early extraction of the primary second molar with interradicular bone resorption to accelerate eruption of the second premolar. Premature loss of maxillary primary molars considerably accelerates the emergence of premolars. In the mandible, early tooth loss has been shown to promote earlier

eruption, except in the lower premolar region, where it has a neutral to mild delaying effect on eruption<sup>6,7</sup>.

The eruption pathway, which involves bone resorption and resorption of primary tooth root, seems to be a genetically programmed event<sup>8</sup>. In permanent tooth eruption, the dental follicle and stellate reticulum seem to play important roles in the resorption of primary root. In primary teeth, root resorption starts at the root of the primary tooth that is closest to the permanent successor. Uneven root resorption occurs in more than one-third of all primary lower second molars. The incidence of uneven root resorption is lower for primary first molars. This is probably due to the smaller difference between their inter-root distance and the size of the follicles of their successors<sup>8</sup>.

Moorrees *et al* examined the development of primary teeth and their root resorption pattern. They found that mesial roots begin to resorb earlier than distal roots in most primary molars<sup>9</sup>. In contrast, Peretz *et al* reported that 55% of root resorption in the primary mandibular first molar was in the distal root, while resorption in that tooth was symmetrical in approximately 41 percent. In addition,

mandibular premolars were mostly located distal to the long axis of the primary first and second molars<sup>10</sup>.

Mandibular premolar tooth buds may develop with varying degrees of distal inclination under the distal root of the primary second molar<sup>4,11</sup>. Distally inclined lower second premolars usually rotate upward and mesially into occlusion, as they contact the permanent first molar in the course of eruption<sup>4</sup>. When a permanent first molar is extracted at an early age, prior to eruption of the second premolar, the chance of distal migration of the second premolar is 5-10%. A distally inclined premolar may erupt along its long axis, or actually tip towards the extraction site<sup>2,4</sup>.

In the current case, a bite-wing radiograph taken at the first visit showed that the right first premolar was located symmetrically between the primary first molar roots (Fig.1). Periradicular bone resorption of the primary second molar led to bone regression that enabled the first premolar to migrate to this area, since the path of least resistance probably determines the direction of movement of the migrating tooth<sup>1</sup>.

Uneven root resorption of the primary first molar was seen in the bite-wing radiograph after 16 months (Fig.2). The diagnosis of uneven root resorption should have prompted removing the space maintainer and extracting the primary first molar, to facilitate correct eruption of the first premolar. Such intervention would have helped to avoid the corrective orthodontic intervention that was needed.

Replacing the band and loop and cementing a lingual arch space maintainer should be considered according to particular patient factors, and according to the evaluated risk of mesial tipping or drifting of the permanent first molar.

The significance of this case report is in its raising awareness among pediatric dentists to the possibility of first premolar distal migration and ectopic eruption, following extraction of mandibular primary second molars with periradicular bone resorption, despite the use of a band and loop space maintainer.

## CONCLUSION

Dentists should be aware of the possibility of first premolar distal migration and ectopic eruption, following extraction of mandibular primary second molars with periradicular bone resorption. In such cases, root resorption of the primary first molar, and the eruption pathway of the first premolar, should be monitored radiographically and early orthodontic intervention when needed.

## REFERENCES

1. Shapira Y, Kufinec MM. Intrabony migration of impacted teeth. *Angle Orthod.* 7: 738-43, 2003.
2. Peck S. On the phenomenon of intraosseous migration of nonerupting teeth. *Am J Orthod Dentofac Orthop.* 113: 515-7, 1998.
3. Sutton PRN. Migration and eruption of non-erupted teeth: A suggested mechanism. *Aust Dent J.* 14 :269-70, 1969.
4. Matteson SR, Kantor ML, Proffit WR. Extreme distal migration of the mandibular second bicuspid. A variant of eruption. *Angle Orthod.* 52: 11-8, 1982.
5. Setia V, Pandit IK, Srivastava N, Gugnani N, Sekhon HK. Space maintainers in dentistry: past to present. *J Clin Diagn Res.* 7: 2402-5, 2013.
6. Kerr WJS. The effect of the premature loss of deciduous canines and molars on the eruption of their successors. *Eu J Orthod;* 2: 123-8, 1980.
7. Leroy R, Bogaerts K, Lesaffre E, Declerck D. Impact of caries experience in the deciduous molars on the emergence of the successors. *Eur J Oral Sci.* 111: 106-10, 2003.
8. Harokopakis-Hajishengallis E. Physiologic root resorption in primary teeth: molecular and histological events. *J Oral Sci.* 49: 1-12, 2007.
9. Moorrees CE, anning EA, Hunt EE Jr. Formation and resorption of three deciduous teeth in children. *Am J Phys Anthropol.* 21: 205-13, 1963.
10. Peretz B, Nisan S, Herteanu L, Blumer S. Root resorption patterns of primary mandibular molars and location of the premolar successors: a radiographic evaluation. *Pediatr Dent.* 35: 426-9, 2013.
11. Stemm RM. The frequency of malposed unerupted lower premolar teeth. *Angle Orthod.* 41: 157-8, 1971.